



# ORIGINAL: Comparison between Percutaneous Lateral Osteotomy and Endonasal Lateral Osteotomy in Primary Rhinoplasty

Hiwa Asaad Abdulkareem  
Haval Ahmed Hama

Sulaymaniyah Teaching Center and Medical College, Kurdistan Region, Iraq.  
Sulaymaniyah Teaching Center and Medical College, Kurdistan Region, Iraq

## ARTICLE INFO

**Submitted:** 20 Dec 2019  
**Accepted:** 31 Mar 2020  
**Published:** 31 Jun 2020

### Keywords:


**Percutaneous osteotomy;**  
**Endonasal osteotomy;**  
**Open rhinoplasty**

### Correspondence:

**Hiwa Asaad Abdulkareem,**  
Assistant Professor at Sulaymaniyah  
Teaching Center and Medical  
College, Kurdistan Region, Iraq.  
**Email:** vizhowan2018@gmail.com  
**ORCID:** 0000-0003-1513-6384

### Citation:

Abdulkareem HA, Hama HA.  
Comparison between percutaneous  
lateral osteotomy and endonasal  
lateral osteotomy in primary  
rhinoplasty. *Tabari Biomed Stu Res*  
*J.* 2020;2(2):29-37.

 10.18502/tbsrj.v2i2.3756

## ABSTRACT

**Introduction:** Open rhinoplasty is a popular method to correct nasal deformities, which is commonly carried out by percutaneous or endonasal techniques. Despite their advantages, these two techniques can also be associated with some disadvantages. The present study was carried out in order to examine the functional and aesthetic outcomes of percutaneous and endonasal osteotomies.

**Material and Methods:** The present comparative study was carried out on 50 patients who underwent percutaneous osteotomy (25 cases) and endonasal osteotomy (25 cases) from August 2018 to September 2019. Before and three days, eight days, and three months after the surgeries, the required data were collected through medical and psychological assessments.

**Results:** According to the results, the mean age of the patients was  $28.7 \pm 6.5$  years, and most of them were females with a female-to-male ratio of 4:1. It was also concluded that percutaneous and endonasal lateral osteotomies were not significantly different in terms of the postsurgical pain felt by the patients, epistaxis, skin scars 21 days and three months after the rhinoplasty, nasal obstruction, closing the open roof deformity, state of correction, patient satisfaction, age, and gender ( $p > 0.05$ ). However, they were significantly different regarding periorbital edema, periorbital ecchymosis, and skin scars during the first eight days after the surgery ( $p < 0.05$ ).

**Conclusion:** Both percutaneous and endonasal lateral osteotomies were found to be useful methods to carry out rhinoplasty because both led to acceptable functional and aesthetic results regarding decreased pain, epistaxis, periorbital edema and ecchymosis, skin scar, nasal obstruction, closing the open roof deformity, and nasal deviation correction and increased patient satisfaction

## Introduction

Most of nasal deformities is corrected by carrying out rhinoplasty, which is a popular procedure to reshape and resize the nose in esthetic surgery (1, 2). The final stage of esthetic surgery is usually associated with lateral osteotomies which are typically conducted in a poor visual field and

only through touching (3, 4). That is why osteotomies have been reported to be associated with a high risk of damaging the periosteum, the supporting tissues, and the mucosa (5). In this regard, osteotomy is considered an ideal method if it leads to a minimum level of damage to the soft tissue

and its outcome can be predictable and reproducible (6). Other unfavorable complications of lateral osteotomy, as indicated by research, include excessive narrow nose, elevated ecchymosis, excessive edema, excessive mobilization of the nose, excessive bleeding, and increased damage to the intranasal mucosa periosteum (7, 8). Moreover, performing lateral osteotomy by conventional techniques has been reported to lead to trauma to the surrounding tissues involving vessels, nerves, and mucosa (9). After dorsal hump resection, lateral osteotomy is carried out either percutaneously or endonasal in order to close the open roof of the nose, correct the deviation of bony noses, narrow the upper third of the nose, and fix the curved lateral nasal wall (10, 11). Conducting osteotomy through either percutaneous (external) or endonasal (internal) techniques, are associated with advantages and disadvantages. Both techniques have been reported to make osteotomy easier to perform, less traumatic, and more controllable and predictable (12, 13). Moreover, percutaneous technique has been shown to decrease the risk of mucosal injury and non-precise fractures (14); however, it can lead to undesirable, visible scars (15). Also, endonasal technique has no the risk of any scar formation (16); however, the need for an additional intranasal incision to approach the pyriform aperture is the disadvantage of this method, which however allows the cut of a smooth osteotomy line with less bony irregularities and fragmentation (17). *Figures 1* and *2* respectively indicate how percutaneous and endonasal lateral osteotomy are carried out. Excessive narrowing of the nose, rhinoplasty deformity, ecchymosis, prolonged edema, excessive hemorrhage, and destabilization after the surgery are among the damage to intranasal mucosa that can form as a result of lateral osteotomy which can be conducted either externally (percutaneous) or internally (endonasal) (20). In this regard, the present study was carried out in order to compare these two techniques of osteotomy and their

advantages and disadvantages and figure out the best way for osteotomy in open rhinoplasty.

## Methods

### Study design

The present research was a comparative study that was conducted on 50 patients (40 females and ten males) aged between 17 and 50 years who underwent a primary rhinoplasty in the Center of Otolaryngology of Head and Neck Surgery in Teaching Hospital of Sulaymaniyah, Iraqi Kurdistan from August 1st 2018 to September 1st 2019.

### Data collection

In order to gather the required data, meticulous preoperative history was taken from all of the patients who had been evaluated for aesthetic and functional complaints. A medical and psychological evaluation was made for some patients, psychological problem, moderate allergic rhinitis, and chronic rhinosinusitis, who were excluded from the study.

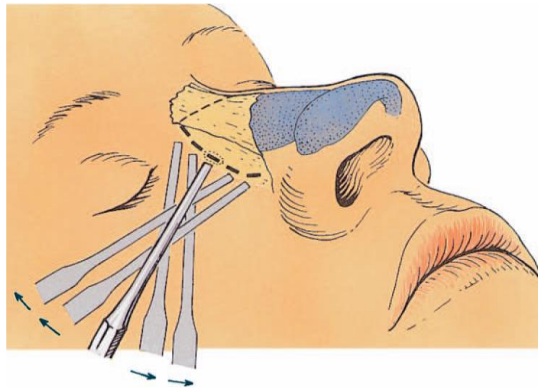
The checkup started through inspecting the face for examining the facial elements and relation of the nose to different facial elements and diagnosing any asymmetry. Furthermore, interior examination of the nasal cavity was carried out so as to have a look at the state of mucosal lining, septum, and internal nasal valve.

Routine preoperative investigations which include biochemical and hematological investigations (i.e. CBC, blood group and Rh, blood urea, bleeding time, and clotting time) according to the case had been carried out. Moreover, viral examinations have been performed. In addition, preoperative images computed tomography or x-ray (from frontal, basal, lateral oblique, right, and left views) had been taken from each patient. Preoperative consent for operation was also taken from the patients.

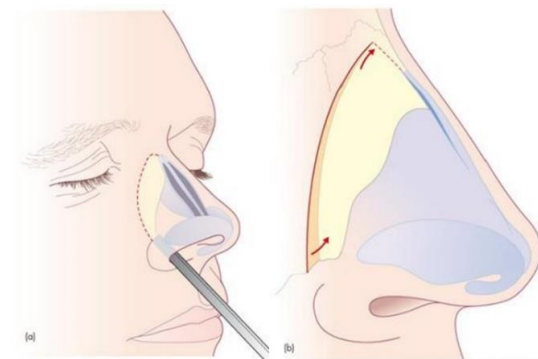
### Sample size

The patients have been positioned in a reverse Trendelenburg position, infiltration of

Lidocaine (1%) in mixture with (1:100,000) epinephrine was used.



**Figure 1. Percutaneous lateral osteotomy making small point osteotomies along the planned osteotomy line (18)**



**Figure 2. Endonasal low-to-low lateral and medial oblique osteotomies, movement**

Endonasal lateral osteotomy was carried out in 25 cases, and percutaneous lateral osteotomy in 25 cases.

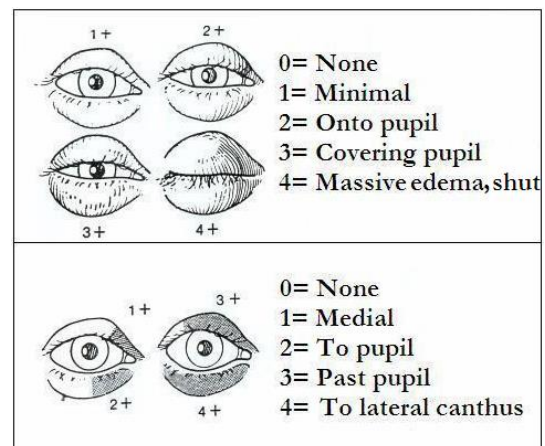
During endonasal lateral osteotomy, the lateral osteotomy was once achieved with the aid of giving small incision at pyriform aperture just anterior to the level of attachment of inferior turbinate. Using the periosteal elevator, the periosteum used to be elevated in accordance with the length of the nasal bone. The osteotome was engaged and handed alongside the (nasofacial groove). The fingers of other hand usually guided the motion of the osteotome.

In percutaneous lateral osteotomy, a stab incision was given halfway alongside the deliberate osteotomy line. The tip of 2 mm osteotome used to be firmly forced against the bone. It was incised cleanly with tip of osteotome via sweeping the osteotome up and down at the proposed line of osteotomy, and

perforation of the bone used to be carried out with a 2 mm sharp osteotome. Multiple-site bone perforation was executed by rotating the osteotome up and down from the same skin incision, and the bone was perforated at 2 mm interval.

In order to examine the consequences of the operations, the following follow-up process was taken into account:

1. During the 1st to the third postoperative days, nasal packing used to be removed, and the Scoring of Periorbital Edema and Ecchymosis was used to check and score the patients' pain subjectively and objectively primarily based on their facial expression, bleeding, periorbital edema, and periorbital ecchymosis (**Figure 3**).



**Figure 3. Scoring of periorbital edema and ecchymosis (21)**

2. After eight days, internal nasal silastic splints and external plaster of Paris have been removed, and the patients were assessed for their pain, bleeding, periorbital edema, periorbital ecchymosis, and nasal obstruction through Cold Spatula Test and Cotton Strip Test.

3. After 21 days, the patients were viewed and assessed for their pain, skin scar, and nasal obstruction.

4. After three months, all of the patients were assessed functionally and aesthetically based on final alignment, skin scar, and correction state of the deviated nasal bone.

Finally, the collected data were analyzed through appropriate statistical tests using SPSS version 21.

## Results

As revealed by the analysis of the collected data, mean age of the patients was  $28.7 \pm 6.5$  years with a minimum of 17 years and maximum of 50 years. Regarding their gender, (80%) of the patients were females, with a female-to-male ratio of 4:1. Half of the patients underwent endonasal lateral osteotomy and half of them received percutaneous lateral osteotomy (*Table 1*).

According to the results, the level of the pain after the operation had a decreasing trend in both endonasal and percutaneous cases, such that 37 patients had pain in 1st to third days after the operation, which decreased to 20 on the 8th day, and six on the 21st day. Therefore, endonasal lateral osteotomy and percutaneous lateral osteotomy were not significantly different in terms of the pain felt by the patients ( $P < 0.05$ ).

In terms of bleeding after operation (epistaxis), the results indicated that only five patients with endonasal lateral osteotomy and 5 with percutaneous lateral osteotomy had epistaxis during the 1st to third days after the operation, and the two methods were not significantly different in this regard.

The results showed that endonasal lateral osteotomy and percutaneous lateral osteotomy were significantly different in terms of the number of periorbital edemas after operation ( $P < 0.001$ ), such that percutaneous lateral osteotomy led to fewer periorbital edemas than endonasal lateral osteotomy during the first eight days after the operation.

According to the results, there was a significant difference between the two

techniques (endonasal lateral osteotomy and percutaneous lateral osteotomy) in terms of the number of periorbital ecchymoses during the 8 days after the operation ( $P < 0.001$ ) such that fewer periorbital ecchymoses were observed in cases with percutaneous lateral osteotomy than endonasal lateral osteotomy. It was also observed that the two techniques were significantly different in terms of skin scars during the first 8 days after the operation ( $p = 0.01$ ) endonasal cases experiences no skin scars, while 7 percutaneous cases did. However, the two techniques were not significantly different during the 21st day and 3rd month after the operation regarding skin scar. The two techniques were not found significantly different in terms of nasal obstruction after the operation; however, percutaneous lateral osteotomy led to fewer cases of nasal obstruction. Moreover, the two techniques were not significantly different in terms of open roof deformity ( $P > 0.05$ ); however, endonasal lateral osteotomy led to fewer cases of open roof deformity (*Table 2*). The results also revealed that the two techniques (endonasal lateral osteotomy and percutaneous lateral osteotomy) were not significantly different in terms of correction state, patient satisfaction, age, and gender (*Table 3*).

## Discussion

Rhinoplasty is performed in order to fix functional or aesthetic deficits. One of the most widely used techniques of rhinoplasty is lateral osteotomy which can be conducted either internally (endonasal) or externally

**Table 1. The patients' demographic information**

Variables	Frequency	Percentage
<b>Age range</b>		
< 18	1	2
18 - 24	13	26
25 - 34	27	54
$\geq 35$	9	18
<b>Gender</b>		
Female	40	80
Male	10	20
<b>Type of osteotomy</b>		
Endonasal lateral osteotomy	25	50
Percutaneous lateral osteotomy	25	50

**Table 2. Clinical features in the endonasal and percutaneous cases**

Variables		Endonasal cases	Percutaneous cases	P-value	
<b>Postsurgical pain</b>					
1st-3rd day	Yes	20 (54.1)	17 (45.9)	0.333	
	No	5 (38.5)	8 (61.5)		
8th day	Yes	11 (55.0)	9 (45.0)	0.564	
	No	14 (46.7)	16 (53.3)		
21th day	Yes	2 (33.3)	4 (66.7)	0.667	
	No	23 (52.3)	21 (47.7)		
<b>Epistaxis</b>					
1st-3rd day	Yes	5(50.0)	5(50.0)	1.000	
	No	20(50.0)	20(50.0)		
<b>Periorbital edemas</b>					
1st-3rd day	1	0	7 (100.0)	<0.001*	
	2	11 (40.7)	16 (59.3)		
	3	14 (87.5)	2 (12.5)		
8th day	0	0	2 (100.0)	<0.001*	
	1	6 (24.0)	19 (76.0)		
	2	14 (82.4)	3 (17.6)		
3	3	5 (83.3)	1 (16.7)		
	<b>Periorbital ecchymosis</b>				
	1st-3rd day	1	0	7 (100.0)	<0.001
2		8 (32.0)	17 (68.0)		
3		17 (94.4)	1 (5.6)		
8th day	0	0	2 (100.0)	<0.001	
	1	4 (17.4)	19 (82.6)		
	2	17 (81.0)	4 (19.0)		
3	3	4 (100.0)	0		
	<b>Skin scars</b>				
	1st-3rd day	Yes	0	7 (100.0)	0.010
No		25 (58.1)	18 (41.9)		
8th day	Yes	1 (16.7)	5 (83.3)	0.189	
	No	24 (54.5)	20 (45.5)		
21th day	Yes	0	4 (100.0)	0.110	
	No	25 (54.3)	21 (45.7)		
<b>Nasal obstruction</b>					
8th day	Yes	5 (62.5)	3 (37.5)	0.702	
	No	20 (47.6)	22 (52.4)		
21th day	Yes	4 (80.0)	1 (20.0)	0.349	
	No	21 (46.7)	24 (53.3)		
3rd month	Yes	2 (50.0)	2 (50.0)	1.000	
	No	23 (50.0)	23 (50.0)		
<b>Open roof deformity</b>					
3rd month	Yes	1 (25.0)	3 (75.0)	1.000	
	No	24 (52.2)	22 (47.8)		

(percutaneous). However, the final result of this technique can vary widely depending on the surgeon's preference and experience (20). The present study was an attempt to figure out the performance and results of endonasal lateral osteotomy and percutaneous lateral osteotomy regarding the patients' pain, scars, periorbital edema, periorbital ecchymosis, nasal obstruction, and patient satisfaction, and the results revealed that both techniques were acceptable in these regards. The present

study was carried out on 50 patients whose age range was 17 to 59 years with a mean of 28.7 ( $\pm$  6.5) years. Most of the patients were females, such that the female-to-male ratio was 4:1. Unlike the present study, the results of the study conducted by Kim et al. (2019) showed that most of the patients were males, such that the male-to-female ratio was 4.45:1. However, their mean age (29.2 years) was similar to that of the present study (22). The results of the present study demonstrated that

most of the patients belonged to the age group 25-34 years. This finding is in good agreement with the results of the study carried out by Parsa et al. (2019) who reported that the majority of those who had undergone facial surgery were between 25 to 34 years (23).

The results showed that the two techniques (endonasal lateral osteotomy and percutaneous lateral osteotomy) were not significantly different regarding the postoperative pain felt by the patients during the first 21 days after the operation. However, as indicated in *Table 2* above, the pain perceived by the patients decreased over time, such that it declined from 37 cases during the first 3 postsurgical days to 6 cases on the 21st day. In line with this finding, Akbas et al. (2004) reported that rhinoplasty conducted by percutaneous technique is accompanied by pain immediately following the surgery; however, the pain declines remarkably over a period of 3 months (24). Also, Rettinger (2007) reported pain, fibrosis, and atrophy immediately after rhinoplasty, performed by any techniques, whose intensity decreases in over a period of time (25).

The results revealed that 5 patients in each group had postoperative epistaxis (nasal bleeding) during the first 3 days following the surgery. This finding is in line with that of the study by Argi and Hosnuter (2003) who compared the clinical outcomes of rhinoplasty through hump resection and lateral osteotomy and reported a low percentage of bleeding after the surgery (26). Also, Becker et al. (2000) reported that lateral osteotomy can lead to increased bleeding after surgery which decreases within a few days after the rhinoplasty (27). According to the results of the present study, endonasal lateral osteotomy and percutaneous lateral osteotomy were not significantly different in terms of epistaxis. Similar results were reported by Ghavimi et al. (2018) and Motamed et al. (2017) who reported that both internal and external lateral osteotomies can lead to bleeding which remarkably declines over a short period of time (7, 8).

The results of the study showed that percutaneous lateral osteotomy and endonasal lateral osteotomy were significantly different in terms of periorbital edema during the first 8 days after the surgery, such that percutaneous lateral osteotomy led to fewer edemas than the endonasal lateral osteotomy. Moreover, the number of edemas in both techniques decreased remarkably over the time. In line with the present study, Ghavimi et al. (2018) concluded that external lateral osteotomy led to less edema than piezosurgery osteotomy (7). These findings are also in line with those of the study performed by Kiliç et al. (2015) who reported that both internal and external lateral osteotomies are typically accompanied by periorbital edema and ecchymosis which decrease remarkable over the first week after surgery (28).

The two techniques were also significantly different regarding periorbital ecchymosis after the surgery, such that percutaneous lateral osteotomy led to less ecchymosis than endonasal lateral osteotomy. This finding is in line with the results of the study conducted by Öğreden et al. (2018) who found that percutaneous lateral osteotomy technique led to less ecchymosis, bone and periosteal trauma and better bone healing (29). In addition, Caglar et al. (2016) pointed out that carrying out lateral osteotomy in the final stages of surgery followed by applying a nasal plaster and splint as fast as possible can lead to a decrease in ecchymosis during the postoperative period (30).

Regarding postoperative skin scars, the results showed a significant difference between endonasal and percutaneous cases, such that during the first 8 days after the surgery, endonasal osteotomy has no skin scars, while percutaneous osteotomy led to 7 cases. However, percutaneous technique has not significantly skin scar during the 21st day and 3rd month. These findings are in agreement with those reported by Gryskiewicz (2004) who concluded that percutaneous osteotomies leave very few visible scars in 6% of the cases, which can also be avoided if sufficient care is taken

**Table 3. Correction state, patient satisfaction, age, and gender differences in the endonasal and percutaneous cases**

Variables	Endonasal cases	Percutaneous cases	P-value	
State of correction	Yes	22 (51.2)	21 (48.8)	1.000
	No	3 (42.9)	4 (57.1)	
Patient satisfaction	Not accepted	2 (40.0)	3 (60.0)	1.000
	Accepted	6 (50.0)	6 (50.0)	
	Good result	12 (50.0)	12 (50.0)	
	Very good (excellent)	5 (55.6)	4 (44.4)	
Age	< 18	1 (100.0)	0	1.000
	18 – 24	7 (53.8)	6 (46.2)	
	25 – 34	13 (48.1)	14 (51.9)	
	≥35	3 (44.4)	5 (55.6)	
Gender	Female	19 (47.5)	21 (52.5)	0.480
	Male	6 (60.0)	4 (40.0)	

while cleansing the chisel prior to percutaneous entry (31).

The two techniques were not significantly different regarding nasal obstruction after surgery, such that both of them led to few cases of nasal obstruction; 8 cases during 8 days after the surgery, 5 cases by the 21st days, and 4 cases by 3rd month. Similar findings were reported by Tasman (2007) who reported that rhinoplasty is typical associated with nasal obstruction due to the inconvenience of nasal packs and mucosal swelling; however, it decreases remarkably after nasal packs are removed and the swelling fades away (6). Occurrence of nasal obstruction has also been reported by other studies, most of which fade away after 3 months following the surgery (32, 33).

According to the results, the two techniques were not significantly different in terms of open roof deformity, such that endonasal technique led to 1 case and percutaneous to 3 cases by in the 3rd month after the surgery. This finding is in line with the reports by Tasman (2007) who pointed out the success on lateral osteotomy in closing open roof deformity in rhinoplasty (6). Similar results have also been reported by other previously conducted studies which introduced percutaneous or endonasal lateral osteotomies as effective techniques to narrow the upper third of the nose, fix the curved lateral nasal wall, and close the open roof of the nose (10, 11).

The results also showed that the two techniques were not significantly different in

terms of correction state, patient satisfaction, age, and gender. As seen above, the results demonstrated that deviation of the nose was corrected in most of the cases (86%). This finding is in line with the study conducted by Vikas et al. (2007) who reported that both external (percutaneous) and internal (endonasal) osteotomies are effective techniques to corrected deviated noses (34). Similar findings were also reported by Cho and Jang (2013) (35). In terms of patient satisfaction, the results showed that only 10% were not satisfied, while the rest were satisfied. This finding is in line with those reported by Becker et al. (2000), who reported acceptable patient satisfaction after lateral osteotomy (36). Similarly, Rohrich et al. (2001) pointed out that an external perforated technique can increase patient's satisfaction with the final work (37).

### Conclusion

Both percutaneous and endonasal osteotomies are useful and almost equally effective in bringing about acceptable aesthetic and functional outcomes of rhinoplasty including decreased pain, epistaxis, periorbital edema and ecchymosis, skin scar, nasal obstruction, closing the open roof deformity, and nasal deviation correction and increased patient satisfaction. Percutaneous lateral osteotomy outperforms endonasal lateral osteotomy regarding pain, periorbital edema, periorbital ecchymosis, and nasal obstruction, while endonasal lateral osteotomy has a better performance in terms

of skin scars, state of correction, and patient satisfaction. It can be concluded that both percutaneous and endonasal osteotomies can be effectively successful techniques for rhinoplasty.

### **Acknowledgments**

Special thanks Sulaymaniyah Teaching Center and Medical college, Kurdistan region, Iraq to support this project.

### **Conflicts of interest**

The authors declare that there is no conflict of interest regarding the publication of this article.

### **Authors' contributions**

Study design: H.A.A.

Writing: H.A.H, H.A.A.

Final revision: All authors

### **References**

1. Kalantar-Hormozi A, Ravar R, Abbaszadeh-Kasbi A, Rita Davai N. Teenage Rhinoplasty. *World J Plast Surg.* 2018;7(1):97–102.
2. Rudy SF, Most SP. Rhinoplasty. *JAMA.* 2017;318(14):1406. doi:10.1001/jama.2017.13267
3. Rod J, Rohrich, Jeffrey E. Janis, Osteotomies in Rhinoplasty: An Updated Technique. *Aesthetic Surgery Journal.* 2003; 23(1):56–58
4. Inaba Y, Kobayashi N, Ike H, Kubota S, Saito T. Computer-Assisted Rotational Acetabular Osteotomy for Patients with Acetabular Dysplasia. *Clin Orthop Surg.* 2016;8(1):99–105.
5. Rho BI, Lee IH, Park ES. Visible Perforating Lateral Osteotomy: Internal Perforating Technique with Wide Periosteal Dissection. *Arch Plast Surg.* 2016;43(1):88–92.
6. Tasman AJ. Rhinoplasty - indications and techniques. *GMS Curr Top Otorhinolaryngol Head Neck Surg.* 2007;6:Doc09.
7. Ghavimi MA, Nezafati S, Yazdani J, et al. Comparison of edema and ecchymosis in rhinoplasty candidates after lateral nasal osteotomy using piezosurgery and external osteotomy. *J Adv Pharm Technol Res.* 2018;9(3):73–79.
8. Motamed S, Saberi A, Niazi F, Molaei H. Complications of Internal Continuous and Perforating External Osteotomy in Primary Rhinoplasty. *World J Plast Surg.* 2017;6(2):164–169.
9. Gerbault O, Daniel RK, Kosins AM. The Role of Piezoelectric Instrumentation in Rhinoplasty Surgery. *Aesthetic Surgery Journal.* 2016;36(1):21–34
10. Meyer R. Crooked nose. In: Gruber RP, Peck GC, editors. *Rhinoplasty: State of the Art.* St. Louis: Mosby; 1993.
11. Byrd HS, Salomon J, Wood J. Correction of the crooked nose. *Plast Reconstr Surg.* 1998;102(6):2148-57.
12. Gyskiewicz JM, Gyskiewicz KM: Nasal osteotomies: A clinical comparison of the perforating methods versus the continuous technique. *Plast Reconstr Surg.* 2004;113(5):1445-56.
13. Becker DG, McLaughlin RB, Loevner LA, et al: The lateral osteotomy in rhinoplasty: Clinical and radiographic rationale for osteotome selection. *Plast Reconstr Surg.* 2000; 105(5):1806-6.
14. Rohrich, RJ. Osteotomies in rhinoplasty: an updated technique. *Aesthet Surg J.* 2003;23(1):56-8.
15. Gyskiewicz JM. Visible scars from percutaneous osteotomies. *Plast Reconstr Surg.* 2005; 116(6):1771-5.
16. Ghassemi A, Prescher A, Talebzadeh M, Holzle F, Modabber A. Osteotomy of the Nasal Wall Using a Newly Designed Piezo Scalpel—A Cadaver Study. *Journal of Oral and Maxillofacial Surgery.* 2013;71(12):2155-e1.
17. Ghassemi A, Ayoub A, Modabber A, Bohluli B, Prescher A. Lateral nasal osteotomy: a comparative study between the use of osteotome and a diamond surgical burr - a cadaver study. *Head & face medicine.* 2013;9(1):41.



18. Nolst Trenite GJ. Surgery of the osseo cartilaginous vault: A practical Guide to the functional and aesthetic of the Nose. 2005, 11:100-104
19. Rowe-Jones JM, Reduction rhinoplasty, Scott-Browns otorhinology. Head and Neck surgery, 2008,3:2950-6.
20. Pizzamiglio, D.S., & Berger, C.A. Comparative study of continuous lateral osteotomy and microperforating osteotomy in patients undergoing primary rhinoplasty. International archives of otorhinology. 2012;16(3):382-386.
21. Hashemi M, Mokhtarinezhad F, Omrani M. A Comparison Between External Versus Internal Lateral Osteotomy in Rhinoplasty. Journal of Research in Medical Sciences. 2005;10(1):10-5
22. Kim SD, Park JH, Seo HS, Lee DJ, Lee YM, Cho KS. Comparative Analysis of Endonasal Lateral Osteotomy and Percutaneous Lateral Osteotomy in Patients with Deviated Nose. Korean J Otorhinology-Head Neck Surg. 2019 Mar;62(3):171-175.
23. Parsa KM, Gao W, Lally J, Davison SP, Reilly MJ. Evaluation of Personality Perception in Men Before and After Facial Cosmetic Surgery. JAMA facial plastic surgery. 2019;21(5):369-74.
24. Akbas H, Guneren E, Eroglu L, Uysal OA, Akpolat I. A painful neuroma in the nose following aesthetic rhinoplasty. Plast Reconstr Surg. 2004;113(2):766-768.
25. Rettinger G. Risks and complications in rhinoplasty. GMS Curr Top Otorhinology Head Neck Surg.2007;6:Doc06.
26. Kargi E, Hosnuter M. Effect of steroids on edema, ecchymosis and intraoperative bleeding in rhinoplasty. Ann Plast Surg. 2003;51(6):570-4.
27. Becker DG, McLaughlin RB, Loevner LA, Mang A. The lateral osteotomy in rhinoplasty: clinical and radiographic rationale for osteotome selection. Plast Reconstr Surg. 2000;105(5):1806-6.
28. Kiliç C, Tuncel Ü, Cömert E, et al. Effect of the rhinoplasty technique and lateral osteotomy on periorbital edema and ecchymosis. J Craniofac Surg. 2015; 26(5):e430-3.
29. Öğreden Şahin, Rüzgar Sedat, Tansuker Hasan Deniz, Taşkın Ümit, Alimoğlu Yalçın, Aydın Salih et al. Histopathological comparison of bone healing effects of endonasal and percutaneous lateral osteotomy methods in rabbit rhinoplasty model. Braz. j. otorhinology. 2018, 84(5):540-544.
30. Caglar E, Celebi S, Topak M, Develioglu NO, Yalcin E, Kulekci M, et al. How can periorbital oedema and ecchymose be reduced in rhinoplasty? Eur Arch Otorhinology. 2016;273(9):2549-54.
31. Gryskiewicz JM. Visible scars from percutaneous osteotomies. Plast Reconstr Surg. 2005;116(6):1771-5.
32. Gryskiewicz JM, Gryskiewicz KM: Nasal osteotomies: A clinical comparison of the perforating methods versus the continuous technique. Plast Reconstr Surg. 2004;113(5):1445-56.
33. Rohrich RJ, Janis JE, Adams WP, et al: An update on the lateral nasal osteotomy in rhinoplasty: An anatomic endoscopic comparison of the external versus the internal approach. Plast Reconstr Surg. 2003; 111(7):2461-2.
34. Vikas S, Devang G, More Y, Prajapati B, Kedia KB, Shashank S. External vs. internal osteotomy in rhinoplasty. Indian journal of otolaryngology and head and neck surgery: official publication of the Association of Otolaryngologists of India. 2007; 59(1):9-12.
35. Cho GS, Jang YJ. Deviated nose correction: different outcomes according to the deviation type. Laryngoscope. 2013;123(5):1136-1142.
36. Becker DG, McLaughlin R, Loevner L, Mang A. The Lateral Osteotomy in Rhinoplasty: Clinical and Radiographic Rationale for Osteotome Selection. Plastic and reconstructive surgery. 2000; 105(5):1806-6.
37. Rohrich, RJ, Krueger, JK, Adams, WP, and Hollier, LH Jr. Achieving consistency in the lateral nasal osteotomy during rhinoplasty: an external perforated technique. Plast Reconstr Surg. 2001; 108(7):2122-30.