

Treatment of Proximal Humerus Varus Deformity Secondary to Neonatal Glenohumeral Septic Arthritis: A Case Report

Reza Shahriar Kamrani¹, Kian Zohrabi^{2,*}

¹ Professor, Department of Orthopedic and Trauma Surgery, Shariati Hospital, School of Medicine, Tehran University of Medical Sciences, Tehran, Iran

² Clinical Fellowship Candidate, Department of Orthopedic Surgery, Shariati Hospital, School of Medicine, Tehran University of Medical Sciences, Tehran, Iran

*Corresponding author: Kian Zohrabi; Department of Orthopedic Surgery, Shariati Hospital, School of Medicine, Tehran University of Medical Sciences, Tehran, Iran. Tel: 21-84901000, Email: k_zohrabi@yahoo.com

Received: 08 April 2022; Revised: 14 June 2022; Accepted: 04 July 2022

Abstract

Background: Proximal humerus shortening and varus can occur secondary to neonatal shoulder septic arthritis and focal fibrocartilage dysplasia. Valgus osteotomy of the proximal humerus compensates for a little bite of shortening, and improves the shoulder joint's range of motion.

Case Report: In this study, we present two patients with severe proximal humerus deformity following glenohumeral septic arthritis. Both of them underwent valgus osteotomy, and had a satisfactory result in terms of range of motions and cosmesis at five years follow-up.

Conclusion: Treatment of varus deformity of proximal humerus is challenging issue. There are few reports of surgical treatment. Severe varus deformity of proximal humerus impacts the motion of shoulder. We reported a novel method of valgus osteotomy of proximal humerus in patients with severe varus deformity secondary to neonatal septic arthritis and long-term clinical follow-up.

Keywords: Humerus; Osteotomy; Arthritis; Shoulder

Citation: Shahriar Kamrani R, Zohrabi K. Treatment of Proximal Humerus Varus Deformity Secondary to Neonatal Glenohumeral Septic Arthritis: A Case Report. *J Orthop Spine Trauma* 2022; 8(3): 104-6.

Background

Proximal humerus shortening and varus can occur secondary to neonatal shoulder septic arthritis and focal fibrocartilage dysplasia. Proximal humerus varus makes not only an exaggeration of shortening, but also a limitation of the shoulder abduction. Valgus osteotomy of the proximal humerus compensates for a little bite of shortening, and improves the shoulder joint's range of motion (1, 2). Here we present two patients with severe proximal humerus varus deformity secondary to neonatal glenohumeral septic arthritis with long-term follow-up.

Case Report

Patient 1: A 14-years-old boy came to us with shortening and limited shoulder range of motion (Figure 1). He had a history of hospitalization when he was 20 days old with a diagnosis of sepsis. After six weeks of intravenous antibiotic therapy, he healed from systemic symptoms; but after three years, he showed humerus shortening. At the age of 8 years, he underwent humerus lengthening with a unilateral external fixator. At 10 years old, he underwent valgus osteotomy for his cubitus varus as a complication of lengthening. Finally, at the age of 14, he underwent his last operation as valgus osteotomy. At the time of final surgery, physical examination showed 6-cm clinical shortening, and shoulder range of motion was 80, 90, 30, and 30 degrees of abduction, forward flexion, and internal and external rotation, respectively. Antero-posterior radiography showed 80 degrees of neck-shaft angle.

Patient 2: A 13-years-old girl came to our center with limited shoulder range of motion and shortening. She had no previous medical history. At her first visit to our

hospital, she had a 5-cm shortening of the humerus. The range of motions of the shoulder were 90, 100, 30, and 40 degrees of abduction, flexion, and external and internal rotation, respectively. Antero-posterior radiography showed 90 degrees of neck-shaft angle.

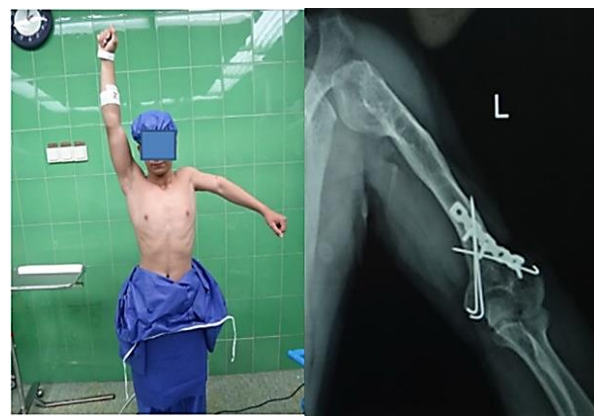

Figure 1. Preoperative photograph and radiography in patient 1

Technique

With general anesthesia and in supine position with a sandbag under affected extremity, with deltopectoral approach, a Synthes Philos plate was placed on the proximal humerus; under the guide of C-arm, the proper position of the plate was confirmed.

The proximal part of humeral head was fixed with two locking screws and with two preliminary K-wire. Then, the plate was removed while the pins were kept in place (Figure 2).



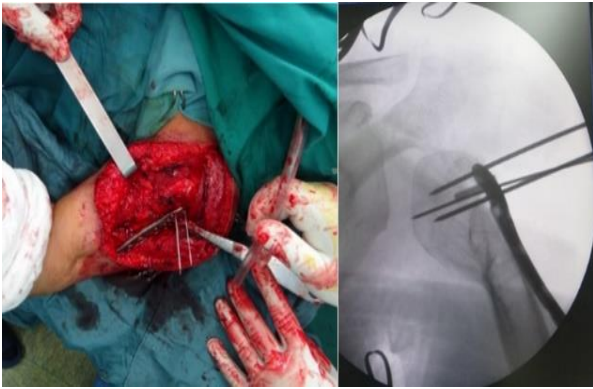


Figure 2. Intraoperative photography and fluoroscopy

The plate was bent as much as the preoperative plan determined (Figure 3). It was 60 degrees in the first patient and 50 degrees in the second patient. The plate was fixed on the same place by passing the pins through plate's holes, and fixed it with previous screws and with one or two additional screws at the proximal part.

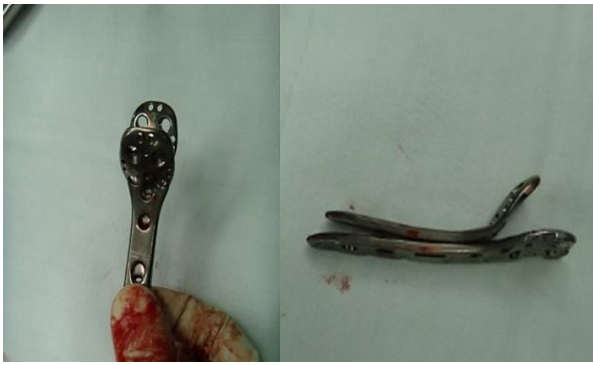

Figure 3. Bending of the Philos plate

Osteotomy was done at the site of plate bending, and the distal segment of the plate was held with a bone holder to the shaft of the humerus. The shaft of the humerus was pushed to the plate; so an open wedge osteotomy was created. The plate was fixed to the shaft of humerus (Figure 4). The wound was repaired layer by layer without any bone graft or bone substitute. The patient were allowed for normal activity, and were advised to avoid heavy working till the radiologic union.

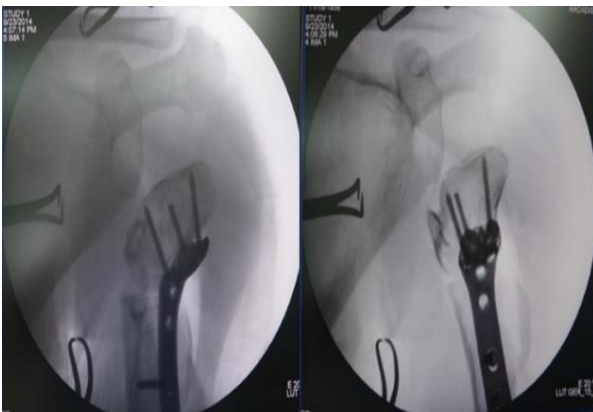


Figure 4. Intraoperative fluoroscopy

Discussion

Proximal humerus varus deformity following septic arthritis is rare, but worsens the disability of the patient who has a short humerus. Valgus osteotomy is a rational treatment to improve function (3). However, it may cause non-union exacerbation of the infection, abduction contraction, and impingement syndrome (4). The best implant and technique for predictable reduction has not been proposed (3, 5). Bending a plate makes it weak at bend point, but it is a usual treatment in adapting a plate to a bone in treating a fracture. Philos plate is a strong instrument, and it resists breakage even with bending, especially in an adolescent patient.

Our study demonstrated the valgus osteotomy is safe and practical with good clinical outcome in long follow-up. We found in our two patients that open valgus osteotomy with a bent Philos plate is safe, reliable, and effective treatment without expected complications.

Conclusion

This report indicates that open valgus osteotomy can be used as an influence treatment for varus deformity of proximal humerus. Bone union was achieved in both patients in three months (Figure 5). At five years follow up, abduction and flexion improved to 140 and 160 in the first patient and 160 and 180 in the second patient. There was no pain or any sign of impingement in our patients. Both of them were satisfied with the improvement of their function and cosmesis.

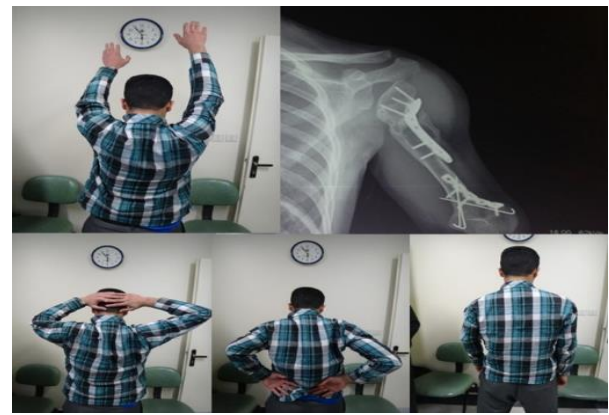

Figure 5. Postoperative photography and radiography

Conflict of Interest

The authors declare no conflict of interest in this study.

Acknowledgements

None.

References

1. Saisu T, Kawashima A, Kamegaya M, Mikasa M, Moriishi J, Moriya H. Humeral shortening and inferior subluxation as sequelae of septic arthritis of the shoulder in neonates and infants. *J Bone Joint Surg Am.* 2007;89(8):1784-93. Doi: [10.2106/JBJS.E.01021](https://doi.org/10.2106/JBJS.E.01021). [PubMed: [17671019](https://pubmed.ncbi.nlm.nih.gov/17671019/)].
2. Panjavi B, Kalantar SH. Assessment of a new test in diagnosing pediatric septic arthritis. *J Orthop Spine Trauma.* 2020;4(2): 38-9. Doi: [10.18502/jost.v4i2.2969](https://doi.org/10.18502/jost.v4i2.2969).
3. Miao W, Wu Y, Wu G, Wang B, Jiang H. Valgus osteotomy of the proximal humerus to treat humerus varus in children. *J*

- Pediatr Orthop.* 2015;35(7):746-50. Doi: [10.1097/BPO.0000000000000366](https://doi.org/10.1097/BPO.0000000000000366). [PubMed: [25494029](https://pubmed.ncbi.nlm.nih.gov/25494029/)].
4. Sano H, Kamimura M, Oizumi A, Isefuku S. Secondary subacromial impingement after valgus closing-wedge osteotomy for proximal humerus varus. *Case Rep Orthop.* 2015;2015:652096. Doi: [10.1155/2015/652096](https://doi.org/10.1155/2015/652096). [PubMed: [26000187](https://pubmed.ncbi.nlm.nih.gov/26000187/)]. [PubMed Central: [PMC4427088](https://pubmed.ncbi.nlm.nih.gov/PMC4427088/)].
 5. Mothes FC, Britto A, Matsumoto F, Tonding M, Ruaro R. Application of three-dimensional prototyping in planning the treatment of proximal humerus bone deformities. *Rev Bras Ortop.* 2018;53(5):595-601. Doi: [10.1016/j.rboe.2018.07.016](https://doi.org/10.1016/j.rboe.2018.07.016). [PubMed: [30258825](https://pubmed.ncbi.nlm.nih.gov/30258825/)]. [PubMed Central: [PMC6148713](https://pubmed.ncbi.nlm.nih.gov/PMC6148713/)].