

# Intra-Pelvic Penetration of Broken Guide Wire during Fixation of Hip Fracture: Presentation of a Case and Review of Literature

Mehrdad Sadighi<sup>1</sup>, Meisam Jafari Kafiabadi<sup>1</sup>, Farsad Biglari<sup>2\*</sup>, Mohammadreza Chehrassan<sup>1</sup>, Amin Karami<sup>3</sup>, Adel Ebrahimpour<sup>4</sup>

<sup>1</sup> Assistant Professor, Department of Orthopedic Surgery, Shohada Tajrish Hospital, Shahid Beheshti University of Medical Sciences, Tehran, Iran

<sup>2</sup> Surgeon, Department of Orthopedic Surgery, Shohada Tajrish Hospital, Shahid Beheshti University of Medical Sciences, Tehran, Iran

<sup>3</sup> Resident, Department of Orthopedic Surgery, Shohada Tajrish Hospital, Shahid Beheshti University of Medical Sciences, Tehran, Iran

<sup>4</sup> Professor, Department of Orthopedic Surgery, Shohada Tajrish Hospital, Shahid Beheshti University of Medical Sciences, Tehran, Iran

\*Corresponding author: Farsad Biglari; Department of Orthopedic Surgery, Shohada Tajrish Hospital, Shahid Beheshti University of Medical Sciences, Tehran, Iran. Tel: +98-9125193843, Email: biglari.farsad@gmail.com

Received: 01 November 2020; Revised: 24 December 2020; Accepted: 09 February 2021

## Abstract

**Background:** The application of a cannulated device is a widely used fixation method for hip fractures. Although the breakage of the guide wire during this procedure is an uncommon complication, migration of the broken fragment might be catastrophic.

**Case Report:** We presented a case of intertrochanteric fracture with breakage of the lag screw guide wire in the acetabulum during fixation with cephalomedullary nail. The broken fragment was located with computed tomography (CT) scan and removed through Stoppa approach.

**Conclusion:** We found the Stoppa approach a safe and useful method for extracting the intra-pelvic broken guide wire.

**Keywords:** Hip Fractures; Orthopedic Fixation Device; Intraoperative Complication; Bone Pins; Bone Screws

**Citation:** Sadighi M, Jafari Kafiabadi M, Biglari F, Chehrassan M, Karami A, Ebrahimpour A. **Intra-Pelvic Penetration of Broken Guide Wire during Fixation of Hip Fracture: Presentation of a Case and Review of Literature.** *J Orthop Spine Trauma* 2021; 7(1): 31-3.



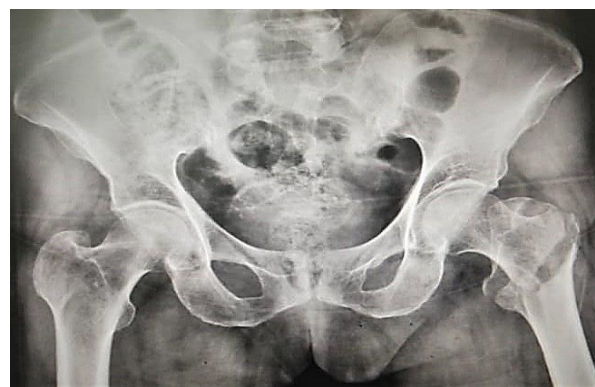## Background

In recent decades, the hip fracture has become a major worldwide health problem due to the growing elderly population. It is estimated that the global annual incidence of hip fractures will rise from 1.6 million in 2000 to 4.5 million by 2050 (1).

Although arthroplasty is the treatment of choice in some elderly patients, most cases are treated with cannulated devices such as cannulated screw, dynamic compression hip screw, and cephalomedullary nail (2). The role of the guide wires is pivotal in the proper positioning of the fixation device or reamer (3). Despite the rarity of guide wire breakage during fixation, the neurovascular or urologic complications due to the possible intra-pelvic penetration and migration of the broken fragment is catastrophic (2). Therefore, it is necessary to be familiar with the causes of guide wire breakage to reduce the risk of major complications. Here, we presented a case of intra-pelvic penetration of a broken guide wire during fixation of hip fracture and discussed the possible etiology and management.

## Case Report

An 83-year-old female was admitted to the orthopedic ward with intertrochanteric fracture caused by falling. The patient's weight and height were 56 kg and 170 cm, respectively [body mass index (BMI): 19.3 kg/m<sup>2</sup>]. Her past medical history was unremarkable except for osteoporosis. On radiographic assessments, the fracture pattern was compatible with type 31-A2 AO Foundation and Orthopedic Trauma Association (AO/OTA) fracture classification (Figure 1).



**Figure 1.** Preoperative radiograph of the left hip with intertrochanteric fracture [AO Foundation and Orthopedic Trauma Association (AO/OTA) type 31-A2]

The significant osteoporosis was in accordance with type B of Dorr et al. classification (4). After preoperational consultations, the patient was scheduled for fixation with cephalomedullary nail.

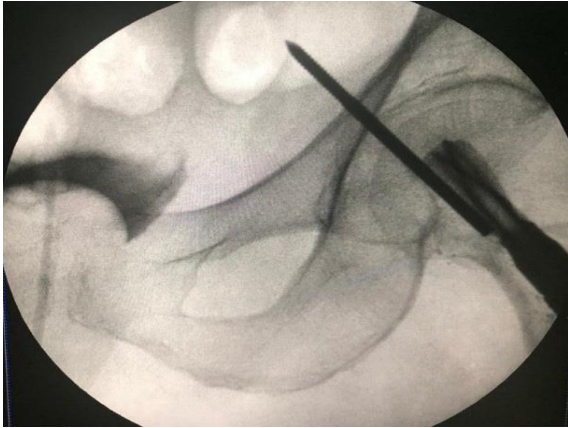
The patient was operated under spinal anesthesia and in a supine position. After correction of posterior sagging, the reduction was achieved by the maneuver of flexion, traction, and internal rotation of the hip. The reduction was confirmed by anteroposterior (AP) and lateral views of intraoperative fluoroscopy.

For fixation, a 3-cm skin incision was made on the lateral aspect of the thigh, just proximal to the greater trochanter. Subdermal soft tissues were incised and the awl was inserted at the tip of the greater trochanter. Then, we passed a guide pin through the entry point and inserted the nail after reaming of the proximal femur.



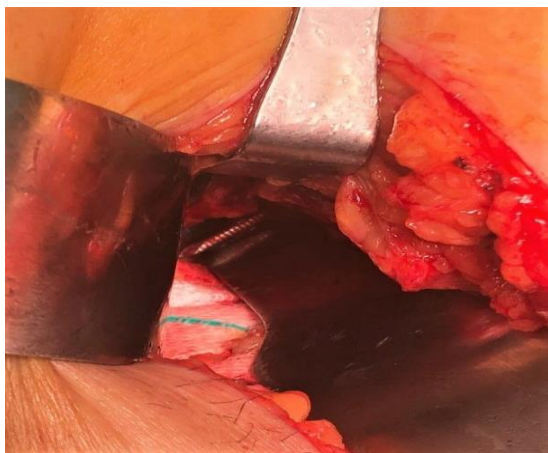
For placing the lag screw, a guide pin was inserted through the jig device to the center of the femoral head and neck, and was checked by fluoroscopy. After estimating the size of the lag screw based on the inserted guide pin, reaming was performed over the inserted guide pin and the lag screw was placed. When the guide pin was extracted, we noticed that it was broken.

The repeated intraoperative imaging showed that the broken fragment had penetrated the acetabulum (Figure 2). The guide pin was migrated into the acetabulum during forceful reaming and was broken when inserting the lag screw with improper direction, probably due to osteoporosis.



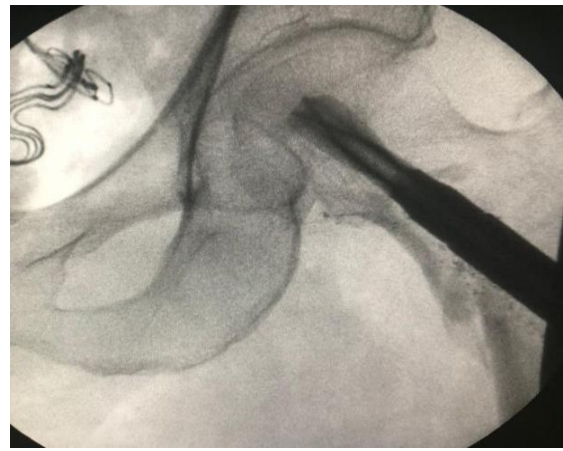**Figure 2.** Intraoperative imaging of the left hip, revealing intra-pelvic broken guide wire

The exact location of the broken guide pin was assessed with postoperative computed tomography (CT) scan. After consultation with a vascular surgeon, a CT angiography was performed, which showed no sign of vascular injuries. However, due to the high risk of pin moving and the possibility of neurovascular or urological injuries, the patient was transferred to the operating room the next day for removing the broken pin. The surgery team included an orthopedic surgeon, an urologist, and a vascular surgeon. The suprapubic region was opened with the modified Stoppa approach. Exploration of obturator neurovascular structures and corona mortis revealed no injury. Then, the broken pin was extracted from the inner table of the pelvis and the extraction was confirmed with intraoperative imaging (Figures 3 and 4).



**Figure 3.** Intra-pelvic penetration of the broken guide wire exposed by the modified Stoppa approach

Finally, according to the urologist's advice, 600 cc of normal saline was injected into the urine catheter to rule out iatrogenic bladder injury during the procedure.



**Figure 4.** Intraoperative imaging of the left hip after removing the broken guide wire

## Discussion

Breakage of guide pin during fixation of hip fracture is an uncommon yet catastrophic complication (2). One of the main causes of breakage is the reuse of wires which are prepared for single use. Multiple-time usage leads to the decrement of mechanical strength and makes it susceptible to bending or breakage (5, 6). The other possible cause is drilling or reaming with a divergent angle over the bent guide wire (7). Migration of the guide wire into the hip joint or pelvis could occur following forceful reaming or over-reaming (3). A stuck cannulated device or reamer might result from a bent guide wire or incarcerated debris in the canal of device which can lead to a forceful reaming and the guide wire breakage (6, 8).

In our case, the most probable cause of the guide wire breakage was reaming with a divergent angle. Consecutively, it resulted in bending of the wire, stuck of the reamer, forceful reaming, migration of the wire, and the final breakage. Therefore, several intraoperative control imaging during guide wire placing, reaming, and device insertion is recommended to confirm the proper position and direction of all tools. Furthermore, it is recommended to check the wires before application to avoid reuse and ensure the absence of bent or erosion. Cannulated devices should also be inspected for canal blockage. Using a blunt drill bit or reamer may result in a forceful reaming and should be avoided.

The remaining of the broken fragment increases the risk of further migration and subsequent neurovascular or urological injuries. Moreover, it might cause additional chondral damage to the hip joint. Therefore, it is better to remove the broken fragment as soon as possible. Sayegh et al. reported a case of intra-pelvic broken guide wire which was approached by open laparotomy (2). Venkata et al. used a laparoscopic assisted technique for removing intra-pelvic broken guide wire (9). They stated that laparoscopy is preferred over laparotomy due to lower morbidity. Mishra et al. removed the broken guide wire through the extended Watson-Jones approach and by making a rectangular bony window on the anterior aspect of the femoral neck (10). In another study, they reported a case of protruded broken wire during fixation of a femoral neck

fracture (3). The fragment was extracted via extra-peritoneal ilioinguinal approach. On the contrary, some authors believe that exploring the broken fragment by the ilioinguinal approach enhances the risk of iatrogenic neurovascular injuries (10). Sen et al. reported four cases of broken guide wires during fixation of hip fractures (11). They used the ilioinguinal approach in 2 cases, in which the broken wire protruded into the pelvic fossa (11).

In another case with a stuck broken fragment in the hip joint, they benefited from the Smith-Peterson approach plus arthrotomy. In the last case, the broken wire penetrated the anterior cortex of the femoral neck and was removed by the extended Watson-Jones approach. Ilizaliturri et al. used an arthroscopic assisted technique for removing the intra-articular broken fragment of the guide wire (7). Sharma et al. extracted the broken fragment of the guide wire by a cannulated reamer (5). They placed the reamer over the broken wire under intra-operative imaging and removed the fragment by reverse reaming (5).

In our case, the exact location of the broken guide wire was assessed by CT scan and the broken fragment was removed via the modified Stoppa approach. This surgical approach provided proper access to the inner table of the pelvis with a lower risk of iatrogenic neurovascular injuries compared to the ilioinguinal approach. We believe that the modified Stoppa approach could be a safe and helpful alternative to the ilioinguinal approach for removing intra-pelvic broken guide wire that is not accessible with minimally invasive methods.

### Conclusion

Although the breakage of the guide wire during fixation of hip fracture is an uncommon complication, migration of the broken fragment might be catastrophic. Removing broken fragment of guide wire is necessary to stop migration of the fragment. It is important to prevent further surgical related complication like neurovascular damage during broken fragment removal. Modified Stoppa approach provided proper access to the inner table of the pelvis with a lower risk of iatrogenic neurovascular injuries compared with the ilioinguinal approach. It seems using modified Stoppa approach could be safe and helpful for removing intra-pelvic broken guide wire that is not accessible with minimally invasive methods.

### Conflict of Interest

The authors declare no conflict of interest in this study.

### Acknowledgments

This study was supported by Shahid Beheshti

University of Medical Sciences, Tehran, Iran.

### References

- Xu X, Han J, Li Y, Sun X, Lin P, Chen Y, et al. Effects of orem's self-care model on the life quality of elderly patients with hip fractures. *Pain Res Manag.* 2020;2020:5602683. doi: [10.1155/2020/5602683](https://doi.org/10.1155/2020/5602683). [PubMed: [32566061](https://pubmed.ncbi.nlm.nih.gov/32566061/)]. [PubMed Central: [PMC7256682](https://pubmed.ncbi.nlm.nih.gov/PMC7256682/)].
- Sayegh FE, Tsintzas D, Kapetanios GA. Intrapelvic migration of a guide pin during fixation of a hip fracture: Who and what is to blame? *Acta Orthop Belg.* 2005;71(2):239-41. [PubMed: [16152863](https://pubmed.ncbi.nlm.nih.gov/16152863/)].
- Saini UC, Gopinathan NR, Aggarwal S, Sen R. Intrapelvic protrusion of a broken guide wire fragment during fixation of a femoral neck fracture. *Arch Bone Jt Surg.* 2018;6(2):155-6. [PubMed: [29600270](https://pubmed.ncbi.nlm.nih.gov/29600270/)]. [PubMed Central: [PMC5867361](https://pubmed.ncbi.nlm.nih.gov/PMC5867361/)].
- Dorr LD, Faugere MC, Mackel AM, Gruen TA, Bognar B, Malluche HH. Structural and cellular assessment of bone quality of proximal femur. *Bone.* 1993;14(3):231-42. doi: [10.1016/8756-3282\(93\)90146-2](https://doi.org/10.1016/8756-3282(93)90146-2). [PubMed: [8363862](https://pubmed.ncbi.nlm.nih.gov/8363862/)].
- Sharma H, Chauhan M, Maini L. A technique to remove a broken guide wire transfixing the hip joint. *Acta Orthop Belg.* 2008;74(5):683-5. [PubMed: [19058705](https://pubmed.ncbi.nlm.nih.gov/19058705/)].
- Mishra P, Jain P, Aggarwal A, Upadhyay A, Maini L, Gautam VK. Intrapelvic protrusion of guide wire during fixation of fracture neck of femur. *Injury.* 2002;33(9):839-41. doi: [10.1016/S0020-1383\(02\)00172-9](https://doi.org/10.1016/S0020-1383(02)00172-9). [PubMed: [12379397](https://pubmed.ncbi.nlm.nih.gov/12379397/)].
- Ilizaliturri VM Jr, Zarate-Kalfopulos B, Martinez-Escalante FA, Cuevas-Olivo R, Camacho-Galindo J. Arthroscopic retrieval of a broken guidewire fragment from the hip joint after annulated screw fixation of slipped capital femoral epiphysis. *Arthroscopy.* 2007;23(2):227.e1-4. doi: [10.1016/j.arthro.2005.08.048](https://doi.org/10.1016/j.arthro.2005.08.048). [PubMed: [17276233](https://pubmed.ncbi.nlm.nih.gov/17276233/)].
- Mueller M, Jahnich H, Butler-Manuel A. Inadvertent guide wire advancement in hip fracture fixation with fatal outcome. *Injury.* 2005;36(5):679-80. doi: [10.1016/j.injury.2004.06.024](https://doi.org/10.1016/j.injury.2004.06.024). [PubMed: [15826632](https://pubmed.ncbi.nlm.nih.gov/15826632/)].
- Venkata GR, Mootha AK, Thayi C, Parekh VG, Ramireddy VK. Concomitant laparoscopy: An effective technique for successful retrieval of intra pelvic migrated broken guide pin. *Injury.* 2012;43(4):526-9. doi: [10.1016/j.injury.2011.11.010](https://doi.org/10.1016/j.injury.2011.11.010). [PubMed: [22209170](https://pubmed.ncbi.nlm.nih.gov/22209170/)].
- Mishra P, Gautam VK. Broken guide wire with intrapelvic protrusion: A technique for removal. *Injury.* 2004;35(12):1324-6. doi: [10.1016/j.injury.2003.10.010](https://doi.org/10.1016/j.injury.2003.10.010). [PubMed: [15561130](https://pubmed.ncbi.nlm.nih.gov/15561130/)].
- Sen RK, Tripathy SK, Aggarwal S, Agarwal A, Goyal T, Tahasildar N, et al. Broken Kirschner or guide-wire retrieval: A report of 4 cases. *Hip Int.* 2010;20(4):551-4. doi: [10.1177/112070001002000422](https://doi.org/10.1177/112070001002000422). [PubMed: [21157764](https://pubmed.ncbi.nlm.nih.gov/21157764/)].