

Black Femoral Head due to Ochronotic Arthropathy: A Case Report

Mahlisa Kazemi¹, Hamid Rabie², Mohammadhasan Sharafi^{1,2,*}

¹ Assistant Professor, Department of Orthopedic and Trauma Surgery, Shariati Hospital, School of Medicine, Tehran University of Medical Sciences, Tehran, Iran

² Resident, Department of Orthopedic and Trauma Surgery, Shariati Hospital, School of Medicine, Tehran University of Medical Sciences, Tehran, Iran

*Corresponding author: Mohammadhasan Sharafi; Department of Orthopedic and Trauma Surgery, Shariati Hospital, School of Medicine, Tehran University of Medical Sciences, Tehran, Iran. Tel: +98-9123214827, Email: sharafi.mohamadhasan@gmail.com

Received: 17 March 2020; Revised: 20 June 2020; Accepted: 19 August 2020

Abstract

Background: Ochronotic arthropathy is a rare complication in patients with alkaptonuria (AKU) that occurs as a result of ochronotic pigment accumulation in the joints.

Case Report: This case report presents a 54-year-old patient with severe degenerative arthritis who underwent total hip arthroplasty on both sides within an interval of three years. The diagnosis was made by observation of a dark capsule and femoral head during the second surgery. The surgical treatments significantly reduced the pain and improved the range of motion (ROM).

Conclusion: Orthopedic surgeons must be vigilant about clinical manifestations of this rare condition, before and during the surgery. Arthroplasty is a favourable therapeutic option in patients suffering from ochronotic arthropathy.

Keywords: Arthroplasty; Alkaptonuria; Ochronosis

Citation: Kazemi M, Rabie H, Sharafi M. **Black Femoral Head due to Ochronotic Arthropathy: A Case Report.** *J Orthop Spine Trauma* 2020; 6(4): 108-10.



Background

Alkaptonuria (AKU) is an uncommon hereditary disease of the phenylalanine and tyrosine metabolism, affecting one in 100,000 to 250,000 people worldwide (1). It is caused by the diminished function of the homogentisate 1,2-dioxygenase enzyme (HGD) and subsequent accumulation of the enzyme's substrate, homogentisic acid (HGA), in blood and body tissues (2, 3). Autoxidation and polymerization of the HGA in collagenous tissues produce ochronotic pigment which can deposit in various tissues such as skin, cardiovascular system, kidney, joints, ligaments, and tendons (4, 5).

Orthopedic manifestation of this condition includes early-onset involvement of the lumbar spine with stiffness and pain, thickening and rupture of the tendons, muscle tearing after low-energy trauma, and ochronotic arthropathy in knee, hip, and shoulder joints. The ochronotic deposits make the cartilage fragile and rigid, leading to degenerative changes in the axial and peripheral skeleton, usually between age 40 to 50 years (6).

Based on the severity of degeneration, surgical treatment may include synovectomy, arthroscopic debridement, or arthroplasty. Although the ochronotic arthropathy is a rare and late sequel in AKU, it can be rapid and aggressive. In many cases, the disease is not diagnosed until the time of arthroplasty (7). In this report, we present a patient with ochronotic arthropathy who underwent bilateral total hip arthroplasty.

Case Report

A healthy 54-year-old woman referred to our hip surgery clinic with mechanical pain in the left hip in the last two years. There was no history of trauma or evidence of inflammatory arthritis (e.g. pain at night or during rest). The familial history of metabolic disorders was

negative, and she had her right hip replaced three years ago in elsewhere hospital via posterior approach. In clinical examination, a decreased hip range of motion (ROM) and painful movement were detected. Other examinations were unremarkable. The right hip that was previously replaced had no pain and the ROM was normal.

Radiographic study of the hip was in favour of degenerative arthritis with joint space narrowing, subchondral sclerosis and cyst formation. Other findings were osteophyte formation and degenerative changes in the lumbar spine and bilateral sacroiliac joints (Figure 1). Primarily, she was treated with conservative management using analgesics and physical rehabilitation. A total hip arthroplasty by posterior approach was performed when she had progressive pain and limited ROM.

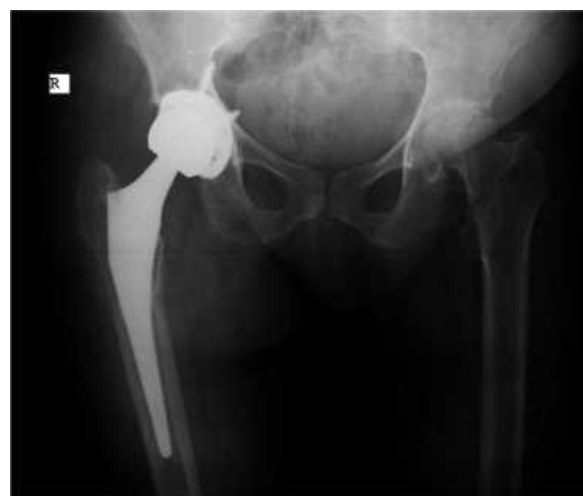

Figure 1. Pelvic X-ray [Anteroposterior (AP) view] after the first surgery showing degenerative changes in the left hip



After three years, the patient returned with mechanical pain in the other hip for several months. The right hip that was previously replaced had no pain and the ROM was normal. In the clinical examination of the left hip, we found limited ROM and pain, especially in rotational movements. Radiographical evidence of severe degenerative arthritis was present in the left hip. During the surgery through a direct anterior approach, we noticed that the hip capsule was thick, contracted, and black with severe pericapsular adhesions. After capsulotomy, in the absence of infection and abnormal preoperative evaluations including erythrocyte sedimentation rate (ESR) and C-reactive protein (CRP), we decided to proceed with arthroplasty. Due to the severe adhesions and contracture, we had to perform an extensive soft tissue release to have the desired exposure.

A double osteotomy was performed in the femoral neck and the black femoral head was removed. By the same anterior approach, femoral and acetabular bone components were inserted without any complications (Figure 2).

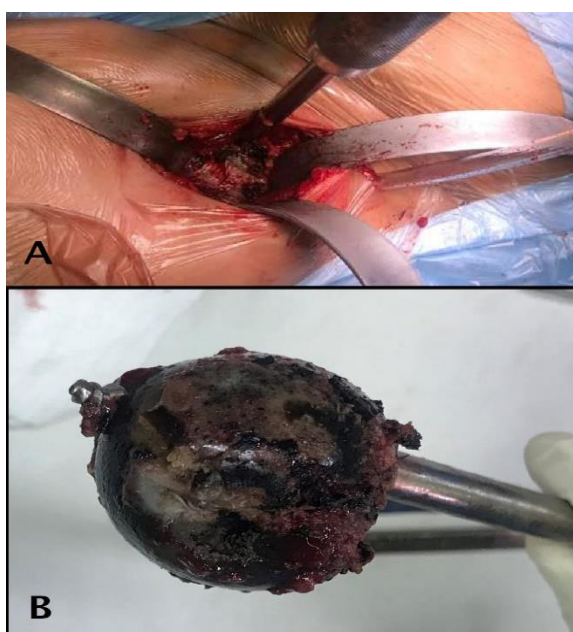


Figure 2. Intraoperative findings. A) Black capsule was seen after exposure; B) Removed black femoral head

In the histological study with Hematoxylin and Eosin (H&E), the cartilage and bone trabeculae showed extensive deposition of dark brown pigments. Many scattered foci of necrotic bone trabeculae and multinuclear giant cell formations were seen in the marrow spaces, without any evidence of malignancy (Figure 3).

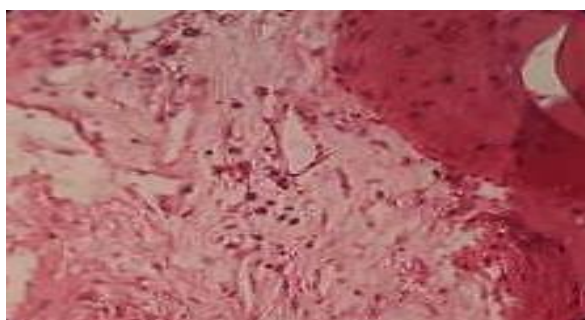


Figure 3. Histological findings in Hematoxylin and Eosin (H&E) staining

After the surgery, the patient was examined carefully for other signs of the disease. At this time, multiple pigmentations were found in the axillary region (Figure 4). We retrospectively reviewed the documentation of the first surgery and found no relevant findings even in the pathology report.

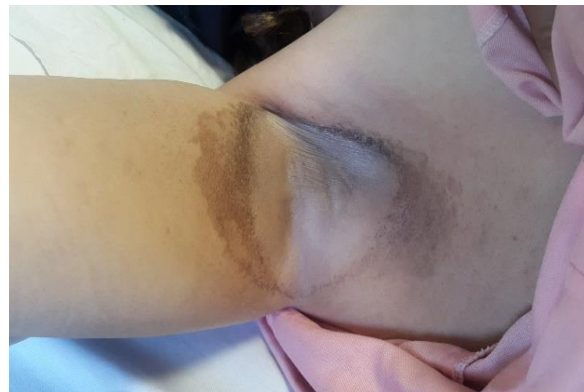

Figure 4. Pigmentation of the axillary region

Her pain was significantly decreased after the surgery. In the latest follow-up, 20 months after the second surgery, the ROM was acceptable in both hips without any pain or discomfort. The radiologic studies showed no further pathological findings in femoral or acetabular components (Figure 5).

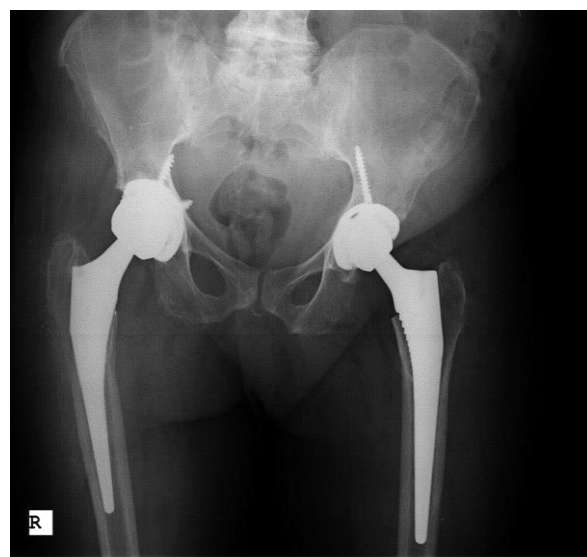

Figure 5. Follow-up pelvic X-ray [Anteroposterior (AP) view]

Discussion

Ochronotic arthropathy is a late complication of AKU that leads to cartilage damage and degenerative changes. It is asymptomatic in most cases until the fourth decade of life, and usually, the disease is diagnosed by intraoperative findings (8). Degenerative joint diseases are usually managed conservatively in the early stages, and surgically in severe cases (9). Our patient was managed with bilateral total hip arthroplasty due to the mechanical pain and degenerative changes in both hips.

Ochronosis can lead to cardiovascular and renal diseases, putting the patients with AKU at higher risk of

general anesthesia and surgery complications. Furthermore, in our experience this condition can be confused with infection intra-operatively. Thus, it is important to diagnose this condition before the surgery and conduct the appropriate preoperative evaluations to avoid complications. In general examination, surgeons must be vigilant about clinical clues such as pigmentations in eyes and skin folds, which were present in our case, and urine color (turns black when exposed to air) (10, 11).

During the surgery, we observed soft tissue and capsular contracture in our patient which was in line with other reports (12). It seems that this finding can be an important intraoperative clue to guide the surgeon. Additionally, extra caution should be taken while providing care for these patients, since this condition may cause osteoporosis and the patients may be vulnerable to intraoperative or postoperative fractures (13).

We managed our patient successfully with total hip arthroplasty due to the severity of the degenerative changes. In accordance with our results, Pachore et al. reported an excellent outcome for total hip arthroplasty in a patient with severe degenerative joint disorder secondary to ochronosis. They also mentioned that joint replacement in ochronotic arthritis was associated with prosthetic survival comparable to the patients with primary osteoarthritis (14).

Similarly, Couto et al. demonstrated that arthroplasty is a safe and effective option to treat ochronotic arthritis. They highlighted the fact that orthopedic surgeons should expect an atypical arthropathy when they see darkened cartilage during surgery (15). Another case report by Acar et al. showed that total hip and knee replacement can greatly improve the physical activity of the patient (16). Although this rare condition has been discussed in a few case reports, the long-term outcomes of joint arthroplasty in ochronotic arthritis should be evaluated in further studies.

Conclusion

Ochronotic arthropathy is a very rare disorder that can be potentially misdiagnosed with osteoarthritis in patients with joint pain and radiographic joint space narrowing. We believe that total hip arthroplasty is a good option in patients with severe degenerative changes due to ochronotic arthritis.

Conflict of Interest

The authors declare no conflict of interest in this study.

Acknowledgments

None.

References

- Jiang L, Cao L, Fang J, Yu X, Dai X, Miao X. Ochronotic arthritis and ochronotic Achilles tendon rupture in alkaptonuria: A 6 years follow-up case report in China. *Medicine (Baltimore)*. 2019;98(34):e16837. doi: [10.1097/MD.00000000000016837](https://doi.org/10.1097/MD.00000000000016837). [PubMed: [31441856](https://pubmed.ncbi.nlm.nih.gov/31441856/)]. [PubMed Central: [PMC6716692](https://pubmed.ncbi.nlm.nih.gov/PMC6716692/)].
- Schiavone ML, Pecorelli A, Woodby B, Ferrara F, Pambianchi E, Santucci A, et al. Mechanisms involved in the unbalanced redox homeostasis in osteoblastic cellular model of Alkaptonuria. *Arch Biochem Biophys*. 2020;690:108416. doi: [10.1016/j.abb.2020.108416](https://doi.org/10.1016/j.abb.2020.108416). [PubMed: [32502471](https://pubmed.ncbi.nlm.nih.gov/32502471/)].
- Helliwell TR, Gallagher JA, Ranganath L. Alkaptonuria-a review of surgical and autopsy pathology. *Histopathology*. 2008;53(5):503-12. doi: [10.1111/j.1365-2559.2008.03000.x](https://doi.org/10.1111/j.1365-2559.2008.03000.x). [PubMed: [18336562](https://pubmed.ncbi.nlm.nih.gov/18336562/)].
- Martin JP Jr, Batkoff B. Homogentisic acid autoxidation and oxygen radical generation: Implications for the etiology of alkaptonuric arthritis. *Free Radic Biol Med*. 1987;3(4):241-50. doi: [10.1016/s0891-5849\(87\)80031-x](https://doi.org/10.1016/s0891-5849(87)80031-x). [PubMed: [3121448](https://pubmed.ncbi.nlm.nih.gov/3121448/)].
- Taylor AM, Boyde A, Wilson PJ, Jarvis JC, Davidson JS, Hunt JA, et al. The role of calcified cartilage and subchondral bone in the initiation and progression of ochronotic arthropathy in alkaptonuria. *Arthritis Rheum*. 2011;63(12):3887-96. doi: [10.1002/art.30606](https://doi.org/10.1002/art.30606). [PubMed: [22127706](https://pubmed.ncbi.nlm.nih.gov/22127706/)].
- Gil JA, Wawrzynski J, Waryasz GR. Orthopedic manifestations of ochronosis: Pathophysiology, presentation, diagnosis, and management. *Am J Med*. 2016;129(5):536. doi: [10.1016/j.amjmed.2016.01.010](https://doi.org/10.1016/j.amjmed.2016.01.010). [PubMed: [26844634](https://pubmed.ncbi.nlm.nih.gov/26844634/)].
- Harun M, Hayrettin Y, Serhat M, Cuneyt M, Firat F, Ufuk O. A rare cause of arthropathy: An ochronotic patient with black joints. *Int J Surg Case Rep*. 2014;5(8):554-7. doi: [10.1016/j.ijscr.2014.06.015](https://doi.org/10.1016/j.ijscr.2014.06.015). [PubMed: [25034257](https://pubmed.ncbi.nlm.nih.gov/25034257/)]. [PubMed Central: [PMC4147659](https://pubmed.ncbi.nlm.nih.gov/PMC4147659/)].
- Patel VG. Total knee arthroplasty in ochronosis. *Arthroplast Today*. 2015;1(3):77-80. doi: [10.1016/j.artd.2015.03.003](https://doi.org/10.1016/j.artd.2015.03.003). [PubMed: [28326376](https://pubmed.ncbi.nlm.nih.gov/28326376/)]. [PubMed Central: [PMC4956685](https://pubmed.ncbi.nlm.nih.gov/PMC4956685/)].
- Rathore FA, Ayaz SB, Mansoor SN. Ochronotic arthropathy: Two case reports from a developing country. *Clin Med Insights Arthritis Musculoskelet Disord*. 2016;9:15-20. doi: [10.4137/CMAMD.S31560](https://doi.org/10.4137/CMAMD.S31560). [PubMed: [26884684](https://pubmed.ncbi.nlm.nih.gov/26884684/)]. [PubMed Central: [PMC4749042](https://pubmed.ncbi.nlm.nih.gov/PMC4749042/)].
- Siavashi B, Zehtab MJ, Pendar E. Ochronosis of hip joint; A case report. *Cases J*. 2009;2:9337. doi: [10.1186/1757-1626-2-9337](https://doi.org/10.1186/1757-1626-2-9337). [PubMed: [20062596](https://pubmed.ncbi.nlm.nih.gov/20062596/)]. [PubMed Central: [PMC2803996](https://pubmed.ncbi.nlm.nih.gov/PMC2803996/)].
- Dom K, Pittevels T. Ochronotic arthropathy: the black hip. Case report and review of the literature. *Acta Orthop Belg*. 1997;63(2):122-5. [PubMed: [9265798](https://pubmed.ncbi.nlm.nih.gov/9265798/)].
- Cebesoy O, Isik M, Subasi M, Kaya A, Bilgin F, Kaya O. Total hip replacement for an ochronotic patient: A technical trick. *Am J Case Rep*. 2014;15:27-30. doi: [10.12659/AJCR.890008](https://doi.org/10.12659/AJCR.890008). [PubMed: [24459540](https://pubmed.ncbi.nlm.nih.gov/24459540/)]. [PubMed Central: [PMC3899173](https://pubmed.ncbi.nlm.nih.gov/PMC3899173/)].
- Aliberti G, Pulignano I, Pisani D, Rocchietti MM, Del PF, Proietta M. Bisphosphonate treatment in ochronotic osteoporotic patients. *Clin Rheumatol*. 2007;26(5):729-35. doi: [10.1007/s10067-006-0390-3](https://doi.org/10.1007/s10067-006-0390-3). [PubMed: [16924393](https://pubmed.ncbi.nlm.nih.gov/16924393/)].
- Pachore JA, Shah VI, Upadhyay S, Shah K, Sheth A, Kshatriya A. Primary hip arthroplasty for the treatment of alkaptonuric hip arthritis: 3-to 24-year follow-ups. *Arthroplasty*. 2019;1(1):1-9. doi: [10.1186/s42836-019-0010-8](https://doi.org/10.1186/s42836-019-0010-8).
- Couto A, Sa Rodrigues A, Oliveira P, Seara M. Ochronotic arthropathy-a rare clinical case. *Oxf Med Case Reports*. 2018;2018(9):omy069. doi: [10.1093/omcr/omy069](https://doi.org/10.1093/omcr/omy069). [PubMed: [30174828](https://pubmed.ncbi.nlm.nih.gov/30174828/)]. [PubMed Central: [PMC6112307](https://pubmed.ncbi.nlm.nih.gov/PMC6112307/)].
- Acar MA, Erkocak OF, Aydin BK, Altan E, Senaran H, Elmadag NM. Patients with black hip and black knee due to ochronotic arthropathy: Case report and review of literature. *Oman Med J*. 2013;28(6):448-9. doi: [10.5001/omj.2013.124](https://doi.org/10.5001/omj.2013.124). [PubMed: [24223251](https://pubmed.ncbi.nlm.nih.gov/24223251/)]. [PubMed Central: [PMC3815858](https://pubmed.ncbi.nlm.nih.gov/PMC3815858/)].