

Acetabular Posterior Wall Fracture: How to Determine the Fragment Size

Seyed Mohammad Javad Mortazavi¹, Mohammad Zarei², Seyed Hadi Kalantar², Sheila Rasta^{3,*}

¹ Professor, Department of Orthopedic Surgery, Joint Reconstruction Research Center, Tehran University of Medical Sciences, Tehran, Iran

² Assistant Professor, Department of Orthopedic Surgery, Joint Reconstruction Research Center, Tehran University of Medical Sciences, Tehran, Iran

³ Resident, Department of Orthopedic Surgery, Joint Reconstruction Research Center, Tehran University of Medical Sciences, Tehran, Iran

*Corresponding author: Sheila Rasta; Department of Orthopedic Surgery, Joint Reconstruction Research Center, Tehran University of Medical Sciences, Tehran, Iran. Tel: +98-9123853785, Email: sheilarasta@gmail.com

Received: 27 March 2020; Revised: 01 June 2020; Accepted: 04 September 2020

Keywords: Acetabulum; Bone Fractures; Surgery

Citation: Mortazavi SMJ, Zarei M, Kalantar SH, Rasta S. **Acetabular Posterior Wall Fracture: How to Determine the Fragment Size.** *J Orthop Spine Trauma* 2020; 6(4): 88-90.



Background

Acetabular fractures usually occur as a result of high-energy trauma in men (1). Fracture of the posterior wall is one of the most common acetabular fractures, accounting for 23.6% of all acetabular fractures (2). The incidence of posterior wall fracture in posterior hip dislocation could be as high as 67.0% (3). The open reduction and internal fixation have been used as a successful treatment for posterior wall fractures (4). The main prognostic factors associated with the poor outcome are delayed reduction more than 12 hours, age more than 55 years, osteonecrosis, and intra-articular comminution (1).

Imaging

Posterior acetabular fractures are usually underestimated in radiographic evaluation. Despite simple fracture appearance, they are often comminuted and involve articular surface which is impacted into the underlying cancellous bone (1). Although it is possible to see the fracture line in anteroposterior (AP) radiographs, the best radiographic view to reveal this fracture is the obturator view. The obturator oblique view can show the size and multifragmentary nature of the fracture. Based on the ability of computed tomography (CT) scan to reveal comminution and marginal impaction, previous studies have suggested that a CT scan is sufficient for classification of the acetabular fractures and plain radiography can be omitted to decrease exposure and cost (5). Posterior wall fractures can be isolated or in combination with posterior column or transverse fractures. In isolated fractures (Figure 1), the iliopectineal and ilioischial lines are often

intact, while a fracture line can be found in the posterior wall in the obturator oblique view (6).

Operative or Non-Operative Treatment

The decision on operative or non-operative management of posterior wall acetabular fracture depends on stability and congruency of the hip joint (7). However, it is not always easy to determine hip stability, especially if the patient has isolated posterior wall fracture without a dislocation (7). Traditionally, the size of the posterior fragment is considered an important factor to predict stability, and large fragments are usually associated with instability (8). However, there is no consensus on the method of measuring the fragment. Moreover, it has been demonstrated that the fragment size alone cannot predict hip stability (9).

In many cases, the fragment's size is between small and large, which is labeled as indeterminate. In addition, even a patient with small fragment may have an unstable hip.

The most reliable method for stability prediction is the hip examination under anesthesia. For this purpose, the patient is placed at the supine position with neutral rotation and full extension of the hip. Then, the hip is flexed to 90 degrees and adducted to 20 degrees. If the joint remains congruent in the AP and oblique fluoroscopic view, it is considered stable (10). Firoozabadi et al. examined 185 patients under anesthesia and measured cranial exit point of fracture from the dome in the radiographs. They concluded that the cranial exit point can be an indicator of instability even if the fragment is small. Therefore, they recommended using dynamic stress fluoroscopic hip examination for all patients with small and indeterminate posterior wall fragment (9).

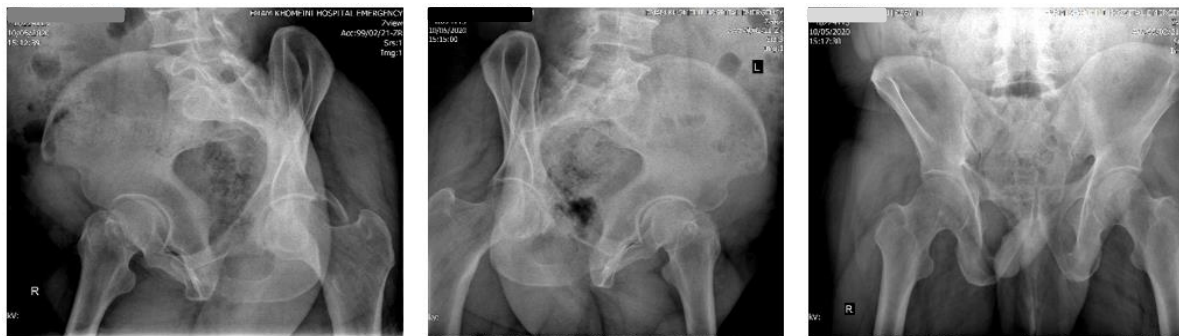

Figure 1. An isolated fracture with intact iliopectineal and ilioischial lines, and fracture line in the posterior wall in obturator oblique view



Here, we review different techniques for measuring the posterior wall fragment size which is the first step to determine hip stability in posterior wall acetabular fracture.

Measuring Methods of Fragment Size in Posterior Wall Fractures

Method of Calkins et al. (11): In a study, Calkins et al. measured acetabular fracture index in 2 sections of patient's CT-scan

- 1) Section with the smallest intact fragment in the fractured side
- 2) Section that was matched to other side according to the femoral head and configuration of fovea and acetabular fossa.

They calculated the acetabular fracture index (AFI) with measuring the length of arc of the intact posterior wall fragment in fractured side and to whole posterior wall in contralateral side (Figure 2) (11).

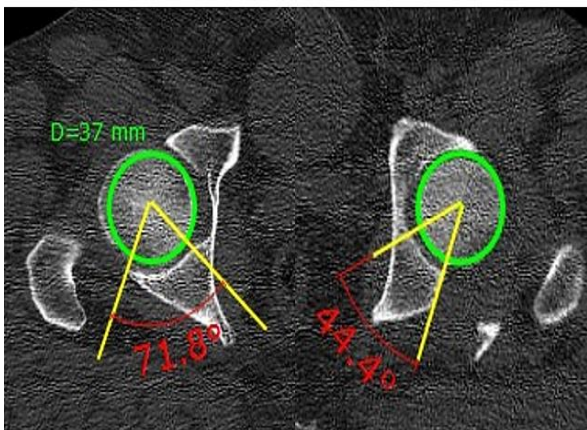
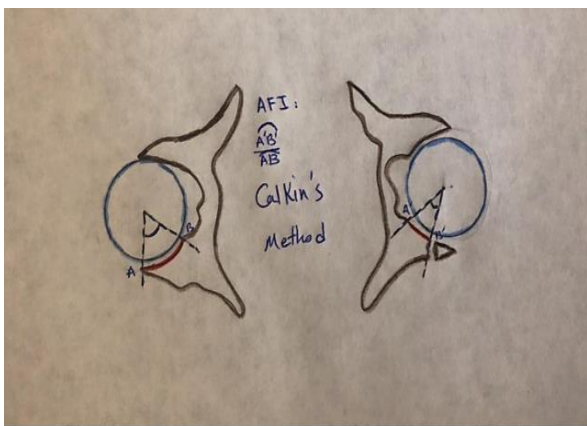


Figure 2. Measuring acetabular fracture index (AFI) in Calkins et al. method (11)

To make it easier, they suggested the straight-line measurement of the posterior acetabulum. They measured the remaining intact articular posterior wall acetabular segment at the level of greatest amount of fracture involvement by a straight line from medial to lateral (Figure 3).

Then the length of the posterior acetabular arc was measured from the uninjured contralateral hip on the same level. In this method, the index percentage is calculated by dividing the first measurement by the second, multiplied by 100. They found a significant association between fracture stability and AFI, with no stable posterior wall fractures in AFI > 55% (11).

Method of Keith et al. (12): In their cadaver study, Keith et al. introduced another way for measuring fracture fragment size. They chose a section at the level of the femoral head fovea capitis in the fractured side and a matched 2-dimensional CT scan section from the contralateral side.

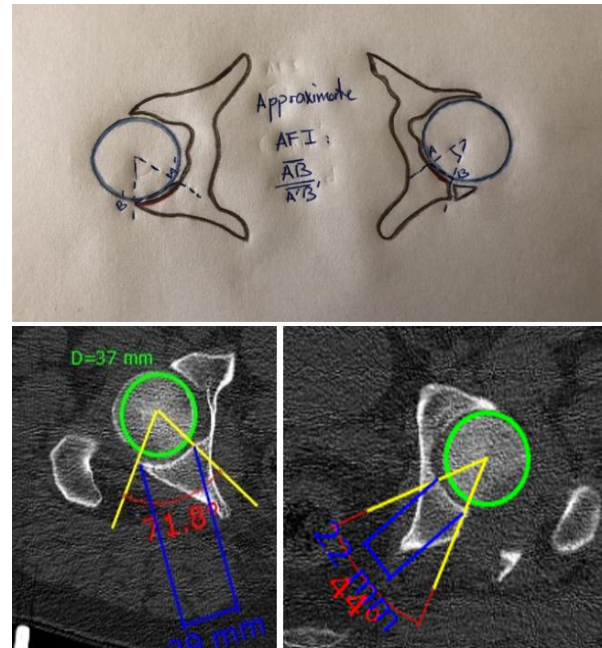


Figure 3. Measuring approximate acetabular fracture index (AFI) in Calkins et al. method (11)

Then, they calculated the ratio of the measured fragment size to the measured acetabular depth in the contralateral intact side. In this method, a stable fracture was defined as involvement of less than 20% of the posterior wall, and unstable, when involving more than 40% (Figure 4) (12).

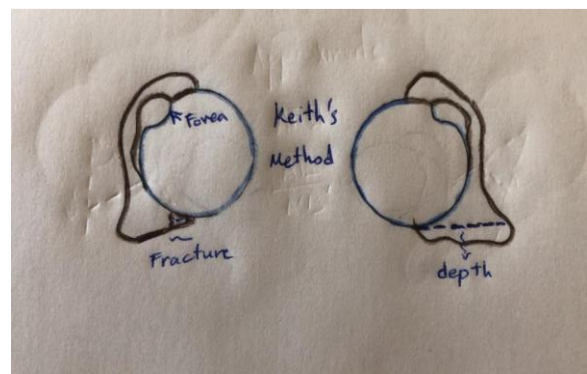


Figure 4. Measuring fracture fragment size in Keith et al. method (12)

Method of Moed et al. (13): In an investigation, Moed et al. proposed a modified version of the method described by Keith et al. (12). They selected a section of CT scan from the side of the fracture which was at the level of the largest posterior wall deficit. Then, they measured the fracture fragment size by the Keith et al.'s method. A fracture fragment greater than 50% was considered unstable and less than 20% stable. This method may decrease the rate of false stable acetabular fractures (13).

Discussion

In a study, Moed tried to find a reason for unsatisfactory outcomes in 30% of patients who underwent surgery. Using the methods described here for measuring fracture fragment size, he found an increase in the number of indeterminate fractures. Because of the high rate of treatment failure, they postulated that there should be another reason for hip stability perdition in addition to the fragment size, such as hip joint capsule injuries (14).

In another study, Reagan and Moed attempted to evaluate the reliability of their fragment size measurement technique. The average time for assessment of the fragment percentage was 5 minutes. The intra-observer and inter-observer reliability were greater than 0.80. The sensitivity and specificity were 90% and 61%, respectively. Compared to examination under anesthesia (EUA), a wrong choice was picked for 6% in nonoperative treatments and 16% in surgical interventions (15).

Firoozabadi et al. (9) demonstrated that the method by Calkins et al. (11) cannot predict the stability of the acetabulum, probably due to difficulty in finding the exact contralateral section matched with the fracture side. By reducing the threshold of stability detection to less than 15%, the precision increased in both methods by Moed et al. (13) and Keith et al. (12). This article emphasized the cranial exit point of the posterior wall fracture within 5 mm of the dome as a major criterion for stability. No uniform method was used by Firoozabadi et al. (9) and Moed et al. for calculation of the fragment percentage (13).

In a study, Goodman et al. assessed the inter- and intra-observer reliability of these methods and published their poster (10). Intraclass correlation coefficients (ICCs) among five raters were 0.71 for Calkins et al. method (11), 0.73 for Keith et al. method (12), and 0.70 for Moed et al. method (13). All techniques showed strong reliability for junior and senior residents: mean absolute error was 12.3% and 12.0% for Calkins et al. method (11), 8.4% and 7.3% for Keith et al. method (12), and 12.0% and 11.5% for Moed et al. method (13). These values were so close to the attending's results. There was no significant difference in accuracy by increasing the level of training. The inter-rater reliability was 0.82 for Calkins et al. method (11), 0.90 for Keith et al. method (12), and 0.86 for Moed et al. method (13).

Mitsionis et al. used a posterior wall involvement more than 50% after reduction as an indication for surgery. They believed that anatomical reduction is the most important factor for an excellent outcome (16). Therefore, checking these factors after reduction can help to choose best candidates for surgery.

We discussed different methods for measuring fracture fragment size in the posterior wall fractures. Predicting the stability of fracture with these methods is still under question and there are other factors that can possibly affect this prediction. Further studies are required to check the reliability of current methods and introduce new techniques that consider more factors

Conflict of Interest

The authors declare no conflict of interest in this study.

Acknowledgments

None.

References

1. Moed BR, WillsonCarr SE, Watson JT. Results of operative

treatment of fractures of the posterior wall of the acetabulum. *J Bone Joint Surg Am.* 2002;84(5):752-8. doi: [10.2106/00004623-200205000-00008](https://doi.org/10.2106/00004623-200205000-00008). [PubMed: [12004016](https://pubmed.ncbi.nlm.nih.gov/12004016/)].

2. Letournel E, Judet R. *Fractures of the acetabulum.* Berlin, Germany: Springer Science & Business Media; 2013.
3. Kumar M, Ahmed M, Hussain G, Saleem M, Sahar K, Bux M. Frequency of posterior wall acetabular fracture in patients presenting with posterior hip dislocations. *Rawal Medical Journal.* 2020;45(2):347-9.
4. Islam MN, Rahman MM, Islam MS, Kabir SJ, Alamgir MK, Kashem MT, et al. Outcome of open reduction and internal fixation of posterior wall fracture of acetabulum. *Mymensingh Med J.* 2020;29(3):502-8. [PubMed: [32844786](https://pubmed.ncbi.nlm.nih.gov/32844786/)].
5. Tazeabadi SA, Noroozi SG, Salehzadeh M, Bahardoust M, Farahini H, Hajjalizade M, et al. Evaluation of Judet view radiographs accuracy in classification of acetabular fractures compared with three-dimensional computerized tomographic scan: A retrospective study. *BMC Musculoskeletal Disord.* 2020;21(1):405. doi: [10.1186/s12891-020-03441-9](https://doi.org/10.1186/s12891-020-03441-9). [PubMed: [32590966](https://pubmed.ncbi.nlm.nih.gov/32590966/)]. [PubMed Central: [PMC7320535](https://pubmed.ncbi.nlm.nih.gov/PMC7320535/)].
6. Ly TV, Stover MD, Sims SH, Reilly MC. The use of an algorithm for classifying acetabular fractures: A role for resident education? *Clin Orthop Relat Res.* 2011;469(8):2371-6. doi: [10.1007/s11999-011-1925-8](https://doi.org/10.1007/s11999-011-1925-8). [PubMed: [21643925](https://pubmed.ncbi.nlm.nih.gov/21643925/)]. [PubMed Central: [PMC3126941](https://pubmed.ncbi.nlm.nih.gov/PMC3126941/)].
7. Grimshaw CS, Moed BR. Outcomes of posterior wall fractures of the acetabulum treated nonoperatively after diagnostic screening with dynamic stress examination under anesthesia. *J Bone Joint Surg Am.* 2010;92(17):2792-800. doi: [10.2106/JBJS.00112](https://doi.org/10.2106/JBJS.00112). [PubMed: [21123609](https://pubmed.ncbi.nlm.nih.gov/21123609/)].
8. Olson SA, Bay BK, Pollak AN, Sharkey NA, Lee T. The effect of variable size posterior wall acetabular fractures on contact characteristics of the hip joint. *J Orthop Trauma.* 1996;10(6):395-402. doi: [10.1097/00005131-199608000-00006](https://doi.org/10.1097/00005131-199608000-00006). [PubMed: [8854317](https://pubmed.ncbi.nlm.nih.gov/8854317/)].
9. Firoozabadi R, Spittler C, Schlepp C, Hamilton B, Agel J, Roult MC, et al. Determining stability in posterior wall acetabular fractures. *J Orthop Trauma.* 2015;29(10):465-9. doi: [10.1097/BOT.0000000000000354](https://doi.org/10.1097/BOT.0000000000000354). [PubMed: [25938598](https://pubmed.ncbi.nlm.nih.gov/25938598/)].
10. Goodman AD, Vaughn J, Gil JA, Kuris EO, Tuttle J. There's No Unreliable Way to Measure a Posterior Wall Acetabular Fracture: An Inter- and Intra-rater Reliability Analysis of Three Methods. ORS 2017 Annual Meeting Poster No.2212. Available from: URL: <https://www.ors.org/Transactions/63/2212.pdf>
11. Calkins MS, Zych G, Latta L, Borja FJ, Mnaymneh W. Computed tomography evaluation of stability in posterior fracture dislocation of the hip. *Clin Orthop Relat Res.* 1988;227:152-63. [PubMed: [3338204](https://pubmed.ncbi.nlm.nih.gov/3338204/)].
12. Keith JE Jr, Brashear HR Jr, Guilford WB. Stability of posterior fracture-dislocations of the hip. Quantitative assessment using computed tomography. *J Bone Joint Surg Am.* 1988;70(5):711-4. [PubMed: [3392065](https://pubmed.ncbi.nlm.nih.gov/3392065/)].
13. Moed BR, Ajibade DA, Israel H. Computed tomography as a predictor of hip stability status in posterior wall fractures of the acetabulum. *J Orthop Trauma.* 2009;23(1):7-15. doi: [10.1097/BOT.0b013e31818f9a5c](https://doi.org/10.1097/BOT.0b013e31818f9a5c). [PubMed: [19104298](https://pubmed.ncbi.nlm.nih.gov/19104298/)].
14. Moed BR. A thirty year perspective on posterior wall fractures of the acetabulum: Enigma or just another intra-articular injury. *J Taibah Univ Med Sci.* 2016;11(3):179-86. doi: [10.1016/j.jtumed.2016.02.002](https://doi.org/10.1016/j.jtumed.2016.02.002).
15. Reagan JM, Moed BR. Can computed tomography predict hip stability in posterior wall acetabular fractures? *Clin Orthop Relat Res.* 2011;469(7):2035-41. doi: [10.1007/s11999-011-1790-5](https://doi.org/10.1007/s11999-011-1790-5). [PubMed: [21274759](https://pubmed.ncbi.nlm.nih.gov/21274759/)]. [PubMed Central: [PMC3111776](https://pubmed.ncbi.nlm.nih.gov/PMC3111776/)].
16. Mitsionis GI, Lykissas MG, Moutsis E, Mitsiou D, Gkiatas I, Xenakis TA, et al. Surgical management of posterior hip dislocations associated with posterior wall acetabular fracture: A study with a minimum follow-up of 15 years. *J Orthop Trauma.* 2012;26(8):460-5. doi: [10.1097/BOT.0b013e31822c4d6c](https://doi.org/10.1097/BOT.0b013e31822c4d6c). [PubMed: [22357088](https://pubmed.ncbi.nlm.nih.gov/22357088/)].