

# Comminuted Patellar Fracture: A Summary of the Latest Updates

Arash Sharafatvaziri<sup>1</sup>, Ramin Shayan-Moghadam<sup>2</sup>, Mohammad Naghi Tahmasebi<sup>3</sup>,  
 Mohammad Tahami<sup>4</sup>, Fardis Vosoughi<sup>1,5</sup>

<sup>1</sup>Fellowship of Knee, Sport and Reconstruction Surgery, Department of Orthopedic Surgery, Shariati Hospital, Tehran University of Medical Sciences, Tehran, Iran  
<sup>2</sup>Resident, Department of Orthopedic Surgery, Shariati Hospital, School of Medicine, Tehran University of Medical Sciences, Tehran, Iran  
<sup>3</sup>Professor, Department of Orthopedic Surgery, Shariati Hospital, School of Medicine, Tehran University of Medical Sciences, Tehran, Iran  
<sup>4</sup>Assistant Professor, Department of Orthopedic Surgery, Bone and Joint Research Center, Chamran Hospital, Shiraz University of Medical Sciences, Shiraz, Iran  
<sup>5</sup>Orthopedic Surgeon, Department of Orthopedic Surgery, Shariati Hospital, School of Medicine, Tehran University of Medical Sciences, Tehran, Iran

Corresponding author: Fardis Vosoughi; Department of Orthopedic Surgery, Shariati Hospital, School of Medicine, Tehran University of Medical Sciences, Tehran, Iran.  
 Tel: +98-2184901000, Email: fardis.vosoughi@gmail.com

Received: 21 July 2019; Revised: 27 September 2019; Accepted: 09 November 2019

**Keywords:** Patella; Comminuted, Fracture; Fractures, Bone

**Citation:** Sharafat Vaziri A, Shayan-Moghadam R, Tahmasebi MN, Tahami M, Vosoughi F. **Comminuted Patellar Fracture: A Summary of the Latest Updates.** *J Orthop Spine Trauma* 2019; 5(4): 99-102.

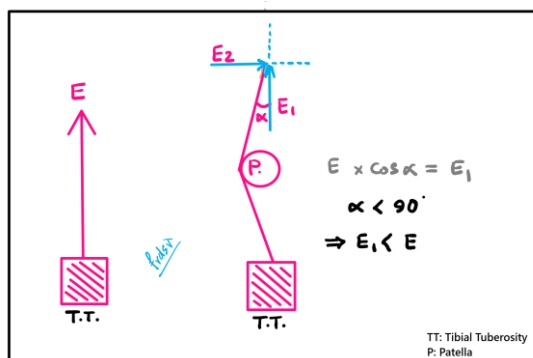


## Background

For many years, the most common approach to a comminuted patella was excision. As further research shed light on the biomechanical importance of the patella, more attention was paid to the complications of patellectomy. So far, numerous attempts have been made to introduce successful alternatives, since nearly 55% of all surgically treated patellar fractures are comminuted (1). Nevertheless, comminuted patellar fractures still pose a challenge to the orthopedic trauma surgeons around the world.

### 1- Anatomy and Biomechanics

Patella is a unique bone in the human body: it is the largest sesamoid bone and one of the few bones that lack a periosteal coverage (2, 3). The biomechanical significance of the patella is overrated. It is located between the two longest lever arms in the body (Femur and Tibia), and acts as a pulley that enhances the function of the knee extensor mechanism (4). This pulley function of the patella which enhances the quadriceps force can be shown mathematically (Figure 1). Being pulled both upward (by quadriceps) and downward (by patellar tendon), it endures a tremendous amount of mechanical stress; so, it is not surprising that patella is the most common failure point in the knee extensor mechanism.



**Figure 1.** Function of the patella as a pulley in extensor mechanism

In order to understand the reasoning behind the fixation strategies, it is essential to become familiar with the patella's anatomy. Thick articular cartilage covers the proximal three quarters of the patella's posterior surface, while the distal pole does not participate in the patellofemoral joint. From the four components of the quadriceps muscle, only the deep layer is attached to the patella. The superficial layer (rectus femoris muscle) passes anterior to the patella, and later, merges with the patellar tendon (2).

### 2- Injury Characteristics and Classification

In the well-known fracture and dislocation classification system of "Arbeitsgemeinschaft für Osteosynthesefragen/ Orthopaedic Trauma Association" (AO/OTA), the patella is coded as number 34, and its comminuted fractures are classified as types 34C2 or 34C3 (5). Recently, there has been some skepticism in the conclusiveness of the AO/OTA classification. For example, coronal split patellar fractures are not particularly described by this classification, despite the different reduction/ fixation techniques required in this pattern (6).

From the injury mechanism perspective, direct blows cause the majority of simple transverse patellar fractures. Indirect mechanisms due to a sudden contraction of quadriceps muscle are less common (7, 8). Comminuted fractures usually happen in the setting of high-energy motor vehicle accidents, and bear the risk of extensive damage to the surrounding soft tissue.

### 3- Diagnosis

Joint effusion, hemarthrosis, focal tenderness, and palpable defect between fracture pieces are commonly present in the setting of comminuted patellar fractures. In the case of concomitant retinacular tear, joint effusion might be absent. Status of the knee extensor mechanism and surrounding soft tissue could have a significant impact on the treatment strategy. However, the patient's ability to actively extend the knee does not rule out a patellar fracture, as it could happen by using lateral retinacular attachments, iliotibial band, or even adductor musculature (2). Moreover, the integrity of ligamentous structures needs special attention. The cruciate ligament

tear has been reported frequently as an associated pathology in dashboard injuries (9, 10).

The anteroposterior (AP) and lateral radiographs should be taken in all patients with suspected patellar fracture. The lateral view is best for visualizing the articular incongruity and step-off. In our center, we generally prefer to perform computed tomography (CT) scans with three-dimensional reconstruction in comminuted fractures of the patella and refrain from painful tangential views in the acute setting (3).

Magnetic resonance imaging (MRI) could be helpful in ruling out injuries to knee ligaments, menisci, and (osteo)chondral lesions (2).

#### 4- Treatment Strategy

Treatment goals are to restore the articular surface, maintain the knee extensor mechanism, restore anatomical alignment, prevent patellar bone loss as much as possible, and start an early rehabilitation program (11, 12). There is a wide variety of options for the treatment of comminuted patellar fractures. Non-operative treatment has been described for patients with severe osteoporosis and medical comorbidities that preclude proper anesthesia (10, 13). However, most comminuted cases eventually undergo surgery. Here, we review some of the most useful strategies.

**Surgical Approach:** Common approaches for patellar fracture treatment are midline longitudinal incision and medial parapatellar incision. In both methods, the patient lies in a supine position with a cushion under the ipsilateral hip which prevents external rotation of the leg during surgery. Putting a cushion below the lower thigh provides 30-40 degrees of flexion in the knee joint. The sterile tourniquet can be set at 300 mmHg or more depending on the size of the thigh (14). For highly complex intra-articular fractures, parapatellar arthrotomy, or a more extensive approach with osteotomy of the tibial tuberosity might be needed to evert the patella and to acquire a better exposure to the articular surface (15, 16).

**Fixation Methods:** Various methods have been introduced lately for fixation of the comminuted patellar fracture, such as basket plates, mesh plates, circumferential cerclage wiring, modified tension band fixation, nickel-titanium patella concentrator, cable pin system, titanium cable cerclage, and plate-screw fixation. Due to the deteriorative effect of partial or total patellectomy on the strength and function of the quadriceps muscle and knee cartilage, patellectomy should be avoided whenever possible (17).

**Tension Band Wiring (TBW)/ Circular Cerclage:** The modified TBW is a common technique for fixing patellar fractures, converting the pulling force of the extensor mechanism on the patella into compression forces. Two or more 1.5-2 mm K-wires are placed perpendicular to the fracture line with a figure-of-eight tension band to secure it. The ends of the K-wires are then concealed deep in the patella. A circular cerclage wire can then be placed around the patella in order to increase the reduction stability (Figure 2). Modified TBW has been successfully used in comminuted fractures but attention must be paid not to over-compress a comminuted fracture.

Augmenting TBW fixation with McLaughlin patello tibial cerclage is also helpful in comminuted or distal pole fractures (18). This construct reduces the quadriceps pull on the fracture during knee flexion. However, the risk of patella baja is a major drawback of this technique, which in most cases can be avoided with intraoperative fluoroscopy and measuring the appropriate amount of tightening of the wire.

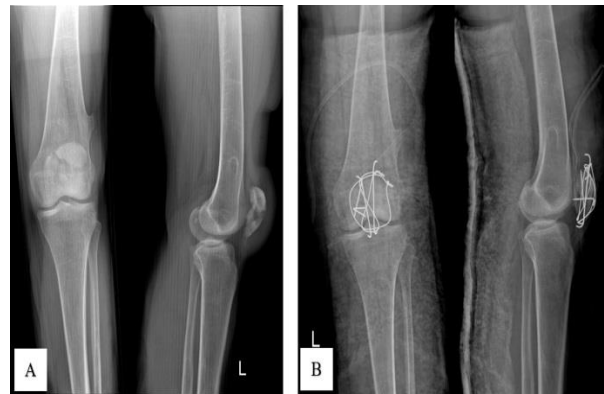

Figure 2. Radiographs of a comminuted patellar fracture, before (A) and after (B) fixation with pin and cerclage wire

Newer modifications of the TBW technique have lately been described. Cho et al. used a miniplate augmented TBW for comminuted patellar fractures with good results (6, 19). Using interfragmentary mini-screws or multiple wires has yielded varying results (20, 21).

One of the main downsides of TBW is, undoubtedly, the symptomatic hardware, which has forced many surgeons to abandon this technique. The rate of symptomatic hardware removal has been reported to be as high as 36.8% (20, 22-25). Concealing the hardware proximally in the soft tissue and more rigid fixation with screws or mini-plates has been reported to reduce this complication by preventing the proximal migration of the K-wires (6).

**Basket Plate:** Some surgeons prefer partial patellectomy in comminuted fractures of the distal pole, as they are usually not easy to reconstruct. Partial patellectomy could cause patella baja, resulting in a reduced postoperative range of motion (ROM) in the knee joint. Restoring the patellar height in such cases presents a challenge. In the last decades, using basket plates has become particularly popular. A basket plate's special geometry conforms to that of patellar distal pole (Figure 3). With six hooks and screws, it is fixated under the comminuted patella to help stabilize the fracture and also maintain its height (26). Acceptable results have been reported with this fixation technique (27, 28). Similar techniques such as augmenting fixation with mesh plates and "X-Change™ Acetabular Revision Mesh" have also been introduced and successfully applied in comminuted patellar fractures with differing results (29, 30).

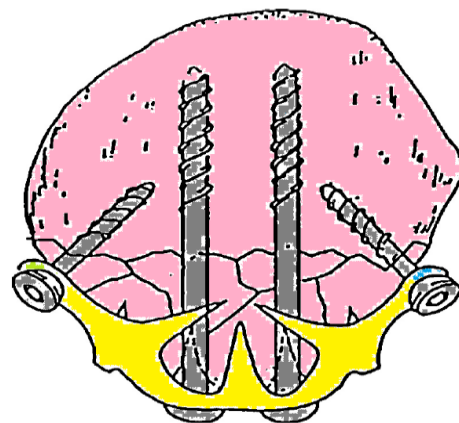




Figure 3. Schematic drawing of a basket plate

**Patellar Concentrator:** Nitinol patellar concentrator (NT-PC), with its 5 claws (2 proximal and 3 distal; [Figure 4](#)), has highly benefited from the deformability characteristics of nitinol (Nickel-Titanium alloy). A concentrator slightly smaller than the patient's patella is chosen. Right after gaining reduction and before implantation, it is soaked in cold saline (0-4 °C) to make it soft and deformable. After fixing all five claws precisely around the patella, warm saline (40-45 °C) is poured on the plate to make it shrink again, imposing compression on the fracture surface. A mean union time of approximately two months has been reported with this technique with excellent results in more than 70% of patients (31). It seems that the high rates of implant breakage and fixation failure related to TBW would not happen with NT-PC. In addition, it does not require drilling, is MRI compatible, and allows earlier rehabilitation owing to the compressive effect (31, 32). Partial weight-bearing is allowed six weeks after surgery. After union, the plate can be removed using cold saline and a forceps to open the claws.



**Figure 4.** Nitinol patella concentrator

**Craniofacial Mesh Plates:** Mesh plates are widely used for fixation of craniofacial fractures. A 2.7 mm mesh variable angle plate can be cut and conformed to the appropriate shape and size ([Figure 5](#)). Then, it is fixed with 2.4 or 2.7 locking screws to the anterior surface of the fragmented patella (29, 30, 33-38). As the far cortex is the articular surface, it is imperative to use locking screws. ROM cannot be started right after the surgery and a two-week interval is usually needed. Acceptable results have been reported with mesh plate augmentation (33).



**Figure 5.** Mesh plate

The most important point to remember is that these new fixation methods are all measures to prevent partial/total patellectomy. All fixation devices that need to be applied on the anterior surface of the patella, including concentrators or mesh plates, may cause soft tissue irritation in kneeling postures or during ROM.

**Partial Patellectomy:** When the comminuted patella consists of a severely fractured distal pole and a main proximal fragment, it is reasonable to think of partial patellectomy due to the low chance of appropriate reduction and fixation. To keep the extensor compartment functional, it is crucial to preserve the central portion of the patella and two-thirds of the articular surface (2, 30, 39). Additionally, reconstruction of the distal pole needs special attention because of the high tension produced by the quadriceps muscle. It is recommended to use McLaughlin cerclage for the first six weeks to prevent re-displacement.

The major drawback to this method is the decrease in the distance between the patella and tibial tuberosity after partial patellectomy which leads to patella baja and increased patellofemoral contact pressure. This may cause knee pain and early onset osteoarthritis (2).

**Complete Patellectomy:** Complete patellectomy is the equivalent of surrendering to the complex fracture and failure to maintain an effective extensor mechanism for the patient. The decision for total patellectomy should be individualized. Kaufer (39) showed that the 30% enhancement in quadriceps function enforced by the presence of the patella is crucial for the appropriate extension of the knee. He also highlighted the 15-50% increase in the traction forces exerted by quadriceps and patellar tendon after complete resection of the patella. All these events lead to quadriceps strength loss, swelling, limitation in ROM, persistent knee pain, and episodes of giving way. The biomechanical role of patella justifies the avoidance of patellectomy, even in severely displaced or comminuted fractures in which great effort should be made to reconstruct the patella. Nevertheless, patellectomy might be inevitable in severe osteomyelitis or severely comminuted fracture patterns.

#### 5- Postoperative Care

After reliable perfect reduction and fixation, patients should initiate careful gentle progressive ROM over a four-week period. Continuous passive motion devices have proven to be helpful in the rehabilitation of these patients. The isometric contraction of quadriceps should be started as soon as possible. In comminuted fractures, we prefer to cast the knee in full extension and start the weight-bearing and isometric contraction exercises (40).

#### Conflict of Interest

The authors declare no conflict of interest in this study.

#### Acknowledgments

None.

#### References

1. Neumann HS, Winckler S, Strobel M. Long-term results of surgical management of patellar fractures. *Unfallchirurg*. 1993;96(6):305-10. [PubMed: 8342058].
2. Gwinner C, Mardian S, Schwabe P, Schaser KD, Krapohl BD, Jung TM. Current concepts review: Fractures of the patella. *GMS Interdiscip Plast Reconstr Surg DGPW*. 2016;5:Doc01. doi: 10.3205/ijprs000080. [PubMed: 26816667]. [PubMed Central: PMC4717300].
3. Mehling I, Mehling A, Rommens PM. (i) Comminuted patellar fractures. *Curr Orthop*. 2006;20(6):397-404.
4. Nordin M, Frankel VH. Basic biomechanics of the musculoskeletal system. Philadelphia, PA: Lippincott Williams & Wilkins; 1991.
5. Muller ME, Allgower M, Schneider R, Willenegger H. Manual of internal fixation: Techniques recommended by the AO group.



- Berlin, Germany: Springer Science & Business Media; 2012.
6. Cho JW, Kent WT, Cho WT, Kim JK, Moon KH, Yeo DH, et al. Miniplate augmented tension-band wiring for comminuted patella fractures. *J Orthop Trauma*. 2019;33(4):e143-e150. doi: [10.1097/BOT.0000000000001390](https://doi.org/10.1097/BOT.0000000000001390). [PubMed: [30893222](https://pubmed.ncbi.nlm.nih.gov/30893222/)].
  7. Bui CN, Learned JR, Scolaro JA. Treatment of patellar fractures and injuries to the extensor mechanism of the knee: A critical analysis review. *JBJS Rev*. 2018;6(10):e1. doi: [10.2106/JBJS.RVW.17.00172](https://doi.org/10.2106/JBJS.RVW.17.00172). [PubMed: [30277900](https://pubmed.ncbi.nlm.nih.gov/30277900/)].
  8. Melvin JS, Mehta S. Patellar fractures in adults. *J Am Acad Orthop Surg*. 2011;19(4):198-207. doi: [10.5435/00124635-201104000-00004](https://doi.org/10.5435/00124635-201104000-00004). [PubMed: [21464213](https://pubmed.ncbi.nlm.nih.gov/21464213/)].
  9. Scolaro J, Bernstein J, Ahn J. Patellar fractures. *Clin Orthop Relat Res*. 2011;469(4):1213-5. doi: [10.1007/s11999-010-1537-8](https://doi.org/10.1007/s11999-010-1537-8). [PubMed: [20740335](https://pubmed.ncbi.nlm.nih.gov/20740335/)]. [PubMed Central: [PMC3048243](https://pubmed.ncbi.nlm.nih.gov/PMC3048243/)].
  10. Braun W, Wiedemann M, Ruter A, Kundel K, Kolbinger S. Indications and results of nonoperative treatment of patellar fractures. *Clin Orthop Relat Res*. 1993;(289):197-201. [PubMed: [8472415](https://pubmed.ncbi.nlm.nih.gov/8472415/)].
  11. Benjamin J, Bried J, Dohm M, McMurtry M. Biomechanical evaluation of various forms of fixation of transverse patellar fractures. *J Orthop Trauma*. 1987;1(3):219-22. doi: [10.1097/00005131-198701030-00004](https://doi.org/10.1097/00005131-198701030-00004). [PubMed: [3506054](https://pubmed.ncbi.nlm.nih.gov/3506054/)].
  12. Sun Y, Sheng K, Li Q, Wang D, Zhou D. Management of comminuted patellar fracture fixation using modified cerclage wiring. *J Orthop Surg Res*. 2019;14(1):324. doi: [10.1186/s13018-019-1385-5](https://doi.org/10.1186/s13018-019-1385-5). [PubMed: [31623684](https://pubmed.ncbi.nlm.nih.gov/31623684/)]. [PubMed Central: [PMC6798409](https://pubmed.ncbi.nlm.nih.gov/PMC6798409/)].
  13. Smith TO, Song F, Donell ST, Hing CB. Operative versus non-operative management of patellar dislocation. A meta-analysis. *Knee Surg Sports Traumatol Arthrosc*. 2011;19(6):988-98. doi: [10.1007/s00167-010-1355-2](https://doi.org/10.1007/s00167-010-1355-2). [PubMed: [21234544](https://pubmed.ncbi.nlm.nih.gov/21234544/)].
  14. Wilber J, Gladden PB. Patellar fractures: Open reduction internal fixation. In: Wiss DA, Editor. *Fractures*. Philadelphia, PA: Lippincott Williams & Wilkins; 1998.
  15. Berg EE. Extensile exposure of comminuted patella fractures using a tibial tubercle osteotomy: results of a new technique. *J Orthop Trauma*. 1998;12(5):351-5. doi: [10.1097/00005131-199806000-00010](https://doi.org/10.1097/00005131-199806000-00010). [PubMed: [9671188](https://pubmed.ncbi.nlm.nih.gov/9671188/)].
  16. Gardner MJ, Griffith MH, Lawrence BD, Lorich DG. Complete exposure of the articular surface for fixation of patellar fractures. *J Orthop Trauma*. 2005;19(2):118-23. doi: [10.1097/00005131-200502000-00008](https://doi.org/10.1097/00005131-200502000-00008). [PubMed: [15677928](https://pubmed.ncbi.nlm.nih.gov/15677928/)].
  17. Galla M, Lobenhoffer P. Patella fractures. *Chirurg*. 2005;76(10):987-97. doi: [10.1007/s00104-005-1081-3](https://doi.org/10.1007/s00104-005-1081-3). [PubMed: [16170504](https://pubmed.ncbi.nlm.nih.gov/16170504/)].
  18. McLaughlin HL. Repair of major tendon ruptures by buried removable suture. *Am J Surg*. 1947;74(5):758-64. doi: [10.1016/0002-9610\(47\)90233-x](https://doi.org/10.1016/0002-9610(47)90233-x). [PubMed: [20270297](https://pubmed.ncbi.nlm.nih.gov/20270297/)].
  19. Gao S, Zhang F, Gao T, Liu X, Zhang Z, Dai M. A novel technique of using a miniature plate in combination with tension band wiring to treat comminuted patellar fractures. *Medicine (Baltimore)*. 2018;97(15):e0311. doi: [10.1097/MD.00000000000010311](https://doi.org/10.1097/MD.00000000000010311). [PubMed: [29642160](https://pubmed.ncbi.nlm.nih.gov/29642160/)]. [PubMed: [PMC5908579](https://pubmed.ncbi.nlm.nih.gov/PMC5908579/)].
  20. Hoshino CM, Tran W, Tiberi JV, Black MH, Li BH, Gold SM, et al. Complications following tension-band fixation of patellar fractures with cannulated screws compared with Kirschner wires. *J Bone Joint Surg Am*. 2013;95(7):653-9. doi: [10.2106/JBJS.K.01549](https://doi.org/10.2106/JBJS.K.01549). [PubMed: [23553301](https://pubmed.ncbi.nlm.nih.gov/23553301/)].
  21. Hambright DS, Walley KC, Hall A, Appleton PT, Rodriguez EK. Revisiting Tension Band Fixation for Difficult Patellar Fractures. *J Orthop Trauma*. 2017;31(2):e66-e72. doi: [10.1097/BOT.0000000000000686](https://doi.org/10.1097/BOT.0000000000000686). [PubMed: [28129272](https://pubmed.ncbi.nlm.nih.gov/28129272/)].
  22. LeBrun CT, Langford JR, Sagi HC. Functional outcomes after operatively treated patella fractures. *J Orthop Trauma*. 2012;26(7):422-6. doi: [10.1097/BOT.0b013e318228c1a1](https://doi.org/10.1097/BOT.0b013e318228c1a1). [PubMed: [22183197](https://pubmed.ncbi.nlm.nih.gov/22183197/)].
  23. Minkowitz RB, Bhadsavle S, Walsh M, Egol KA. Removal of painful orthopaedic implants after fracture union. *J Bone Joint Surg Am*. 2007;89(9):1906-12. doi: [10.2106/JBJS.F.01536](https://doi.org/10.2106/JBJS.F.01536). [PubMed: [17768185](https://pubmed.ncbi.nlm.nih.gov/17768185/)].
  24. Lazaro LE, Wellman DS, Sauro G, Pardee NC, Berkes MB, Little MT, et al. Outcomes after operative fixation of complete articular patellar fractures: assessment of functional impairment. *J Bone Joint Surg Am*. 2013;95(14):e96-e98. doi: [10.2106/JBJS.L.00012](https://doi.org/10.2106/JBJS.L.00012). [PubMed: [23864187](https://pubmed.ncbi.nlm.nih.gov/23864187/)].
  25. Dy CJ, Little MT, Berkes MB, Ma Y, Roberts TR, Helfet DL, et al. Meta-analysis of re-operation, nonunion, and infection after open reduction and internal fixation of patella fractures. *J Trauma Acute Care Surg*. 2012;73(4):928-32. doi: [10.1097/TA.0b013e31825168b6](https://doi.org/10.1097/TA.0b013e31825168b6). [PubMed: [22902732](https://pubmed.ncbi.nlm.nih.gov/22902732/)].
  26. Matejcic A, Smiljanic B, Bekavac-Beslin M, Ledinsky M, Puljiz Z. The basket plate in the osteosynthesis of comminuted fractures of distal pole of the patella. *Injury*. 2006;37(6):525-30. doi: [10.1016/j.injury.2004.09.020](https://doi.org/10.1016/j.injury.2004.09.020). [PubMed: [16324701](https://pubmed.ncbi.nlm.nih.gov/16324701/)].
  27. Matejcic A, Ivica M, Jurisic D, Cuti T, Bakota B, Vidovic D. Internal fixation of patellar apex fractures with the basket plate: 25 years of experience. *Injury*. 2015;46(Suppl 6):S87-S90. doi: [10.1016/j.injury.2015.10.068](https://doi.org/10.1016/j.injury.2015.10.068). [PubMed: [26584729](https://pubmed.ncbi.nlm.nih.gov/26584729/)].
  28. Vidovic D, Matejcic A, Ivica M, Durdevic D, Tomljenovic M, Bekavac-Beslin M, et al. Approach to distal femur by osteotomy of the patellar distal pole and internal fixation with basket plate in complex articular fracture: report of five cases. *Acta Clin Croat*. 2013;52(1):113-8. [PubMed: [23837281](https://pubmed.ncbi.nlm.nih.gov/23837281/)].
  29. Lorich DG, Warner SJ, Schottel PC, Shaffer AD, Lazaro LE, Helfet DL. Multiplanar fixation for patella fractures using a low-profile mesh plate. *J Orthop Trauma*. 2015;29(12):e504-e510. doi: [10.1097/BOT.0000000000000415](https://doi.org/10.1097/BOT.0000000000000415). [PubMed: [26270460](https://pubmed.ncbi.nlm.nih.gov/26270460/)].
  30. Matthews B, Hazratwala K, Barroso-Rosa S. Comminuted patella fracture in elderly patients: A systematic review and case report. *Geriatr Orthop Surg Rehabil*. 2017;8(3):135-44. doi: [10.1177/2151458517710517](https://doi.org/10.1177/2151458517710517). [PubMed: [28835869](https://pubmed.ncbi.nlm.nih.gov/28835869/)]. [PubMed Central: [PMC5557194](https://pubmed.ncbi.nlm.nih.gov/PMC5557194/)].
  31. Zhao QM, Yang HL, Wang L, Liu ZT, Gu XF. Treatment of comminuted patellar fracture with the nitinol patellar concentrator. *Minim Invasive Ther Allied Technol*. 2016;25(3):171-5. doi: [10.3109/13645706.2015.1134577](https://doi.org/10.3109/13645706.2015.1134577). [PubMed: [26796538](https://pubmed.ncbi.nlm.nih.gov/26796538/)].
  32. Tan HL, Qian C, Zhao JK, Shi Y, Zhou Q. Treatment of comminuted patellar fractures with internal Ni-Ti patellar concentrator and tension band wire fixation. *Zhongguo Gu Shang*. 2009;22(2):128-30. [PubMed: [19281026](https://pubmed.ncbi.nlm.nih.gov/19281026/)].
  33. Volgas D, Dreger TK. The use of mesh plates for difficult fractures of the patella. *J Knee Surg*. 2017;30(3):200-3. doi: [10.1055/s-0037-1598078](https://doi.org/10.1055/s-0037-1598078). [PubMed: [28192827](https://pubmed.ncbi.nlm.nih.gov/28192827/)].
  34. Siljander M, Vara AD, Koueiter DM, Gandhi S, Quigley M, Wiater B, et al. Plate osteosynthesis of patella fractures-a video case report. *J Orthop Trauma*. 2017;31(Suppl 3):S26-S27. doi: [10.1097/BOT.0000000000000908](https://doi.org/10.1097/BOT.0000000000000908). [PubMed: [28697080](https://pubmed.ncbi.nlm.nih.gov/28697080/)].
  35. Singer MS, Halawa AM, Adawy A. Outcome of low profile mesh plate in management of comminuted displaced fracture patella. *Injury*. 2017;48(6):1229-35. doi: [10.1016/j.injury.2017.03.026](https://doi.org/10.1016/j.injury.2017.03.026). [PubMed: [28413065](https://pubmed.ncbi.nlm.nih.gov/28413065/)].
  36. Siljander MP, Vara AD, Koueiter DM, Wiater BP, Wiater PJ. Novel anterior plating technique for patella fracture fixation. *Orthopedics*. 2017;40(4):e739-e743. doi: [10.3928/01477447-20170615-02](https://doi.org/10.3928/01477447-20170615-02). [PubMed: [28632289](https://pubmed.ncbi.nlm.nih.gov/28632289/)].
  37. Verbeek DO, Hickerson LE, Warner SJ, Helfet DL, Lorich DG. low profile mesh plating for patella fractures: Video of a novel surgical technique. *J Orthop Trauma*. 2016;30(Suppl 2):S32-S33. doi: [10.1097/BOT.0000000000000589](https://doi.org/10.1097/BOT.0000000000000589). [PubMed: [27441934](https://pubmed.ncbi.nlm.nih.gov/27441934/)].
  38. Vajapey S, Santiago J, Contreras E, Quatman CE, Phieffer LS. Contourable craniofacial mesh plate osteosynthesis of patellar fractures: A new, low-profile fixation technique. *J Clin Orthop Trauma*. 2019;10(Suppl 1):S201-S206. doi: [10.1016/j.jcot.2019.02.015](https://doi.org/10.1016/j.jcot.2019.02.015). [PubMed: [31700211](https://pubmed.ncbi.nlm.nih.gov/31700211/)]. [PubMed Central: [PMC6823816](https://pubmed.ncbi.nlm.nih.gov/PMC6823816/)].
  39. Kaufer H. Mechanical function of the patella. *JBJS*. 1971;53(8):1551-60. doi: [10.2106/00004623-197153080-00007](https://doi.org/10.2106/00004623-197153080-00007).
  40. Zhou K, Yang J, Pan F. Surgical treatment of comminuted patellar fractures by a percutaneous Pylford technique. *Int J Clin Exp Med*. 2017;10(11):15278-85.