

Do Not Do this Case Report: Recurrence of Knee Flexion Contracture after Extension Osteotomy in Congenital Patellar Dislocation: The Importance of a Thorough Patient Evaluation

Soroush Baghdadi¹, Taghi Baghdadi^{2,*}

¹ Assistant Professor, Department of Orthopedics, Joint Reconstruction Research Center, School of Medicine, Tehran University of Medical Sciences, Tehran, Iran; Children's Hospital of Philadelphia (CHOP), Division of Orthopedics, Philadelphia, Pennsylvania, USA

² Professor, Department of Orthopedics, Joint Reconstruction Research Center, School of Medicine, Tehran University of Medical Sciences, Tehran, Iran

*Corresponding author: Taghi Baghdadi; Department of Orthopedics, Joint Reconstruction Research Center, School of Medicine, Tehran University of Medical Sciences, Tehran, Iran. Tel: +98-9121274549, Email: taghibaghdadi@hotmail.com

Received: 17 November 2018; Revised: 24 January 2019; Accepted: 05 May 2019

Abstract

Background: Congenital patellar dislocation (CPD) is a rare disorder which presents with hypoplastic and irreducible patellae. It is accompanied by flexion contracture of the knee joint, genu valgum, and external tibial rotation.

Case Report: A seven-year-old girl with CPD who was misdiagnosed as having cerebral palsy (CP) crouch gait and underwent distal femoral extension osteotomy (DFEO) without paying attention to the dislocated patellae, is presented. Recurrence ensued, and the patient was referred for further evaluation. After a second surgery to address the dislocated patellae, the flexion contracture and gait pattern improved significantly.

Conclusion: The case underscores the importance of a systematic, thorough physical examination, without which uncommon diagnoses will be overlooked, exposing the patient to further morbidity and complications.

Keywords: Congenital Dislocation of the Patella; Gait; Knee; Osteotomy

Citation: Baghdadi S, Baghdadi T. Do Not Do this Case Report: Recurrence of Knee Flexion Contracture after Extension Osteotomy in Congenital Patellar Dislocation: The Importance of a Thorough Patient Evaluation. *J Orthop Spine Trauma* 2019; 5(2): 50-2.



Background

Knee flexion contracture (KFC) is one of the complications caused by many neuromuscular disorders (MSDs) [e.g., cerebral palsy (CP) and myelomeningocele], sequelae of infections (e.g., poliomyelitis), and a complication of inflammatory disorders [e.g., juvenile idiopathic arthritis (JIA)], as well as syndromes affecting the musculoskeletal system (e.g., pterygium). It could also be an iatrogenic complication following limb lengthening or long-term immobilization of the knee (1-3).

The deleterious effects of flexed knees on gait has been known for decades. Jacqueline Perry-a pillar of the modern orthopedic surgery-emphasized the significance of achieving full extension in the knee biomechanics. Perry et al. found that the quadriceps force needed to stabilize the knee while standing with knees flexed to 30° is 210% of the body weight (4). The same results have been observed during gait (3). A continuous knee extensor moment is needed to prevent the knee from collapse, as the mechanical axis of the limbs is posterior to the knee joint (3, 4).

The initial attempts to correct KFC through the center of rotation of angulation (CORA) by posterior capsulotomy of the knee were to put it mildly, unsatisfactorily with unpredictable results and frequent neurovascular complications. Although a distal femoral extension osteotomy (DFEO) is biomechanically inferior to a capsulotomy due to the correction being performed proximal to CORA, it has been proven to be technically easier and yield more predictable results, with considerably less risk of complications, especially if combined with shortening. Initially made accessible for

the treatment of arthrogryptic and poliomyelitis knee contractures (5), DFEO has become the mainstay of treatment of flexion deformity of the knee joint in many etiologies, including CP (6).

Congenital dislocation of the patella (CDP) is a rare disorder characterized by a persistent, irreducible patellar dislocation and severe shortening of the lateral structures and the quadriceps (7). The earlier reports on the subject did not distinguish between congenital and habitual dislocation. Langenskiöld and Ritsila described his findings in ten patients with CDP, of whom nine were syndromic (8). Ghanem et al. later discussed CDP in further detail and provided their operative findings in eight patients (9). Knee joint flexion contracture, lack of active knee extension, external rotation of the tibia, and genu valgum were found to be the common features in the patients.

We present the case of a seven-year-old girl with idiopathic CDP, who was misdiagnosed with CP and underwent DFEO to correct flexion contracture of her knee joint. She subsequently experienced a deformity recurrence.

Case Report

The seven-year-old girl was referred to the pediatric orthopedics clinic of a tertiary referral hospital for a second opinion. She started walking at the age of 26 months and had always been strolling with bent knees. She had healthy upper limbs and intelligence performing well at school. One year earlier, she was visited by an orthopedic surgeon at an outside facility complaining of

genu valgum and bent knees and was told that she had mild CP. She subsequently underwent bilateral distal femoral extension-varus osteotomies. Despite being satisfied with the coronal balance, the sagittal balance and the walking pattern were not improved by the surgery. The patient's five-year-old brother had recently undergone the same procedure and was in long-leg casts at the time of referral. Neither our patient nor her brother had a significant medical or surgical history except for the knees.

On physical examination, the patellae were laterally displaced, irreducible, and hypoplastic. Active knee extension was weak, and the flexion contracture of the knees was appreciable bilaterally (Figure 1).

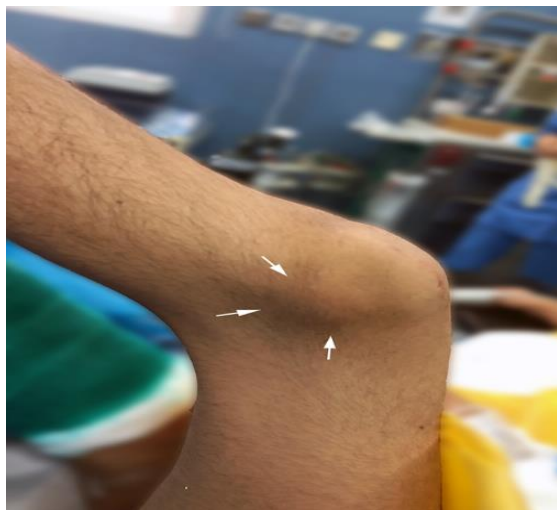

Figure 1. Left knee before the second surgery. The foot is to the left. Flexion contracture of the knee is evident. Arrows point to the hypoplastic patella, which is irreducibly dislocated.

A wide-based, crouch-type gait with small steps was present. On the pre-operative radiographs, the patellae were not visualized, while severe knee valgus and lateral subluxation of the tibiae over femurs were evident (Figure 2).

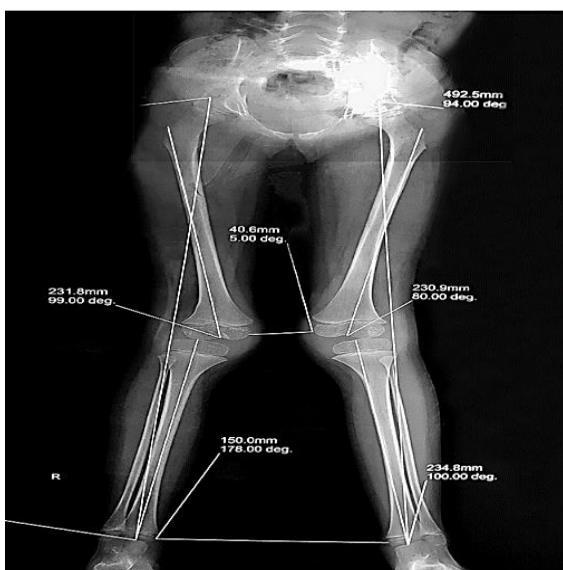


Figure 2. Pre-operative standing radiograph showing genu valgum and lateral subluxation of the tibia. The patellae are not ossified yet, despite the patient being five years old.

On the latest radiographs, the patellae were ossified bilaterally, albeit hypoplastic and dislocated (Figure 3).

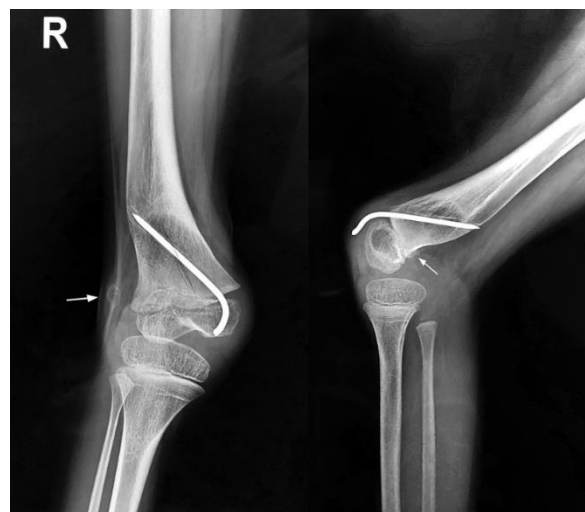

Figure 3. Anteroposterior (AP) and lateral radiographs of the right knee at the time the patient was referred for a second opinion. The first surgeon added a distal femoral varus component to the patient's deformity to improve the clinical knee valgus. Arrows point to the patella, which is now ossified and is visible along with a faint shadow of the patellar tendon.

With the diagnosis of CDP, the patient underwent bilateral extensive lateral release and reefing of the medial structures. Additionally, the extensor mechanism was short and hypoplastic, which necessitated a V-Y quadricepsplasty. The patellae were stable on gentle range-of-motion (ROM) at the end of the operation, and a cast was applied in 30° of flexion for four weeks. In the final follow-up, a full extension was achieved on both knees, active knee extension was present but weak, and the walking speed and endurance were significantly improved. Her brother was also scheduled for the same operation.

Discussion

The presented case epitomizes the imperative to 'treat the patient, not the x-rays' or, in this case, the gait pattern. In his operative notes, the first surgeon had mentioned that DFEO was performed to correct the 'knees in valgus and flexion contracture' due to a diagnosis of CP. Delayed walking age, KFC, and crouch gait were suggestive of a neuromuscular diagnosis. The absence of a patellar shadow on the standing pre-operative radiographs might have also been a factor in missing the diagnosis of CDP. However, a systematic physical examination would have revealed that the patella bone, albeit hypoplastic, was lying on the knee joint lateral side.

CDP is an uncommon condition. It may occur in isolation or associated with specific syndromes, including nail-patella syndrome. CDP should be identified from more common causes of patellar dislocation: habitual and recurrent patellar dislocation. An irreducible, laterally-located patella with weakness in extending the knee joint, external rotation of the tibia on the femur, and flexion contracture and valgus of the joint help make the diagnosis of CDP (10).

CDP alters the knee joint biomechanics. With the patella closer to the center of rotation of the joint, the extensor mechanism' moment arm is shortened, which,

combined with an already contracted and weak quadriceps, results in significant weakness in knee extension. The quadriceps will eventually act as a flexor of the knee, which will further deteriorate the walking ability and endurance (7, 10). The CDP treatment is always surgical and includes an extensive lateral release and medialization of the extensor mechanism. The trochlear groove is hypoplastic and may need deepening if severe (11). In older patients, pre-operative serial casting or surgical lengthening of the hamstrings have been performed to correct KFC. However, enhancing the knee biomechanics by restoring the regular knee extension forces will gradually improve KFC, and in many cases, obviates the need for a surgical release (12). The results of surgical treatment are generally favorable. Complications are not common but may include redislocation and neuropraxia (11, 12).

To conclude, the treating surgeon should never overlook a careful, systematic physical examination. In this case, it was revealed that the patient suffered from bilateral CDP, and despite the crouch gait and walking delay, there was no neuromuscular disease underlying to KFC.

Conflict of Interest

The authors declare no conflict of interest in this study.

Acknowledgments

None.

References

1. Tew M, Forster IW. Effect of knee replacement on flexion deformity. *J Bone Joint Surg Br.* 1987;69(3):395-9. [PubMed: 3584192].
2. Ritter MA, Lutgring JD, Davis KE, Berend ME, Pierson JL, Meneghini RM. The role of flexion contracture on outcomes in primary total knee arthroplasty. *J Arthroplasty.* 2007;22(8):1092-6. doi: 10.1016/j.arth.2006.11.009. [PubMed: 18078875].
3. Harato K, Nagura T, Matsumoto H, Otani T, Toyama Y, Suda Y. Knee flexion contracture will lead to mechanical overload in both limbs: A simulation study using gait analysis. *Knee.* 2008;15(6):467-72. doi: 10.1016/j.knee.2008.07.003. [PubMed: 18760608].
4. Perry J, Antonelli D, Ford W. Analysis of knee-joint forces during flexed-knee stance. *J Bone Joint Surg Am.* 1975;57(7):961-7. [PubMed: 1194303].
5. DelBello DA, Watts HG. Distal femoral extension osteotomy for knee flexion contracture in patients with arthrogryposis. *J Pediatr Orthop.* 1996;16(1):122-6. doi: 10.1097/00004694-199601000-00025. [PubMed: 8747369].
6. Boyer ER, Stout JL, Laine JC, Gutknecht SM, Araujo de Oliveira LH, Munger ME, et al. Long-term outcomes of distal femoral extension osteotomy and patellar tendon advancement in individuals with cerebral palsy. *J Bone Joint Surg Am.* 2018;100(1):31-41. doi: 10.2106/JBJS.17.00480. [PubMed: 29298258].
7. Wada A, Fujii T, Takamura K, Yanagida H, Suriyamorn P. Congenital dislocation of the patella. *J Child Orthop.* 2008;2(2):119-23. doi: 10.1007/s11832-008-0090-4. [PubMed: 19308591]. [PubMed Central: PMC2656798].
8. Langenskiold A, Ritsila V. Congenital dislocation of the patella and its operative treatment. *J Pediatr Orthop.* 1992;12(3):315-23. doi: 10.1097/01241398-199205000-00007. [PubMed: 1572994].
9. Ghanem I, Wattincourt L, Seringe R. Congenital dislocation of the patella. Part II: Orthopaedic management. *J Pediatr Orthop.* 2000;20(6):817-22. doi: 10.1097/00004694-200011000-00024. [PubMed: 11097262].
10. Drennan JC. Congenital dislocation of the knee and patella. *Instr Course Lect.* 1993;42:517-24. [PubMed: 8463700].
11. Sever R, Fishkin M, Hemo Y, Wientroub S, Yaniv M. Surgical treatment of congenital and obligatory dislocation of the patella in children. *J Pediatr Orthop.* 2019;39(8):436-40. doi: 10.1097/BPO.0000000000000973. [PubMed: 31393310].
12. Clark D, Metcalfe A, Wogan C, Mandalia V, Eldridge J. Adolescent patellar instability: Current concepts review. *Bone Joint J.* 2017;99-B(2):159-70. doi: 10.1302/0301-620X.99B2.BJJ-2016-0256.R1. [PubMed: 28148656].