

# Decision Making in Femoral Neck Fractures: Internal Fixation versus Arthroplasty

Seyed Mir Mansour Moazen Jamshidi<sup>1</sup>, Mohammadreza Razzaghof<sup>2</sup>,  
Seyed Mohammad Javad Mortazavi<sup>3,\*</sup>

<sup>1</sup>Fellowship of Hip Surgery, Joint Reconstruction Research Center, Tehran University of Medical Sciences, Tehran, Iran

<sup>2</sup>Resident, Department of Orthopedics, Joint Reconstruction Research Center, School of Medicine, Tehran University of Medical Sciences, Tehran, Iran

<sup>3</sup>Professor, Department of Orthopedics, Joint Reconstruction Research Center, School of Medicine, Tehran University of Medical Sciences, Tehran, Iran

\*Corresponding author: Seyed Mohammad Javad Mortazavi; Department of Orthopedics, Joint Reconstruction Research Center, School of Medicine, Tehran University of Medical Sciences, Tehran, Iran. Tel: +98-9121776150, Email: smjmort@yahoo.com

Received: 10 December 2018; Revised: 04 February 2019; Accepted: 12 April 2019

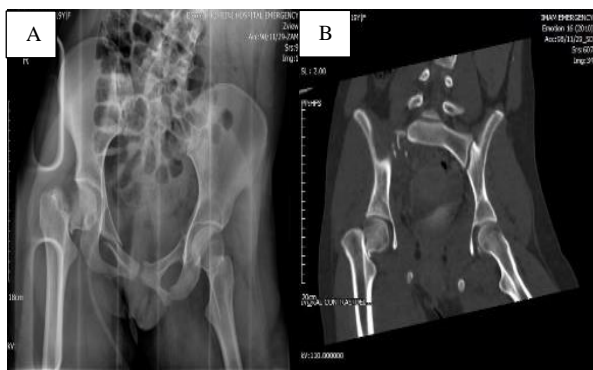**Keywords:** Femoral Neck Fracture; Internal Fixation Device; Total Hip Replacement; Hemiarthroplasty; Hip Fractures

**Citation:** Moazen Jamshidi SMM, Razzaghof M, Mortazavi SMJ. Decision Making in Femoral Neck Fractures: Internal Fixation versus Arthroplasty. *J Orthop Spine Trauma* 2019; 5(2): 45-9.



## Background

A 19-year-old woman came to our clinic with a femoral neck fracture (Figure 1). What is your stepwise approach to choose the appropriate treatment, i.e., internal fixation or arthroplasty?



**Figure 1.** A 19-year-old woman with right femoral neck fracture; pelvic anteroposterior (AP) x-ray (A), computed tomography (CT) scan (B)

Hip fracture is considered a global public health issue, as nearly 1.5 million hip fractures occur worldwide annually. It is anticipated that 3.9 million hip fractures will occur worldwide in 2050 per year, more than 700,000 of which will be in the United States (US). Hip fractures in the elderly are associated with diminished mobility, conspicuous loss of independence, increased morbidity, and mortality (1). Therefore, hip fractures are a public health concern, particularly with the aging population, and must be surveyed and treated accurately.

Due to its unique retrograde blood supply, the rates of nonunion and necrosis of femoral head following femoral neck fracture are higher than the general population (approximately 4.2% and 33.0%, respectively) (2).

Since 1930, when Smith Petersen et al. invented their method for the fixation of femoral neck fractures, the surgical treatment method has improved remarkably, and the rates of nonunion and femoral head necrosis have declined (3). However, no consensus has been reached

regarding the ideal treatment (1). Currently, the choice of treatment for femoral neck fractures is as follows: in a non-displaced fracture, internal fixation is recommended. In a displaced fracture, if the patient is younger than 65 years old with good bone quality, internal fixation is recommended. In patients older than 65 years, the recommended treatment is total hip arthroplasty (THA) and hemiarthroplasty (HA) in active and inactive patients, respectively (4).

Two problems might occur with this treatment concept. First, it is too generalized, with no standardization as a reference. The clinical decision on choosing surgical methods should be based on patient- and surgeon-related factors (5).

Second, it struggles to meet with clinical practice in some conditions. HA is more applicable than internal fixation for a large proportion of inactive patients with non-displaced femoral neck fractures due to the low bone density and serious medical conditions. Over the last few years, it has been understood that the type and displacement of the fracture, the patient's age, mobility, medical comorbidities, cognition, and many other factors must be taken into account when choosing surgical methods for femoral neck fractures (5).

In this study, we briefly describe the best criteria in choosing the best surgical method for a femoral neck fracture and discuss their advantages and disadvantages.

### ***When Should the Orthopedic Surgeons Choose Internal Fixation?***

The main goal of internal fixation is to decrease the risk of displacement for non-displaced fractures and to maintain fracture reduction for displaced fractures that have been reduced operatively (6).

The reduction can be gained either by closed (under fluoroscopy) or open maneuver. Several devices and more than a hundred types of fixation exist (7). The most common complications after internal fixation are as follows: nonunion (10%), avascular necrosis (AVN) (14%), femoral neck shortening (10-32 percent), and reoperation (20%). Nonunion is due to the displacement secondary to implant failure or, less frequently, failure of the fracture to consolidate with an intact implant (8).

Moreover, one of the most important reasons for

nonunion is suboptimal reduction of the femoral neck fracture (9).

AVN occurs when the vascular supply of the femoral head is destroyed by a displaced bone fragment or by the implant itself. Various implants have been used for internal fixation of the fracture (10).

The most used implants include cancellous screw and sliding hip screw (SHS), both of which allow for sliding of the fracture fragments along the femoral neck axis. Consistent with the "strain theory", the sliding must lead to a biologic motion of fracture for healing. A fixed-angle blade and valgus osteotomy are other options that must be used in special conditions such as a highly vertical fracture with Pauwels type III. Pauwels classification is based on the verticality of shear angle of femoral neck fractures, that is, an angle up to 30° is defined as type I, between 30° and 50° as type II, and 50° and more as type III (11).

The choice of internal fixation to treat a femoral neck fracture depends on many factors, such as the patient's age, the angle of the fracture line with the horizontal line, bone quality, and the surgeon's experience (12).

Bhandari et al. showed that closed reduction and internal fixation (CRIF) was preferable to arthroplasty in patients with displaced femoral neck fractures who were under 60 years old. In another study in 2003, they showed that arthroplasty in patients older than 60 years had better outcomes than CRIF in terms of the postoperative function and revision rate (10).

Other studies demonstrated that CRIF in ages over 70 years had the worst outcomes regarding the complication and reoperation rates, compared with arthroplasty. Keating et al. showed that internal fixation was not preferred to arthroplasty in patients over 70 years old (13). Leonard et al. found that internal fixation had more complications than arthroplasty in patients over 70 years old (14). They showed that patients older than 70 years had more pain and reoperation rate after internal fixation compared to arthroplasty (12).

#### **Authors' Preferred Approach to the Treatment of Femoral Neck Fractures**

In our institute, we choose internal fixation as below:

1. Internal fixation for non-displaced femoral neck fractures
2. Internal fixation for displaced femoral neck fractures in:
  - a. Patients under 40 years old
  - b. Patients between 40-60 years old with a good bone quality and no comorbidities

According to above criteria, we can decide which treatment to choose in most of the femoral neck fractures, but in some conditions such as rheumatoid arthritis (RA), end-stage renal disease (ESRD), menopause, or neuromuscular diseases, decision-making is controversial due to low bone quality and other comorbidities. To solve this problem, we recommend the below criteria to choose between internal fixation and arthroplasty in these circumstances. Based on the study by Liu et al., five major factors, including patient's age, fracture type, bone mineral density, activities of daily living, and medical comorbidities were selected as the quantitative score system (QSS) table (Table 1).

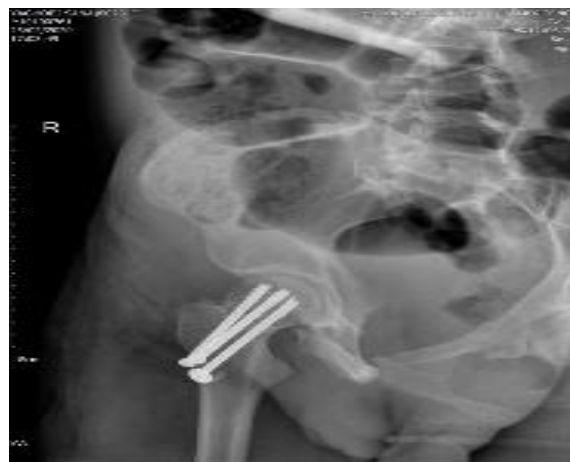Each component has many subtypes, and each subtype has its unique score. If the score is 11 or less, CRIF should be chosen, and if the score is 12 or higher, arthroplasty is indicated. The use of this table may solve the controversies over the treatment of femoral neck fractures (15).

**Table 1.** Quantitative score system (QSS) for the surgical decision on adult femoral neck fractures

Component score	
<b>Age (year)</b>	
20-60	0
61-65	1
66-70	2
71-75	3
76-80	4
> 80	5
<b>Fracture type</b>	
Non-displaced (Garden I, II)	0
Displaced (Garden III, IV)	5
<b>Activities of daily living</b>	
<b>Outdoor</b>	
Completely normal; can participate in vigorous activities such as swimming	0
Able to participate in physical activity in general; can be up and down 6 floors independently	1
Mild limitation of general physical activity; can be up and down 3 floors independently	2
<b>Indoor</b>	
Able to perform usual self-care	3
Able to perform little usual self-care; confined to a wheelchair	4
Bedridden and limited in ability to perform usual self-care	5
<b>Bone mineral density (Singh index)</b>	
<b>Normal</b>	
All trabecular groups are visible on the radiographic image	0
Principal tensile trabeculae or trabeculae are accentuated	1
Principal tensile trabeculae or trabeculae are reduced (markedly) but can still be traced	2
<b>Osteoporosis</b>	
There is a break in the continuity of the bone tensile	3
Principal compressive trabeculae are seen prominently	4
Principal compressive trabeculae are reduced in number	5
<b>Medical comorbidities (modified ASA score)</b>	
Normally healthy patient	0
Patient with mild systemic disease	1
Patient with severe systemic disease that limits activity but is not incapacitating	3
Patient with an incapacitating systemic disease that is a constant threat to life	5

ASA: American Society of Anesthesiologists

According to this protocol, the recommended treatment for a patient would be internal fixation if it is a displaced fracture in a patient under 40 years old without comorbidities. The postoperative radiograph is seen in figure 2.



**Figure 2.** The postoperative radiograph of our patient showing closed reduction and internal fixation (CRIF) by three cannulated screws

#### **When Should the Orthopedic Surgeons Choose Arthroplasty?**

When the patient is not appropriate for internal fixation, the surgeon must select one of the possible arthroplasty methods to avoid the complications:

1. THA
2. HA [bipolar HA (BH) or unipolar HA (UH)]

We choose arthroplasty in these conditions:

1. Displaced femoral neck fracture in patients older than 60 years
2. Displaced femoral neck fracture in patients between 40-60 years if there are osteoporosis or other comorbidity conditions
3. Non-displaced or displaced femoral neck fracture if they have a QSS score of more than 11

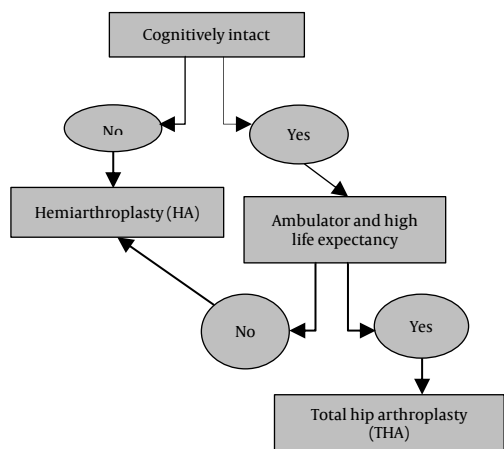
**Which Patients Are Candidates for HA?**

Treatment of femoral neck fracture can be successfully achieved through a HA that leaves the acetabular side intact. It is used in the following circumstances: elderly patients over 80 years, life expectancy less than four years, low mobility capacity, compromised cognition, need for more support, hemiplegia, being underweight, and being on hemodialysis. It is because the large diameter of the head, which is used in these conditions, protects the patient from further dislocation, and the operation time is shorter than internal fixation (16, 17). It is noticeable that choosing HA for the treatment of femoral neck fracture is a last resort. In other words, the treatment of choice in a patient, who is not a candidate for internal fixation, is THA unless they have the criteria mentioned above (6, 18).

**What Are the Common Complications Following HA?**

1. Major complications include periprosthetic fracture (2%), aseptic loosening, dislocation (4%), nine-year mortality (78%), unexplained pain, deep infection, protrusion, and acetabular wear (7). It should be noted that acetabular wear progresses 0.7 mm per year, and 15% to 67% of the HAs ultimately fall into this complication (18).
2. Minor complications include persistent hip pain and poor mobility (18).

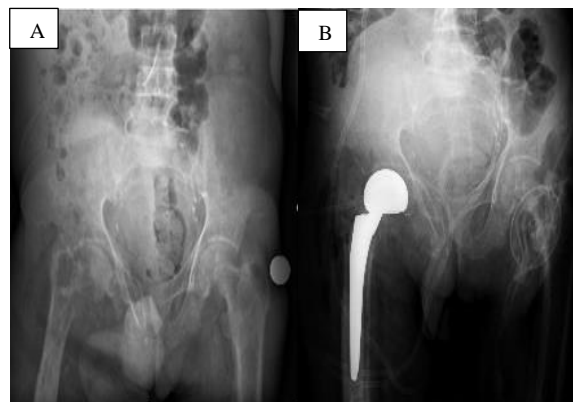The most important factor contributing to the complications after HA is the American Society of Anesthesiologists (ASA) score. It is a subjective grading system (I-V) of the preoperative physical health of the patients from a completely healthy fit (I) to a moribund patient not expected to survive without surgery (V) (19). Thus, in patients with a high ASA score, more complications are to be waited (7, 18). The risk of complications can be reduced potentially by improving postoperative care and the rehabilitation of patients. More systematic training of the surgeons in HA could further reduce the complication rate. The hospital stay duration showed no difference between THA and HA (6). The below algorithm provides a simplified approach to the use of HA in treating femoral neck fractures (Figure 3).



**Figure 3.** A simplified algorithm on when to choose hemiarthroplasty (HA) in the treatment of femoral neck fractures

If the patient has diminished cognition, HA is indicated. Otherwise, we consider the life expectancy and ambulation of the patient. If he is ambulatory and has a life expectancy more than four years (20), THA is indicated. Otherwise, HA will be our choice.

Figure 4 shows a case of femoral neck fracture in a 65-year-old man with severe osteoporosis and ESRD who came to our clinic. As the fracture was displaced and the patient was over 60 years old, the treatment of choice would be arthroplasty according to the criteria mentioned above. Due to the presence of comorbidities, we performed cemented HA.



**Figure 4.** Preoperative (A) and postoperative (B) radiographs of a 65-year-old patient with right femoral neck fracture who had end-stage renal disease (ESRD) and severe osteoporosis

**Which Prosthesis is Better in HA, BH or UH?**

There are three recent meta-analyses and one cohort study that compare these two types of prosthesis. A unipolar prosthesis consists of a single endoprosthetic head, whereas a bipolar prosthesis has both a bipolar endoprosthetic head and an internal metal bearing. The most important disadvantage of UH is the enhanced rate of acetabular wear associated with it in the short-term follow-up (less than one year). Theoretically, BH has three advantages due to a mobile bearing concept: 1) lower rate of acetabular wear, 2) increased hip range of motion (ROM) and improved Harris Hip score (HHS), and 3) lower rate of dislocation (21, 22). It is essential to know that the function of a bipolar prosthesis changes to unipolar function after approximately one year (12).

However, despite the enhanced rate of acetabular wear following UH, no significant difference was found between these two prostheses in terms of the surgical and functional outcomes, complications, and acetabular wear in the long-term (up to four years) (23). Furthermore, the bipolar prosthesis is more expensive (7). Thus, these two types of prostheses are equal according to recent data and more studies with longer follow-up durations are perhaps needed for better decision-making.

**Cemented or Cementless HA, Which One is Better?**

Supporting literature can be found in favor of both methods. Each method has unique advantages and disadvantages. In theory, cementing is associated with a better fixation, less postoperative thigh pain, and lower revision rate, but the most important issues associated with its use are cardiopulmonary fat embolism, cement hypersensitivity reaction, and difficult revision procedure. The uncemented technique has the advantages of shorter operative time, less pressurization, less fat embolism, and cheaper and easier revision procedure (7).



According to three large meta-analysis studies and National Institute for Health and Care Excellence (NICE) guidelines, we can conclude that cemented HA would appear to be superior in general (24-27). It is because although the uncemented technique confers a shorter operative time, cementing has the advantages of a lower rate of femoral fracture, less postoperative thigh pain, and better mobility. Moreover, there is no difference between the two methods in terms of blood loss, complications, and mortality rates (7). However, we noted that all of the studies suffer from lack of standardization in stems, small group of patients, and selection bias (4). In our institute, we choose cemented technique in case of a(n):

1. Dorr type C classification
2. Mismatch between the proximal and distal segments
3. Osteoporosis fracture

#### **Which Approach Is Preferred for HA?**

There are three possible surgical approaches for HA:

4. Lateral approach (LA)
5. Direct anterior approach (DAA)
6. Posterior approach (PA)

Each approach has a unique technique, advantages, and disadvantages. Two large meta-analytic studies compared the outcomes of HA between different approaches. According to their results, PA is associated with a higher rate of dislocation and reoperation than LA and anterior approach (AA). Nevertheless, there is no difference between AA and LA concerning the rate of dislocation and reoperation (28, 29). Based on available data, none of these approaches could be recommended as a preferred approach and more comparative studies are required for better decision-making.

#### **Which Patients Should Undergo THA?**

Numerous studies have shown that functional outcomes, walking distance, and pain scores are better in patients treated by THA. THA is more cost-effective than HA in the long term, thanks to its low revision rate. However, it has some disadvantages, such as longer operative time, more blood loss, and is more technically demanding.

THA is a better choice than HA in many respects (7). THA is associated with a lower rate of acetabular erosion and reoperation after four years. It is preferred in cases of a neglected femoral neck fracture. HHS has also been found to be higher in those undergoing THA compared to those undergoing HA (6, 7, 18).

Regarding the complications, there is a higher dislocation risk following THA compared to HA, but there is no difference between both techniques in terms of postoperative infection and other complications. This higher risk for dislocation must be well noted in the selection of the appropriate technique in patients who might be at high risk for dislocation. Although HA is a rapid and greatly standardized technique that permits for early weight-bearing and recovery, it is linked to a higher risk of reoperation and lower HHS compared with THA. Moreover, a trend for higher risk of mortality at one year exists in patients treated by HA. Hence, HA is inferior to THA in treating femoral neck fractures, and THA has a more significant role in the treatment of this group of patients than it had in the past (4).

#### **Ultimate Protocol**

In patients with a femoral neck fracture, if the patient has the criteria for internal fixation according to the QSS score and the criteria mentioned above, internal fixation is recommended. Otherwise, arthroplasty is the favored treatment. The preferred technique in arthroplasty is THA unless the patient has the aforementioned criteria for HA (4).

#### **Conflict of Interest**

The authors declare no conflict of interest in this study.

#### **Acknowledgments**

None.

#### **References**

1. Dijkman B, Kooistra B, Ferguson T, Bhandari M. Decision making: Open reduction/internal fixation versus arthroplasty for femoral neck fractures. *Tech Orthop*. 2008;23(4):288-95. doi: [10.1097/BTO.0b013e318196fb53](https://doi.org/10.1097/BTO.0b013e318196fb53).
2. Hayat Z, Varacallo M. Surgical management of femoral neck fractures. StatPearls [Internet]. Treasure Island (FL): StatPearls Publishing 2020. [PubMed: [30855824](https://pubmed.ncbi.nlm.nih.gov/30855824/)].
3. Smith-Petersen MN, CAVE EF, VANGORDER GW. Intracapsular fractures of the neck of the femur: treatment by internal fixation. *Arch Surg*. 1931;23(5):715-59. doi: [10.1001/archsurg.1931.01160110002001](https://doi.org/10.1001/archsurg.1931.01160110002001)
4. Bhandari M, Devereaux PJ, Swiontkowski MF, Tornetta P 3<sup>rd</sup>, Obremskey W, Koval KJ, et al. Internal fixation compared with arthroplasty for displaced fractures of the femoral neck. A meta-analysis. *J Bone Joint Surg Am*. 2003;85(9):1673-81. doi: [10.2106/00004623-200309000-00004](https://doi.org/10.2106/00004623-200309000-00004). [PubMed: [12954824](https://pubmed.ncbi.nlm.nih.gov/12954824/)].
5. Bhandari M, Devereaux PJ, Tornetta P 3<sup>rd</sup>, Swiontkowski MF, Berry DJ, Haidukewych G, et al. Operative management of displaced femoral neck fractures in elderly patients. An international survey. *J Bone Joint Surg Am*. 2005;87(9):2122-30. doi: [10.2106/JBJS.E.00535](https://doi.org/10.2106/JBJS.E.00535). [PubMed: [16140828](https://pubmed.ncbi.nlm.nih.gov/16140828/)].
6. Florschutz AV, Langford JR, Haidukewych GJ, Koval KJ. Femoral neck fractures: Current management. *J Orthop Trauma*. 2015;29(3):121-9. doi: [10.1097/BOT.0000000000000291](https://doi.org/10.1097/BOT.0000000000000291). [PubMed: [25635363](https://pubmed.ncbi.nlm.nih.gov/25635363/)].
7. Zielinski SM, Meeuwis MA, Heetveld MJ, Verhofstad MH, Roukema GR, Patka P, et al. Adherence to a femoral neck fracture treatment guideline. *Int Orthop*. 2013;37(7):1327-34. doi: [10.1007/s00264-013-1888-3](https://doi.org/10.1007/s00264-013-1888-3). [PubMed: [23595233](https://pubmed.ncbi.nlm.nih.gov/23595233/)]. [PubMed Central: [PMC3685653](https://pubmed.ncbi.nlm.nih.gov/PMC3685653/)].
8. Mathews V, Cabanela ME. Femoral neck nonunion treatment. *Clin Orthop Relat Res*. 2004;(419):57-64. doi: [10.1097/00003086-200402000-00010](https://doi.org/10.1097/00003086-200402000-00010). [PubMed: [15021132](https://pubmed.ncbi.nlm.nih.gov/15021132/)].
9. Raaymakers EL, Marti RK. Nonunion of the femoral neck: Possibilities and limitations of the various treatment modalities. *Indian J Orthop*. 2008;42(1):13-21. doi: [10.4103/0019-5413.38575](https://doi.org/10.4103/0019-5413.38575). [PubMed: [19823649](https://pubmed.ncbi.nlm.nih.gov/19823649/)]. [PubMed Central: [PMC2759582](https://pubmed.ncbi.nlm.nih.gov/PMC2759582/)].
10. Bhandari M, Tornetta P, III, Hanson B, Swiontkowski MF. Optimal internal fixation for femoral neck fractures: Multiple screws or sliding hip screws? *J Orthop Trauma*. 2009;23(6):403-7. doi: [10.1097/BOT.0b013e318176191f](https://doi.org/10.1097/BOT.0b013e318176191f). [PubMed: [19550225](https://pubmed.ncbi.nlm.nih.gov/19550225/)].
11. Shen M, Wang C, Chen H, Rui YF, Zhao S. An update on the Pauwels classification. *J Orthop Surg Res*. 2016;11(1):161. doi: [10.1186/s13018-016-0498-3](https://doi.org/10.1186/s13018-016-0498-3). [PubMed: [27955672](https://pubmed.ncbi.nlm.nih.gov/27955672/)]. [PubMed Central: [PMC5154085](https://pubmed.ncbi.nlm.nih.gov/PMC5154085/)].
12. Bray TJ. Femoral neck fracture fixation. Clinical decision making. *Clin Orthop Relat Res*. 1997;(339):20-31. doi: [10.1097/00003086-199706000-00004](https://doi.org/10.1097/00003086-199706000-00004). [PubMed: [9186197](https://pubmed.ncbi.nlm.nih.gov/9186197/)].
13. Keating JF, Grant A, Masson M, Scott NW, Forbes JF. Randomized comparison of reduction and fixation, bipolar hemiarthroplasty, and total hip arthroplasty. Treatment of displaced intracapsular hip fractures in healthy older patients. *J Bone Joint Surg Am*. 2006;88(2):249-60. doi: [10.2106/JBJS.E.00215](https://doi.org/10.2106/JBJS.E.00215). [PubMed: [16452734](https://pubmed.ncbi.nlm.nih.gov/16452734/)].
14. Leonard M, Alao U, Glynn A, Dolan M. Hip fractures: Failure of fixation and outcome of salvage arthroplasty. *Eur J Orthop*

- Surg Traumatol.* 2009;19(8):553-8.
15. Liu YJ, Xu B, Li ZY, Zhang Q, Zhang YZ. Quantitative score system for the surgical decision on adult femoral neck fractures. *Orthopedics.* 2012;35(2):e137-e143. doi: [10.3928/01477447-20120123-09](https://doi.org/10.3928/01477447-20120123-09). [PubMed: [22310396](https://pubmed.ncbi.nlm.nih.gov/22310396/)].
  16. Dilogo IH, Djaja YP. Hemi or Total Hip Arthroplasty in Hip Fractures: What is the Contemporary Recommendations? Real Scenario and How I Select My Patients. In: Tanavalee A, Mow CS, Abbas AA, Azores GMS, Budhiparama NC, Lo NN, Editors. *Comprehensive Hip and Knee Textbook.* 1<sup>st</sup> ed. Bangkok, Thailand: Holistic Publishing; 2013. p. 268-83.
  17. Fan L, Dang X, Wang K. Comparison between bipolar hemiarthroplasty and total hip arthroplasty for unstable intertrochanteric fractures in elderly osteoporotic patients. *PLoS One.* 2012;7(6):e39531. doi: [10.1371/journal.pone.0039531](https://doi.org/10.1371/journal.pone.0039531). [PubMed: [22745778](https://pubmed.ncbi.nlm.nih.gov/22745778/)]. [PubMed Central: [PMC3382155](https://pubmed.ncbi.nlm.nih.gov/PMC3382155/)].
  18. Burgers PT, Van Geene AR, Van den Bekerom MP, Van Lieshout EM, Blom B, Aleem IS, et al. Total hip arthroplasty versus hemiarthroplasty for displaced femoral neck fractures in the healthy elderly: A meta-analysis and systematic review of randomized trials. *Int Orthop.* 2012;36(8):1549-60. doi: [10.1007/s00264-012-1569-7](https://doi.org/10.1007/s00264-012-1569-7). [PubMed: [22623062](https://pubmed.ncbi.nlm.nih.gov/22623062/)]. [PubMed Central: [PMC3535035](https://pubmed.ncbi.nlm.nih.gov/PMC3535035/)].
  19. Daabiss M. American society of anaesthesiologists physical status classification. *Indian J Anaesth.* 2011;55(2):111-5. doi: [10.4103/0019-5049.79879](https://doi.org/10.4103/0019-5049.79879). [PubMed: [21712864](https://pubmed.ncbi.nlm.nih.gov/21712864/)]. [PubMed Central: [PMC3106380](https://pubmed.ncbi.nlm.nih.gov/PMC3106380/)].
  20. Ossendorf C, Scheyerer MJ, Wanner GA, Simmen HP, Werner CM. Treatment of femoral neck fractures in elderly patients over 60 years of age-which is the ideal modality of primary joint replacement? *Patient Saf Surg.* 2010;4(1):16. doi: [10.1186/1754-9493-4-16](https://doi.org/10.1186/1754-9493-4-16). [PubMed: [20961437](https://pubmed.ncbi.nlm.nih.gov/20961437/)]. [PubMed Central: [PMC2972258](https://pubmed.ncbi.nlm.nih.gov/PMC2972258/)].
  21. Yang B, Lin X, Yin XM, Wen XZ. Bipolar versus unipolar hemiarthroplasty for displaced femoral neck fractures in the elder patient: A systematic review and meta-analysis of randomized trials. *Eur J Orthop Surg Traumatol.* 2015;25(3): 425-33. doi: [10.1007/s00590-014-1565-2](https://doi.org/10.1007/s00590-014-1565-2). [PubMed: [25476243](https://pubmed.ncbi.nlm.nih.gov/25476243/)].
  22. Jia Z, Ding F, Wu Y, Li W, Li H, Wang D, et al. Unipolar versus bipolar hemiarthroplasty for displaced femoral neck fractures: A systematic review and meta-analysis of randomized controlled trials. *J Orthop Surg Res.* 2015;10:8. doi: [10.1186/s13018-015-0165-0](https://doi.org/10.1186/s13018-015-0165-0). [PubMed: [25616914](https://pubmed.ncbi.nlm.nih.gov/25616914/)]. [PubMed Central: [PMC4334611](https://pubmed.ncbi.nlm.nih.gov/PMC4334611/)].
  23. Robertson GA, Wood AM. Hip hemi-arthroplasty for neck of femur fracture: What is the current evidence? *World J Orthop.* 2018;9(11):235-44. doi: [10.5312/wjo.v9.i11.235](https://doi.org/10.5312/wjo.v9.i11.235). [PubMed: [30479970](https://pubmed.ncbi.nlm.nih.gov/30479970/)]. [PubMed Central: [PMC6242732](https://pubmed.ncbi.nlm.nih.gov/PMC6242732/)].
  24. Veldman HD, Heyligers IC, Grimm B, Boymans TA. Cemented versus cementless hemiarthroplasty for a displaced fracture of the femoral neck: A systematic review and meta-analysis of current generation hip stems. *Bone Joint J.* 2017;99-B(4):421-31. doi: [10.1302/0301-620X.99B4.BJJ-2016-0758.R1](https://doi.org/10.1302/0301-620X.99B4.BJJ-2016-0758.R1). [PubMed: [28385929](https://pubmed.ncbi.nlm.nih.gov/28385929/)].
  25. Luo X, He S, Li Z, Huang D. Systematic review of cemented versus uncemented hemiarthroplasty for displaced femoral neck fractures in older patients. *Arch Orthop Trauma Surg.* 2012;132(4):455-63. doi: [10.1007/s00402-011-1436-9](https://doi.org/10.1007/s00402-011-1436-9). [PubMed: [22160512](https://pubmed.ncbi.nlm.nih.gov/22160512/)].
  26. Grosso MG, Danoff JR, Padgett DE, Iorio R, Macaulay WB. The cemented unipolar prosthesis for the management of displaced femoral neck fractures in the dependent osteopenic elderly. *J Arthroplasty.* 2016;31(5):1040-6. doi: [10.1016/j.arth.2015.11.029](https://doi.org/10.1016/j.arth.2015.11.029). [PubMed: [26742902](https://pubmed.ncbi.nlm.nih.gov/26742902/)].
  27. National Institute for Health and Care Excellence. Evidence review and recommendations-Displaced intracapsular hip fracture. In: National Institute for Health and Care Excellence, Editor. Addendum to Clinical Guideline 124, Hip fracture: Management. London, UK: National Institute for Health and Care Excellence; 2017.
  28. van der Sijp MPL, van Delft D, Krijnen P, Niggebrugge AHP, Schipper IB. Surgical approaches and hemiarthroplasty outcomes for femoral neck fractures: A meta-analysis. *J Arthroplasty.* 2018;33(5):1617-27. doi: [10.1016/j.arth.2017.12.029](https://doi.org/10.1016/j.arth.2017.12.029). [PubMed: [29398259](https://pubmed.ncbi.nlm.nih.gov/29398259/)].
  29. Kunkel ST, Sabatino MJ, Kang R, Jevsevar DS, Moschetti WE. A systematic review and meta-analysis of the direct anterior approach for hemiarthroplasty for femoral neck fracture. *Eur J Orthop Surg Traumatol.* 2018;28(2):217-32 doi: [10.1007/s00590-017-2033-6](https://doi.org/10.1007/s00590-017-2033-6). [PubMed: [28852880](https://pubmed.ncbi.nlm.nih.gov/28852880/)].