

# A Comparison of Bipolar Hemiarthroplasty versus Dynamic Hip Screw Fixation of Basicervical Femoral Neck Fractures

Ali Mousapour<sup>1</sup>, Keykhosro Mardanpour<sup>2</sup>, Adel Hojabrian<sup>3</sup>, Morteza Saeb<sup>2</sup>, Seyyed Saeed Khabiri<sup>1</sup>, Roya Safari-Faramani<sup>4</sup>, Monireh Yaghoobi<sup>3,\*</sup>, Sepehr Rahimpour<sup>3</sup>, Alireza Shafiee<sup>3</sup>

<sup>1</sup> Assistant Professor, Department of Orthopedic Surgery, School of Medicine, Kermanshah University of Medical Sciences, Kermanshah, Iran

<sup>2</sup> Associate Professor, Department of Orthopedic Surgery, School of Medicine, Kermanshah University of Medical Sciences, Kermanshah, Iran

<sup>3</sup> Senior Resident, Department of Orthopedic Surgery, School of Medicine, Kermanshah University of Medical Sciences, Kermanshah, Iran

<sup>4</sup> Department of Epidemiology, Research Center for Environmental Determinants of Health, School of Public Health, Kermanshah University of Medical Sciences, Kermanshah, Iran

\*Corresponding author: Monireh Yaghoobi; Department of Orthopedic Surgery, School of Medicine, Kermanshah University of Medical Sciences, Kermanshah, Iran. Tel: +98-9182591007, Email: monireh.yaghoobi@kums.ac.ir

Received: 16 October 2018; Revised: 13 December 2018; Accepted: 05 February 2019

## Abstract

**Background:** Surgical treatment of basicervical femoral neck fractures, which are biomechanically similar to intertrochanteric fractures, is an internal fixation by dynamic hip screw (DHS) and anti-rotation screw. Since one of the remarkable complications of this surgical procedure is device failure, we aimed to make a comparison between bipolar hemiarthroplasty and the DHS plate fixation in elderly patients with basicervical femoral neck fracture.

**Methods:** In this randomized controlled clinical trial study, 60 patients with femoral neck fractures were randomly divided into two groups of DHS fixation (control group, n = 30) and bipolar hemiarthroplasty (intervention group, n = 30). Harris Hip Score (HHS) questionnaire and the Visual Analogue Scale (VAS) for pain assessment were used for functional evaluations. Postoperative complications were evaluated at 6 months and one year postoperatively.

**Results:** The mean age was  $73.95 \pm 9.85$  years in the hemiarthroplasty group and  $74.22 \pm 7.85$  years in the internal fixation group. Three patients in the internal fixation group and 6 patients in the hemiarthroplasty group were excluded. HHS in 6 months and one year after surgery in the intervention group was dramatically higher than the control group. There were no noticeable changes in VAS scores between the two groups. Two cases of device failure happened in the control group.

**Conclusions:** It seems that bipolar hemiarthroplasty is more effective than internal fixation by DHS plate in improving the patient's quality of life, considering higher HHS scores, earlier patient mobilization, shorter hospital stay, lower device failure rate, and lower revision rate.

**Keywords:** Femoral Neck Fractures; Hemiarthroplasty; Fracture Fixation

**Citation:** Mousapour A, Mardanpour K, Hojabrian A, Saeb M, Khabiri SS, Safari-Faramani R, et al. **A Comparison of Bipolar Hemiarthroplasty versus Dynamic Hip Screw Fixation of Basicervical Femoral Neck Fractures.** *J Orthop Spine Trauma* 2019; 5(1): 25-8.



## Background

Peritrochanteric fracture in the elderly is one of the common fall injuries. The incidence is increasing due to a higher life expectancy and the aging of societies. Almost half of the patients with fractures of the hip area develop permanent impairment of motor function. Also, a 10%-20% mortality rate has been reported in one-year follow-up studies (1-4).

Anatomically, the basicervical fractures (fractures of the base of the femoral neck, in the interface between the femoral neck and intertrochanteric area) have an intermediate nature that causes disturbance of both areas. Thus, the treatment of choice is the internal fixation with dynamic hip screw (DHS) together with an anti-rotation screw (5, 6). The fracture instability is originated from the narrow cortical base of the proximal fragment that results in an arrow contact between the cortex and the main fragment. Because of the fracture angle and higher varus forces, the chance of collapse and device failure in these fractures is higher than the stable intertrochanteric fractures (6-9). On the other hand, low bone density and poor bone mechanical quality in these patients reduce the chance of proper screw purchase in the femoral head. This factor can increase the chance of device failure.

Since the old age and patient comorbidities increase the complications related to the revision surgery, choosing a

proper therapeutic method is crucial (1, 10). In the present study, we planned to compare bipolar hemiarthroplasty versus fracture reduction and fixation using DHS in aged patients suffering from basicervical fractures.

## Methods

The present study was a parallel randomized controlled clinical trial (IRCT20180904040953N1). The study population consisted of patients suffering from basicervical fractures, hospitalized in Taleghani Hospital, Kermanshah, Iran. The convenience sampling method was used and the participants were selected from the eligible patients. Written informed consent was obtained from all patients before entering the study, based on the protocol approved by Kermanshah University of Medical Sciences, Kermanshah (number: IR.KUMS.REC.1398.956).

The inclusion criteria were age more than 60 years, basicervical fracture, and previous walking ability without assistance. The exclusion criteria included the patients who did not consent to participate in the study, the existence of pathological or bilateral fractures, and hip joint osteoarthritis (OA). The patients were divided into two groups: bipolar hemiarthroplasty (intervention group) and fixation using DHS (control group). Figure 1 shows the CONSORT flow diagram for the study progress (11).

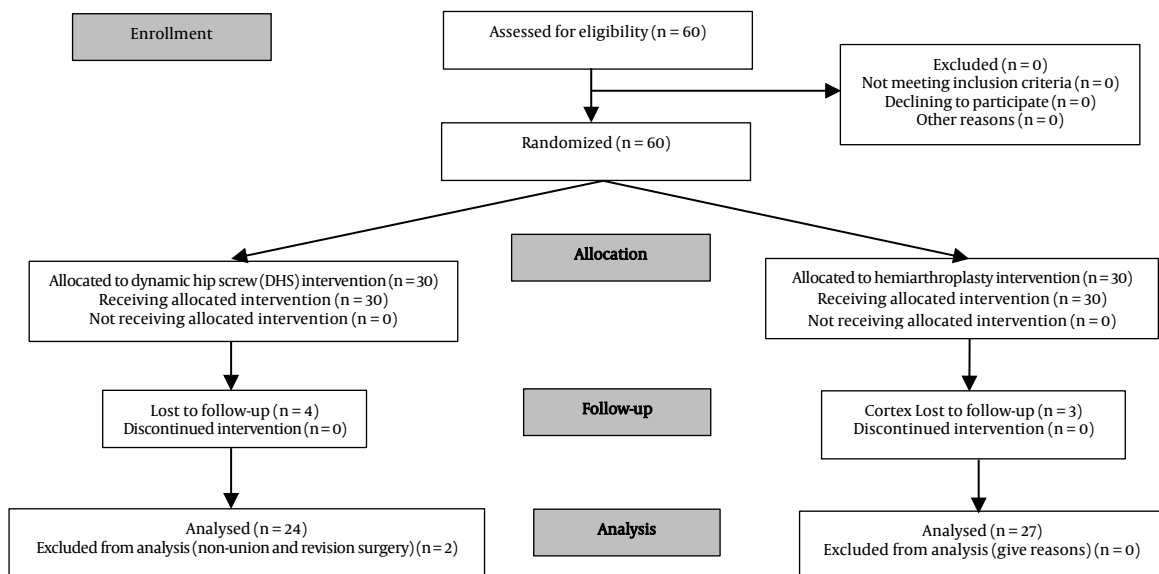


Figure 1. The CONSORT flow diagram

A questionnaire was used for information collection, including the demographic factors such as age, gender, union in the post-operative radiography, underlying diseases, and tobacco use. The Harris Hip Score (HHS) questionnaire was used for function evaluation and the Visual Analogue Scale (VAS) for patient pain severity evaluation. The incidence of postoperative complications including re-fracture, infection, revision surgery requirement, prosthesis dislocation, nonunion, nerve injury and deep vein thrombosis (DVT), as well as the mortality rates were recorded. The patients had follow-up visits in 6 months and one year after the surgery, and the questionnaires were filled at those time points.

Data analysis was performed using the Stata software (version 14.2, Stata Corporation, College Station, TX, USA). The frequency distribution tables (in forms of absolute and percentage frequencies) and the numerical indices such as the mean and standard deviation (SD) were used for data description. The Mann-Whitney U test was applied to make a comparison between two groups and the  $\chi^2$  test was used for comparison among the means of the non-parametric variables, pre- and post-operation. Any difference with  $P < 0.05$  was considered as significant.

**Results**

This study was performed on 60 patients (30 in each group). The average age of patients was  $73.95 \pm 9.85$  years and  $74.22 \pm 7.85$  years in the control and intervention groups, respectively ( $P = 0.4956$ ). There were no significant changes in terms of basic characteristics such as gender distribution ( $P = 0.7470$ ), smoking status ( $P = 0.6270$ ), and diabetes ( $P = 0.5490$ ) between the hemiarthroplasty and internal fixation groups (Table 1).

**Table 1.** The frequencies of the study participants in terms of age, smoking condition, and diabetes condition in the control and intervention groups

Variable	Control	Intervention	$\chi^2$	Pvalue	
<b>Gender</b>	Female	10	12	0.10	0.7500
	Male	14	15		
<b>Smoking</b>	Nonsmoker	19	19	0.59	0.4400
	Smoker	5	8		
<b>Diabetes</b>	Non-diabetic	16	17	0.11	0.7400
	Diabetic	8	10		

The Shapiro-Wilk W-test ( $< 0.05$ ) showed that the study population was not normally distributed, so the data analysis was performed using the non-parametric Mann-Whitney U test. Comparing the means of HHS scores in 6-month and one-year follow-ups depicted a considerable difference between the two groups ( $P = 0.0003$  for 6 months,  $P = 0.0097$  for 1 year) (Figure 2 and Table 2), while no significant differences were found in VAS scores ( $P = 0.4557$ ) (Figure 3 and Table 2).

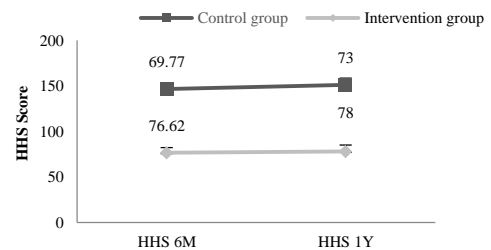


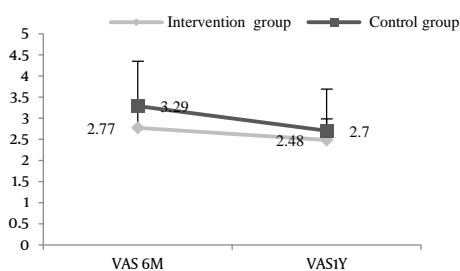
Figure 2. Comparison between the mean Harris Hip Score (HHS) scores in the control and intervention groups in 6 months and one year after surgery

No complications of prosthesis dislocation in the intervention group and nerve injury in both groups were reported. Two non-union cases with device failure were reported in a 6-month follow-up in the control group. These cases were treated with bipolar hemiarthroplasty and were not introduced into the final analysis. Four patients in the Hemiarthroplasty and three in the internal fixation group expired within the follow-up period and were excluded from the study.

**Table 2.** The Mann-Whitney U test for Harris Hip Score (HHS) and Visual Analogue Scale (VAS) scores in 6 months and one year after surgery in the control and intervention groups

Variable		6 months after surgery	Pvalue	1 year after surgery	Pvalue
<b>HHS</b>	Control	69.77 ± 7.21	0.0003	73.00 ± 7.52	0.0097
	Intervention	76.62 ± 5.70		78.00 ± 4.93	
<b>VAS</b>	Control	3.29 ± 1.06	0.4557	2.70 ± 0.99	0.4578
	Intervention	2.77 ± 1.12		2.48 ± 1.05	

Data are presented as mean ± standard deviation (SD)  
HHS: Harris Hip Score; VAS: Visual Analogue Scale



**Figure 3.** Comparison between the mean Visual Analogue Scale (VAS) scores in 6 months and one year after surgery in the control and intervention groups

There were no considerable changes between the two groups in terms of mortality ( $P = 0.6880$ ). One case of surgical site infection was observed in the intervention group which was superficial and resolved by oral antibiotics. No infection cases were observed in the hemiarthroplasty group. One case of cerclage wiring due to fracture during the surgery was reported in the internal fixation by the DHS group while no re-fracture cases were observed in the control group.

## Discussion

The goal of treatment in peritrochanteric fractures is early mobilization and rehabilitation to avoid the high morbidity (from 4% to 50%) and mortality rate due to complications like decubitus ulcers, pneumonia, atelectasis, and malunion (12, 13). Although the internal fixation treatment is effective, the pre-existing osteoporosis, comminution, and excessive slide can result in a severe collapse of the fracture site, excessive shaft medialization, and subsequent introduction of the lag screw into the joint. This chain of events can cause limited mobility in patients. Also, patient mobilization and limb loading are usually delayed until the complete union (14). Therefore, researchers are looking for other therapeutic modalities with lower failure rates and lower need for revision surgery, in addition to functional improvement (9, 12).

In the present study, the device failure rate was reported to be 7.6% which is lower than the previous studies (15-17). In the studies by Sinno et al., (15) Emami et al., (19) and Thakkar et al., (20) the result of the HHS assessment after bipolar hemiarthroplasty was better than the internal fixation, in all follow-up time points. This finding was compatible with our study, in which the HHS in both 6-month and one-year follow-ups was significantly better in the bipolar hemiarthroplasty group.

The previous studies declared that the patients who went through bipolar hemiarthroplasty had a distinctly better condition than the internal fixation group, considering the factors such as length of operation, blood loss during operation, blood transfusion need, and length of hospitalization (15, 22). As a limitation, we were not able to investigate these factors in the current study.

One of the most serious complications associated with the surgeries of hip fractures is a deep infection, being reported as high as 3%. The factors such as a large incision and excessive dissection can increase the chance of infection (23). In our study, one case of superficial infection was observed in the bipolar hemiarthroplasty group, who was treated with oral antibiotics with no need for further surgical interventions.

Another important complication of arthroplasty is prosthesis dislocation. It can be caused by various factors

including weakness of abductor's muscles, technical errors during surgery, inadequate soft tissue tension, and small size of the femoral head (24). In the studies by Rodop et al. (18) and Thakkar et al., (20) no cases of prosthesis dislocation or loosening were reported, which was in accordance with our results.

Patient pain severity was evaluated using VAS in 6 months and one year after surgery. Similar to previous studies, no significant differences were observed between the two groups (19). In the studies by Rodop et al. (18) and Thakkar et al., (20) 7 and 11 patients expired, respectively. In our study, 7 patients (4 in the internal fixation group and 3 in the hemiarthroplasty group) expired with no remarkable statistical changes in two groups. In general, various studies showed different results in mortality rate, some reporting a lower mortality rate in addition to better functional results in the arthroplasty group (22), and others reporting the opposite (25). These differences may be due to the extended surgery length or patient mobilization delay.

## Conclusion

Considering higher HHS scores, earlier patient mobilization, shorter hospital stay, lower device failure rate, and lower revision rate, it seems that the bipolar hemiarthroplasty surgery has better functional results compared to the internal fixation using DHS.

## Conflict of Interest

The authors declare no conflict of interest in this study.

## Acknowledgments

The authors would like to thank the Clinical Research Development Center of Taleghani and Imam Ali Hospitals, Kermanshah University of Medical Sciences, for the support, cooperation, and assistance throughout the period of this study. We also express our special thanks and appreciation to all the orthopedic residents of Kermanshah University of Medical Sciences who helped us with this information. This study has been derived from a PhD dissertation (No. 98.984) approved by Kermanshah University of Medical Sciences.

## References

- Sendtner E, Renkawitz T, Kramny P, Wenzl M, Grifka J. Fractured neck of femur-internal fixation versus arthroplasty. *Dtsch Arztebl Int.* 2010;107(23):401-7. doi: [10.3238/arztebl.2010.0401](https://doi.org/10.3238/arztebl.2010.0401). [PubMed: [20589205](https://pubmed.ncbi.nlm.nih.gov/20589205/)]. [PubMed Central: [PMC2893522](https://pubmed.ncbi.nlm.nih.gov/PMC2893522/)].
- Gao H, Liu Z, Xing D, Gong M. Which is the best alternative for displaced femoral neck fractures in the elderly?: A meta-analysis. *Clin Orthop Relat Res.* 2012;470(6):1782-91. doi: [10.1007/s11999-012-2250-6](https://doi.org/10.1007/s11999-012-2250-6). [PubMed: [22278852](https://pubmed.ncbi.nlm.nih.gov/22278852/)]. [PubMed Central: [PMC3348330](https://pubmed.ncbi.nlm.nih.gov/PMC3348330/)].
- Parker MJ, Gurusamy K. Internal fixation versus arthroplasty for intracapsular proximal femoral fractures in adults. *Cochrane Database Syst Rev.* 2006;(4):CD001708. doi: [10.1002/14651858.CD001708.pub2](https://doi.org/10.1002/14651858.CD001708.pub2). [PubMed: [17054139](https://pubmed.ncbi.nlm.nih.gov/17054139/)].
- Ravikumar KJ, Marsh G. Internal fixation versus hemiarthroplasty versus total hip arthroplasty for displaced subcapital fractures of femur-13 year results of a prospective randomised study. *Injury.* 2000;31(10):793-7. doi: [10.1016/S0020-1383\(00\)00125-X](https://doi.org/10.1016/S0020-1383(00)00125-X). [PubMed: [11154750](https://pubmed.ncbi.nlm.nih.gov/11154750/)].
- Xie H, Wang Z, Zhang J, Xu L, Chen B. Clinical outcome of dynamic hip locking plates and proximal femoral nails anti-

- rotation-Asia for treating intertrochanteric femur fracture with lateral wall fractures in the elder patients. *Oncotarget*. 2017;8(47):82700-4. doi: [10.18632/oncotarget.19754](https://doi.org/10.18632/oncotarget.19754). [PubMed: [29137295](https://pubmed.ncbi.nlm.nih.gov/29137295/)]. [PubMed Central: [PMC5669921](https://pubmed.ncbi.nlm.nih.gov/PMC5669921/)].
6. Azar FM, Canale ST, Beaty HJ. Campbell's operative orthopaedics. Philadelphia, PA: Elsevier Health Sciences; 2016.
  7. McLoughlin SW, Wheeler DL, Rider J, Bolhofner B. Biomechanical evaluation of the dynamic hip screw with two- and four-hole side plates. *J Orthop Trauma*. 2000;14(5):318-23. doi: [10.1097/00005131-200006000-00002](https://doi.org/10.1097/00005131-200006000-00002). [PubMed: [10926237](https://pubmed.ncbi.nlm.nih.gov/10926237/)].
  8. Bolhofner BR, Russo PR, Carmen B. Results of intertrochanteric femur fractures treated with a 135-degree sliding screw with a two-hole side plate. *J Orthop Trauma*. 1999;13(1):5-8. doi: [10.1097/00005131-199901000-00002](https://doi.org/10.1097/00005131-199901000-00002). [PubMed: [9892117](https://pubmed.ncbi.nlm.nih.gov/9892117/)].
  9. Su BW, Heyworth BE, Protopsaltis TS, Lipton CB, Sinicropi SM, Chapman CB, et al. Basicervical versus intertrochanteric fractures: An analysis of radiographic and functional outcomes. *Orthopedics*. 2006;29(10):919-25. doi: [10.3928/01477447-20061001-04](https://doi.org/10.3928/01477447-20061001-04). [PubMed: [17061418](https://pubmed.ncbi.nlm.nih.gov/17061418/)].
  10. Desjardins AL, Roy A, Paiement G, Newman N, Pedlow F, Desloges D, et al. Unstable intertrochanteric fracture of the femur. A prospective randomised study comparing anatomical reduction and medial displacement osteotomy. *J Bone Joint Surg Br*. 1993;75(3):445-7. [PubMed: [8496218](https://pubmed.ncbi.nlm.nih.gov/8496218/)].
  11. CONSORT Transparent Reporting of Trails. CONSORT 2010 Flow Diagram [Online]. [cited 2010]; Available from: URL: <http://www.consort-statement.org/download/Media/Default/Downloads/CONSORT%202010%20Flow%20Diagram.doc>
  12. Levy RN, Siegel M, Sedlin ED, Siffert RS. Complications of Ender-pin fixation in basicervical, intertrochanteric, and subtrochanteric fractures of the hip. *J Bone Joint Surg Am*. 1983;65(1):66-9. [PubMed: [6848537](https://pubmed.ncbi.nlm.nih.gov/6848537/)].
  13. Koval KJ, Cantu RV. Intertrochanteric fractures. In: Rockwood CA, Bucholz RW, Heckman JD, Court-Brown CM, Koval KJ, Tornetta P, et al., Editors. Rockwood and green's fractures in adults. Philadelphia, PA: Lippincott Williams & Wilkins; 2006. p. 1793-825.
  14. Bergman GD, Winqvist RA, Mayo KA, Hansen ST Jr. Subtrochanteric fracture of the femur. Fixation using the Zickel nail. *J Bone Joint Surg Am*. 1987;69(7):1032-40. [PubMed: [3654694](https://pubmed.ncbi.nlm.nih.gov/3654694/)].
  15. Sinno K, Sakr M, Girard J, Khatib H. The effectiveness of primary bipolar arthroplasty in treatment of unstable intertrochanteric fractures in elderly patients. *N Am J Med Sci*. 2010;2(12):561-8. doi: [10.4297/najms.2010.2561](https://doi.org/10.4297/najms.2010.2561). [PubMed: [22558568](https://pubmed.ncbi.nlm.nih.gov/22558568/)]. [PubMed Central: [PMC3338223](https://pubmed.ncbi.nlm.nih.gov/PMC3338223/)].
  16. Hassankhani EG, Omid-Kashani F, Hajitaghi H, Hassankhani GG. How to treat the complex unstable intertrochanteric fractures in elderly patients? DHS or Arthroplasty. *Arch Bone Jt Surg*. 2014;2(3):174-9. [PubMed: [25386578](https://pubmed.ncbi.nlm.nih.gov/25386578/)]. [PubMed Central: [PMC4225022](https://pubmed.ncbi.nlm.nih.gov/PMC4225022/)].
  17. Kayali C, Agus H, Ozluk S, Sanli C. Treatment for unstable intertrochanteric fractures in elderly patients: Internal fixation versus cone hemiarthroplasty. *J Orthop Surg (Hong Kong)*. 2006;14(3):240-4. doi: [10.1177/230949900601400302](https://doi.org/10.1177/230949900601400302). [PubMed: [17200522](https://pubmed.ncbi.nlm.nih.gov/17200522/)].
  18. Rodop O, Kiral A, Kaplan H, Akmaz I. Primary bipolar hemiprostheses for unstable intertrochanteric fractures. *Int Orthop*. 2002;26(4):233-7. doi: [10.1007/s00264-002-0358-0](https://doi.org/10.1007/s00264-002-0358-0). [PubMed: [12185526](https://pubmed.ncbi.nlm.nih.gov/12185526/)]. [PubMed Central: [PMC3620945](https://pubmed.ncbi.nlm.nih.gov/PMC3620945/)].
  19. Emami M, Manafi A, Hashemi B, Nemati A, Safari S. Comparison of intertrochanteric fracture fixation with dynamic hip screw and bipolar hemiarthroplasty techniques. *Arch Bone Jt Surg*. 2013;1(1):14-7. [PubMed: [25207277](https://pubmed.ncbi.nlm.nih.gov/25207277/)]. [PubMed Central: [PMC4151394](https://pubmed.ncbi.nlm.nih.gov/PMC4151394/)].
  20. Thakkar CJ, Thakkar S, Kathalgere RT, Kumar MN. Calcar femorale grafting in the hemiarthroplasty of the hip for unstable inter trochanteric fractures. *Indian J Orthop*. 2015;49(6):602-9. doi: [10.4103/0019-5413.168762](https://doi.org/10.4103/0019-5413.168762). [PubMed: [26806966](https://pubmed.ncbi.nlm.nih.gov/26806966/)]. [PubMed Central: [PMC4705725](https://pubmed.ncbi.nlm.nih.gov/PMC4705725/)].
  21. Singh S, Shrivastava C, Kumar S. Hemi replacement arthroplasty for unstable inter-trochanteric fractures of femur. *J Clin Diagn Res*. 2014;8(10):LC01-LC04. doi: [10.7860/JCDR/2014/10171.4972](https://doi.org/10.7860/JCDR/2014/10171.4972). [PubMed: [25478376](https://pubmed.ncbi.nlm.nih.gov/25478376/)]. [PubMed Central: [PMC4253194](https://pubmed.ncbi.nlm.nih.gov/PMC4253194/)].
  22. Broos PL, Rommens PM, Geens VR, Stappaerts KH. Per-trochanteric fractures in the elderly. Is the Belgian VDP prosthesis the best treatment for unstable fractures with severe comminution? *Acta Chir Belg*. 1991;91(5):242-9. [PubMed: [1950312](https://pubmed.ncbi.nlm.nih.gov/1950312/)].
  23. Weidmann E, Huggler AH. Hip prosthesis in per-trochanteric fractures. *Z Unfallmed Berufskr*. 1976;69(3-4):147-50. [PubMed: [1014921](https://pubmed.ncbi.nlm.nih.gov/1014921/)]. [In French].
  24. Woo RY, Morrey BF. Dislocations after total hip arthroplasty. *J Bone Joint Surg Am*. 1982;64(9):1295-306. [PubMed: [7142237](https://pubmed.ncbi.nlm.nih.gov/7142237/)].
  25. Kesmezacar H, Ogut T, Bilgili MG, Gokay S, Tenekcioglu Y. Treatment of intertrochanteric femur fractures in elderly patients: Internal fixation or hemiarthroplasty. *Acta Orthop Traumatol Turc*. 2005;39(4):287-94. [PubMed: [16269874](https://pubmed.ncbi.nlm.nih.gov/16269874/)].