

# Tranexamic Acid Effectiveness on the Amount of Bleeding during Surgery and Surgeon's Satisfaction in Intertrochanteric Fracture Fixation: A Randomized Clinical Trial

Morteza Saeb<sup>1</sup>, Ali Mousapour<sup>2</sup>, Alireza Shafiee<sup>3,\*</sup>, Seyyed Saeed Khabiri<sup>2</sup>, Roya Safari-Faramani<sup>4</sup>, Ali Gholami<sup>5</sup>, Keykhosro Mardanpour<sup>1</sup>, Monireh Yaghoubi<sup>3</sup>, Sepehr Rahimpour<sup>3</sup>, Adel Hojabrian<sup>3</sup>

<sup>1</sup> Associate Professor, Department of Orthopedic Surgery, School of Medicine, Kermanshah University of Medical Sciences, Kermanshah, Iran

<sup>2</sup> Assistant Professor, Department of Orthopedic Surgery, School of Medicine, Kermanshah University of Medical Sciences, Kermanshah, Iran

<sup>3</sup> Senior Resident, Department of Orthopedic Surgery, School of Medicine, Kermanshah University of Medical Sciences, Kermanshah, Iran

<sup>4</sup> Department of Epidemiology, Research Center for Environmental Determinants of Health, School of Public Health, Kermanshah University of Medical Sciences, Kermanshah, Iran

<sup>5</sup> Assistant Professor, Department of Anesthesiology, School of Medicine, Kermanshah University of Medical Sciences, Kermanshah, Iran

\*Corresponding author: Alireza Shafiee; Department of Orthopedic Surgery, School of Medicine, Kermanshah University of Medical Sciences, Kermanshah, Iran. Tel: +98-9183787039, Email: alireza.shafiee@kums.ac.ir

Received: 16 August 2018; Revised: 09 November 2018; Accepted: 27 December 2018

## Abstract

**Background:** The purpose of this study was to evaluate the effect of intravenous tranexamic acid (TXA) on the blood loss volume during surgery and surgeon's satisfaction in intertrochanteric fracture surgery.

**Methods:** A total of 62 patients with intertrochanteric fracture were involved in the study and accidentally categorized into two groups. In the control or first group, patients were medicated with placebo (age:  $69.2 \pm 6.1$  years old) and in the second group or intervention, they received 1 g injection of TXA (age:  $69.7 \pm 6.4$  years old). Intraoperative bleeding was measured by the amount of blood in the suction bottle and amount of gauze utilized and postoperative blood loss was measured by the amount of blood in the drain 48 hours after surgery. Also, hemoglobin (Hb) levels were compared before and after surgery. In the end, the surgeon's satisfaction was measured by Likert scale.

**Results:** The difference in the amount of intra-operative bleeding was significant between the groups ( $P < 0.050$ ). The mean number of utilized gauze in the intervention group was meaningfully less than the placebo group ( $P < 0.050$ ). The mean Hb in the control group was considerably inferior to the intervention group ( $P < 0.050$ ). The respect of patients in need of transfusion in the placebo group was outstandingly superior to the intervention group ( $P < 0.005$ ). Surgeon satisfaction in the intervention group was considerably greater than the control group ( $P < 0.050$ ).

**Conclusion:** The use of intravenous TXA during intertrochanteric fracture surgery can reduce hemorrhage during surgery, reduce the need for blood products, and finally improve the surgeon's satisfaction.

**Keywords:** Tranexamic Acid; Hip Fractures; Surgical Blood Loss; Randomized Controlled Trial

**Citation:** Saeb M, Mousapour A, Shafiee A, Khabiri SS, Safari-Faramani R, Gholami A, et al. **Tranexamic Acid Effectiveness on the Amount of Bleeding during Surgery and Surgeon's Satisfaction in Intertrochanteric Fracture Fixation: A Randomized Clinical Trial.** *J Orthop Spine Trauma* 2019; 5(1): 17-20.



## Background

Intertrochanteric fracture is one of the most prevalent orthopedic emergencies and the most common type of hip fracture, which is expected to affect 4.5 million people worldwide in 2050 (1). Treatment of these fractures (except those with medical contraindications) is the internal fixation with extensive approaches. The tendency for bleeding during and after surgery is considered as a common and inevitable problem among anesthesiologists and surgeons (2, 3). In addition to hypnosis, anesthesia aims to create a combination of analgesia, forgetfulness, and immobility in patients; therefore, it can provide a suitable environment for the surgeon to have adequate vision, reduce the operative time and in the end, reduce the risk of damage to internal and vital organs (4, 5). Intraoperative hemorrhage reduces the surgeon's vision and increases repeated use of suction, so it results in further manipulation of the operation site, increases the risk of bleeding in the surgical site, and prolongs the operation time (6, 7). Hence, various ways have been proposed to control bleeding and improve the quality of the surgical site, including the use of just intravenous

anesthesia (8), the position of the head above the heart and the use of vasoconstrictor drugs (9), and creation of controlled hypotension (10). Each of the above-mentioned methods has not yet been approved as a selective approach and should be chosen based on the patient's condition, the degree of utilitarianism, and potential side effect considerations (8). One of these interventions is the use of tranexamic acid (TXA), an antifibrinolytic drug that has the potential to stabilize the blood clot formation and thus prevent bleeding (11). Contrary to the abundant clinical trials in this field, the routine utilizing of TXA in orthopedic surgeries as a low-risk procedure to decline the blood loss remains to be discussed (12). Hence, the researchers aim to evaluate the intravenous TXA effectiveness on the hemorrhage volume in intertrochanteric fracture surgery.

## Methods

This parallel randomized clinical trial (RCT) study was done on patients who referred to Taleghani Hospital (a referral trauma hospital located in the western part of Iran that presents clinical services to three provinces of

Kermanshah, Ilam, and Kurdistan) by intertrochanteric fractures in the years 2018 to 2020, which went through surgery by a board-certified orthopedic surgeon. First, we reviewed and collected the details of patient demographics (age, sex, and weight), medical history (a brief history of illness or drug use), and preoperative tests including hematocrit (HCT), platelet count, prothrombin time (PT), partial thromboplastin time (PTT), and international normalized ratio (INR). The details of the study were thoroughly described for all patients and we received informed consent from them. The inclusion criteria for the study were patients aged 60 to 80 years with American Society of Anesthesiologist (ASA) classes I and II. Exclusion criteria included any history of coagulation problems and anticoagulant drug consumption or a history of diseases such as stroke, coronary artery disease (CAD), hypertension (HTN), deep vein thrombosis (DVT), venous thromboembolism (VTE), peripheral artery disease (PAD), renal failure, seizure, and declining to participate. Finally, 62 patients were selected based on the eligibility criteria and divided into two groups after using a table of random numbers. A total of 31 patients in each group underwent operative treatment of intertrochanteric fractures [Arbeitsgemeinschaft für Osteosynthesefragen (AO) class 1 to 3 which class 1 fractures are simple two-part fractures, class 2 fractures are comminuted with a posteromedial fragment, and class 3 are reversed obliquity pattern] with the lateral approach and were fixed by plate fixation. Patients were blinded to the intervention. The first group known as the control group received 10 mg of normal saline (syringe A) and the second group known as the intervention group received 1 g TXA (syringe B) prepared by the preoperative nurse unaware of the study hypothesis, then it was given to anesthesiologist who administered the drug, up to 10 minutes before surgery via intravenous infusion. Neither

the anesthesiologist nor the surgeons were aware of the groups, nor did they know the nature and dose of the prescribed drugs. Surgeons' satisfaction with the field of surgery was recorded on a five-point Likert scale showing as very bad (1) to excellent (5) at 30, 60, 90, 120, and 180 minutes. After surgery, the total amount of intraoperative bleeding in the suction bottle was recorded while reducing the amount of serum from it. Also, the mean number of used gauze was documented. After 48 hours, the patient's hemoglobin (Hb) levels were rechecked. Moreover, the amount of blood product requirements and intra-drain bleeding were calculated. Statistical analysis was carried out by Stata software (version 14.2, Stata Corporation, College Station, TX, USA). Differences in baseline characteristics between the groups were analyzed using chi-square test for categorical variables and student t-test for continuous variables. Since the outcome has been measured more than 2 times, we conducted repeated measures analysis of variance (ANOVA) to assess the effect of the intervention of defined outcomes. The significance level was defined at 0.05. The study protocol was recorded at the Iranian Registry of Clinical Trials (IRCT) under registration number IRCT202000114046133N1. The Ethics Committee of Kermanshah University of Medical Sciences, Kermanshah, Iran, approved this trial (ethics code: IR.KUMS.REC.1398/450).

**Results**

83 patients were assessed for eligibility characteristics. Finally, 62 patients (31 patients for each group) were enlisted in the study. Moreover, all the registered patients were enumerated in the final analysis (Figure 1).

The demographic characteristics of each group are described in table 1.

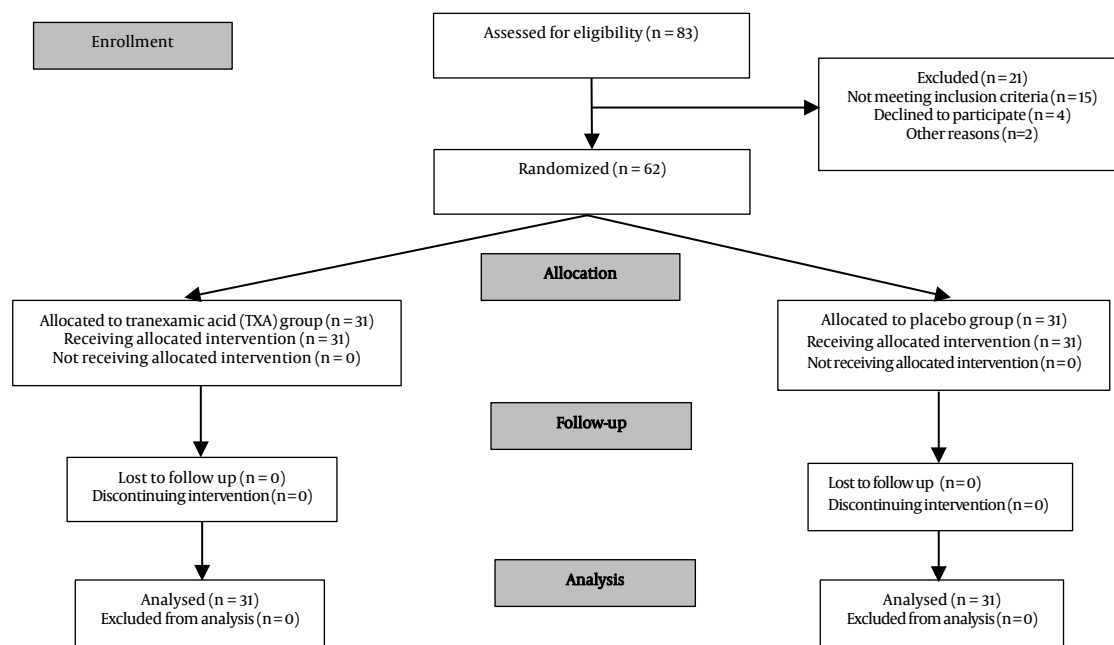


Figure 1. Enrollment in the randomized clinical trial

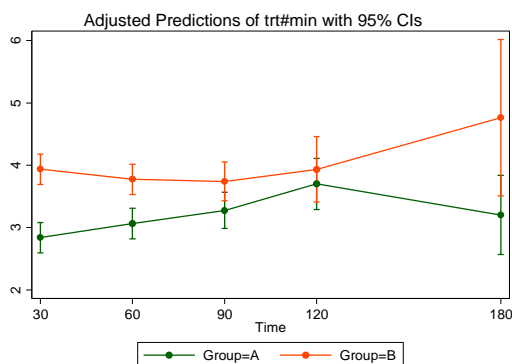
**Table 1.** Demographic variables in intervention and control groups

Variable	Group A	Group B	P-value
Age (year) (mean ± SD)	6.1 ± 69.2	6.4 ± 69.7	0.715
Gender	Male [n (%)]	22 (70.9)	21 (67.7)
	Female [n (%)]	9 (29.1)	10 (23.3)
Preoperative Hb (mean ± SD)	1.6 ± 11.9	1.1 ± 11.9	0.813
Fracture classification [n (%)]	A1	10 (32.3)	9 (29.1)
	A2	15 (48.4)	15 (48.4)
	A3	6 (19.3)	7 (22.6)

SD: Standard deviation; Hb: Hemoglobin

The mean amount of intraoperative bleeding was 170.2 ± 57.7 ml in group A (control group) and 145.6 ± 46.1 ml in group B (intervention group). In group A, it was about 25 ml higher than group B. This difference was statistically significant (P = 0.046). The mean number of gauze was 23.5 in group A and 19.2 in group B, which was statistically significant (P = 0.016). The mean intra-drain hemorrhage after 48 hours post-surgery in group A (85.44 ± 37.30) was about 13.3 ml higher than group B (72.14 ± 27.20), but this difference was not statistically significant (P = 0.050). The mean preoperative Hb level in both groups was 11.9 g/dl, but the mean Hb level after surgery in group A was 0.46 units lower than group B; this difference was statistically significant (P = 0.036). Eleven patients in the placebo or control group and 3 patients in the drug therapy group required transfusion of blood products after surgery. This difference was significant (P = 0.002).

According to Likert's satisfaction scale, the surgeon's satisfaction with the field of surgery was significantly higher in group B than in group A during surgery. In group B, the mean satisfaction score during surgery up to 120 minutes was almost constant; but in group A, it was gradually increasing. This difference was statistically significant (P = 0.001) (Figure 2).



**Figure 2.** Surgeon's satisfaction during surgery based on Likert's scale

**Discussion**

A spacious number of studies have appraised the utilizing of TXA in elective orthopedic surgeries such as total knee and hip replacement. Zeng et al. showed that intravenous TXA could significantly reduce the amount of hemorrhage volume and the need for transfusion of blood products in the first 24 hours in total knee arthroplasty surgery (13). Moreover, in total hip arthroplasty surgery, a meta-analysis conducted by Zhu et al. in a review of 25 clinical trials showed that TXA significantly reduced total hemorrhage volume, occult hemorrhage, and the necessity for blood transfusion after surgery (14). But in fractures such as intertrochanteric fracture, this subject remains somewhat controversial. A study by Zhang et al. showed that the effect of this drug on bleeding during surgeries for

fractures around the hip and acetabulum was still unclear (12). So, there is a need for further studies to determine drug efficacy and safety. The study by Tian et al., about the TXA effectiveness on occult bleeding in the patients treated by nailing [proximal femoral nail antirotation (PFNA)], showed that this drug caused a reduction in the occult bleeding compared with the control or placebo group (P = 0.037) (15). In the study by Zhou et al., in patients operated due to intertrochanteric fracture by nailing (PFNA), 1 g of TXA was given intravenously to the therapy group. The mean amount of intraoperative bleeding was 140.30 ± 80.64 ml in comparison with the placebo or control group (230.50 ± 130.56 ml), which was noticeably lower (P = 0.010). The mean amount of postoperative bleeding in the control group was 97.90 ± 20.93 ml versus 94.70 ± 35.78 ml which was not significantly different (P = 0.630). Also, 27 patients in the control group and 5 patients in the therapy group needed blood product transfusions. No side effects were reported after a 1-month follow-up (16).

Another meta-analysis conducted by Jiang and Shang on embase, pubmed, google data base, Cochrane Library and Chinese Wanfang databases between 1950 and 2018 years it was reported that tranexamic acid using in Intertrochanteric fractures can decrease the total amount of bleeding, amount of post-surgery intra-drain bleeding, need of blood transfusion, length of hospitalization and hematoma formation (P < 0.05) and it also increased hemoglobin levels during 3 days after surgery (P < 0.05) and the difference between groups were not affected by thromboembolic events and infection (P > 0.05) (17). In a study by Chen et al., TXA reduced the amount of bleeding and length of hospitalization in intertrochanteric fractures (18). Another clinical review by Krebs et al. on 8 intervention study between 2015 and 2019 reported that although TXA was regularly used as a method to reduce blood loss in elective orthopedic procedures (e.g., total hip and knee arthroplasty), there currently is little evidence concerning the optimal dosage, timing, and route for the use of TXA to reduce postoperative blood loss in hip fracture repair and further studies are needed to truly gauge the effect of TXA on long-term patient outcomes and hospital costs (19).

In our study, TXA also diminished hemorrhage volume as well as the number of gauze utilized during surgery, but the mean intra-drain bleeding 48 hours after surgery was not noticeable, and the drug utilization prevented a 0.46 unit decrease in Hb, a reduction in the necessity for blood products transfusion, and improved surgeons' satisfaction.

Although some studies have been conducted over the last year, especially in China, to evaluate the TXA effectiveness on intertrochanteric fractures, regarding differences in the races with the Middle East peoples, there is a need to assess its effectiveness in these countries.

The present study had some limitations. It did not compare the patient's blood pressure during surgery at different times, and it was preferable to weigh the number of consumable gauze during surgery.

**Conclusion**

The results of this study showed that utilizing intravenous TXA diminished hemorrhage volume, the amount of Hb, and the need to blood product transfusion and improved the surgeon's satisfaction.

**Conflict of Interest**

The authors declare no conflict of interest in this study.

## Acknowledgments

The authors would like to thank the Clinical Research Development Center of Taleghani and Imam Ali Hospitals, Kermanshah University of Medical Sciences, for the support, cooperation, and assistance throughout the period of this study. They also express their special thanks and appreciation to all the orthopedic residents of Kermanshah University of Medical Sciences who helped with this information. This study has been derived from a PhD dissertation (No. 3008336) approved by Kermanshah University of Medical Sciences.

## References

- Rockwood CA, Bucholz RW, Court-Brown CM, Heckman JD, Tornetta P. Rockwood and Green's fractures in adults. Philadelphia, PA: Lippincott Williams & Wilkins; 2010.
- Wanderer JP, Rathmell JP. Searching for quality: Hip Fractures and type of anesthesia. *Anesthesiology*. 2018;128(3):A1. doi: [10.1097/ALN.0000000000002115](https://doi.org/10.1097/ALN.0000000000002115).
- Craven RM. Managing anaesthetic provision for global disasters. *Br J Anaesth*. 2017;119(suppl\_1):i126-i134. doi: [10.1093/bja/aex353](https://doi.org/10.1093/bja/aex353). [PubMed: [29161394](https://pubmed.ncbi.nlm.nih.gov/29161394/)].
- Memtsoudis SG, Poeran J, Zubizarreta N, Rasul R, Opperer M, Mazumdar M. Anesthetic care for orthopedic patients: Is there a potential for differences in care? *Anesthesiology*. 2016;124(3):608-23. doi: [10.1097/ALN.0000000000001004](https://doi.org/10.1097/ALN.0000000000001004). [PubMed: [26771909](https://pubmed.ncbi.nlm.nih.gov/26771909/)].
- Jones KE, Butler EK, Barrack T, Ledonio CT, Forte ML, Cohn CS, et al. Tranexamic acid reduced the percent of total blood volume lost during adolescent idiopathic scoliosis surgery. *Int J Spine Surg*. 2017;11(4):27. doi: [10.14444/4027](https://doi.org/10.14444/4027). [PubMed: [29372131](https://pubmed.ncbi.nlm.nih.gov/29372131/)]. [PubMed Central: [PMC5779269](https://pubmed.ncbi.nlm.nih.gov/PMC5779269/)].
- Franchini M, Mengoli C, Marietta M, Marano G, Vaglio S, Pupella S, et al. Safety of intravenous tranexamic acid in patients undergoing major orthopaedic surgery: A meta-analysis of randomised controlled trials. *Blood Transfus*. 2018;16(1):36-43. doi: [10.2450/2017.0219-17](https://doi.org/10.2450/2017.0219-17). [PubMed: [29337665](https://pubmed.ncbi.nlm.nih.gov/29337665/)]. [PubMed Central: [PMC5770313](https://pubmed.ncbi.nlm.nih.gov/PMC5770313/)].
- Koehler D, Marsh JL, Karam M, Fruehling C, Willey M. Efficacy of surgical-site, multimodal drug injection following operative management of femoral fractures: A randomized controlled trial. *J Bone Joint Surg Am*. 2017;99(6):512-9. doi: [10.2106/JBJS.16.00733](https://doi.org/10.2106/JBJS.16.00733). [PubMed: [28291185](https://pubmed.ncbi.nlm.nih.gov/28291185/)].
- Casati V, Sandrelli L, Speziali G, Calori G, Grasso MA, Spagnolo S. Hemostatic effects of tranexamic acid in elective thoracic aortic surgery: A prospective, randomized, double-blind, placebo-controlled study. *J Thorac Cardiovasc Surg*. 2002;123(6):1084-91. doi: [10.1067/mtc.2002.120717](https://doi.org/10.1067/mtc.2002.120717). [PubMed: [12063454](https://pubmed.ncbi.nlm.nih.gov/12063454/)].
- Kerr AR. Anaesthesia with profound hypotension for middle ear surgery. *Br J Anaesth*. 1977;49(5):447-52. doi: [10.1093/bja/49.5.447](https://doi.org/10.1093/bja/49.5.447). [PubMed: [861111](https://pubmed.ncbi.nlm.nih.gov/861111/)].
- Subramanyam KN, Khanchandani P, Tulajaprasad PV, Jaipuria J, Mundargi AV. Efficacy and safety of intra-articular versus intravenous tranexamic acid in reducing perioperative blood loss in total knee arthroplasty: A prospective randomized double-blind equivalence trial. *Bone Joint J*. 2018;100-B(2):152-60. doi: [10.1302/0301-620X.100B2.BJJ-2017-0907.R1](https://doi.org/10.1302/0301-620X.100B2.BJJ-2017-0907.R1). [PubMed: [29437056](https://pubmed.ncbi.nlm.nih.gov/29437056/)].
- Bullmann V, Granitzka M. Blood management in complex reconstructive spine surgery in ASD patients: Do effective measures to reduce bleeding exist?. *Orthopade*. 2018;47(4):296-300. doi: [10.1007/s00132-018-3535-6](https://doi.org/10.1007/s00132-018-3535-6). [PubMed: [29435595](https://pubmed.ncbi.nlm.nih.gov/29435595/)].
- Zhang S, Xiao C, Pei F. Research progress on tranexamic acid in traumatic orthopedic surgery. *Zhongguo Xiu Fu Chong Jian Wai Ke Za Zhi*. 2019;33(11):1457-61. doi: [10.7507/1002-1892.201902030](https://doi.org/10.7507/1002-1892.201902030). [PubMed: [31650766](https://pubmed.ncbi.nlm.nih.gov/31650766/)].
- Zeng Y, Si H, Li C, Wu Y, Shen B. Effect of knee flexion position and combined application of tranexamic acid on blood loss following primary total knee arthroplasty: A prospective randomized controlled trial. *Int Orthop*. 2018;42(3):529-35. doi: [10.1007/s00264-018-3808-z](https://doi.org/10.1007/s00264-018-3808-z). [PubMed: [29396806](https://pubmed.ncbi.nlm.nih.gov/29396806/)].
- Zhu J, Zhu Y, Lei P, Zeng M, Su W, Hu Y. Efficacy and safety of tranexamic acid in total hip replacement: A PRISMA-compliant meta-analysis of 25 randomized controlled trials. *Medicine (Baltimore)*. 2017;96(52):e9552. doi: [10.1097/MD.0000000000009552](https://doi.org/10.1097/MD.0000000000009552). [PubMed: [29384974](https://pubmed.ncbi.nlm.nih.gov/29384974/)]. [PubMed Central: [PMC6393088](https://pubmed.ncbi.nlm.nih.gov/PMC6393088/)].
- Tian S, Shen Z, Liu Y, Zhang Y, Peng A. The effect of tranexamic acid on hidden bleeding in older intertrochanteric fracture patients treated with PFNA. *Injury*. 2018;49(3):680-4. doi: [10.1016/j.injury.2018.01.026](https://doi.org/10.1016/j.injury.2018.01.026). [PubMed: [29426608](https://pubmed.ncbi.nlm.nih.gov/29426608/)].
- Zhou XD, Zhang Y, Jiang LF, Zhang JJ, Zhou D, Wu LD, et al. Efficacy and Safety of Tranexamic Acid in Intertrochanteric Fractures: A Single-Blind Randomized Controlled Trial. *Orthop Surg*. 2019;11(4):635-42. doi: [10.1111/os.12511](https://doi.org/10.1111/os.12511). [PubMed: [31419080](https://pubmed.ncbi.nlm.nih.gov/31419080/)]. [PubMed: [PMC6712408](https://pubmed.ncbi.nlm.nih.gov/PMC6712408/)].
- Jiang W, Shang L. Tranexamic acid can reduce blood loss in patients undergoing intertrochanteric fracture surgery: A meta-analysis. *Medicine (Baltimore)*. 2019;98(11):e14564. doi: [10.1097/MD.0000000000014564](https://doi.org/10.1097/MD.0000000000014564). [PubMed: [30882622](https://pubmed.ncbi.nlm.nih.gov/30882622/)]. [PubMed Central: [PMC6426473](https://pubmed.ncbi.nlm.nih.gov/PMC6426473/)].
- Chen F, Jiang Z, Li M, Zhu X. Efficacy and safety of perioperative tranexamic acid in elderly patients undergoing trochanteric fracture surgery: A randomised controlled trial. *Hong Kong Med J*. 2019;25(2):120-6. doi: [10.12809/hkmj187570](https://doi.org/10.12809/hkmj187570). [PubMed: [30919809](https://pubmed.ncbi.nlm.nih.gov/30919809/)].
- Krebs NM, VanWagner MJ, Marchewka T, Faraj U, Vitale CR. Tranexamic Acid in the Treatment of Hip Fractures: A Clinical Review. *Spartan Medical Research Journal*. 2019;3(3):7026.