

# Genu Varum Correction: A Comparison of Conventional Open Wedge High Tibial Osteotomy versus Open Wedge Osteotomy with Sagittal Plane Cutting

Morteza Saeb<sup>1</sup>, Seyyed Saeed Khabiri<sup>2</sup>, Monireh Yaghoobi<sup>3,\*</sup>, Ali Mousapour<sup>2</sup>, Keykhosro Mardanpour<sup>1</sup>, Roya Safari-Faramani<sup>4</sup>, Alireza Shafiee<sup>3</sup>, Adel Hojabrian<sup>3</sup>, Sepehr Rahimpour<sup>3</sup>

<sup>1</sup> Associate Professor, Department of Orthopedic Surgery, School of Medicine, Kermanshah University of Medical Sciences, Kermanshah, Iran

<sup>2</sup> Assistant Professor, Department of Orthopedic Surgery, School of Medicine, Kermanshah University of Medical Sciences, Kermanshah, Iran

<sup>3</sup> Senior Resident, Department of Orthopedic Surgery, School of Medicine, Kermanshah University of Medical Sciences, Kermanshah, Iran

<sup>4</sup> Department of Epidemiology, Research Center for Environmental Determinants of Health, School of Public Health, Kermanshah University of Medical Sciences, Kermanshah, Iran

\*Corresponding author: Monireh Yaghoobi; Department of Orthopedic Surgery, School of Medicine, Kermanshah University of Medical Sciences, Kermanshah, Iran. Tel: +98-9182591007, Email: monireh.yaghoobi@kums.ac.ir

Received: 07 September 2018; Revised: 13 November 2018; Accepted: 02 February 2019

## Abstract

**Background:** Open wedge high tibial osteotomy (OWHTO) is commonly utilized to correct genu varum. To decrease various complications of OWHTO, some modifications are needed.

**Methods:** In a parallel randomized controlled clinical trial, 42 patients were divided into two groups: conventional OWHTO (control group) and OWHTO with the cut in the sagittal plane or distal tubercle osteotomy (OWHTO/DTO) (intervention group). Evaluation of the following items was conducted pre- and post-operatively: Knee Society Score (KSS) questionnaire, incidence of postoperative complications, patellar height by Blackburne-Peel (BP) ratio and Insall-Salvati Index (ISI), posterior tibial slope (PTS), tibiofemoral angle (TFA), Q-angle, medial proximal tibial angle (MPTA), three joint alignment radiography, and union radiological parameters.

**Results:** The differences between preoperative and postoperative variables including the KSS, PTS, TFA, BP Index (BPI), ISI, MPTA, and Q-angle within the intervention and control groups were not statistically significant. In four cases (3 in the control group and 1 in the intervention group), the delayed union was observed but the complete union was achieved after a mean of 23 weeks. No nonunion was observed.

**Conclusion:** Our results showed equal effectiveness for OWHTO/DTO compared with the conventional OWHTO.

**Keywords:** Genu Varum; Osteotomy; Techniques

**Citation:** Saeb M, Khabiri SS, Yaghoobi M, Mousapour A, Mardanpour K, Safari-Faramani R, et al. **Genu Varum Correction: A Comparison of Conventional Open Wedge High Tibial Osteotomy versus Open Wedge Osteotomy with Sagittal Plane Cutting.** *J Orthop Spine Trauma* 2019; 5(1): 12-6.



## Background

Genu varum is considered to be a common cause of medial knee pain, particularly while walking. Varus knee results in thinned articular surfaces, reduced articular space in the medial side, and the lateral deviation towards the mechanical axis. Ultimately, it leads to osteoarthritis (OA) (1).

In this condition, surgery is carried out to shift the pressure from the affected side to the other one. Thus, to conduct an effective surgery, at least there should be one healthy side in the medial or lateral knee compartment (2). Preoperatively, Ahlbäck classification should be used to determine the degree of articular cartilage injury. A grade 3 or higher implies the benefits of the osteotomy. The improvement level for varus correction varies from 3-5 to 7-9 degrees (3). During a 5-year follow-up study, Brinkman et al., showed a 87% survival rate with a correction value of more than 8 degrees (1). Increased pain and the probable patella baja, fracture, infection, and knee stiffness have been mentioned as the common postoperative complications for open wedge high tibial osteotomy (OWHTO). When the patella baja, also known as patella infera, is present, converting the osteotomy to total knee arthroplasty (TKA) is difficult (4, 5).

On the other hand, there is not a comprehensive

understanding of the biomechanics of patella baja after OWHTO. The patella tendon scarring and subsequent shortening of the patellar tendon are postulated as possible causes (6). Thus, other methods should be employed to reduce these complications. In limbs with varus alignment, the highest pressure (65%) is on the medial side, compared with the 60% pressure on the normal knee alignment (1). Besides, increased posterior tibial slope (PTS) is strongly related to the anterior tibial translation. Increased PTS in the OWHTO results in the restriction of knee extension and increased pressure on the anterior cruciate ligament (ACL) (3). Given the lower tibial tubercle position following open wedge osteotomy, reduced patellar height could be the important source of patient dissatisfaction (6).

In this study, we attempted to assess the outcome of OWHTO with and without the cut in the sagittal plane or distal tubercle osteotomy (OWHTO/DTO). Also, the consequence of changes in the patellar height and quality of life in these patients was evaluated.

## Methods

This parallel randomized study was performed as a controlled clinical trial that was registered under registration number of IRCT20180904040954N1 at the

Iranian Registry of Clinical Trials (IRCT) center. The study population included patients with genu varus deformity presented to Taleghani Hospital, Kermanshah, Iran, from March 2019 to September 2019.

We used inclusion criteria proposed by the International Society of Arthroscopy, Knee Surgery, and Orthopaedic Sports Medicine (ISAKOS) (1), as follows: patients under 50 years old, isolated pain in the medial articular area, malalignment of less than 20 degrees, normal knee movements, lack of flexion contracture, normal patellofemoral component, and normal ligament balance. Patients with the following conditions were excluded: fractures in other parts of the body, open wounds or infections, changes resulted from knee arthritis, OA in lateral and medial compartments, flexion contracture more than 25 degrees, obesity, and meniscectomy in the target compartment (1).

The patients were randomly categorized into the conventional OWHTO group (control group) and OWHTO/DTO (intervention group). Randomization was performed by a random number table. Once the informed consent was obtained (code: IR.KUMS.REC.1398/947), the patients were incorporated into the study (Figure 1).

Pre- and post-operative evaluation of the following items were conducted: the assessment of patients with Knee Society Score (KSS) questionnaire, incidence of postoperative complications such as fracture, infection determined by positive culture and laboratory tests like C-reactive protein (CRP), nonunion and nerve damage, the assessment of the patellar height by Blackburne-Peel (BP) ratio and Insall-Salvati Index (ISI), PTS, tibiofemoral angle (TFA), Q-angle, medial proximal tibia angle (MPTA), three joint alignment radiography, and union radiological parameters.

The conventional OWHTO surgery involved retaining an attachment between the tibial tubercle and the distal tibial segment. At first, the patient lay on the supine position, inflating the tourniquet. Then, an incision was made at the

proximal tibial anteromedial surface, the fascia was cut, and the pes anserinus was identified. Once a posterior third of the medial collateral ligament (MCL) was dissected, the anterior two-third was transversely incised. Then, two 2.4-mm k-wires were placed parallel to the osteotomy line, being examined by fluoroscopy at the lateral and posteroanterior (PA) view. The protection of the posterior neurovascular and patellar tendon was performed with a retractor. Before the saw reaches the lateral cortex, osteotomy is accomplished, then using a 3.2 mm drill bit, 2 holes are created in the lateral cortex. Then wedge or bone graft was inserted into the osteotomy site. After that, osteotomy fixation was performed using a 4.5-mm plate, TomoFix, or T-plate.

In OWHTO/DTO, an attachment was made between the tibial tubercle and the proximal tibial segment. Therefore, the possibility of changing the patella height decreased. Unlike the previous method, keeping at least 2.5 cm of the tubercle length is needed for low corrections and the longer in the further correction. Then, an osteotomy was conducted in the posterior of the tibial tubercle. To start the osteotomy, the tibial tubercle was cut in the sagittal and distal planes through the anterior tibial cortex in an overlapping manner with the distal tibial segment (at least 2 cm of tubercle length is needed to prevent intra-operative fracture after OWHTO/DTO). After osteotomy and fixation by a plate, the tubercle was attached to the tibia with a bicortical screw (Figure 2a).

To evaluate the union, two methods of clinical examination [pain during weight-bearing (WB) and movement, warmth, and tenderness of the osteotomy site] as well as radiology signs (increased graft density and trabecular bridging in the osteotomy place) were employed. In the absence of the aforementioned indicators three months after surgery and the creation of sclerotic margins in the osteotomy site, it was interpreted as nonunion. The postoperative visits were held at intervals of 1, 2, 4, 6, and 8 weeks and 3, 6, and 12 months (Figure 2b).

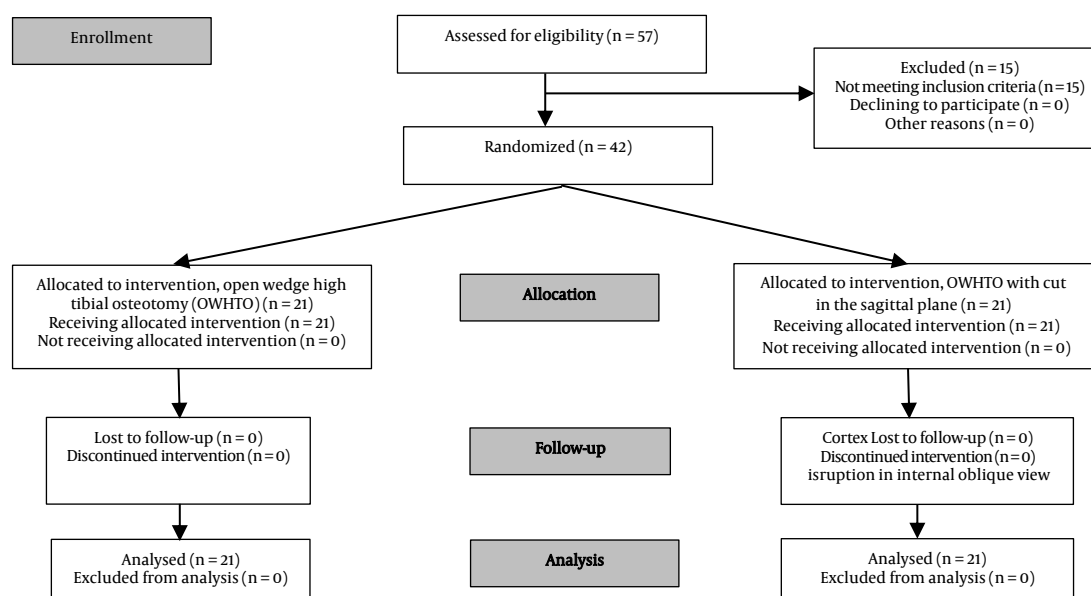
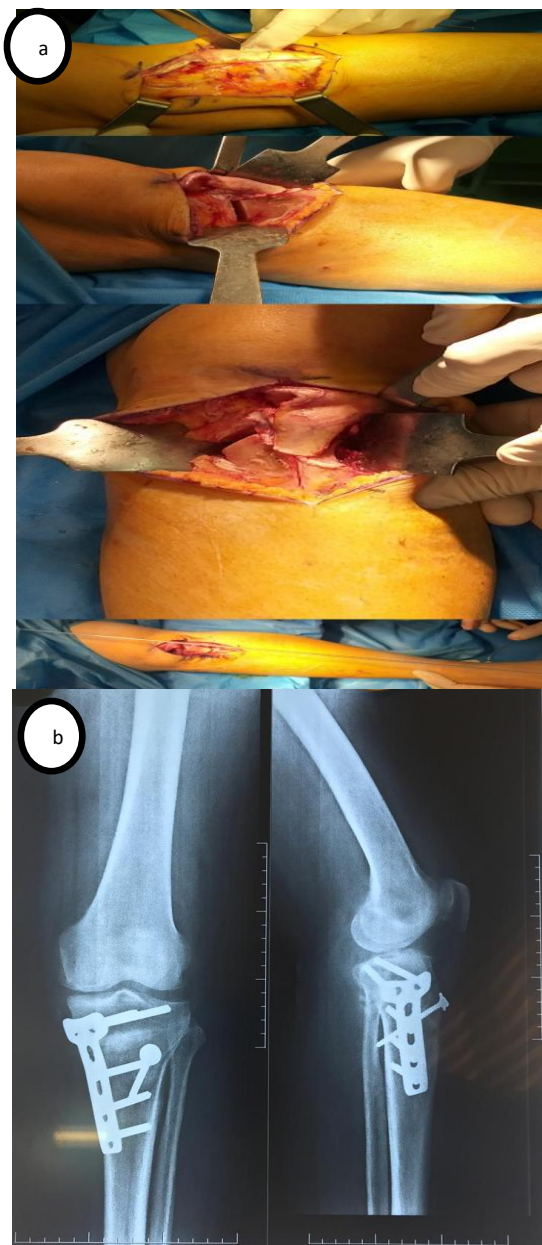


Figure 1. Flowchart of study enrolment



**Figure 2.** Open wedge high tibial osteotomy (OWHTO) with the cut in the sagittal plane; (a) surgical incision and osteotomy in the sagittal plane in left knee, (b) plain radiographic appearance after 8 weeks

On the first day after surgery, straight leg raise (SLR) was allowed. On the second day, the patient was discharged and instructed to do touch-down WB with crutches. Within the first week after surgery, knee flexion should be achieved up to 90 degrees.

Radiographic examinations were performed in the 2<sup>nd</sup>, 4<sup>th</sup>, 8<sup>th</sup>, and 12<sup>th</sup> week. Between the 6<sup>th</sup> and 8<sup>th</sup> week, when union signs observed, patients were allowed progressive WB. Receiving anticoagulants for up to 6 weeks is recommended.

To conduct data analysis, Stata software (version 14.2, Stata Corporation, College Station, TX, USA) was used. Data description was performed through numerical indices such as mean, standard deviation (SD), etc. The normality of data was tested with the Shapiro-Wilk test. The Mann-Whitney U test was employed to compare the means of the quantitative variables pre- and post-operatively. Moreover,

the chi-square test was applied for comparing the categorized variables. In the present study,  $P < 0.05$  was considered as significant.

**Results**

Out of 57 enrolled patients, 15 were excluded due to the lack of inclusion criteria. Finally, 42 patients were included (21 in each control and intervention groups). The mean age of patients was  $29.50 \pm 5.75$  years ( $28.42 \pm 5.46$  years in the intervention and  $30.57 \pm 5.97$  years in the control group,  $P = 0.090$ ). There were no statistically significant differences between the control and the intervention groups in terms of gender distribution ( $P = 0.747$ ), smoking status ( $P = 0.627$ ), and diabetes ( $P = 0.549$ ) (Table 1). Based on the Shapiro-Wilk test, the variables in the two groups were not normally distributed ( $P = 0.020$ ) and data analysis was carried out using nonparametric tests.

**Table 1.** Comparison of demographic variables in intervention and control groups by Pearson's chi-square test

Variable		Control (n=21)	Intervention (n=21)	$\chi^2$	P-value
Gender	Female	13	14	0.103	0.747
	Male	8	7		
Smoking	Nonsmoker	18	16	0.236	0.627
	Smoker	3	17		
Diabetes	Non diabetic	20	19	0.359	0.549
	Diabetic or with impaired glucose tolerance	1	2		

In both groups, most patients obtained complete union osteotomy within 3 months, but in 4 cases (3 in the control group and 1 in the intervention group), the delayed union was observed with a complete union being achieved after a mean of 23 weeks. However, a comparison of the union between the two groups was not statistically significant ( $P = 0.293$ ). None of the two groups showed nonunion. No patient showed complications such as infection, intra-articular fracture during surgery, and peroneal nerve injury.

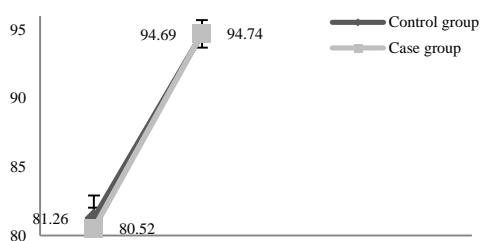
The mean left distal femur angle (DFA) at the baseline showed the values of  $88.50 \pm 0.45$  and  $88.65 \pm 0.56$  in the control and intervention groups, respectively.

The difference between pre- and post-operative variables including the KSS, PTS, TFA, BP Index (BPI), ISI, MPTA, and Q-angle within the intervention and control groups was not statistically significant (Table 2, Figures 3-7).

**Table 2.** Comparison of variables in intervention and control groups by Mann-Whitney U test

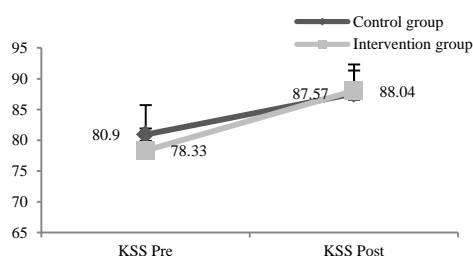
Variable		Score before surgery (mean $\pm$ SD)	P-value	Score after surgery (mean $\pm$ SD)	P-value
KSS	Control	80.90 $\pm$ 4.79	0.060	87.57 $\pm$ 4.75	0.820
	Intervention	78.33 $\pm$ 3.65		88.04 $\pm$ 3.29	
BPI	Control	0.81 $\pm$ 0.04	0.130	0.79 $\pm$ 0.04	0.060
	Intervention	0.82 $\pm$ 0.03		0.81 $\pm$ 0.03	
ISI	Control	1.05 $\pm$ 0.09	0.830	1.10 $\pm$ 0.09	0.240
	Intervention	1.05 $\pm$ 0.08		1.06 $\pm$ 0.91	
TFA	Control	-6.95 $\pm$ 1.39	0.970	5.09 $\pm$ 0.88	0.920
	Intervention	-6.05 $\pm$ 1.49		5.04 $\pm$ 0.80	
PTS	Control	8.37 $\pm$ 3.11	0.240	9.57 $\pm$ 2.99	0.900
	Intervention	3.12 $\pm$ 8.00		8.20 $\pm$ 3.11	
Q-angle	Control	13.39 $\pm$ 1.52	0.130	15.06 $\pm$ 1.53	0.050
	Intervention	13.96 $\pm$ 1.76		15.74 $\pm$ 1.58	
MPTA	Control	81.26 $\pm$ 1.65	0.430	94.69 $\pm$ 0.64	0.160
	Intervention	80.52 $\pm$ 1.50		94.74 $\pm$ 0.97	

KSS: Knee Society Score; BPI: Blackburne-Peel Index; ISI: Insall-Salvati Index; PTS: Posterior tibial slope; TFA: Tibiofemoral angle; MPTA: Medial proximal tibial angle; SD: Standard deviation

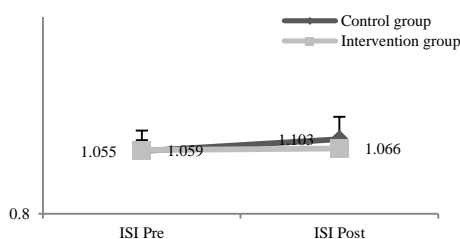


**Figure 3.** Comparison of the mean pre- and post-operative medial proximal tibial angle (MPTA) in intervention and control groups

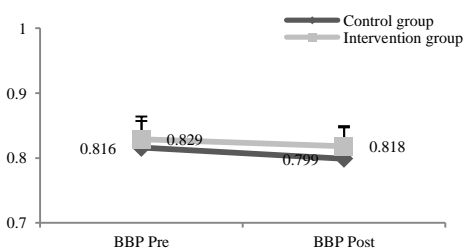
The mean MPTA angle in both control and intervention groups increased after surgery, but this difference was not statistically significant (Figure 3).



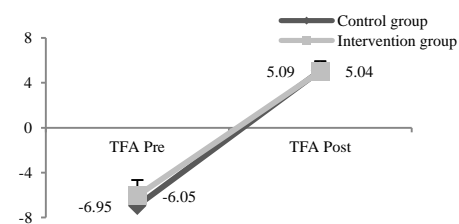
**Figure 4.** Comparison of the mean pre- and post-operative Knee Society Score (KSS) in intervention and control groups



**Figure 5.** Comparison of the mean pre- and post-operative Insall-Salvati Index (ISI) in intervention and control groups



**Figure 6.** Comparison of the mean pre- and post-operative Blackburne-Peel (BP) score in intervention and control groups



**Figure 6.** Comparison of the mean pre- and post-operative Blackburne-Peel (BP) score in intervention and control groups

### Discussion

Various studies have suggested changes in the patellar tendon length and PTS after OWHTO, and increasing forces on the patellofemoral tendon at the beginning of flexion (0 to 10°). Such studies consider these changes as a reason for the modification of the conventional OWHTO (7-9). The most important step of the OWHTO/DTO technique is to cut the attachment between the tibial tubercle and the proximal segment in the sagittal plane. So, changing the patellar tendon's length through this procedure is less possible (8).

Despite increasing the PTS in both methods, larger posterior gaps than anterior ones have been made in some studies to avoid increasing tibial slopes. Moreover, using OWHTO/DTO method has been considered in many papers for correction of genu varum with varus above 10 degrees (9-12). Since correction angles in most of our patients were 10 degrees, we were not able to examine this matter in our research.

In the present study, the KSS questionnaire for quality of life showed no significant difference between the two study groups. However, both groups had KSS values higher than the baseline. Unlike our study, previous studies found significant differences between the two groups in the scores of knee evaluation tests such as Oxford Knee Score (OKS) and Lysholm score. The ISI, BPI, and Caton-Deschamps (CD) index were employed to evaluate changes in the patellar tendon's length in most studies and reported significant differences (7-9, 13, 14). In our study, ISI and BP indices showed changes in postoperative mean values which were not statistically and significantly different from preoperative values. Given the concurrent changes of CD and BP with the tibial slope, other indices such as ISI and Miura-Kawamura (MK) should be used in proximal tibial osteotomy with increased tibial posterior slope (10). Park et al. suggested using MK index as a better method to examine the patella height (9).

On the other hand, the postoperative Q-angle increase in both groups was not statistically significant and the patella lateralization did not change ultimately.

Based on previous reports, patients with OWHTO had increased mean PTS (9, 12). In both of our study groups, a slightly increasing trend in PTS changes was detected. In OWHTO/DTO group, the trend was less than the OWHTO group. However, this difference between the two groups was not statistically significant. Therefore, the result of the present study was not following previous studies.

In this study in line with other studies, the genu varus correction osteotomy was expected to obtain an average TFA angle of 6 and an MPTA of at least 95 (13). However, changes in the MPTA angle and TFA angles were compared in both groups in pre- and post-operative periods, finding no statistically significant difference.

Based on previous clinical experience, nonunion was considered as one of the complications of tubercle osteotomy (13, 14). The union rate seemed to be different between the two osteotomy groups. Three patients from the control group and one from the intervention group showed delayed union (with an average of 23 weeks). However, consistent with previous studies (9, 13, 14), we did not find nonunion in any of our patients.

Incomplete evaluation of the patella inclination was one of our limitations. In the study of Park et al., the patellar tilt was measured employing the computed tomography (CT) scan (axial cut) and despite their expectations, the lateralization of the patellar tendon decreased after OWHTO/DTO in both groups (9). Our study

had other limitations including the lack of pre-osteotomy arthroscopic examination, short follow-up duration, and small sample size.

### Conclusion

Although we could not prove the superiority of OWHTO/DTO in comparison to the conventional OWHTO, our results indicated equal effectiveness. Therefore, it can be used for varus correction based on the surgeon's preference for selected patients. Further clinical trials are needed to explore the advantages and disadvantages of these approaches.

### Conflict of Interest

The authors declare no conflict of interest in this study.

### Acknowledgments

The authors would like to thank the Clinical Research Development Center of Taleghani and Imam Ali Hospitals, Kermanshah University of Medical Sciences, Kermanshah, Iran, for the support, cooperation, and assistance throughout the period of this study. We also thank and appreciate all the orthopedic residents of Kermanshah University of Medical Sciences who helped us with this information. This study has been derived from a PhD dissertation (No. 3008934) approved by Kermanshah University of Medical Sciences.

### References

1. Brinkman JM, Lobenhoffer P, Agneskirchner JD, Staubli AE, Wymenga AB, van Heerwaarden RJ. Osteotomies around the knee: Patient selection, stability of fixation and bone healing in high tibial osteotomies. *J Bone Joint Surg Br.* 2008;90(12):1548-57. doi: [10.1302/0301-620X.90B12.21198](https://doi.org/10.1302/0301-620X.90B12.21198). [PubMed: [19043123](https://pubmed.ncbi.nlm.nih.gov/19043123/)].
2. Gao L, Madry H, Chugaev DV, Denti M, Frolov A, Burtsev M, et al. Advances in modern osteotomies around the knee: Report on the association of sports traumatology, arthroscopy, orthopaedic surgery, rehabilitation (ASTAOR) Moscow international osteotomy congress 2017. *J Exp Orthop.* 2019;6(1):9. doi: [10.1186/s40634-019-0177-5](https://doi.org/10.1186/s40634-019-0177-5). [PubMed: [30805738](https://pubmed.ncbi.nlm.nih.gov/30805738/)]. [PubMed Central: [PMC6389998](https://pubmed.ncbi.nlm.nih.gov/PMC6389998/)].
3. Rossi R, Bonasia DE, Amendola A. The role of high tibial osteotomy in the varus knee. *J Am Acad Orthop Surg.* 2011;19(10):590-9. doi: [10.5435/00124635-201110000-00003](https://doi.org/10.5435/00124635-201110000-00003). [PubMed: [21980024](https://pubmed.ncbi.nlm.nih.gov/21980024/)].
4. Song EK, Seon JK, Park SJ, Jeong MS. The complications of high tibial osteotomy: Closing- versus opening-wedge methods. *J Bone Joint Surg Br.* 2010;92(9):1245-52. doi: [10.1302/0301-620X.92B9.23660](https://doi.org/10.1302/0301-620X.92B9.23660). [PubMed: [20798442](https://pubmed.ncbi.nlm.nih.gov/20798442/)].
5. Miller BS, Downie B, McDonough EB, Wojtys EM. Complications after medial opening wedge high tibial osteotomy. *Arthroscopy.* 2009;25(6):639-46. doi: [10.1016/j.arthro.2008.12.020](https://doi.org/10.1016/j.arthro.2008.12.020). [PubMed: [19501295](https://pubmed.ncbi.nlm.nih.gov/19501295/)].
6. Jabalameli M, Rahbar M, Radi M, Hadi H, Moradi A. Radiographic results of high tibial open wedge osteotomy. *Iran J Surg.* 2013;21(1). [In Persian].
7. Raymond LD, Laflamme GY, Ranger P, Zhim F, Girard J. Open-wedge retro-tubercular tibial osteotomy: An innovating technique. *Rev Chir Orthop Reparatrice Appar Mot.* 2007;93(6):588-93. doi: [10.1016/s0035-1040\(07\)92681-1](https://doi.org/10.1016/s0035-1040(07)92681-1). [PubMed: [18065868](https://pubmed.ncbi.nlm.nih.gov/18065868/)].
8. Hopwood S, Khan W, Agarwal S. The biplanar open wedge high tibial osteotomy preserving the tibial tubercle. *J Orthop Sci.* 2016;21(6): 786-90. doi: [10.1016/j.jos.2016.07.006](https://doi.org/10.1016/j.jos.2016.07.006). [PubMed: [27484856](https://pubmed.ncbi.nlm.nih.gov/27484856/)].
9. Park H, Kim HW, Kam JH, Lee DH. Open wedge high tibial osteotomy with distal tubercle osteotomy lessens change in patellar position. *Biomed Res Int.* 2017;2017:4636809. doi: [10.1155/2017/4636809](https://doi.org/10.1155/2017/4636809). [PubMed: [28804716](https://pubmed.ncbi.nlm.nih.gov/28804716/)]. [PubMed Central: [PMC5540386](https://pubmed.ncbi.nlm.nih.gov/PMC5540386/)].
10. Akizuki S, Shibakawa A, Takizawa T, Yamazaki I, Horiuchi H. The long-term outcome of high tibial osteotomy: A ten- to 20-year follow-up. *J Bone Joint Surg Br.* 2008;90(5):592-6. doi: [10.1302/0301-620X.90B5.20386](https://doi.org/10.1302/0301-620X.90B5.20386). [PubMed: [18450624](https://pubmed.ncbi.nlm.nih.gov/18450624/)].
11. Grimm NL, Lazarides AL, Amendola A. Tibial tubercle osteotomies: A review of a treatment for recurrent patellar instability. *Curr Rev Musculoskelet Med.* 2018;11(2):266-71. doi: [10.1007/s12178-018-9482-3](https://doi.org/10.1007/s12178-018-9482-3). [PubMed: [29721692](https://pubmed.ncbi.nlm.nih.gov/29721692/)]. [PubMed Central: [PMC5970117](https://pubmed.ncbi.nlm.nih.gov/PMC5970117/)].
12. Phillips CL, Silver DA, Schranz PJ, Mandalia V. The measurement of patellar height: A review of the methods of imaging. *J Bone Joint Surg Br.* 2010;92(8):1045-53. doi: [10.1302/0301-620X.92B8.23794](https://doi.org/10.1302/0301-620X.92B8.23794). [PubMed: [20675745](https://pubmed.ncbi.nlm.nih.gov/20675745/)].
13. Kaper BP, Bourne RB, Rorabeck CH, Macdonald SJ. Patellar infera after high tibial osteotomy. *J Arthroplasty.* 2001;16(2): 168-73. doi: [10.1054/arth.2001.20538](https://doi.org/10.1054/arth.2001.20538). [PubMed: [1122889](https://pubmed.ncbi.nlm.nih.gov/1122889/)].
14. Gaasbeek RD, Sonneveld H, van Heerwaarden RJ, Jacobs WC, Wymenga AB. Distal tuberosity osteotomy in open wedge high tibial osteotomy can prevent patella infera: A new technique. *Knee.* 2004;11(6):457-61. doi: [10.1016/j.knee.2004.02.002](https://doi.org/10.1016/j.knee.2004.02.002). [PubMed: [15581764](https://pubmed.ncbi.nlm.nih.gov/15581764/)].