

Traumatic, Old, and Unreduced Bilateral Knee Dislocation: A Case Study and Literature Review

Seyed Mohammad Javad Mortazavi¹, Nima Bagheri^{2,*}, Mohammad Vahedian-Ardakani³ and Hojjat Askari⁴

¹ Professor, Department of Orthopedic Surgery, Joint Reconstruction Research Center, Tehran University of Medical Sciences, Tehran, Iran

² Assistant Professor, Department of Orthopedic Surgery, Joint Reconstruction Research Center, Tehran University of Medical Sciences, Tehran, Iran

³ Assistant Professor, Department of Orthopedic Surgery, Firouzgar Hospital, Iran University of Medical Sciences, Tehran, Iran

⁴ Orthopedic Surgeon, Joint Reconstruction Research Center, Tehran University of Medical Sciences, Tehran, Iran

*Corresponding author: Nima Bagheri; Assistant Professor, Department of Orthopedic Surgery, Joint Reconstruction Research Center, Tehran University of Medical Sciences, Tehran, Iran. Tel: +98-2161192767, +98-9122149817, Email: nimabi360@gmail.com

Received 2018 June 14; Revised 2018 August 18; Accepted 2018 September 22

Abstract

Background: Old unreduced knee dislocation is rare, which means the experience is still lacking about the best treatment options. Moreover, several surgical options for this condition are still lacking in peer-reviewed research. This is a case report of the treatment of a patient who had bilateral traumatic knee dislocations that were unreduced two months after injury.

Case Presentation: A 45-year-old man with bilateral traumatic unreduced knee dislocation came 2 months after injury. He had no active knee extension and was unable to walk. He underwent open reduction and external fixation. He had good range of motion (ROM) and painless walking in short term. After 5 years, he had acceptable ROM and painless walking, but x-rays showed persistent posterior subluxation of the left knee and some bone loss of the right tibia.

Conclusions: Open reduction, repair of torn ligaments, and external fixation was an effective treatment in regaining ROM and stability in a patient who had bilateral unreduced knee dislocations of two months duration. After five years, the patient had a satisfactory function, but radiographs showed persistent posterior subluxation of one knee and some bone loss of the tibia in the other.

Keywords: Knee Dislocation; Range of Motion; Articular; Joint Dislocations; Knee Joint

Citation: Mortazavi SMJ, Bagheri N, Vahedian-Ardakani M, Askari H. Traumatic, Old, and Unreduced Bilateral Knee Dislocation: A Case Study and Literature Review. *J Orthop Spine Trauma* 2018; 4(4): 84-7.



Background

This is a case report of the treatment of a patient who had bilateral traumatic knee dislocations that were unreduced two months after injury. The patient was informed that data concerning the case would be submitted for publication and he provided consent.

Case Presentation

A 45-year-old man attended our clinic in Imam Khomeini Hospital Complex, Iran, with a history of a car accident (rollover crash) and multiple traumas that had occurred two months ago. The patient had been hospitalized in the intensive care unit (ICU) and was in a coma after the accident. He sustained head (contusion), chest (right pneumothorax and 2 ribs fracture), and abdominal trauma (spleen rupture) and had received a splenectomy operation. His bilateral dislocation was overlooked because of his general condition and the fact that he was unconscious. In the presentation to our clinic, he was alert sitting on a wheelchair. The patient complained of bilateral knee deformity, inability to walk, and inability to extend the knee joints. Both knees had only about 20 degrees range of motion (ROM) and between 70 to 90-degree flexion. The patient also had severe bilateral quadriceps atrophy and no active extension. His pulse and sensorimotor examination were normal and the skin was intact.

Figure 1 shows the results of the patient's radiography. The x-rays revealed a bilateral posterolateral knee dislocation.

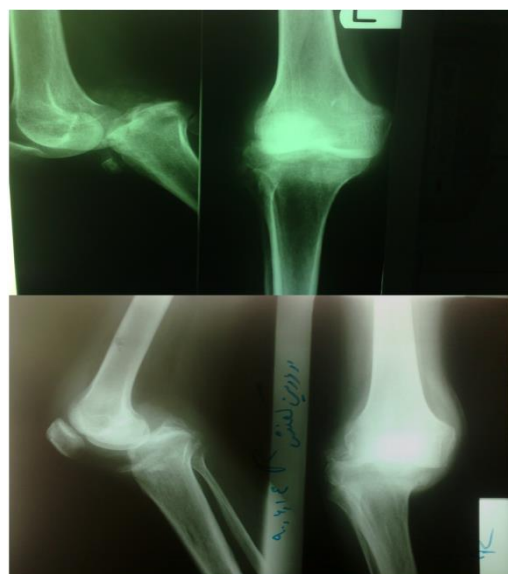


Figure 1. Right (below) and left (above) knees [anteroposterior (AP) and lateral radiography]

The patient received magnetic resonance imaging (MRI), computed tomography (CT) scan, angiography, and electromyography-nerve conduction velocity (EMG-NCV) exam when he arrived at the clinic. The MRI showed multiple ligament injuries and bone bruises, but the patellar tendon was still intact (Figure 2).

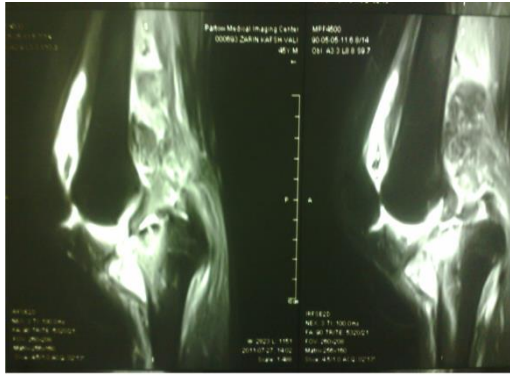


Figure 2. Magnetic resonance imaging (MRI) of left knee

The angiography and EMG-NCV exam were both normal. Due to the amount of time that had elapsed since the trauma, we decided to perform an open reduction for the patient's knees in two separate operations in a one-week interval and the same admission: one for the left knee and one for the right knee. Our approach was to focus on the anterior midline with medial parapatellar arthrotomy (MPPA), which released the soft tissue fibrosis and contracted capsule of the tibia and femur. According to bilateralism, stiffness of the knees, and severe quadriceps atrophy, we did not have the plan of ligament reconstruction, but we planned to preserve every soft tissue attachment in medial and lateral sides to repair at the end of surgery. After each step, we tried to reduce the knee joint; however, the medial femoral condyle was buttonholed in the medial capsule, which seemed to be the cause of the irreducibility (Figure 3).

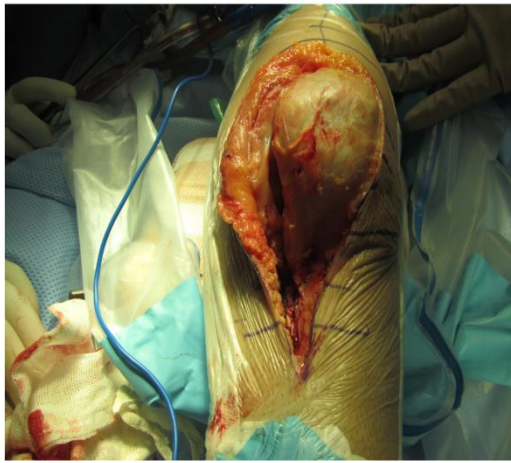


Figure 3. Medial femoral condyle buttonholing in the medial capsule

After sufficient release of the knee joint, we were able to reduce the knee and repair every component that was repairable, including both menisci and collateral ligaments. To take care of the remaining reduction, we applied a bridging external fixator in the knee extension because the hinged external fixator was inaccessible (Figure 4). Isometric quadriceps strengthening exercise began the day of surgery. The knees were brought to flexion gradually by readjusting the external fixator each week. After six weeks, the fixator was removed and the patient underwent an active rehabilitation program including continuous passive motion (CPM), quadriceps strengthening, and physical therapy exercises to walk again.

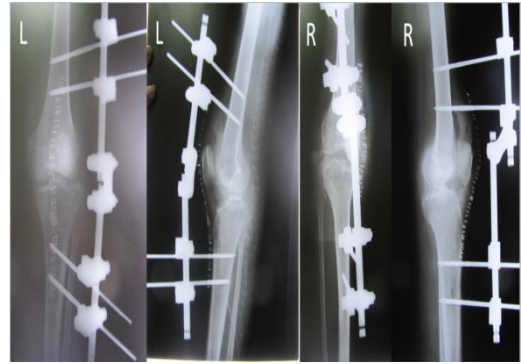


Figure 4. Post-operative radiography of the left and right knees [anteroposterior (AP) and lateral radiography]

The patient gained zero to 95 degrees in his ROM and was able to walk painlessly four months after surgery (Figure 5).

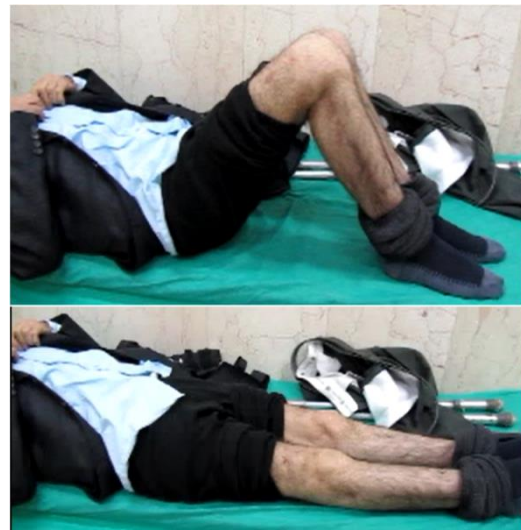

Figure 5. Range of motion (ROM) in the knees after four months

After 5 years, the patient did not have any lookup because of no serious symptoms. We called him several times to have some photos and radiographs after 5 years of treatment. He was able to walk without any aids and felt no annoying pain. Both knees had acceptable ROM (Figure 6), but radiographs of knees were not as good (Figure 7).

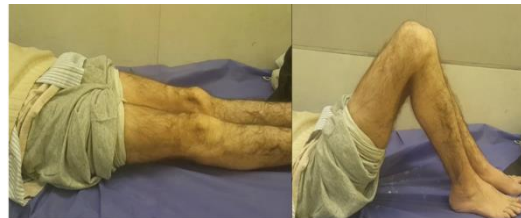

Figure 6. Patient's photograph of both knees range of motion (ROM) after 5 years of follow-up

Discussion

Multiple associated injuries, such as head, chest, and abdomen trauma (the same as in our patient) can lead surgeons to overlook important problems, such as bilateral knee dislocation.

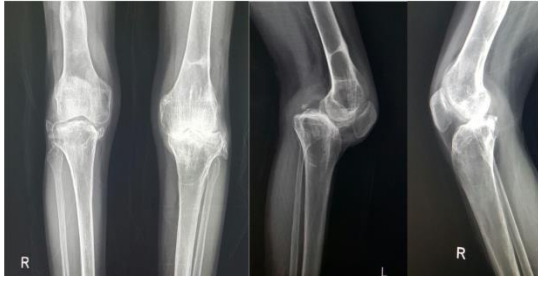

Figure 7. X-rays after 5 years of follow-up

Spontaneous relocation and later re-dislocation, a torn capsule, and leakage of the hemarthrosis could be other causes that go untreated. Old unreduced knee dislocation is rare, which means the experience is still lacking about the best treatment options. Moreover, several surgical options for this condition are still lacking in peer-reviewed research. Sharing experience via case reports can help surgeons when making difficult choices that range from open reduction to arthrodesis and arthroplasty.

Choosing the proper technique is a significant dilemma that surgeons face when deciding how to reduce a patient's knee by open surgery. Surgeons face many challenges when trying to reduce an old unreduced knee joint, such as choosing the best approach, deciding how much soft tissue to release, figuring out how to maintain the reduction, choosing a rehabilitation protocol, and reconstructing the ligament. Firm guidance on these challenges is lacking in the literature. In our patient,

severe atrophy of the quadriceps and bilateralism meant that arthroplasty and arthrodesis were contraindicated. Therefore, our best choice was an open reduction. Karn et al. reported a case of neglected knee dislocation that lasted for two months and was treated by open reduction and external fixation at 70 degrees of flexion (because re-dislocation was possible with more extension) followed by gradual extension until the full extension was achieved. Their result was 5 to 70 degrees in the ROM and painless weight-bearing one year after follow-up (1). We used a similar approach, but we fixed the knees in extension using an external fixator and gradually flexed the knee until 90 degrees of flexion. After six weeks, we removed the fixator and the patient began rehabilitation and physiotherapy. The ROM was better in our study and the amount of time until painless weight-bearing was the same. However, due to bilateral involvement in our patient, using a walker and crutches was inevitable.

Vicente-Guillen et al. reported a case of neglected posterior knee dislocation that was managed by staged reduction and external fixation followed by a final arthrodesis (2). In our case, arthrodesis was not a viable option because of the bilateral involvement. Chen and Chiu also mentioned a case of chronic knee dislocation that was successfully treated by arthroplasty despite another dislocation five days postoperative (3). In presentation, our patient's quadriceps was severely atrophied and his extensor mechanism was inefficient, meaning that arthroplasty was contraindicated.

Table 1 shows the results of case reports of neglected knee dislocation in the English literature.

Table 1. Data of studies reporting chronic knee dislocation

| Study | Chronicity | Treatment option | Result of ROM | Bilateralism | Result of stability | Result of function |
|-----------------------------|---|---|--|--------------------------|--|--------------------|
| Simonian et al. (7) | 4 months | Ligament reconstruction and external fixation | -5 to 105 | Unilateral | Stable | - |
| Simonian et al. (7) | 8 months | Ligament reconstruction and external fixation | 0 to 120 | Unilateral | Stable | Good |
| Henshaw et al. (8) | 24 weeks | Open reduction and pinning and casting | 5 to 40 | Unilateral | Stable | Satisfactory |
| Petrie et al. (9) | 4 months | TKA | 5 to 90 | Unilateral | Stable | Good |
| Richter and Lobenhoffer (4) | 1 month | PCL reconstruction and hinged external fixation | - | Unilateral | Stable | Good |
| Said and Learmonth (5) | 14 months | 2-stage ligament reconstruction and casting | - | Unilateral subluxation | Stable | - |
| Saini et al. (6) | 3 months | PCL reconstruction and MCL repair + external fixation | 0 to 90 | Unilateral | Stable | Good |
| Karn et al. (1) | 2 months | Open reduction and external fixation | 5 to 70 | Unilateral | Stable | Good |
| Vicente-Guillen et al. (2) | 50 months | Arthrodesis | 0 | Unilateral | Stable | Satisfactory |
| Leonardi et al. (10) | 3 years | Patient refused treatment | - | Unilateral | - | - |
| Jabalamehi et al. (11) | 3 cases Case 1: 6 years Case 2: 8 years Case 3: 6 months | Hinged TKA | Case 1: 0 to 110 Case 2: 0 to 94 Case 3: 0 to 90 | All cases: Unilateral | Stable | Satisfactory |
| Our patient | 2 months | Open reduction and external fixation | 0 to 95 | Bilateral | Short term: stable Long term: right side: stable, left side: unstable | |

ROM: Range of motion; TKA: Total knee arthroplasty; PCL: Posterior cruciate ligament; MCL: Medial collateral ligament

Our patient's final result was good in short term; it seems that in this rare condition, by meticulous and careful soft tissue (subperiosteal) release, good results as no hesitancy in complete release, maximal possible repair of ligaments and capsular attachment, external fixation in reduced position, and gradual regaining of ROM have been achieved. Findings of our patient after 5 years indicate that it would be better if we performed ligament reconstruction after achieving knee ROM.

Reporting the long-term results of different treatment options performed in cases of old unreduced knee dislocation may help orthopedic surgeons make optimal decisions.

Conclusion

Open reduction, repair of torn ligaments, and external fixation was the effective treatment in regaining ROM and stability in a patient who had bilateral unreduced knee dislocations of two months duration. After five years, the patient had satisfactory function, but radiographs showed persistent posterior subluxation of one knee and some bone loss of the tibia in the other.

Conflict of Interest

The authors declare no conflict of interest in this study.

Acknowledgments

None.

References

1. Karn NK, Khanal GP, Singh MP. Long-standing unreduced anterior dislocation of the knee-a case report. *Internet Journal of Medical Update-EJOURNAL*. 2010;5(1):51-3. doi: [10.4314/ijmu.v5i1.49295](https://doi.org/10.4314/ijmu.v5i1.49295).
2. Vicente-Guillen P, Figa-Mataro J, Coloma-Bellver J. Long-standing unreduced dislocation of the knee. A case report. *Int Orthop*. 1998;22(4):275-6. doi: [10.1007/s002640050259](https://doi.org/10.1007/s002640050259). [PubMed: [9795820](https://pubmed.ncbi.nlm.nih.gov/9795820/)]. [PubMed Central: [PMC3619615](https://pubmed.ncbi.nlm.nih.gov/PMC3619615/)].
3. Chen HC, Chiu FY. Chronic knee dislocation treated with arthroplasty. *Injury Extra*. 2007;38(8):258-61.
4. Richter M, Lobenhoffer P. Chronic posterior knee dislocation: Treatment with arthrolysis, posterior cruciate ligament reconstruction and hinged external fixation device. *Injury*. 1998;29(7):546-9. doi: [10.1016/s0020-1383\(98\)00095-3](https://doi.org/10.1016/s0020-1383(98)00095-3). [PubMed: [10193500](https://pubmed.ncbi.nlm.nih.gov/10193500/)].
5. Said HG, Learmonth DJ. Chronic irreducible posterolateral knee dislocation: Two-stage surgical approach. *Arthroscopy*. 2007;23(5):564. doi: [10.1016/j.arthro.2005.12.046](https://doi.org/10.1016/j.arthro.2005.12.046). [PubMed: [17478296](https://pubmed.ncbi.nlm.nih.gov/17478296/)].
6. Saini R, Mootha AK, Goni VG, Dhillon MS. Neglected irreducible posterolateral knee dislocation. *Indian J Orthop*. 2010;44(4):468-70. doi: [10.4103/0019-5413.69323](https://doi.org/10.4103/0019-5413.69323). [PubMed: [20924494](https://pubmed.ncbi.nlm.nih.gov/20924494/)]. [PubMed Central: [PMC2947740](https://pubmed.ncbi.nlm.nih.gov/PMC2947740/)].
7. Simonian PT, Wickiewicz TL, Hotchkiss RN, Warren RF. Chronic knee dislocation: Reduction, reconstruction, and application of a skeletally fixed knee hinge. A report of two cases. *Am J Sports Med*. 1998;26(4):591-6. doi: [10.1177/03635465980260042201](https://doi.org/10.1177/03635465980260042201). [PubMed: [9689385](https://pubmed.ncbi.nlm.nih.gov/9689385/)].
8. Henshaw RM, Shapiro MS, Oppenheim WL. Delayed reduction of traumatic knee dislocation. A case report and literature review. *Clin Orthop Relat Res*. 1996;(330):152-6. doi: [10.1097/00003086-199609000-00018](https://doi.org/10.1097/00003086-199609000-00018). [PubMed: [8804285](https://pubmed.ncbi.nlm.nih.gov/8804285/)].
9. Petrie RS, Trousdale RT, Cabanela ME. Total knee arthroplasty for chronic posterior knee dislocation: Report of 2 cases with technical considerations. *J Arthroplasty*. 2000;15(3):380-6. doi: [10.1016/s0883-5403\(00\)90854-4](https://doi.org/10.1016/s0883-5403(00)90854-4). [PubMed: [10794237](https://pubmed.ncbi.nlm.nih.gov/10794237/)].
10. Leonardi F, Zorzan A, Palermo A, Molfetta L. Neglected posterior knee dislocation: An unusual case report. *Joints*. 2017;5(4):253-5. doi: [10.1055/s-0037-1607219](https://doi.org/10.1055/s-0037-1607219). [PubMed: [29270565](https://pubmed.ncbi.nlm.nih.gov/29270565/)]. [PubMed Central: [PMC5738492](https://pubmed.ncbi.nlm.nih.gov/PMC5738492/)].
11. Jabalameli M, Bagherifard A, Hadi H, Askari A, Ghaffari S. Total knee arthroplasty for chronic anterior knee dislocation. *Clin Med Insights Case Rep*. 2018;11:1179547618782882. doi: [10.1177/1179547618782882](https://doi.org/10.1177/1179547618782882). [PubMed: [29977119](https://pubmed.ncbi.nlm.nih.gov/29977119/)]. [PubMed Central: [PMC6024489](https://pubmed.ncbi.nlm.nih.gov/PMC6024489/)].