

A New Pattern of Distal Femoral Unicondylar Fracture in a Middle-Aged Man

Hadi Kalantar^{1*}, Soroush Baghdadi¹, Mohammadjavad Dehghani-Firoozabadi², Saeed Panahi² and Sareh Moslemi³

¹ Assistant Professor and Orthopedic Surgeon, Joint Reconstruction Research Center, Tehran University of Medical Sciences, Tehran, Iran

² Orthopedic Surgeon, Joint Reconstruction Research Center, Tehran University of Medical Sciences, Tehran, Iran

³ Radiologist, Department of Radiology, Imam Khomeini Hospital Complex, Tehran University of Medical Sciences, Tehran, Iran

*Corresponding author: Seyyed Hadi Kalantar; Department of Orthopedic Surgery, Imam-Khomeini Hospital, Tehran University of Medical Sciences, Tehran, Iran. Tel: +98-9126110015, Email: hadikalantar4@gmail.com

Received 2018 February 15; Revised 2018 April 19; Accepted 2018 June 02

Abstract

Background: Distal femoral fractures are not common among all fractures and the incidence rises with age. While this kind of fracture is usually caused by low-energy trauma in the elderly, there are many known fracture patterns. We encountered a new pattern of fracture in a middle-aged man.

Case Presentation: A 56-year-old obese man presented to our hospital with direct trauma from a motor car accident. We encountered a bizarre pattern of distal femoral fracture, which was a biplanar unicondylar fracture in medial condyle of the femur through physal remnant. This fracture was similar to the pattern of Salter-Harris type III fracture and unicondylar type of T-type simple articular epiphyseal fracture in Association for Osteosynthesis/Orthopaedic Trauma Association (AO/OTA) classification (type 43.C1.3). The fracture was fixed with two 7.3mm cannulated screws.

Conclusions: A direct trauma to the distal femur can result in different fracture patterns. In our case, a fracture through physal remnant of distal femur has been occurred in a morbidly obese patient with radiographic signs of osteoarthritis (OA). We hypothesize that the conduction of axial and anterior to posterior forces through the weak epiphyseal line in a patient can cause a new pattern of fracture similar to AO/OTA type 43.C1.3.

Keywords: Femur; Femoral Fractures; Intra-Articular Fractures; Classification

Citation: Kalantar H, Baghdadi S, Dehghani-Firoozabadi M, Panahi S, Moslemi S. A New Pattern of Distal Femoral Unicondylar Fracture in a Middle-Aged Man. *J Orthop Spine Trauma* 2018; 4(3): 65-8.



Background

Distal femoral fractures account for one percent of all fractures and three to six percent of femoral fractures. Although, the incidence increases with age, this type of fracture follows a bimodal distribution; the main mechanism of fracture is high-energy trauma in younger patients and low-energy trauma in the elderly (1, 2).

We hereby present a case of a middle-aged man who was referred with an unusual biplanar unicondylar distal femoral fracture.

Case Presentation

A 56-year-old obese [body mass index (BMI) = 40 kg/m²] man was admitted to our institution following a motor vehicle accident. He was mainly complaining of severe right knee pain. His right knee was swollen and massive ecchymosis was noted on the medial side of his knee. On X-ray, a unique fracture pattern in the right distal femur was noted (Figures 1 and 2).

Computed tomography (CT) scan revealed that the fracture was consisting of a vertical intra-articular line extending up to the physis remnant and a horizontal line through the medial condyle, similar to a Salter-Harris type III fracture in the pediatrics (Figures 3-5).

The fracture was non-comminuted and minimally-displaced. On the next day, percutaneous fixation of the fracture was performed and fixation was achieved using

two 7.3mm partial-threaded cannulated screws. Reduction was anatomic on multiple projections.

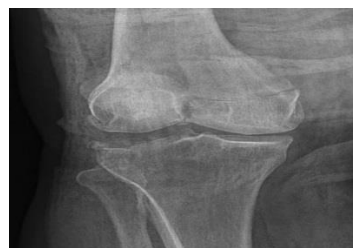

Figure 1. Anteroposterior (AP) x-ray of the knee joint showing distal femoral fracture

Post-operative and follow-up radiographs were satisfactory (Figures 6 and 7).

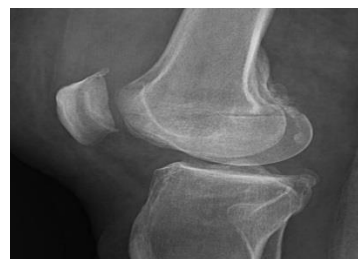

Figure 2. Lateral x-ray of the knee joint showing distal femoral fracture

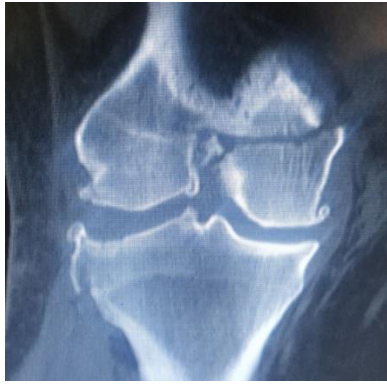

Figure 3. Coronal view cut of computed tomography (CT) scan showing unusual fracture pattern similar to Salter-Harris type III fracture in children

There was also a tibial plateau lateral side depression fracture which was less than 1 cm. Early range of motion (ROM) was initiated. Toe-touch weight-bearing was started after a week and full weight-bearing was allowed after 8 weeks. At 3rd month post-surgery, the patient walked cane-free and returned to his previous level of activity.

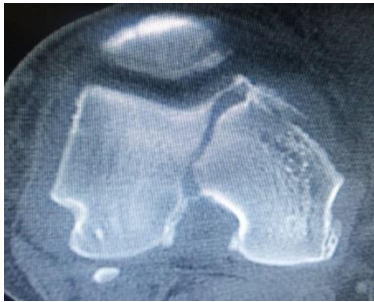


Figure 4. Axial view cut of computed tomography (CT) scan showing unusual fracture pattern similar to Salter-Harris type III fracture in children

Discussion

Distal femoral fractures are relatively common injuries with a bimodal pattern of distribution.

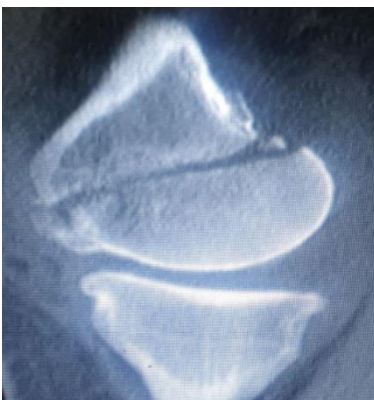

Figure 5. Sagittal view cut of computed tomography (CT) scan showing unusual fracture pattern similar to Salter-Harris type III fracture in children

Although low-energy injuries are common among the elderly with this fracture, high-energy injuries are not uncommon in the elderly with distal femoral fractures (3).

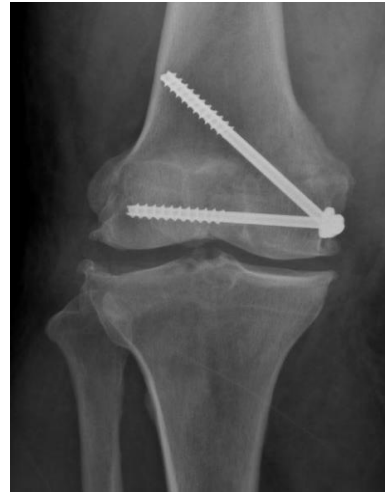

Figure 6. Post-operative anteroposterior (AP) x-ray of the patient's knee showing anatomically-reduced fracture fixed with two 7.3 mm cannulated screws

The rich musculature of the area leads to various fracture and deformity patterns. However, as a rule of thumb, quadriceps tends to shorten, adductors and iliotibial band (ITB) cause varus and valgus, respectively, and gastrocnemius may cause a posterior apex deformity at the fracture level (1, 4, 5).

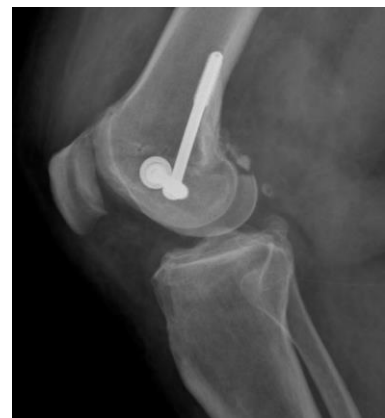

Figure 7. Post-operative lateral x-ray of the patient's knee showing anatomically-reduced fracture fixed with two 7.3 mm cannulated screws

The treatment of distal femoral fractures has evolved considerably in the last three decades. However, it often poses a challenge to the surgeon and the patient. Achieving a satisfactory result relies on a precise preoperative planning, concomitant treatment of possible comorbidities, and rigorous rehabilitation. Many researchers have attempted to classify distal femoral fractures, but three classifications are of clinical importance: Neer classification presented in 1967, Seinsheimer classification in 1980, and Association for Osteosynthesis/Association for the Study of Internal Fixation (AO/ASIF) classification presented in 1990 (6).

Neer et al. classified fractures in three groups (7). Group I consists of minimally-displaced fractures, group II constitutes fractures with displacement of the medial or lateral condyles, and group III with concomitant supracondylar or femoral shaft fractures.

Seinsheimer described a more complex 4-type

classification (8): type I, non-displaced fractures with less than 2 mm of displacement, type II, distal metaphyseal extra-articular fractures, type III, fractures with the involvement of intercondylar notch and separate fragments, and type IV, intra-articular fractures with three subgroups for medial condyle, lateral condyle, and comminuted fractures (6).

The above-mentioned classifications are primarily of historical interest and not used nowadays, as they tend to overlook fracture lines in the sagittal plane and do not give prognostic information on various fracture types.

AO/ASIF classification is the standard system of describing fracture types. The continuous re-evaluation of this system, having prognostic significance and being an internationally-accepted language of fracture definition, has led to its widespread use. AO/ASIF places distal femoral fractures in 3 main groups: A (extra-articular), B (partial-articular), and C (complete articular). Three subgroups have been described for type A fractures: A1 (simple), A2 (metaphyseal wedge), and A3 (complex metaphyseal fracture). Type C is subsequently subclassified based on metaphyseal and articular comminution.

Partial articular fractures of the distal femur (type B AO/ASIF) are rare and are mostly the result of a direct impact on a flexed knee in a weight-bearing position. The primary fracture line typically begins in the lateral or medial intercondylar-trochlear groove. Extension in the sagittal plane will cause a type B1 or B2 fracture for lateral or medial condyle, respectively. Extension in the coronal plane can result in displacement of the posterior fragment of the condyle, which is known as "Hoffa fracture" and counts for type B3 (9).

Type C fractures, however, are classified as C1 to C3 based on the site of comminution. In C1, fractures are complete articular, simple articular, and simple metaphyseal. The fracture can be T- or Y-shaped as with minimal or marked displacement. Our case was T-shaped epiphyseal, making it look like a subtype C1.1 to C1.3. In our patient, it seems that the distal femoral fracture is similar to C1.3 fracture in which only one condyle has a fracture and is seen as an L-shaped fracture in coronal view and horizontal fracture in sagittal view. However, it can be subcategorized as C1.4 by the name of complete articular, simple articular, and epiphyseal unicondylar fracture.

In the specific case presented here, the fracture line begins from intercondylar part of medial condyle in the sagittal plane and extends in the axial plane. This creates a fracture identical to a Salter-Harris type III fracture in the pediatric population. A fracture in these planes in adults is extremely rare, and based on our knowledge, has not been reported in the English literature. This fracture pattern is common in pediatric population, but a distal femoral fracture through the physeal remnant has not been reported in the skeletally mature patients.

Treatment of a distal femoral fracture should be individualized to the specific "personality" of the fracture. Type of the fracture, displacement, and comminution (if present) should be taken into consideration when planning a treatment strategy. Non-operative management is seldom the treatment of choice and is only reserved for non-ambulatory patients with severe comorbidities (1, 4). Multiple devices have been used for the fixation of distal femoral fractures, including locking and non-locking plates, intramedullary nails, fixed angle devices, and arthroplasty techniques (9), which are out of the scope of this paper. Of note is the role of external fixation for fractures with extensive soft tissue damage,

and keeping in mind the high-energy nature of many of these fractures may prove beneficial as temporary fixation devices (10, 11).

One of the advantages of the AO/ASIF classification is that it can be a guide for choosing the most appropriate fixation device and technique. Namely, in type C fractures, it necessitates anatomic rigid fixation for the articular fragments and compression or bridge plating for the metaphyseal segment (1).

Several studies have recommended utilizing at least two 6.5mm cancellous screws for fixation of AO type B fractures (9, 12). Khalafi et al. compared 6.5mm with 3.5mm screws and concluded that in order to achieve the same stability, at least four 3.5mm cortical screws should be used instead of two 6.5mm screws (12).

Considering the fracture pattern, displacement, and minimal comminution along with previous symptoms of osteoarthritis (OA) and a probable knee arthroplasty in the future, a minimally-invasive percutaneous fixation technique was used. Two 7.3mm cannulated screws were utilized, each perpendicular to a primary fracture line. Early ROM exercises were begun, and considering the risk of a thromboembolic incidence, early toe-touch weight-bearing was allowed. At 8 weeks, with evidence of bony union on plain radiography, full weight-bearing was allowed. Finally, the patient regained his preoperative ROM and returned to his previous activities.

We believe that a fracture through the physeal remnant, alike to what has been described as a Salter-Harris type III fracture, was observed in this case due to the sclerosis present because of OA. In a non-OA joint, the metaphyseal fracture line would typically be oblique, ending above the physeal remnant. In this case, a new fracture pattern happened due to unknown reason; this can have many biomechanical explanations such as distribution of energy through weak epiphysis, but it is only a hypothesis and needs further investigations to be proved. The authors cannot overemphasize the role of individualizing treatment for the "personality" of each distinct distal femoral fracture, as described in many articles.

Conflict of Interest

The authors declare no conflict of interest in this study.

Acknowledgments

Special thanks to our beloved deceased colleague, orthopedics resident Dr. Rasoul Ghaedi who helped us in collecting data on this case.

References

1. Gangavalli AK, Nwachuku CO. Management of distal femur fractures in adults: An overview of options. *Orthop Clin North Am.* 2016;47(1):85-96 .doi: [10.1016/j.ocl.2015.08.011](https://doi.org/10.1016/j.ocl.2015.08.011). [PubMed: [26614924](https://pubmed.ncbi.nlm.nih.gov/26614924/)].
2. Dugan TR, Hubert MG, Siska PA, Pape HC, Tarkin IS. Open supracondylar femur fractures with bone loss in the polytraumatized patient-Timing is everything! *Injury.* 2013;44(12):1826-31. doi: [10.1016/j.injury.2013.03.018](https://doi.org/10.1016/j.injury.2013.03.018). [PubMed: [23601115](https://pubmed.ncbi.nlm.nih.gov/23601115/)].
3. Court-Brown CM, Caesar B. Epidemiology of adult fractures: A review. *Injury.* 2006;37(8):691-7. doi: [10.1016/j.injury.2006.04.130](https://doi.org/10.1016/j.injury.2006.04.130). [PubMed: [16814787](https://pubmed.ncbi.nlm.nih.gov/16814787/)].
4. Trillat A, Dejour H, Bost J, Nourissat C. Unicondylar fractures of the femur. *Rev Chir Orthop Reparatrice Appar. Mot* 1975;61(7):611-26. [PubMed: [133422](https://pubmed.ncbi.nlm.nih.gov/133422/)].
5. Marsh JL, Slongo TF, Agel J, Broderick JS, Creevey W, DeCoster TA, et al. Fracture and dislocation classification

- compendium-2007: Orthopaedic Trauma Association classification, database and outcomes committee. *J Orthop Trauma*. 2007;21(10 Suppl):S1-133. doi: [10.1097/00005131-200711101-00001](https://doi.org/10.1097/00005131-200711101-00001). [PubMed: [18277234](https://pubmed.ncbi.nlm.nih.gov/18277234/)].
6. Raja BK, Arun KC, Dheenadayalan J. Classification of distal femur fractures and their clinical relevance. *Trauma International*. 2016;2(1):3-6.
 7. Neer CS, Grantham SA, Shelton ML. Supracondylar fracture of the adult femur. A study of one hundred and ten cases. *J Bone Joint Surg Am*. 1967;49(4):591-613. [PubMed: [6025996](https://pubmed.ncbi.nlm.nih.gov/6025996/)].
 8. Seinsheimer F 3rd. Fractures of the distal femur. *Clin Orthop Relat Res*. 1980;(153):169-79. [PubMed: [7449211](https://pubmed.ncbi.nlm.nih.gov/7449211/)].
 9. Bel JC, Court C, Cogan A, Chantelot C, Pietu G, Vandenbussche E. Unicondylar fractures of the distal femur. *Orthop Traumatol Surg Res*. 2014;100(8):873-7. doi: [10.1016/j.otsr.2014.10.005](https://doi.org/10.1016/j.otsr.2014.10.005). [PubMed: [25453913](https://pubmed.ncbi.nlm.nih.gov/25453913/)].
 10. Haidukewych GJ. Temporary external fixation for the management of complex intra- and periarticular fractures of the lower extremity. *J Orthop Trauma*. 2002;16(9):678-85. doi: [10.1097/00005131-200210000-00012](https://doi.org/10.1097/00005131-200210000-00012). [PubMed: [12368651](https://pubmed.ncbi.nlm.nih.gov/12368651/)].
 11. Arazi M, Memik R, Ogun TC, Yel M. Ilizarov external fixation for severely comminuted supracondylar and intercondylar fractures of the distal femur. *J Bone Joint Surg Br*. 2001;83(5):663-7. doi: [10.1302/0301-620x.83b5.11520](https://doi.org/10.1302/0301-620x.83b5.11520). [PubMed: [11476301](https://pubmed.ncbi.nlm.nih.gov/11476301/)].
 12. Khalafi A, Hazelwood S, Curtiss S, Wolinsky P. Fixation of the femoral condyles: A mechanical comparison of small and large fragment screw fixation. *J Trauma*. 2008;64(3):740-4 doi: [10.1097/TA.0b013e318165c12a](https://doi.org/10.1097/TA.0b013e318165c12a). [PubMed: [18332817](https://pubmed.ncbi.nlm.nih.gov/18332817/)].