

Primary Long Distal Fitting Bipolar Hemiarthroplasty for Unstable Intertrochanteric Fracture in Elderly Patients

Reza Zandi¹, Amin Karimi¹, Mehrdad Sadighi², Mohammadreza Minator-Sajjadi¹, Mohammad Ali Okhovatpour¹, Adel Ebrahimpour^{1,*} and Mehdi Fazeli³

¹ Assistant Professor, Department of Orthopedics, Taleghani Hospital Research Development Committee, Shahid Beheshti University of Medical Sciences, Tehran, Iran

² Assistant Professor, Department of Orthopedics, Shohada Tajrish Hospital, School of Medicine, Shahid Beheshti University of Medical Sciences, Tehran, Iran

³ Orthopedic Surgeon, Rasool Akram Hospital, Kalaleh, Iran

*Corresponding author: Adel Ebrahimpour; Assistant Professor, Department of Orthopedics, Taleghani Hospital Research Development Committee, Shahid Beheshti University of Medical Sciences, Tehran, Iran. Tel: +98-9121242388, Email: a.ebrahimpour@sbmu.ac.ir

Received 2018 February 05; Revised 2018 March 13; Accepted 2018 April 29

Abstract

Background: Intertrochanteric fracture in elderly patients is a frequent problem and is becoming more prominent as the proportion of this injury increases. The ideal treatment for an unstable intertrochanteric femoral fracture in senile osteoporotic patients remains controversial.

Methods: Seventy-five patients (over 70 years of age) with unstable intertrochanteric fractures were randomized into three groups and treated with three different procedures including long-stem bipolar hemiarthroplasty, proximal femoral nail (PFN), and dynamic hip screw (DHS). Estimated blood loss, duration of the operation, time of full weight-bearing, and Harris Hip Score (HHS) were determined for each patient.

Results: Surgical time was longer in hemiarthroplasty group, but the HHS and time from surgery to mobilization in these patients were significantly superior to the two other groups. PFN group had the lowest bleeding volume during surgery. Revision surgery was lower in hemiarthroplasty compared to the internal fixation, although it was not statistically significant.

Conclusions: In elderly patients with an unstable intertrochanteric femoral fracture who cannot tolerate long immobilization time, primary long distal fitting bipolar hemiarthroplasty is a valid treatment option for faster mobilization, good clinical efficacy, and satisfactory functional outcome.

Keywords: Hemiarthroplasty; Hip Fracture; Aged

Citation: Zandi R, Karimi A, Sadighi M, Minator-Sajjadi M, Okhovatpour MA, Ebrahimpour A, et al. **Primary Long Distal Fitting Bipolar Hemiarthroplasty for Unstable Intertrochanteric Fracture in Elderly Patients.** *J Orthop Spine Trauma* 2018; 4(3): 42-7.



Background

Intertrochanteric fracture is a frequent problem in elderly patients that is becoming more prominent as the proportion of this injury increases (1). As high as 20% mortality rate has been reported in the first year after surgical treatment of unstable intertrochanteric fracture in old patients (2-6). The ideal treatment for an unstable intertrochanteric fracture in elderly patients with osteoporosis still remains controversial (7-10).

Today, the role of gamma nail in management of Intertrochanteric fracture has received wide attention and has shown promising results in cases of unstable hip fractures. Calcar defect and osteoporosis in these patients can lead to the failure of internal fixation, which necessitates conversion to hip arthroplasty (11, 12). Primary hip arthroplasty in cases of intertrochanteric fractures has been recommended by some articles (13-16). Cemented stems have been used more frequently than cementless ones for treating unstable intertrochanteric fractures in patients with osteoporosis (14-16). However, some studies showed that the use of acrylic cement in old patients was associated with an increased risk of cardiopulmonary complications (17-22).

The ideal cementless stem design for unstable intertrochanteric fractures in elderly patients with osteoporosis should have enough length and extensive surface coating to obtain optimal stability at the

subtrochanteric level (10, 18, 19).

In this prospective randomized study, we evaluated the use of a long-stem cementless replacement hemiarthroplasty compared with the proximal femoral nail (PFN) and dynamic hip screw (DHS) in elderly patients with unstable intertrochanteric fractures.

Methods

We enrolled all elderly patients (> 70 years of age) who were referred to our level 1 trauma center during 2016-2018, with unstable intertrochanteric fractures. We included the patients with type A2 intertrochanteric fracture according to the Arbeitsgemeinschaft für Osteosynthesefragen (AO) Foundation/Orthopedic Trauma Association (AO/OTA) classification, all of whom were able to walk independently before the recent fracture and had at least one-year post-operation follow-up. We excluded patients with pathological fractures or any previous hip surgeries.

The patients were randomized into equal three treatment groups by means of computer-generated random numbers. Study groups were as follows: group I: long-stem cementless bipolar hemiarthroplasty (Zimmer Biomet), group II: intramedullary nail (PFN), and group III: DHS.

All operations were performed by a single experienced surgeon with an interval of 0 to 5 days after initial injury. Use of prophylactic antibiotics was the same in all three

groups. Prophylaxis for deep venous thrombosis (DVT) was applied in all groups. Before entering the study, written consent was obtained from each patient. The Institutional Ethics Committee of Taleghani Hospital, affiliated to Shahid Beheshti University of Medical Sciences, Tehran, Iran, approved all the procedures, and the study was registered in the Iranian Registry of Clinical Trials (IRCT).

Operative Technique

A. Cementless Long-Stem Hemiarthroplasty: We used a direct lateral approach (23). The appropriate length of the stem was determined preoperatively by comparing the center of the injured hip with the center of the contralateral hip. The Wagner SL Revision Stem is available in three lengths (19, 22.5, and 26 cm) to accommodate for limb length and femoral offset (24). We used devices with 19 or 22.5 cm length in all patients (Figure 1). The fractured greater trochanter was attached to the prosthesis with a fiber wire. We occasionally placed additional wires through the two-wire passage portals on the lateral side of the stem.

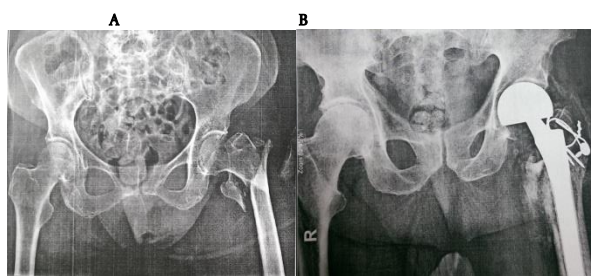


Figure 1. A) Unstable Intertrochanteric Fracture in a 78-year-old Woman; B) Radiography of Hip Joints 3 Months after Long-Stem Cementless Bipolar Hemiarthroplasty

B. PFN: After closed reduction on the fracture table, the stainless steel PFN with 240 mm length was inserted percutaneously under fluoroscopic control. The lower limb was placed in slight adduction to facilitate the insertion of the nail. After reaming the proximal part of the femur with a 17-mm reamer, the guidewire for the neck screw was introduced through the radiolucent aiming arm into the femoral neck centrally, confirmed on both anteroposterior (AP) and lateral radiographs (25).

C. DHS: After closed reduction on the fracture table, a lateral incision was made and reduction of the anteromedial cortex (AMC) was checked directly and then provisionally fixed with K-wire in an anatomical position. The K-wire with an appropriate angle guide was centered on the AP and lateral views and introduced to the femoral neck at the level of the lesser trochanter (26).

Once the lag screw was selected, it was inserted with a cannulated attachment over the guidewire and seated within 5 to 10 mm of subchondral bone. The four-hole plate was attached to the lag screw.

Postoperative Protocol

Patients were allowed to get out of bed on the second postoperative day and to walk as soon as possible. They were allowed to bear full weight as tolerated with the aid of a walker for six weeks postoperatively. Then, they were transitioned to a single cane or crutch in the second six weeks.

Follow-up evaluation was performed at 6 weeks, 3 months, 6 months, and 12 months postoperatively, and yearly thereafter. Three patients died in the first

postoperative year and were excluded from the study. Revision surgeries led to the exclusion of further three patients. AP and lateral radiographs of the affected hip were obtained postoperatively and at each follow-up visit. The radiographic evaluation was performed by two independent observers. We classified the quality of the reduction of the fracture as anatomical ($< 5^\circ$ of varus or valgus and/or anteversion or retroversion), acceptable (5° to 10°), or poor ($> 10^\circ$) (27). In the hemiarthroplasty group, change in the stem position, progressive subsidence of stem exceeding 3 mm, a continuous radiolucent line around the stem wider than 2 mm, widening of the femoral canal, and large distal bone pedestal formation were noticed as the signs of loosening.

We recorded any intraoperative and postoperative complications related to the implant, the estimated blood loss, the number of units of blood that were transfused, the duration of the operation, and the time of full weight-bearing for each patient.

Evaluation of functional results was performed by Harris Hip Score (HHS) (28). It includes four domains: pain, physical function, deformity, and range of motion with a total of 100 points. Patients are divided into four functional levels according to their score: poor (< 70), moderate (70-79), good (80-89), and the great (90-100).

We used chi-square test for qualitative variables (gender and side), Kruskal-Wallis test for non-parametric quantitative variables (surgery time, weight-bearing time, bleeding), and analysis of variance (ANOVA) for comparing age and HHS among the groups. For pairwise comparison, Mann-Whitney test was used for non-parametric variables and Tukey's test for variables with normal distribution.

Results

Seven patients were excluded from the study: 3 because of death (one death in each group) and 4 as a result of incomplete follow-up (all in PFN group). The demographic characteristics of all patients (24 patients in group 1, 20 patients in group 2, and 24 patients in group 3) were compared (Table 1). No significant difference was observed among the three groups in the patients' characteristics, including gender, age, and side (Table 1).

Table 1. Demographics among the groups

Demographics	Bipolar hemiarthroplasty (n=24)	PFN (n=20)	DHS (n=24)	P-value
Age (year)	78.6 ± 6.2	80.3 ± 6.0	80.8 ± 6.0	0.438
Gender				0.823
Male	17 (70.8)	13 (65.0)	15 (62.5)	
Female	7 (29.2)	7 (35.0)	9 (37.5)	
Side				0.114
Right	10 (41.7)	10 (50.0)	17 (70.8)	
Left	14 (58.3)	10 (50.0)	7 (29.2)	

Data are presented as mean ± standard deviation (SD) or number and percentage
PFN: Proximal femoral nail; DHS: Dynamic hip screw

There was a significant difference in surgical time (bipolar hemiarthroplasty: 111.0 ± 13.9 minutes, PFN: 87.1 ± 12.4 minutes, and DHS: 87.1 ± 25.3 minutes, $P < 0.0001$). Pairwise comparison showed a significant difference between groups. Hemiarthroplasty group had the longest surgical time ($P < 0.0001$), but there was no significant difference between groups 2 and 3 ($P = 0.924$).

Difference in bleeding during surgery was significant between the groups (bipolar hemiarthroplasty: 523 ± 125 ml, PFN: 653 ± 116 ml, and DHS: 269 ± 108 ml, $P < 0.0001$). DHS

had the least bleeding during surgery ($P = 0.0010$); thus, bleeding in hemiarthroplasty group was less than PFN group ($P < 0.0001$).

Clinical Results

The mean weight-bearing time was 1 day for bipolar hemiarthroplasty group, 8.90 ± 7.90 days for DHS group, and 16.10 ± 2.83 days for PFN group (Figure 2). All of the patients in hemiarthroplasty group were able to walk full weight with walker aid in the first post-operative day. There was a significant difference in weight-bearing time among groups ($P < 0.0001$). Pairwise comparison showed a significant difference between group 1 vs. 2 ($P < 0.0001$), group 1 vs. 3 ($P < 0.0001$), and group 2 vs. 3 ($P = 0.0060$).

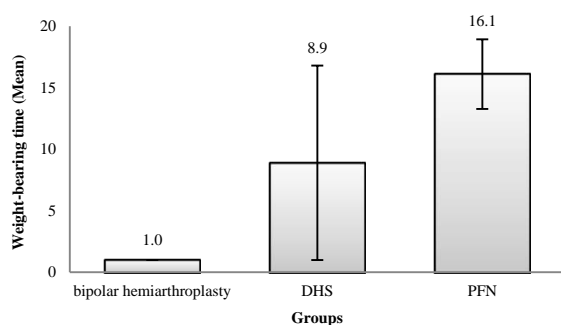


Figure 2. Weight-bearing time among the groups
PFN: Proximal femoral nail; DHS: Dynamic hip screw

The mean HHS was 79.0 ± 11.8 for bipolar hemiarthroplasty group, 62.0 ± 13.7 for PFN group, and 60.2 ± 22.4 for DHS group (Figure 3). There was a significant difference among the three groups ($P = 0.0001$). HHS was significantly higher in hemiarthroplasty group than two others ($P = 0.0010$), but there was no significant difference between groups 2 and 3 ($P = 0.9370$).

Moreover, despite rehabilitation program for all of the patients in the postoperative period, only 26.1% of patients in hemiarthroplasty group had great HHS at the last follow-up visit, and this value decreased to 13.0% in group 3 and 8.7% in group 2.

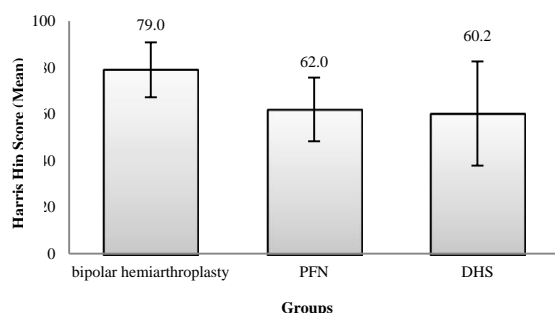


Figure 3. Harris Hip Score (HHS) among the groups
PFN: Proximal femoral nail; DHS: Dynamic hip screw

Radiological Results

We did not observe any signs of loosening in hemiarthroplasty group during the first postoperative year. Although all of the patients in groups 2 and 3 had anatomical or acceptable reduction in the first postoperative X-ray, it failed in one patient of PFN group and two patients of DHS group at 6 weeks after surgery and

resulted in a poor reduction ($> 10^\circ$ malalignment) in these patients. We observed the blade or screw cut-out in the next follow-up visit for all of these three patients, and they underwent revision surgery with total hip arthroplasty.

Complications

We did not have any surgical site infection in our patients. Moreover, no patients in hemiarthroplasty group experienced dislocation. Three patients died during follow-up (one patient in each group), which was not statistically significant ($P = 0.9880$). Revision surgery was performed in two patients in DHS group and one patient in PFN group because of fixation failure and lag screw cut-out, which was not statistically significant ($P = 0.3680$).

Discussion

There is no consensus on the best treatment method for unstable intertrochanteric fractures in elderly population. For several years, unstable intertrochanteric fractures in elderly patients have been treated by open reduction and internal fixation (ORIF). Although close reduction and fixation with intramedullary hip screw has become popular recently, poor functional outcome due to excessive collapse, loss of fixation, and lag screw cut-out is the main problem associated with internal fixation of unstable intertrochanteric fractures (29). To allow earlier postoperative weight-bearing and to decrease complications, many surgeons prefer arthroplasty especially with a calcar-replacement or diaphyseal fixation type of femoral prosthesis for the treatment of unstable trochanteric fractures in the elderly (30-32).

In this study, we tried to evaluate the outcomes of three types of intertrochanteric fracture treatment including long-stem cementless bipolar hemiarthroplasty, PFN, and DHS. The outcomes including bleeding, surgery time, weight-bearing, and the functional score showed a significant difference among these three types of surgery.

It has been demonstrated that fixation with the sliding hip screw is the gold standard treatment for stable intertrochanteric fractures. However, up to 26% complications have been reported in patients with unstable intertrochanteric fractures treated by DHS (33-35). With early studies showing fewer complications and reoperations with intramedullary devices compared to DHS, the use of these devices has become popular for unstable intertrochanteric fractures (36, 37). In 2010, Parker and Handoll conducted a systematic review of trochanteric fractures involving 3746 patients to compare the PFN with sliding hip screw. They showed that gamma nail was associated with an increased risk of fixation complication and reoperation. Also, there were no major differences between implants in mortality rate and functional outcomes (29). In our study, we found no significant difference in surgery time, functional score, fixation failure, and reoperation rate between PFN group and DHS group, but PFN group had significantly higher bleeding during surgery, and also later full weight-bearing with walker aid than DHS group.

Some authors favor the use of endoprosthesis in unstable intertrochanteric fractures in elderly patients to have less mechanical problems (16, 30). In a systematic review, Yoo et al. revealed that more studies used cemented stems instead of cementless stems in these patients (38). Because of the potential risk of poor fitting of the cementless stem in an osteoporotic bone of the

proximal femur, most of the authors recommended cemented stem to obtain immediate stability and early full weight-bearing (14-16). Cement was reported to be the factor that increased mortality due to fat embolization as a result of increased intramedullary pressure during cementation (17-22, 39, 40). Fortunately, an excellent cementless stem survival rate had been reported for hip arthroplasty after more than 5 years of follow-up in elderly patients (41, 42). Wagner SL implant is a long-stem femoral prosthesis that was originally designed for treating patients with severe bone loss in the proximal femur with a good initial and long-term stability (43).

Although we followed our patients for 12 months, we did not have any loosening with this long-stem distal fitting prosthesis in this clinical trial. Moreover, all of our patients in hemiarthroplasty group could mobilize by full weight-bearing in the first postoperative day. Thus, from a mechanical standpoint, long cementless distal fitting stem is a reliable option to treat unstable intertrochanteric fractures in elderly patients.

Early mobilization is the major factor responsible for decreasing postoperative complications in the treatment of unstable intertrochanteric fractures (44). Arthroplasty in comparison to the internal fixation is accompanied by earlier weight-bearing ability (45); unlimited weight-bearing is especially important in elderly patients who are often unable to compete with partial weight-bearing required after an internal fixation. Although the complication rate did not differ significantly amongst three groups in this study, weight-bearing was significantly earlier in hemiarthroplasty group (1 day) compared with PFN group (8.3 days) and DHS group (15.2 days).

A recent systemic review by Yoo et al. in 2017 reported that the arthroplasty group had superior functional outcomes than the internal fixation group in elderly patients with unstable intertrochanteric fractures (46). Likewise, our patients in hemiarthroplasty group significantly had a higher HHS at the final follow-up. Unfortunately, the mean HHS in PFN group (59.39) and DHS group (63.13) was below 70, demonstrating that our attempts for restoring the pre-fracture function in these patients with internal fixation were abortive.

Two main limitations of our study were the small number of patients and a short follow-up period. A long-term follow-up is barely possible in senile patients who have a short life expectancy, and as such, short-term complications seem to be more important.

Conclusion

In elderly patients with an unstable intertrochanteric femoral fracture, who are unable to tolerate long immobilization periods, primary long distal fitting bipolar hemiarthroplasty is a valid treatment option for faster mobilization, good clinical efficacy, and satisfactory functional outcome.

Conflict of Interest

The authors declare no conflict of interest in this study.

Acknowledgments

We thank the specialist surgeon who performed the surgeries.

This study has been derived from a residency dissertation (no. 174417) approved by Shahid Beheshti University of Medical Sciences.

References

- Bartucci EJ, Gonzalez MH, Cooperman DR, Freedberg HI, Barmada R, Laros GS. The effect of adjunctive methylmethacrylate on failures of fixation and function in patients with intertrochanteric fractures and osteoporosis. *J Bone Joint Surg Am.* 1985;67(7):1094-107. [PubMed: 4030829].
- Jensen JS. Trochanteric fractures. An epidemiological, clinical and biomechanical study. *Acta Orthop Scand Suppl.* 1981;188:1-100. doi: 10.3109/ort.1981.52.suppl-188.01. [PubMed: 6939295].
- Sexson SB, Lehner JT. Factors affecting hip fracture mortality. *J Orthop Trauma.* 1987;1(4):298-305. doi: 10.1097/00005131-198701040-00005. [PubMed: 3506066].
- White BL, Fisher WD, Laurin CA. Rate of mortality for elderly patients after fracture of the hip in the 1980's. *J Bone Joint Surg Am.* 1987;69(9):1335-40. [PubMed: 3440792].
- Eiskjaer S, Ostgaard SE, Jakobsen BW, Jensen J, Lucht U. Years of potential life lost after hip fracture among postmenopausal women. *Acta Orthop Scand.* 1992;63(3):293-6. doi: 10.3109/17453679209154785. [PubMed: 1609593].
- Dahl E. Mortality and life expectancy after hip fractures. *Acta Orthop Scand.* 1980;51(1):163-70. doi: 10.3109/17453678008990781. [PubMed: 7376837].
- Little NJ, Verma V, Fernando C, Elliott DS, Khaleel A. A prospective trial comparing the Holland nail with the dynamic hip screw in the treatment of intertrochanteric fractures of the hip. *J Bone Joint Surg Br.* 2008;90(8):1073-8. doi: 10.1302/0301-620X.90B8.20825. [PubMed: 18669966].
- Anglen JO, Weinstein JN. Nail or plate fixation of intertrochanteric hip fractures: Changing pattern of practice. A review of the American Board of Orthopaedic Surgery Database. *J Bone Joint Surg Am.* 2008;90(4):700-7. doi: 10.2106/JBJS.G.00517. [PubMed: 18381305].
- Aros B, Tosteson AN, Gottlieb DJ, Koval KJ. Is a sliding hip screw or im nail the preferred implant for intertrochanteric fracture fixation? *Clin Orthop Relat Res.* 2008;466(11):2827-32. doi: 10.1007/s11999-008-0285-5. [PubMed: 18465180]. [PubMed Central: PMC2565060].
- Kim SY, Kim YG, Hwang JK. Cementless calcar-replacement hemiarthroplasty compared with intramedullary fixation of unstable intertrochanteric fractures. A prospective, randomized study. *J Bone Joint Surg Am.* 2005;87(10):2186-92. doi: 10.2106/JBJS.D.02768. [PubMed: 16203881].
- Zhang B, Chiu KY, Wang M. Hip arthroplasty for failed internal fixation of intertrochanteric fractures. *J Arthroplasty.* 2004;19(3):329-33. doi: 10.1016/j.arth.2003.10.010. [PubMed: 15067646].
- Hsu CJ, Chou WY, Chiou CP, Chang WN, Wong CY. Hemiarthroplasty with supplemental fixation of greater trochanter to treat failed hip screws of femoral intertrochanteric fracture. *Arch Orthop Trauma Surg.* 2008;128(8):841-5. doi: 10.1007/s00402-007-0483-8. [PubMed: 18034254].
- Shahrezaee M, Okhovatpour MA, Banasiri M, Sharifzadeh SR. Studying the effects of primary arthroplasty on post-treatment results among elderly patients with pertrochanteric fracture. *Clin Pract.* 2018;8(1):1055. doi: 10.4081/cp.2018.1055. [PubMed: 29441191]. [PubMed Central: PMC5806500].
- Grimsrud C, Monzon RJ, Richman J, Ries MD. Cemented hip arthroplasty with a novel cerclage cable technique for unstable intertrochanteric hip fractures. *J Arthroplasty.* 2005;20(3):337-43. doi: 10.1016/j.arth.2004.04.017. [PubMed: 15809952].
- Rodop O, Kiral A, Kaplan H, Akmaz I. Primary bipolar hemiprosthesis for unstable intertrochanteric fractures. *Int*

- Orthop.* 2002;26(4):233-7. doi: [10.1007/s00264-002-0358-0](https://doi.org/10.1007/s00264-002-0358-0). [PubMed: [12185526](https://pubmed.ncbi.nlm.nih.gov/12185526/)]. [PubMed Central: [PMC3620945](https://pubmed.ncbi.nlm.nih.gov/PMC3620945/)].
16. Chan KC, Gill GS. Cemented hemiarthroplasties for elderly patients with intertrochanteric fractures. *Clin Orthop Relat Res.* 2000;(371):206-15. doi: [10.1097/00003086-200002000-00025](https://doi.org/10.1097/00003086-200002000-00025). [PubMed: [10693568](https://pubmed.ncbi.nlm.nih.gov/10693568/)].
 17. Parvizi J, Erath MH, Lewallen DG. Thirty-day mortality following hip arthroplasty for acute fracture. *J Bone Joint Surg Am.* 2004;86(9):1983-8. doi: [10.2106/00004623-200409000-00017](https://doi.org/10.2106/00004623-200409000-00017). [PubMed: [15342761](https://pubmed.ncbi.nlm.nih.gov/15342761/)].
 18. Chen YT, Chen WM, Lee KS, Huang CK, Chiang CC, Chen TH. Diaphyseal locking hip arthroplasty for treatment of failed fixation of intertrochanteric hip fractures. *J Arthroplasty.* 2008;23(2):241-6. doi: [10.1016/j.arth.2007.03.042](https://doi.org/10.1016/j.arth.2007.03.042). [PubMed: [18280419](https://pubmed.ncbi.nlm.nih.gov/18280419/)].
 19. Sporer SM, Obar RJ, Bernini PM. Primary total hip arthroplasty using a modular proximally coated prosthesis in patients older than 70: Two to eight year results. *J Arthroplasty.* 2004;19(2):197-203. doi: [10.1016/j.arth.2003.08.014](https://doi.org/10.1016/j.arth.2003.08.014). [PubMed: [14973863](https://pubmed.ncbi.nlm.nih.gov/14973863/)].
 20. Byrick RJ. Cement implantation syndrome: A time limited embolic phenomenon. *Can J Anaesth.* 1997;44(2):107-11. doi: [10.1007/BF03012996](https://doi.org/10.1007/BF03012996). [PubMed: [9043720](https://pubmed.ncbi.nlm.nih.gov/9043720/)].
 21. Saleh KJ, Kassim R, Yoon P, Vorlicky LN. Complications of total hip arthroplasty. *Am J Orthop (Belle Mead NJ).* 2002;31(8):485-8. [PubMed: [12216974](https://pubmed.ncbi.nlm.nih.gov/12216974/)].
 22. Fallon KM, Fuller JG, Morley-Forster P. Fat embolization and fatal cardiac arrest during hip arthroplasty with methylmethacrylate. *Can J Anaesth.* 2001;48(7):626-9. doi: [10.1007/BF03016194](https://doi.org/10.1007/BF03016194). [PubMed: [11495867](https://pubmed.ncbi.nlm.nih.gov/11495867/)].
 23. Brun OL, Sund HN, Nordsletten L, Rohrl SM, Mjaaland KE. Component placement in direct lateral vs minimally invasive anterior approach in total hip arthroplasty: Radiographic outcomes from a prospective randomized controlled trial. *J Arthroplasty.* 2019;34(8):1718-22. doi: [10.1016/j.arth.2019.04.003](https://doi.org/10.1016/j.arth.2019.04.003). [PubMed: [31053468](https://pubmed.ncbi.nlm.nih.gov/31053468/)].
 24. Zhen P, Liu J, Li X, Lu H, Zhou S. Primary total hip arthroplasty using an uncemented Wagner SL stem in elderly patients with Dorr type C femoral bone. *J Orthop Surg Res.* 2019;14(1):377. doi: [10.1186/s13018-019-1421-5](https://doi.org/10.1186/s13018-019-1421-5). [PubMed: [31752915](https://pubmed.ncbi.nlm.nih.gov/31752915/)]. [PubMed Central: [PMC6868742](https://pubmed.ncbi.nlm.nih.gov/PMC6868742/)].
 25. Sonmez MM, Camur S, Erturer E, Ugurlar M, Kara A, Ozturk I. Strategies for proximal femoral nailing of unstable intertrochanteric fractures: Lateral decubitus position or traction table. *J Am Acad Orthop Surg.* 2017;25(3):e37-e44. doi: [10.5435/JAAOS-D-15-00691](https://doi.org/10.5435/JAAOS-D-15-00691). [PubMed: [28134676](https://pubmed.ncbi.nlm.nih.gov/28134676/)].
 26. Gruss M, Traut R. Management of unstable pertrochanteric and per- to subtrochanteric femoral fractures with the dynamic hip screw. *Aktuelle Traumatol.* 1992;22(4):144-8. [PubMed: [1357932](https://pubmed.ncbi.nlm.nih.gov/1357932/)].
 27. Marmor M, Liddle K, Buckley J, Matityahu A. Effect of varus and valgus alignment on implant loading after proximal femur fracture fixation. *Eur J Orthop Surg Traumatol.* 2016;26(4):379-83. doi: [10.1007/s00590-016-1746-2](https://doi.org/10.1007/s00590-016-1746-2). [PubMed: [27120073](https://pubmed.ncbi.nlm.nih.gov/27120073/)].
 28. Harris WH. Traumatic arthritis of the hip after dislocation and acetabular fractures: Treatment by mold arthroplasty. An end-result study using a new method of result evaluation. *J Bone Joint Surg Am.* 1969;51(4):737-55. [PubMed: [5783851](https://pubmed.ncbi.nlm.nih.gov/5783851/)].
 29. Parker MJ, Handoll HH. Gamma and other cephalocondylic intramedullary nails versus extramedullary implants for extracapsular hip fractures in adults. *Cochrane Database Syst Rev.* 2010;(9):CD000093. doi: [10.1002/14651858.CD000093.pub5](https://doi.org/10.1002/14651858.CD000093.pub5). [PubMed: [20824825](https://pubmed.ncbi.nlm.nih.gov/20824825/)].
 30. Sinno K, Sakr M, Girard J, Khatib H. The effectiveness of primary bipolar arthroplasty in treatment of unstable intertrochanteric fractures in elderly patients. *N Am J Med Sci.* 2010;2(12):561-8. doi: [10.4297/najms.2010.2561](https://doi.org/10.4297/najms.2010.2561). [PubMed: [22558568](https://pubmed.ncbi.nlm.nih.gov/22558568/)]. [PubMed Central: [PMC3338223](https://pubmed.ncbi.nlm.nih.gov/PMC3338223/)].
 31. Choy WS, Ahn JH, Ko JH, Kam BS, Lee DH. Cementless bipolar hemiarthroplasty for unstable intertrochanteric fractures in elderly patients. *Clin Orthop Surg.* 2010;2(4):221-6. doi: [10.4055/cios.2010.2.4.221](https://doi.org/10.4055/cios.2010.2.4.221). [PubMed: [21119938](https://pubmed.ncbi.nlm.nih.gov/21119938/)]. [PubMed Central: [PMC2981778](https://pubmed.ncbi.nlm.nih.gov/PMC2981778/)].
 32. Lee YK, Ha YC, Chang BK, Kim KC, Kim TY, Koo KH. Cementless bipolar hemiarthroplasty using a hydroxyapatite-coated long stem for osteoporotic unstable intertrochanteric fractures. *J Arthroplasty.* 2011;26(4):626-32. doi: [10.1016/j.arth.2010.05.010](https://doi.org/10.1016/j.arth.2010.05.010). [PubMed: [20637559](https://pubmed.ncbi.nlm.nih.gov/20637559/)].
 33. Clawson DK. Trochanteric fractures treated by the sliding screw plate fixation method. *J Trauma.* 1964;4:737-52. doi: [10.1097/00005373-196411000-00001](https://doi.org/10.1097/00005373-196411000-00001). [PubMed: [14225321](https://pubmed.ncbi.nlm.nih.gov/14225321/)].
 34. Kyle RF, Gustilo RB, Premer RF. Analysis of six hundred and twenty-two intertrochanteric hip fractures. *J Bone Joint Surg Am.* 1979;61(2):216-21. [PubMed: [422605](https://pubmed.ncbi.nlm.nih.gov/422605/)].
 35. Yong CK, Tan CN, Penafort R, Singh DA, Varaprasad MV. Dynamic hip screw compared to condylar blade plate in the treatment of unstable fragility intertrochanteric fractures. *Malays Orthop J.* 2009;3(1):13-8.
 36. Adams CI, Robinson CM, Court-Brown CM, McQueen MM. Prospective randomized controlled trial of an intramedullary nail versus dynamic screw and plate for intertrochanteric fractures of the femur. *J Orthop Trauma.* 2001;15(6):394-400. doi: [10.1097/00005131-200108000-00003](https://doi.org/10.1097/00005131-200108000-00003). [PubMed: [11514765](https://pubmed.ncbi.nlm.nih.gov/11514765/)].
 37. Fritz T, Hiersemann K, Kriegelstein C, Friedl W. Prospective randomized comparison of gliding nail and gamma nail in the therapy of trochanteric fractures. *Arch Orthop Trauma Surg.* 1999;119(1-2):1-6. doi: [10.1007/s004020050345](https://doi.org/10.1007/s004020050345). [PubMed: [10076936](https://pubmed.ncbi.nlm.nih.gov/10076936/)].
 38. Yoo JI, Cha YH, Kim KJ, Kim HY, Choy WS, Hwang SC. Comparison between cementless and cemented bipolar hemiarthroplasty for treatment of unstable intertrochanteric fractures: Systematic review and meta-analysis. *Hip Pelvis.* 2018;30(4):241-53. doi: [10.5371/hp.2018.30.4.241](https://doi.org/10.5371/hp.2018.30.4.241). [PubMed: [30534543](https://pubmed.ncbi.nlm.nih.gov/30534543/)]. [PubMed Central: [PMC6284077](https://pubmed.ncbi.nlm.nih.gov/PMC6284077/)].
 39. Langslet E, Frihagen F, Opland V, Madsen JE, Nordsletten L, Figved W. Cemented versus uncemented hemiarthroplasty for displaced femoral neck fractures: 5-year followup of a randomized trial. *Clin Orthop Relat Res.* 2014;472(4):1291-9. doi: [10.1007/s11999-013-3308-9](https://doi.org/10.1007/s11999-013-3308-9). [PubMed: [24081667](https://pubmed.ncbi.nlm.nih.gov/24081667/)]. [PubMed Central: [PMC3940758](https://pubmed.ncbi.nlm.nih.gov/PMC3940758/)].
 40. Cankaya D, Ozkurt B, Tabak AY. Cemented calcar replacement versus cementless hemiarthroplasty for unstable intertrochanteric femur fractures in the elderly. *Ulus Travma Acil Cerrahi Derg.* 2013;19(6):548-53. doi: [10.5505/tjtes.2013.57615](https://doi.org/10.5505/tjtes.2013.57615). [PubMed: [24347215](https://pubmed.ncbi.nlm.nih.gov/24347215/)].
 41. Berend KR, Lombardi AV, Mallory TH, Dodds KL, Adams JB. Cementless double-tapered total hip arthroplasty in patients 75 years of age and older. *J Arthroplasty.* 2004;19(3):288-95. doi: [10.1016/j.arth.2003.11.002](https://doi.org/10.1016/j.arth.2003.11.002). [PubMed: [15067639](https://pubmed.ncbi.nlm.nih.gov/15067639/)].
 42. Pieringer H, Labek G, Auersperg V, Bohler N. Cementless total hip arthroplasty in patients older than 80 years of age. *J Bone Joint Surg Br.* 2003;85(5):641-5. [PubMed: [12892182](https://pubmed.ncbi.nlm.nih.gov/12892182/)].
 43. Bohm P, Bischel O. Femoral revision with the Wagner SL revision stem: Evaluation of one hundred and twenty-nine revisions followed for a mean of 4.8 years. *J Bone Joint Surg Am.* 2001;83(7):1023-31. [PubMed: [11451971](https://pubmed.ncbi.nlm.nih.gov/11451971/)].
 44. Leung KS, So WS, Shen WY, Hui PW. Gamma nails and dynamic hip screws for peritrochanteric fractures. A randomised prospective study in elderly patients. *J Bone*

- Joint Surg Br.* 1992;74(3):345-51. [PubMed: [1587874](#)].
45. Haentjens P, Casteleyn PP, De Boeck H, Handelberg F, Opdecam P. Treatment of unstable intertrochanteric and subtrochanteric fractures in elderly patients. Primary bipolar arthroplasty compared with internal fixation. *J Bone Joint Surg Am.* 1989;71(8):1214-25. [PubMed: [2777850](#)].
46. Yoo JI, Ha YC, Lim JY, Kang H, Yoon BH, Kim H. Early rehabilitation in elderly after arthroplasty versus internal fixation for unstable intertrochanteric fractures of femur: Systematic review and meta-analysis. *J Korean Med Sci.* 2017;32(5):858-67. doi: [10.3346/jkms.2017.32.5.858](#). [PubMed: [28378562](#)]. [PubMed Central: [PMC5383621](#)].