

Arthroscopic Fixation of Posterior Cruciate Ligament Tibial Bony Avulsion Fractures: The Double Suture Bridge Technique and Evaluation of Results

Mihir R. Patel¹, Mahesh B. Shinde^{2,*}, Ushma Butala³, Lakshya Bhardwaj², Amit S. Yadav¹, Gowda Karthik⁴, Saif G. Ansari², Atharva Sharma⁴

¹ Assistant Professor, Department of Orthopedics, H.B.T Medical College and Dr R.N. Cooper Hospital Juhu, Mumbai, Maharashtra, India

² Senior Resident, Department of Orthopedics, H.B.T Medical College and Dr R.N. Cooper Hospital Juhu, Mumbai, Maharashtra, India

³ Assistant Professor, Department of General Surgery, H.B.T Medical College and Dr R.N. Cooper Hospital Juhu, Mumbai, Maharashtra, India

⁴ Junior Resident, Department of Orthopedics, H.B.T Medical College and Dr R.N. Cooper Hospital Juhu, Mumbai, Maharashtra, India

*Corresponding author: Mahesh B. Shinde; Department of Orthopedics, H.B.T Medical College and Dr R.N. Cooper Hospital Juhu, Mumbai, Maharashtra, India. Tel: +22-26210045
Email: mahesh.shinde.1466@gmail.com

Received: 23 February 2024; Revised: 10 May 2024; Accepted: 19 June 2024

Abstract

Background: Surgical fixation is required for displaced posterior cruciate ligament (PCL) tibial bony avulsion fractures or with fractures having grade 2 or more posterior instability. The purpose of this study is to evaluate the results of arthroscopic fixation of PCL tibial bony avulsion fractures using the double suture bridge technique.

Methods: A retrospective study was done involving 24 patients having displaced PCL tibial bony avulsion fractures. The arthroscopic double suture bridge technique was used to fix these fractures. Patients were followed up for three years and assessed for knee-related symptoms, signs, Lysholm Knee Score, and satisfaction.

Results: The study group consisted of 21 men and three women. Fracture union was achieved in all cases two months postoperatively. The mean Lysholm Knee Score at follow-ups of three months, six months, one year, two years, and three years was 86.6, 96.5, 98.8, 99.1, and 99.4, respectively. At the latest follow-up, all the patients were satisfied with their knee function with respect to pain, range of motion (ROM), stability, and resumption of pre-injury activity level.

Conclusion: The arthroscopic double suture bridge technique is an effective method for the fixation of PCL tibial bony avulsion fractures with respect to knee stability, ROM, and resumption of pre-injury activity level.

Keywords: Knee; Arthroscopy; Avulsion Fractures; Lysholm Knee Score

Citation: Patel MR, Shinde MB, Butala U, Bhardwaj L, Yadav AS, Karthik G, et al. **Arthroscopic Fixation of Posterior Cruciate Ligament Tibial Bony Avulsion Fractures: The Double Suture Bridge Technique and Evaluation of Results.** *J Orthop Spine Trauma* 2024; 10(3): 119-23.

Background

Posterior cruciate ligament (PCL) tibial avulsion fractures represent one of the spectrum of injuries to the PCL (1), the incidence of which is between 3% and 38% (2). These are more common in the younger age group and developing countries due to the higher incidence of "2-wheeler" related injuries. The injuries result from a force directed towards the back. It occurs when the front part of the upper tibia experiences a blow while the knee is bent at a 90-degree angle, often referred to as the "dashboard" injury (3). They may also be caused by a sudden hyperextension force (4) in conjunction with varus or valgus or a hyperflexion injury (5).

PCL tibial bony avulsion fractures are commonly associated with other intraarticular pathologies. Hooper et al. reported meniscal injuries in 17% of patients, and 19% had other ligaments involved in patients with PCL tibial bony avulsion fractures (4). Pardiwala et al. reported a 28% incidence of concomitant intraarticular pathology (6). Geissler and Whipple showed that in acute knee injuries, chondral injuries were found in 4% and meniscal tears in 27% of patients (7).

Nonoperative treatment in the form of immobilization is indicated for undisplaced fractures. For fractures displaced less than 5 mm, Zhao and Wang recommended that conservative management be tried (8). Nonoperative treatment for displaced fractures yields poor results as there

is no way to manipulate the bony fragment (8). Operative treatment is indicated for displaced PCL tibial bony avulsion fractures or fractures having grade 2 or more posterior instability. These fractures develop nonunion, resulting in posterior instability (9). Surgical techniques include open or arthroscopic reduction and internal fixation. Open reduction involves the risk of neurovascular injury to the structures in and around the popliteal fossa (10). The arthroscopic technique allows magnified vision with bright illumination, accurate reduction, minimal soft tissue dissection, stable fixation, and management of associated intra-articular pathologies (11). The fixation options include wires, screws, and sutures (12). The advantage of using sutures is that they provide very stable and rigid fixation and do not need removal (13). This study aimed to assess the outcomes of repairing PCL tibial bony avulsion fractures using the double suture bridge technique.

Methods

This was a retrospective study that included 24 patients having displaced PCL tibial avulsion fractures as diagnosed on plain radiography (Figure 1) and/or magnetic resonance imaging (MRI) (Figure 2) or PCL tibial avulsion fractures with grade 2 or more posterior instability as diagnosed on clinical examination. Institutional ethics committee approval was taken and informed consent was obtained from the patients.



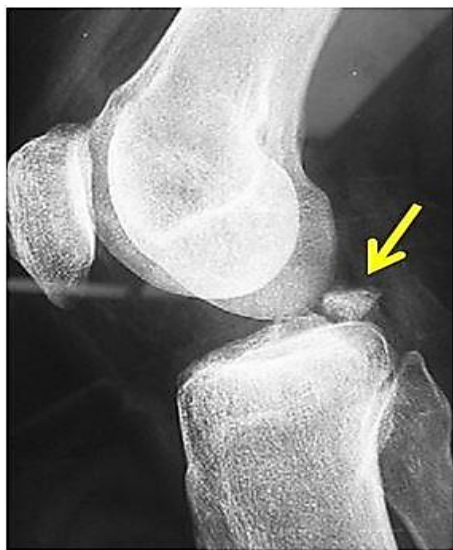

Figure 1. Lateral X-ray showing displaced posterior cruciate ligament (PCL) tibial bony avulsion fracture (yellow arrow)

Pre-operative data recording included age, sex, side, mechanism of injury, duration since the injury, and complaints with respect to pain, locking, clicking, sensation of giving away, and swelling. Clinical examination included tenderness, range of motion (ROM), McMurray's test, and tests for instability (these are the tests used to demonstrate the sensation of the knee twisting or moving from side to side when doing basic activities) (14-16). Lysholm Knee Score was recorded pre-operatively (17-19). Radiological investigations included X-rays and MRI of the knee.

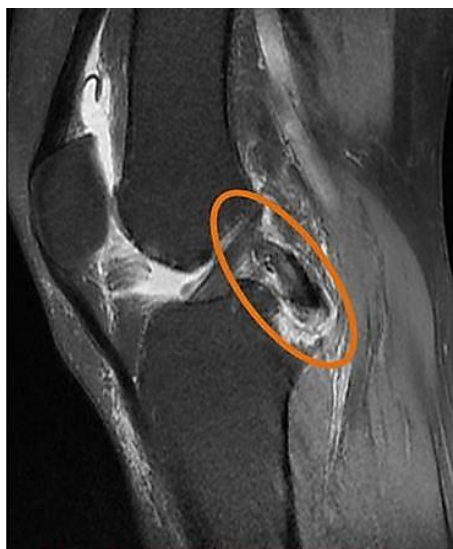

Figure 2. Magnetic resonance imaging (MRI) showing posterior cruciate ligament (PCL) tibial bony avulsion fracture with intact PCL (orange circle)

Spinal anaesthesia was administered to all patients. A high thigh tourniquet was applied, and the patient's leg was positioned in an arthroscopic leg holder at the edge of the table. The standard anterolateral (AL) portal for viewing and the anteromedial (AM) portal for instrumentation were established. The fracture hematoma was drained followed by a diagnostic arthroscopy to confirm the status of the PCL.

A partial meniscectomy was performed for the two patients with meniscal tears.

The synovium between the anterior cruciate ligament (ACL) and PCL was removed using a motorized shaver to create a window lateral to the PCL into the posteromedial (PM) compartment. Similarly, the synovium between the PCL and the medial femoral condyle was removed to create a window medial to the PCL into the PM compartment. The scope was progressed into the PM compartment through the medial window, and two PM portals were established using the out-to-in needle technique – a high PM viewing portal was made 3 cm above the PM tibial joint line, and a low PM working portal was made at the level of the PM joint line. A 5.5-mm cannula was placed in the low PM portal. The arthroscope was then shifted into the high PM portal (Figure 3). A PCL elevator (Acufex, Smith, and Nephew - a manufacturing company) was introduced from the AM portal into the posterior compartment through the lateral window. It was placed posterior to the PCL to protect the neurovascular structures. A motorized shaver, introduced through the low PM portal, and the PCL elevator were used to remove the synovium in the posterior compartment in relation to the PCL. The PCL, the PCL tibial bony avulsion fragment, and the fracture bed were identified. The status of the PCL was confirmed. The fracture bed was debrided using a motorized shaver and burr. An arthroscopic probe was used to provisionally reduce the fragment into the fracture bed.

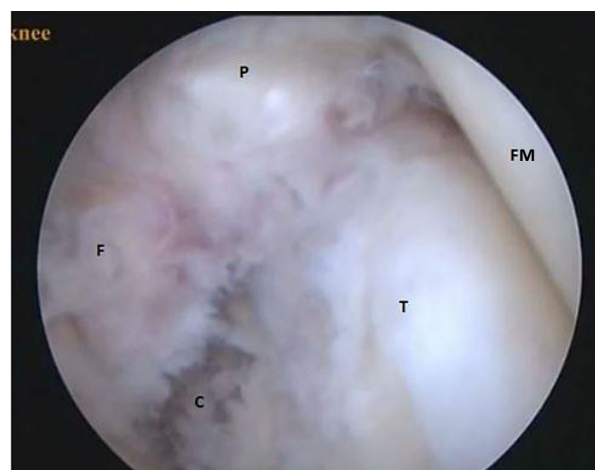

Figure 3. Arthroscopic view from the high posteromedial (PM) portal showing the displaced posterior cruciate ligament (PCL) tibial avulsion fracture (P: PCL; F: PCL tibial avulsed fragment; C: Fracture crater; FM: Medial femoral condyle; T: Medial tibial condyle)

An incision measuring 2 cm vertically was created on the AM surface of the tibia, starting 3 cm away from the joint line. A PCL aimer guide (Acufex, Smith, and Nephew a manufacturing company), set at 60 degrees, was introduced from the AM portal into the posterior compartment through the lateral window and placed in the lateral and inferior aspect of the fracture crater. A 1-mm guide wire was drilled through the external portion of the guide from the AM surface of the tibia into the lateral and inferior aspect of the fracture crater. Similarly, the PCL aimer guide was placed through the medial window to drill a 1-mm guide wire into the medial and inferior aspect of the fracture crater (Figure 4). Care was taken to ensure a 1-cm bone bridge on the AM tibial cortex between the guide wires.

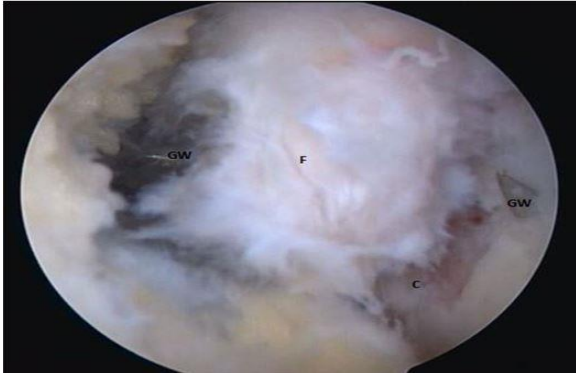


Figure 4. Arthroscopic view of the placement of guide wires in relation to the posterior cruciate ligament (PCL) tibial avulsion fragment (F: PCL tibial avulsion fragment; C: Fracture crater; GW: Guide wire)

One end of a No. 2 fiber wire was passed from the AM portal into the PM compartment through the lateral window and retrieved through the low PM portal. The other end of the fiber wire was passed through the AM portal into the PM compartment through the medial window and retrieved through the low PM portal. The two ends of the fiber wire were synched to loop the PCL at the junction of its attachment with the tibial bony avulsed fragment. An arthroscopic knot pusher passed through the low PM portal was used to place four to five snugly fitting half hitches around the PCL at its attachment with the avulsed bony fragment. This step was repeated with a second No. 2 fiber wire. Thus, two sets of half hitches were snugly placed around the PCL, creating a double suture bridge posterior to the avulsed PCL tibial bony fragment.

A 4.5-mm endoscopic reamer was used to ream, from anterior to posterior, over the previously placed guide wires. Protection from posterior migration was provided by the PCL elevator during this step to avoid any neurovascular injury. Thus, two tunnels are created - medial and lateral - from the AM tibia into the fracture crater. One suture shuttle is passed through each tunnel from the AM cortex into the posterior compartment and retrieved through the low PM portal. Each suture shuttle is used to shuttle one end of each of the two fiber wires from the PM compartment onto the AM cortex. The two ends of each fiber wire were synched in an anterior direction to make the half hitches taut, which in turn, compressed the PCL tibial avulsion fragment into the fracture crater. Reduction was confirmed, and the two ends of each fiber wire were knotted over the AM bony bridge (Figure 5). The knee was taken through a ROM to confirm the stability of fixation.

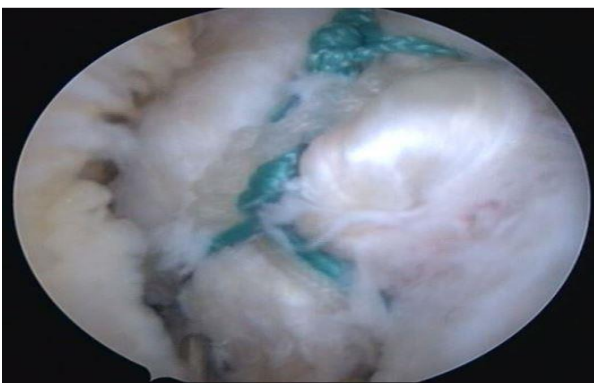


Figure 5. Arthroscopic view of the fixed posterior cruciate ligament (PCL) tibial avulsion fracture using the double suture bridge

Postoperatively, the knee was placed in a long knee brace with a pad placed posterior to the proximal aspect of the calf muscles. Ankle pump exercises, static quadriceps sets, and active straight leg raises were started immediately after surgery. Active knee bending was started as per pain relief, usually from the second postoperative day. Bedside knee bends and prone knee bends were started after four weeks. The patients were mobilized non-weight-bearing till four weeks postoperatively. Full weight-bearing with a long knee brace was allowed after four weeks. The long knee brace was discontinued after two months. The patients were allowed to run, jump, and do sporting activities after six months.

Postoperative knee ROM was noted on the first- and second-month follow-up visits. The third month, the sixth month, one-year, two-year, and three-year follow-ups were done as follows: patient complaints of pain, locking, clicking, sensation of giving way, and swelling, clinical examination for tenderness, ROM, McMurray's test and tests for instability, and Lysholm Knee Score.

At the latest follow-up, patient satisfaction with respect to knee pain, ROM, stability, and return to the previous activity level was noted.

Results

Of the 24 patients included in the study, 21 were men and three were women, with a mean age of 36.4 years (range: 22 to 46 years). The left knee was involved in 8 cases, and the right knee in 16 cases. All the patients had a knee injury following which their knee complaints started. Fourteen patients had a road traffic accident, and ten patients had a twisting knee injury due to a fall. The patients presented at a mean duration of 4.6 weeks (range: 1 to 10 weeks) from injury.

All patients presented with chief complaints of knee pain. Two patients complained of clicking and locking. Six patients complained of the sensation of giving way, and 11 patients had knee swellings. Tenderness over the back of the knee was observed in fourteen patients. Twelve individuals exhibited complete knee ROM, while the remaining patients had an average ROM of 71.7 degrees, with a range of 30 to 120 degrees. McMurray's test was not performed in 12 patients due to incomplete knee ROM. This test was positive only in one patient who had a medial meniscus tear. The posterior drawer test was performed in 20 patients and was positive (grade 3: n = 10, grade 2: n = 10) in all. Lachman's test for posterior instability was performed in all the patients and was positive in all (grade 3: n = 13, grade 2: n = 11). Other tests for instability (varus stress, valgus stress, dial test, anterior drawer, and Lachman's test for anterior instability) were negative. The pre-operative Lysholm Knee Score was not calculated for seven patients due to non-functional knee status at the time of presentation. The mean Lysholm Knee Score of the remaining patients (n = 17) at the time of presentation was 60.5.

On X-ray of the knee, all patients had a PCL tibial bony avulsion fracture (Figure 1). MRI of all patients confirmed the diagnosis and showed an intact PCL (Figure 2), with one patient having a medial meniscus and one patient having a lateral meniscus tear.

Diagnostic arthroscopy confirmed the findings of PCL tibial avulsion fracture with an intact PCL in all the patients. All of the patients were free from any chondral lesions. One patient had a lateral, and one patient had a medial meniscus tear.

Ten patients achieved full knee ROM by the end of the first month, and all except two patients achieved full knee ROM by the end of the second month. All fractures united by two months postoperatively.

At three-month follow-up, 16 patients complained of pain in the knee. None of the patients complained of clicking, locking, or the sensation of giving way. Two patients had knee effusions in the postoperative period, which settled down with exercise restriction and anti-inflammatory medications (indomethacin 25 mg, three times daily) for three days. All, except two patients, had full knee ROM. These two patients had a terminal 20-degree restriction of flexion. Nine patients had posterior knee joint tenderness. McMurray's test was negative in all, and six patients had grade 1 posterior instability. The mean Lysholm Score at three months follow-up was 86.6 (range: 57 to 99).

At six-month follow-up, five patients had intermittent knee pain. None of the patients had any knee locking, clicking, the sensation of giving way, or swelling. All, except two patients, had full knee ROM. These two patients had a terminal 20-degree restriction of flexion. Two patients had posterior knee tenderness. McMurray's test was negative in all, and six patients had grade 1 posterior instability. The mean Lysholm Score at six-month follow-up was 96.5 (range: 76 to 100).

At one-year follow-up, two patients had intermittent knee pain. None of the patients had any knee locking, clicking, the sensation of giving way, or swelling. All, except one patient, had full knee ROM. This patient had a terminal 20-degree restriction of flexion. One patient had posterior knee tenderness. McMurray's test was negative in all, and six patients had grade 1 posterior instability. The mean Lysholm Score at one-year follow-up was 98.8 (range: 85 to 100).

At two-year follow-up, the same two patients had intermittent knee pain. None of the patients had any knee locking, clicking, the sensation of giving way, or swelling. All patients had full knee ROM. One patient had posterior knee tenderness. McMurray's test was negative in all, and six patients had grade 1 posterior instability. The mean Lysholm Score at two-year follow-up was 99.1 (range: 87 to 100).

At three-year follow-up, two patients had intermittent knee pain. None of the patients had any knee locking, clicking, the sensation of giving way, or swelling. All patients had full knee ROM. None of the patients had any knee tenderness (Table 1). McMurray's test was negative in all, and six patients had grade 1 posterior instability. The mean Lysholm Score at three-year follow-up was 99.4 (range: 91 to 100).

Follow-up	3 months	6 months	1 year	2 year	3 year
Pain	16	5	2	2	2
Click	0	0	0	0	0
Locking	0	0	0	0	0
Giving way sensation	0	0	0	0	0
Knee effusion	2	0	0	0	0
Restricted ROM	2	2	1	0	0
Posterior joint line tenderness	9	2	1	1	1

ROM: Range of motion

At the latest follow-up, all the patients were satisfied with their knee function with respect to pain, ROM, and stability and had resumed their previous level of activities.

Discussion

The present study was done to study the clinical results of fixation of PCL tibial avulsion fractures using the double

suture bridge technique. Displaced PCL tibial bony avulsion fractures need operative intervention as immobilization fails to obtain a reduction of the fracture fragment into its crater, resulting in non-union and posterior instability. The knee joint did not experience any clicking, locking, or giving way sensation in almost all patients following surgery. More than half of the patients complained of knee pain at 3 months which was reduced in further follow-up. Some patients had joint line tenderness initially. No one had shown any joint line tenderness at 3 years after surgery.

Open reduction requires a posterior approach, which is not without risk to the complex anatomy of the popliteal fossa (10). Postoperative swelling from tissue edema can cause compartment syndrome. Retraction of soft tissue can cause traction neuropraxia of the common peroneal nerve. Arthroscopic reduction avoids any posterior dissection, and hence minimizes the risk of injury to the posterior structures. Arthroscopy allows magnified vision with bright illumination and accurate reduction. Femoral and patellar chondral defects and concomitant tears of the ACL and menisci have been found in association with PCL injuries (7). The arthroscopic technique, unlike the open approach, allows full exploration of the knee joint for these pathologies and their management in the same stage (13, 20, 21).

A variety of fixation techniques have been used to fix these fractures arthroscopically, some of them being screws (antegrade, retrograde), anchors (4), sutures (22), Kirschner wires (K-wires) (23), and wire loops. Most PCL tibial avulsion fractures are just a sliver of bone being held together by the fibers of the PCL. The fracture bed is of poor bone quality due to the fracture. Invariably, comminution is noted during arthroscopy. Conservative treatment fails to re-establish the normal biomechanics of the knee (24).

Screws cannot be used in comminuted PCL tibial avulsion fractures. Insertion of screws for fixation needs drilling to be done, which can cause comminution of the bony fragment (13). There is a risk of screws backing out and causing injury to the posterior neurovascular structures during the postoperative period, and may need hardware removal. Pardiwala et al. reported a 12% incidence of implant-related problems when screws were used for fixation (6). K-wires have an insecure fixation, and there is a possibility of migration. All metal implants can affect future knee imaging due to metal artifacts and can interfere with any other future knee surgery (25-28).

The use of pull-through sutures to fix the PCL tibial avulsion fracture has many advantages over the previously discussed metal fixation options. Sutures hold the fragment at the bone-ligament interface, and thus have a very good hold even in comminuted fractures (24). The use of sutures does not need drilling of the avulsed fragment, and thus can be used even in comminuted fractures. Secure and stable fixation is obtained as the free ends of the sutures are tied to each other over the AM tibial cortical bridge. Sutures do not need removal and neither cause any artifact in future imaging nor interfere with any future knee surgery.

The double suture bridge technique, while retaining all the advantages of the use of sutures for fixation, creates a diverging bridge of sutures over the posterior aspect of the PCL tibial avulsed fracture fragment, similar to the suture bridge construct used for rotator cuff repair in the shoulder, and gives uniform compression in a direction perpendicular to the fracture, hence reducing chances of nonunion.

As the fixation obtained by the double suture bridge technique is secure, the ROM of the knee can be started immediately postoperatively, and hence the chances of stiffness are far less (23). In the present study, knee ROM was started on the second postoperative day, and full knee range was obtained in all but two patients by the second postoperative month. This technique produces uniform compression across the fracture, and hence chances of nonunion are very low. In the present study, all the fractures were united by two months postoperatively.

The drawbacks of the present study are the small number of patients and lack of a control group in the study.

Conclusion

The arthroscopic double suture bridge technique is an effective method for the fixation of PCL tibial bony avulsion fractures with respect to knee stability, ROM, and resumption of pre-injury activity level.

Conflict of Interest

The authors declare no conflict of interest in this study.

Acknowledgements

There was no funding source for this research work.

References

- Toritsu T. Avulsion fracture of the tibial attachment of the posterior cruciate ligament. Indications and results of delayed repair. *Clin Orthop Relat Res.* 1979;143:107-14. [PubMed: 509810].
- Katsman A, Strauss EJ, Campbell KA, Alaia MJ. Posterior cruciate ligament avulsion fractures. *Curr Rev Musculoskelet Med.* 2018;11(3):503-9. doi: 10.1007/s12178-018-9491-2. [PubMed: 29869136]. [PubMed Central: PMC6105473].
- Joshi S, Bhatia C, Gondane A, Rai A, Singh S, Gupta S. Open reduction and internal fixation of isolated posterior cruciate ligament avulsion fractures: Clinical and functional outcome. *Knee Surg Relat Res.* 2017;29(3):210-6. doi: 10.5792/ksrr.17.022. [PubMed: 28854767]. [PubMed Central: PMC5596399].
- Hooper PO^{3rd}, Silko C, Malcolm TL, Farrow LD. Management of posterior cruciate ligament tibial avulsion injuries: A systematic review. *Am J Sports Med.* 2018;46(3):734-42. doi: 10.1177/0363546517701911. [PubMed: 28437619].
- Bianchi M. Acute tears of the posterior cruciate ligament: clinical study and results of operative treatment in 27 cases. *Am J Sports Med.* 1983;11(5):308-14. doi: 10.1177/036354658301100505. [PubMed: 6638245].
- Pardiwala D, Agrawal D, Patil V, Saini U, Dhawal P. Paper 133: Comparison of open versus arthroscopic fixation for isolated PCL tibial bony avulsions: A prospective randomized study with minimum 2 year follow-up. *Arthroscopy.* 2012;28(9):e413-e414. doi: 10.1016/j.arthro.2012.05.616.
- Geissler WB, Whipple TL. Intraarticular abnormalities in association with posterior cruciate ligament injuries. *Am J Sports Med.* 1993;21(6):846-9. doi: 10.1177/036354659302100615. [PubMed: 8291637].
- Zhao J, He Y, Wang J. Arthroscopic treatment of acute tibial avulsion fracture of the posterior cruciate ligament with suture fixation technique through Y-shaped bone tunnels. *Arthroscopy.* 2006;22(2):172-81. doi: 10.1016/j.arthro.2005.10.020. [PubMed: 16458803].
- Hoogervorst P, Gardeniers JW, Moret-Wever S, van Kampen A. Pseudo-arthrosis repair of a posterior cruciate ligament avulsion fracture. *Knee Surg Sports Traumatol Arthrosc.* 2010;18(11):1612-6. doi: 10.1007/s00167-010-1114-4. [PubMed: 20405107]. [PubMed Central: PMC2957579].
- Nourbakhsh ST, Bahramian F, Zafarani Z, Alidousti A, Aslani H. Arthroscopic bridge technique for pcl avulsion: surgical technique and key points. *Arch Bone Jt Surg.* 2016;4(4):393-5. [PubMed: 27847856]. [PubMed Central: PMC5100459].
- Patel MR, Butala UK, Thakor NS, Bansod RR, Dhotre RA. Arthroscopic fixation of anterior cruciate ligament tibial avulsion fractures: the suture "bridge" pull out technique and evaluation of results. *Int J Res Orthop.* 2017;3(5):979-85. doi: 10.18203/issn.2455-4510.IntJResOrthop20173375
- Kakarlapudi TK, Bickerstaff DR. Knee instability: Isolated and complex. *West J Med.* 2001;174(4):266-72. doi: 10.1136/ewj.174.4.266. [PubMed: 11290686]. [PubMed Central: PMC1071355].
- Kim SJ, Shin SJ, Choi NH, Cho SK. Arthroscopically assisted treatment of avulsion fractures of the posterior cruciate ligament from the tibia. *J Bone Joint Surg Am.* 2001;83(5):698-708. doi: 10.2106/00004623-200105000-00008. [PubMed: 11379739].
- Akseki D, Ozcan O, Boya H, Pinar H. A new weight-bearing meniscal test and a comparison with McMurray's test and joint line tenderness. *Arthroscopy.* 2004;20(9):951-8. doi: 10.1016/j.arthro.2004.08.020. [PubMed: 15525928].
- Corea JR, Moussa M, al OA. McMurray's test tested. *Knee Surg Sports Traumatol Arthrosc.* 1994;2(2):70-2. doi: 10.1007/BF01476474. [PubMed: 7584186].
- Anderson AF, Lipscomb AB. Clinical diagnosis of meniscal tears. Description of a new manipulative test. *Am J Sports Med.* 1986;14(4):291-3. doi: 10.1177/036354658601400408. [PubMed: 3755297].
- Briggs KK, Kocher MS, Rodkey WG, Steadman JR. Reliability, validity, and responsiveness of the Lysholm knee score and Tegner activity scale for patients with meniscal injury of the knee. *J Bone Joint Surg Am.* 2006;88(4):698-705. doi: 10.2106/JBJS.E.00339. [PubMed: 16595458].
- Briggs KK, Lysholm J, Tegner Y, Rodkey WG, Kocher MS, Steadman JR. The reliability, validity, and responsiveness of the Lysholm score and Tegner activity scale for anterior cruciate ligament injuries of the knee: 25 years later. *Am J Sports Med.* 2009;37(5):890-7. doi: 10.1177/0363546508330143. [PubMed: 19261899].
- Briggs KK, Steadman JR, Hay CJ, Hines SL. Lysholm score and Tegner activity level in individuals with normal knees. *Am J Sports Med.* 2009;37(5):898-901. doi: 10.1177/0363546508330149. [PubMed: 19307332].
- Chen SY, Cheng CY, Chang SS, Tsai MC, Chiu CH, Chen AC, et al. Arthroscopic suture fixation for avulsion fractures in the tibial attachment of the posterior cruciate ligament. *Arthroscopy.* 2012;28(10):1454-63. doi: 10.1016/j.arthro.2012.04.141. [PubMed: 22929009].
- Sabat D, Jain A, Kumar V. Displaced posterior cruciate ligament avulsion fractures: A retrospective comparative study between open posterior approach and arthroscopic single-tunnel suture fixation. *Arthroscopy.* 2016;32(1):44-53. doi: 10.1016/j.arthro.2015.06.014. [PubMed: 26311286].
- Deehan DJ, Pinczewski LA. Arthroscopic reattachment of an avulsion fracture of the tibial insertion of the posterior cruciate ligament. *Arthroscopy.* 2001;17(4):422-5. doi: 10.1053/jars.2001.21841. [PubMed: 11288019].
- Gui J, Wang L, Jiang Y, Wang Q, Yu Z, Gu Q. Single-tunnel suture fixation of posterior cruciate ligament avulsion fracture. *Arthroscopy.* 2009;25(1):78-85. doi: 10.1016/j.arthro.2008.08.011. [PubMed: 19111222].
- Meyers MH. Isolated avulsion of the tibial attachment of the posterior cruciate ligament of the knee. *J Bone Joint Surg Am.* 1975;57(5):669-72. [PubMed: 1150710].
- Chen CA, Chen W, Goodman SB, Hargreaves BA, Koch KM, Lu W, et al. New MR imaging methods for metallic implants in the knee: Artifact correction and clinical impact. *J Magn Reson Imaging.* 2011;33(5):1121-7. doi: 10.1002/jmri.22534. [PubMed: 21509870]. [PubMed Central: PMC3081101].
- Wendt RE^{3rd}, Wilcott MR^{3rd}, Nitz W, Murphy PH, Bryan RN. MR imaging of susceptibility-induced magnetic field inhomogeneities. *Radiology.* 1988;168(3):837-41. doi: 10.1148/radiology.168.3.3406413. [PubMed: 3406413].
- Butts K, Pauly JM, Gold GE. Reduction of blurring in view angle tilting MRI. *Magn Reson Med.* 2005;53(2):418-24. doi: 10.1002/mrm.20375. [PubMed: 15678535].
- Cho ZH, Kim DJ, Kim YK. Total inhomogeneity correction including chemical shifts and susceptibility by view angle tilting. *Med Phys.* 1988;15(1):7-11. doi: 10.1118/1.596162. [PubMed: 3352554].