

## **<sup>99m</sup>Tc-MIBI SPECT/CT imaging contribution in the diagnosis of patients with hyperparathyroidism**

**Manevska Nevena, Stojanoski Sinisa, Stoilovska Bojana, Sazdova Irena**

Institute of Pathophysiology and Nuclear Medicine "Acad Isak S. Tadzer",  
Faculty of Medicine, Ss Cyril and Methodius University, Skopje, Macedonia

(Received 7 July 2018, Revised 13 November 2018, Accepted 18 November 2018)

### **ABSTRACT**

**Introduction:** Hyperparathyroidism is presented with increased parathyroid hormone (PTH) secretion due to hyperfunctioning of one or more of the four parathyroid glands. Primary hyperparathyroidism (p-HPT) can be due to parathyroid adenoma, hyperplasia or carcinoma of the parathyroid gland. Secondary hyperparathyroidism (s-HPT) is usually a response to hypocalcaemia and consecutive hyperplasia of the glands. Our aim was to compare the efficacy of <sup>99m</sup>Tc-methoxyisobutylisonitrile (MIBI) SPECT/CT in identification of the location of the lesion(s) in cases of HPT by comparing these results with the findings of ultrasound (US) and planar scintigraphy.

**Methods:** Forty one consecutive patients (54±17 age, 12 males and 29 females) with primary or secondary hyperparathyroidism were included. All patients were examined by US and afterwards patients underwent conventional double-phase <sup>99m</sup>Tc-MIBI scintigraphy combined with neck SPECT/CT procedure. Planar images (early and delayed), US and SPECT/CT image sets were evaluated for adenoma localization at the neck and thorax. Regions of interest (ROIs), equal sized, were selected and compared, over the hyperfunctioning parathyroid tissue (accumulated impulses-counts value) and over the contralateral lobe of the thyroid gland (control counts value).

**Results:** The ultrasonography detected 24 positive findings. The late phase of planar scan detected 26 positive findings. SPECT/CT presented with bigger detection rate than late planar phase or US (75.6%, 63.4%, 61.5%) and with higher sensitivity (100%, 83.8%, 77.4%), respectively.

**Conclusion:** The SPECT/CT study seems reliable, sensitive and with added value in diagnosing hyperparathyroidism as a complementary method to planar scintigraphy. US as compatible method, should be performed prior the scintigraphy protocols.

**Key words:** Hyperparathyroidism; Parathyroid; SPECT/CT; <sup>99m</sup>Tc-MIBI; Ultrasound

**Iran J Nucl Med 2019;27(1):1-7**

Published: January, 2019

<http://irjnm.tums.ac.ir>

**Corresponding author:** Dr Manevska Nevena, No 17, Mother Teresa St., Skopje, Macedonia. E-mail: [dr.nmanevska@gmail.com](mailto:dr.nmanevska@gmail.com)

## INTRODUCTION

Hyperparathyroidism is presented with increased parathyroid hormone (PTH) secretion in the bloodstream, due to hyperfunctioning of one or more of the four parathyroid glands. PTH helps maintain an appropriate balance of calcium in the bloodstream and in tissues that depend on calcium for proper functioning. Primary hyperparathyroidism (p-HPT) is usually caused by a single hyperfunctioning parathyroid gland – (parathyroid adenoma in 85-96% of cases) or less frequently (10%-15%) is due to hyperplasia, multiple adenomas, and ~1% due to carcinoma [1, 2]. It may be asymptomatic [3] (75%-80% of cases) or symptomatic (20%-25% of cases). Secondary hyperparathyroidism (s-HPT) refers to the excessive secretion of PTH by the parathyroid glands in response to hypocalcaemia and associated hyperplasia of the glands. This disorder is especially seen in patients with chronic kidney failure. Failing kidneys do not convert enough vitamin D to its active form, and they do not adequately excrete phosphate. When this happens, insoluble calcium phosphate forms in the body and removes calcium from the circulation. Secondary hyperparathyroidism can also result from malabsorption (chronic pancreatitis, small bowel disease, and malabsorption-dependent bariatric surgery) in that the fat-soluble vitamin D cannot get reabsorbed. The practical choice for localization analysis in p-HPT and s-HPT is a combination of <sup>99m</sup>Tc-methoxyisobutylisonitrile (MIBI) scintigraphy and ultrasonography (US) [4].

The standard of care of HPT is a surgical excision of the responsible lesion(s) and the most effective combination of different modalities for planning operative strategy is very important. Our aim was to investigate the efficacy of <sup>99m</sup>Tc-MIBI SPECT/CT study to identify the location of the lesion(s) in cases of HPT, by comparing it with US and dual phase <sup>99m</sup>Tc-MIBI planar scan.

## METHODS

Between December 2016 and June 2017, 41 consecutive patients (54±17 age, 12 males and 29 females) with diagnosis of p-HPT (30 patients, 73.17%) or s-HPT (11 patients, 26.83%) were admitted at the Institute of Pathophysiology and Nuclear Medicine for a parathyroid scintigraphy. The average PTH value in the p-HPT group was 1453±576 pg/ml, with average ionized Ca<sup>2+</sup> level=1.33±0.07 mmol/l. The average PTH value in the s-HPT group was 228±34 pg/ml, with average ionized Ca<sup>2+</sup> level = 1.27±0.05 mmol/l. This study was approved by the Ethical Committee of Medical faculty in Skopje, and consent has been obtained from each patient or subject after full explanation of the purpose and nature of all procedures used. Prior scintigraphy, we examined the patients by US of the neck region, separately, by two

nuclear medicine specialists, both with over 5 years of experience in the field of expertise. For the US we used Phillips H.D 6, Version 1.1, probe 7.5Hz. After the US examination, all patients underwent conventional planar <sup>99m</sup>Tc-MIBI double-phase scintigraphy combined with neck SPECT/CT study. Planar scintigraphy was performed after IV injection of 740MBq <sup>99m</sup>Tc-MIBI and consisted of an early phase (10 minutes after injection) and delayed phase (2 hours after injection of the radiotracer). We used dual-headed gamma camera MEDISO DHV Nucline Spirit, with the 140 keV photo-peak using a low-energy, high resolution (LEHR) parallel collimator, in AP, DL, LL projections. After the delayed phase, SPECT/CT study was performed using the Optima NM/CT 640 GE Health care dual detector/4-slice CT gamma camera, LEHR collimator, 120 views, and matrix size 128x128. The images were reconstructed with slice thickness 2.5 mm, slice spacing 2.5 mm and matrix size 512x512. Planar images (early and delayed), ultrasonography and SPECT/CT image sets were evaluated for adenoma localization at the neck and thorax. The results were interpreted by two nuclear medicine specialists, separately, as a blinded method of analysis. Afterwards, the interpretations were compared, and a match in the interpretations was considered as a positive scintigraphy finding. All patients with positive scintigraphy findings underwent surgical intervention. Postoperatively, a comparison analysis was performed between the positive scintigraphy findings and the positive histology findings, the latter being considered as the gold standard for a positive study. Blood levels of PTH – intraoperative quick assay and postoperative evaluation (significant decrease in the concentration) and clinical and biochemical follow up of patients, also contributed to confirmation of the positive study and the success of the surgical procedure. Regions of interest (ROIs) were selected over the hyperfunctioning parathyroid tissue (accumulated impulses-counts value) and over the contralateral lobe of the thyroid gland (control counts value). The ROIs were equal sized.

## Statistical analysis

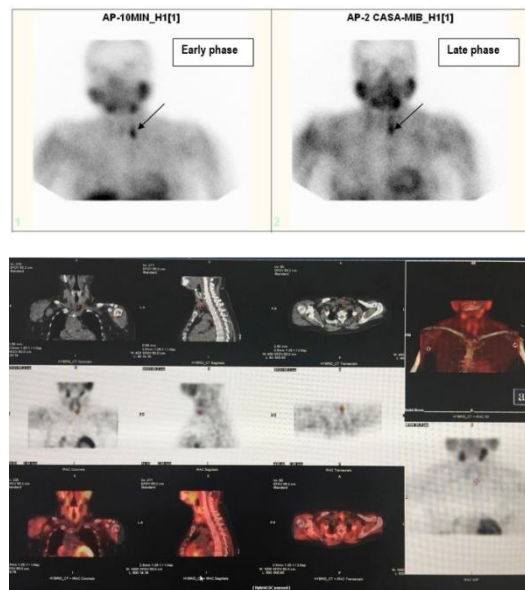
Statistical analysis was performed with SPSS16 software (SPSS, Inc., Chicago, IL). Results are expressed as mean ± SD unless otherwise stated. The chi square statistic was used for comparison of categorical variables. Continuous variables were analyzed by Student's t-test. A probability level of random difference of p<0.05 was considered significant.

## RESULTS

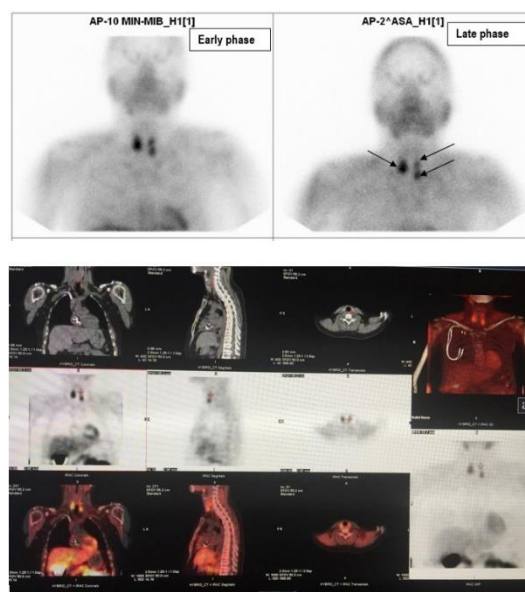
The ultrasonography revealed 24 positive findings versus (vs.) 15 negative, no data existed for 2 patients.

**Table 1:** Findings on ultrasound, planar images and SPECT/CT images.

	Positive				Negative
	Left lobe	Right lobe	Bilateral	No data	
<b>Ultrasonography</b>	13	6	5	2	15
<b>Planar late phase</b>	10	9	7	-	15
<b>SPECT - CT</b>	13	10	8	-	10



**Fig 1.** Patient with parathyroid adenoma (positive on both planar and SPECT/CT images).



**Fig 2.** Patient with parathyroid hyperplasia (positive on both planar and SPECT/CT images).

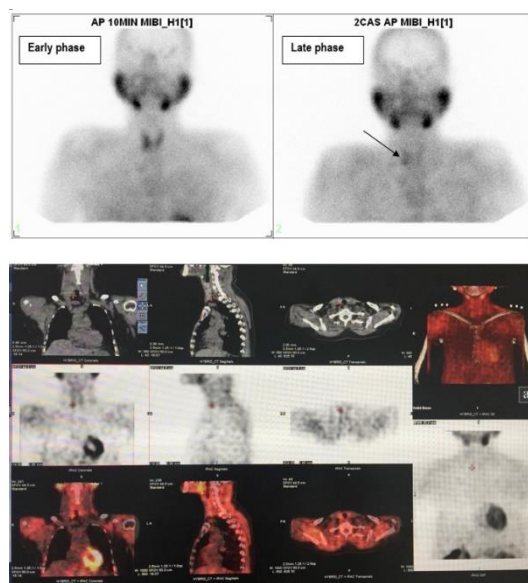


Fig 3. Patient with parathyroid adenoma (negative early planar, positive late planar and positive SPECT/CT images).

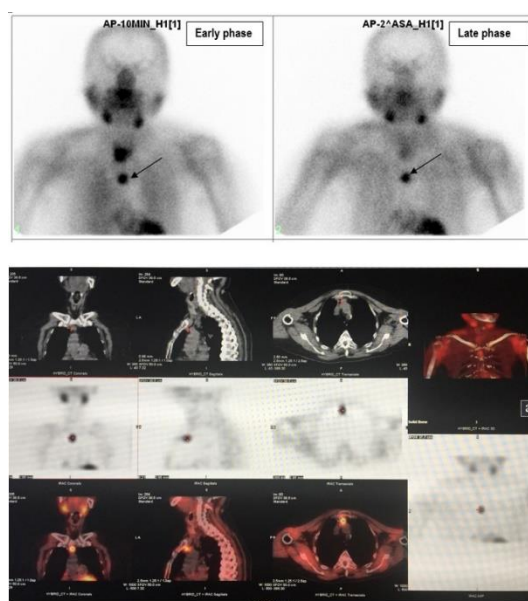


Fig 4. Patient with ectopic parathyroid gland in the mediastinum (positive on both planar and SPECT/CT images)

The late phase of planar scan detected 26 positive findings for parathyroid adenoma and 15 negative findings (equal as the US), (Table 1). Figures 1 and 2 show patients with parathyroid adenoma and hyperplasia (positive on both planar and SPECT/CT images), respectively.

The SPECT/CT presented with bigger detection rate (75.6% vs. 63.4% vs. 61.5%) and with higher sensitivity (100% vs. 83.8% vs. 77.4%), vs. late planar phase and US, respectively (Table 2).

Table 2: Detection rate and sensitivity of the diagnostic modalities.

Method	Detection rate (%)	Sensitivity (%)
US	61.5	77.4
Planar scintigraphy	63.4	83.8
SPECT/CT	75.6	100

Figure 3 shows a patient with parathyroid adenoma (negative early planar, positive late planar and positive SPECT/CT images). One ectopic parathyroid in the upper mediastinum was revealed with SPECT/CT technique (Figure 4).

Our findings presented positive results for hyperfunctional parathyroid tissue in the early phase of the scintigraphy in 20 patients (14 of which were with pHPT and 6 were with sHPT) and in the delayed phase including SPECT/CT in 31 patients (23 of which were with pHPT and 8 were with sHPT), which was statistically significant (p<0.05).

Statistically significant increase of counts was detected in the ROI of adenoma vs. ROI of control in both early and late phases (Tables 3 and 4).

Table 3: Counts value in early phase (10 minutes) of the ROI of adenoma vs. ROI of control.

Counts	Control	Adenoma	P value
	Mean ± SD	Mean ± SD	
Total	17781 ± 29	27525 ± 44	<0.01
Average	191 ± 29	287 ± 44	
Min-Max	74-380	37-622	

Table 4: Counts value in late phase (2 hours) of the ROI of adenoma vs. ROI of control.

Counts	Control	Adenoma	P value
	Mean ± SD	Mean ± SD	
Total	9999 ± 14	15326 ± 22	<0.001
Average	107 ± 14	155 ± 22	
Min-Max	42-268	52-387	

All 31 positive scintigraphic findings on SPECT/CT, presented positive on postoperative histology for parathyroid tissue. No false positive findings were noted and none of the lesions presented rapid <sup>99m</sup>Tc-MIBI washout.

### DISCUSSION

Parathyroid scintigraphy with <sup>99m</sup>Tc-MIBI has been used as a universal method that identifies parathyroid adenomas or hyperactive parathyroid tissue. The use of <sup>99m</sup>Tc-MIBI parathyroid scintigraphy has proven to be the single best imaging modality for preoperative localization of parathyroid adenomas. It was first reported in 1989 by Coakley and colleagues, with characteristic of superior image quality, more favorable dosimetry, and improved detection sensitivity than thallium [5, 6]. Neck ultrasonography

is rapid, non-expensive, safe and non-invasive technique with sensitivity 65%-85% for detecting parathyroid adenomas [7]. In other studies sensitivity of ultrasonography (US) for detecting a single parathyroid adenoma was reported to be 56%–100% and specificity of 40%–99% in accurate localization of the lesions [8, 9]. However, parathyroid US is dependent on the experience of the operator and has a suboptimal detection rate for multinodular thyroid disease and silent areas, such as the mediastinum, trachea-esophageal groove, and retrosophageal region [10].

The distribution of <sup>99m</sup>Tc-MIBI is proportional to the blood flow and mitochondrial activity; it is thought to be sequestered in the mitochondria once inside the cell [11]. In the early phase of the scintigraphy (10-15 minutes after application of the tracer) this tracer can be accumulated in both thyroid tissue and the parathyroid glands, but in the late phase (2-3 hours after) it usually washes out of normal thyroid tissue more rapidly than it does out of abnormal parathyroid tissue. This is the principle of the dual-phase method, which was first reported in 1992 [12]. High signal-to-background ratio on the delayed images of <sup>99m</sup>Tc-MIBI scintigraphy can be seen in the case of parathyroid adenoma and hyperplasia lesions. In 1992, O'Doherty et al. described slower washout of <sup>99m</sup>Tc-MIBI from hyperfunctioning parathyroid than from the thyroid gland [13]. The utility on dual-phase methodology for parathyroid scintigraphy was reported by Taillefer et al. who demonstrated the diagnostic advantage of the differential washout [12]. The method had similar accuracy to the subtraction method, although few direct comparison studies have been reported [14, 15].

In our study, the early planar phase was positive in 20 patients and the delayed phase including SPECT/CT was positive in 31 patients. The results favor the delayed phase versus the early phase, and the analysis present significant advantage of the delayed phase findings (p<0.05). However, routinely we use the combination of the early and delayed phase, since it presents the best results in detecting hyperfunctional parathyroid tissue. Ultrasound in our study presented sensitivity of 77.4% and detection rate of 61.5 %, while planar scintigraphy presented sensitivity of 83.8% and detection rate of 63.4% with no statistically significant difference.

The combination of <sup>99m</sup>Tc-MIBI scintigraphy and US for localization of parathyroid pathology (parathyroid adenoma and hyperplasia) is currently the primary diagnostic choice. The sensitivity of US, <sup>99m</sup>Tc-MIBI planar and <sup>99m</sup>Tc-MIBI SPECT/CT scan in the study of Noda et al. were 77%, 75% and 89%, respectively, and had no significant difference in precise localization. No factors were identified indicating



weak point of planar <sup>99m</sup>Tc-MIBI scintigraphy for precise localization [16].

SPECT/CT affords the opportunity to shorten acquisition time, perform accurate attenuation correction, increase specificity, and improve localization of disease. However, the rate of persistent and recurrent disease after parathyroidectomy is high, ranging between 10% and 30% [17]. It is extremely important to correctly locate all parathyroid tissue preoperatively, because most failures occur when the surgeon does not remove all hyperfunctioning parathyroid tissue. CT, MRI, arteriography, and high resolution ultrasound have all been used in the diagnosis of secondary hyperparathyroidism. However, the performance of these anatomic techniques is not satisfactory in preoperative identification of hyperfunctional parathyroid tissue [18].

<sup>99m</sup>Tc-MIBI SPECT/CT could overcome the difficulty in pointing out the location of the lesion than planar image. As shown in the present series, intrathyroidal adenoma could not be identified by planar image, because of the lack in information of the depth of the lesion. SPECT/CT gave this information at a glance. Ultrasound, <sup>99m</sup>Tc-MIBI planar and <sup>99m</sup>Tc-MIBI SPECT/CT determine the laterality of the lesion with accuracy of 84, 85 and 89% respectively, when applied in solitary [16]. SPECT/CT in our study presented sensitivity of 100% and detection rate of 75.6% and it presented significantly better diagnostic features when compared to US and planar scintigraphy alone (p<0.05).

The goal of the study of Yang was to compare the diagnostic value of early and delayed phase of <sup>99m</sup>Tc-MIBI SPECT/CT in the detection of parathyroid tissue to guide operative treatment of patients with s-HPT. To our knowledge, no study has directly compared early with delayed phase <sup>99m</sup>Tc-MIBI SPECT/CT in the detection of parathyroid tissue in s-HPT patients. However, their findings revealed that 7 of 80 patients had positive results only on the delayed phase and 6 of 80 patients had positive results only on the early phase. So they concluded that either early or delayed phase <sup>99m</sup>Tc-MIBI SPECT/CT may depict new lesions, and both phases of <sup>99m</sup>Tc-MIBI SPECT/CT together can depict more lesions than with either phase alone [19].

Higher sensitivity of early phase than delayed phase <sup>99m</sup>Tc-MIBI SPECT scintigraphy was demonstrated by Carty et al. in the detection of parathyroid glands (sensitivity, 92% and 74%) [20]. However, Civelek et al. reported that delayed phase SPECT was a promising protocol in the preoperative detection and localization of parathyroid adenomas in both unexplored and reexplored patients. All patients had underwent both early and delayed phase scintigraphy, but CT data were acquired only once (used in both phases of <sup>99m</sup>Tc-MIBI SPECT/CT, early and delayed).

This method does not entail more radiation dose than early or delayed phase scanning alone [21].

A major advantage of SPECT/CT seems to be its ability to differentiate inferior from inferior-posterior glands (superior glands in the trachea-esophageal groove). The statistical advantage of SPECT/CT was not evident when analysis was done with the inferior and inferior-posterior locations combined [22].

The factor most commonly reported to correlate with false-negative findings is the size of the parathyroid gland (i.e., smaller glands are less likely to be detected than larger glands [23, 24], and inclusion of anatomic information may benefit patient treatment.

SPECT/CT is particularly useful for equivocal cases or when uniglandular disease has been undetected with ultrasound techniques [25, 26]. Schachter et al. concluded that early phase SPECT is useful for localizing parathyroid adenomas and is superior to dual-phase delayed imaging. They reported that only 60% of adenomas exhibited retention of activity on delayed phase images. Therefore, delayed phase <sup>99m</sup>Tc-MIBI may be non-diagnostic and is not recommended, if similar washout rates were found between thyroid and parathyroid tissue and thus cause false negative [27]. Neumann showed that the sensitivity (approximately 70%) for localizing an adenoma did not improve with SPECT/CT, but anatomic localization significantly improved the specificity (96% for SPECT/CT vs. 48% for SPECT alone, p < 0.006) [28].

Despite its high sensitivity and specificity, SPECT alone is substantially limited by low spatial resolution and its inability to provide anatomical detail. Dual-modality imaging systems which allow both functional and structural imaging to be performed during a single imaging session improve image quality in comparison to functional imaging only [29]. Fusion imaging resulting from hybrid devices has been reported to be clearly giving better localization of disease and differentiation between physiologic and pathologic uptake [30].

## CONCLUSION

The SPECT/CT protocol, according to our results, seems quite reliable and is a sensitive method in the diagnostic imaging algorithm of hyperparathyroidism. We suggest using SPECT/CT protocol as a complementary method to planar parathyroid scintigraphy whenever possible, selectively in p-HPT patients, but extensively in s-HPT patients. US as compatible method with scintigraphy, should be performed prior the scintigraphy protocols.

## REFERENCES

1. Cordellat IM. Hyperparathyroidism: primary or secondary disease? *Reumatol Clin*. 2012 Sep-Oct;8(5):287-91.

2. Gopinath P, Mihai R. Hyperparathyroidism. *Surgery*. 2011;29:451-458.
3. Bilezikian JP, Silverberg SJ. Clinical practice. Asymptomatic primary hyperparathyroidism. *N Engl J Med*. 2004 Apr 22;350(17):1746-51.
4. Sukan A, Reyhan M, Aydin M, Yapar AF, Sert Y, Canpolat T, Aktas A. Preoperative evaluation of hyperparathyroidism: the role of dual-phase parathyroid scintigraphy and ultrasound imaging. *Ann Nucl Med*. 2008 Feb;22(2):123-31.
5. Coakley AJ, Kettle AG, Wells CP, O'Doherty MJ, Collins RE. <sup>99m</sup>Tc sestamibi--a new agent for parathyroid imaging. *Nucl Med Commun*. 1989 Nov;10(11):791-4.
6. Bergenfelz A, Tennvall J, Valdermarsson S, Lindblom P, Tibblin S. Sestamibi versus thallium subtraction scintigraphy in parathyroid localization: a prospective comparative study in patients with predominantly mild primary hyperparathyroidism. *Surgery*. 1997 Jun;121(6):601-5.
7. Mazzeo S, Caramella D, Lencioni R, Molea N, De Liperi A, Marcocci C, Miccoli P, Iaconi P, Bossio GB, Viacava P, Lazzeri E, Bartolozzi C. Comparison among sonography, double-tracer subtraction scintigraphy, and double-phase scintigraphy in the detection of parathyroid lesions. *AJR Am J Roentgenol*. 1996 Jun;166(6):1465-70.
8. Tziakouri C, Eracleous E, Skannavis S, Pierides A, Symeonides P, Gourtsoyiannis N. Value of ultrasonography, CT and MR imaging in the diagnosis of primary hyperparathyroidism. *Acta Radiol*. 1996 Sep;37(5):720-6.
9. Purcell GP, Dirbas FM, Jeffrey RB, Lane MJ, Desser T, McDougall IR, Weigel RJ. Parathyroid localization with high-resolution ultrasound and technetium Tc <sup>99m</sup> sestamibi. *Arch Surg*. 1999 Aug;134(8):824-8; discussion 828-30.
10. Ahuja AT, Wong KT, Ching AS, Fung MK, Lau JY, Yuen EH, King AD. Imaging for primary hyperparathyroidism--what beginners should know. *Clin Radiol*. 2004 Nov;59(11):967-76.
11. Hetrakul N, Civelek AC, Stagg CA, Udelsman R. In vitro accumulation of technetium-99m-sestamibi in human parathyroid mitochondria. *Surgery*. 2001 Dec;130(6):1011-8.
12. Taillefer R, Boucher Y, Potvin C, Lambert R. Detection and localization of parathyroid adenomas in patients with hyperparathyroidism using a single radionuclide imaging procedure with technetium-99m-sestamibi (double-phase study). *J Nucl Med*. 1992 Oct;33(10):1801-7.
13. O'Doherty MJ, Kettle AG, Wells P, Collins RE, Coakley AJ. Parathyroid imaging with technetium-99m-sestamibi: preoperative localization and tissue uptake studies. *J Nucl Med*. 1992 Mar;33(3):313-8.
14. Leslie WD, Dupont JO, Bybel B, Riese KT. Parathyroid <sup>99m</sup>Tc-sestamibi scintigraphy: dual-tracer subtraction is superior to double-phase washout. *Eur J Nucl Med Mol Imaging*. 2002 Dec;29(12):1566-70.
15. Chen CC, Holder LE, Scovill WA, Tehan AM, Gann DS. Comparison of parathyroid imaging with technetium-99m-pertechnetate/sestamibi subtraction, double-phase technetium-99m-sestamibi and technetium-99m-sestamibi SPECT. *J Nucl Med*. 1997 Jun;38(6):834-9.
16. Noda S, Onoda N, Kashiwagi S, Kawajiri H, Takashima T, Ishikawa T, Yoshida A, Higashiyama S, Kawabe J, Imanishi Y, Tahara H, Inaba M, Osawa M, Hirakawa K. Strategy of operative treatment of hyperparathyroidism using US scan and (<sup>99m</sup>Tc-MIBI SPECT/CT. *Endocr J*. 2014;61(3):225-30.
17. Giordano A, Rubello D, Casara D. New trends in parathyroid scintigraphy. *Eur J Nucl Med*. 2001 Sep;28(9):1409-20.
18. Perez-Monte JE, Brown ML, Shah AN, Ranger NT, Watson CG, Carty SE, Clarke MR. Parathyroid adenomas: accurate detection and localization with Tc-99m sestamibi SPECT. *Radiology*. 1996 Oct;201(1):85-91.
19. Yang J, Hao R, Yuan L, Li C, Yan J, Zhen L. Value of dual-phase (<sup>99m</sup>Tc-sestamibi scintigraphy with neck and thoracic SPECT/CT in secondary hyperparathyroidism. *AJR Am J Roentgenol*. 2014 Jan;202(1):180-4.
20. Carty SE, Worsley J, Virji MA, Brown ML, Watson CG. Concise parathyroidectomy: the impact of preoperative SPECT <sup>99m</sup>Tc sestamibi scanning and intraoperative quick parathormone assay. *Surgery*. 1997 Dec;122(6):1107-14; discussion 1114-6.
21. Civelek AC, Ozalp E, Donovan P, Udelsman R. Prospective evaluation of delayed technetium-99m sestamibi SPECT scintigraphy for preoperative localization of primary hyperparathyroidism. *Surgery*. 2002 Feb;131(2):149-57.
22. Lavelly WC, Goetze S, Friedman KP, Leal JP, Zhang Z, Garret-Mayer E, Dackiw AP, Tufano RP, Zeiger MA, Ziessman HA. Comparison of SPECT/CT, SPECT, and planar imaging with single- and dual-phase (<sup>99m</sup>Tc-sestamibi parathyroid scintigraphy. *J Nucl Med*. 2007 Jul;48(7):1084-9.
23. Thrall J, Ziessman H. *Medicina Nuclear*. 2nd ed. Rio de Janeiro: Guanabara Koogan S.A.; 2003. p. 28-31
24. Junior FAM, Guiberteau MJ. *Essentials of Nuclear Medicine Imaging*. 5th ed. London, U.K.: Saunders Elsevier; 2006. p. 85-181.
25. Tublin ME, Pryma DA, Yim JH, Ogilvie JB, Mountz JM, Bencherif B, Carty SE. Localization of parathyroid adenomas by sonography and technetium tc <sup>99m</sup> sestamibi single-photon emission computed tomography before minimally invasive parathyroidectomy: are both studies really needed? *J Ultrasound Med*. 2009 Feb;28(2):183-90.
26. Eslamy HK, Ziessman HA. Parathyroid scintigraphy in patients with primary hyperparathyroidism: <sup>99m</sup>Tc sestamibi SPECT and SPECT/CT. *Radiographics*. 2008 Sep-Oct;28(5):1461-76.
27. Schachter PP, Issa N, Shimonov M, Czerniak A, Lorberboym M. Early, postinjection MIBI-SPECT as the only preoperative localizing study for minimally invasive parathyroidectomy. *Arch Surg*. 2004 Apr;139(4):433-7.
28. Neumann DR, Obuchowski NA, Difilippo FP. Preoperative <sup>123I</sup>/<sup>99m</sup>Tc-sestamibi subtraction SPECT and SPECT/CT in primary hyperparathyroidism. *J Nucl Med*. 2008 Dec;49(12):2012-7.
29. Hasegawa BH, Wong KH, Iwata K, Barber WC, Hwang AB, Sakdinawat AE, Ramaswamy M, Price DC, Hawkins RA. Dual-modality imaging of cancer with SPECT/CT. *Technol Cancer Res Treat*. 2002 Dec;1(6):449-58.
30. Patton JA, Townsend DW, Hutton BF. Hybrid imaging technology: from dreams and vision to clinical devices. *Semin Nucl Med*. 2009 Jul;39(4):247-63.