



## Sex Determination through 3D Analysis of the Maxillary Sinus

*Eun-Young Jeon<sup>1</sup>, Hyun-Na Ahn<sup>2</sup>, \*Jong-Tae Park<sup>2</sup>*

1. Department of Dental Hygiene, Kyungbok University, Namyangju, South Korea
2. Department of Oral Anatomy, College of Dentistry, Dankook University, Cheonan, South Korea

\*Corresponding Author: Email: [jongta2@dankook.ac.kr](mailto:jongta2@dankook.ac.kr)

(Received 15 Feb 2021; accepted 23 Feb 2021)

### Dear Editor-in-Chief

Skeletal analysis for sex determination is the first step of forensic medicine, and is mainly based on analyzing the skull, pelvis, iliac bone, and mandibular bone. However, these bones cannot be used for sex identification when they are severely damaged in criminal cases, natural disasters, or other types of major trauma. The maxillary sinus is an important structure because it often remains intact even when other bones are severely damaged, which makes it worthwhile to investigate the sex-related characteristics of the maxillary sinus (1).

Diagnostic tests such as Computed Tomography (CT) and Magnetic Resonance Imaging (MRI) have been used as standard approaches for determining the size of the maxillary sinus. However, the application of these methods is restricted by their high cost and low accessibility. The recent introduction of cone-beam computed tomography (CBCT) has reduced the disadvantages of CT scans and MRI, with CBCT making it possible to acquire volumetric images rapidly with exposure to only low doses of radiation (2). In particular, three-dimensional (3D) models constructed from CBCT image data can facilitate the accurate visualization of structural information about the skull, teeth, and soft tissue, which makes this approach suitable for the analysis of the complex anatomical structure of the maxillary sinus.

This study measured the dimensions of the maxillary sinuses of subjects by reconstructing CBCT image data into 3D models. To establish the reliability of measurements of the maxillary sinus for sex identification, morphological differences in the maxillary sinuses according to sex were identified.

The Institutional Review Board of the Dental College Hospital at Dankook University reviewed and approved this study (DKUDH IRB 2020-02-007).

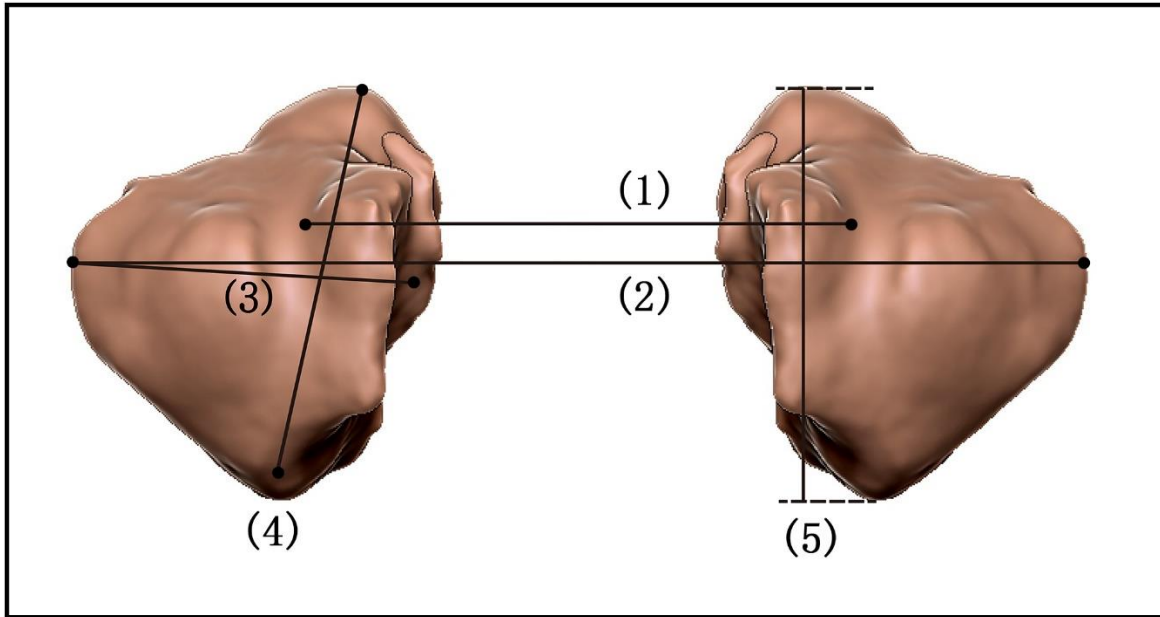
CBCT data of outpatients at the Dento-Maxillo-Facial Radiology Unit of the Dental College Hospital at Dankook University were obtained. The subjects comprised 60 patients (30 males and 30 females) aged 20-40 years (mean age 22.82 years) who did not have missing teeth, facial asymmetry, or systemic diseases. The CBCT data of the subjects were obtained using a CBCT scanner (Alphard 3030, Asahi, Kyoto, Japan) in the Digital Imaging and Communications in Medicine (DICOM) format. Mimics (Materialise, Leuven, Belgium) was used to import the DICOM files and reconstruct the 3D skull models.

The width, length, and height of each maxillary sinus, the distance between the infraorbital foramina, and the distances between the maxillary sinuses were measured based on previously reported methods (1-3). The results were analyzed statistically at a 95% significance level using ver-



sion 20.0 of the Statistical Package for the Social Sciences (SPSS, IBM, USA). The Mann-Whitney test was used to analyze the differences in the maxillary sinus measurements according to sex.

The mean distances between the infraorbital foramina were 37.67 and 23.33 mm in males and females, respectively ( $\chi^2=10.106$ ,  $P=0.001$ ) (Fig. 1).



**Fig. 1:** Measurements of maxillary sinus ((1). Distance of Infraorbital Foramina, (2). Distance of sinuses, (3). Width, (4). Length, (5). Height)

In addition, the mean distances between the maxillary sinuses were 36.03 and 24.97 mm in males and females, respectively. The mean width of the maxillary sinus was 36.55 mm in males and 24.45 mm in females on the left side, and 35.20 and 25.80 mm on the right side. The mean lengths of the maxillary sinus in males and females were 38.12 and 22.88 mm, respectively, on the left side, and 39.42 and 21.58 mm on the right side. For mean heights of the maxillary sinus in males and females were 37.33 and 23.67 mm, respectively, on the left side, and 37.80 and 23.30 mm on the right side (Table 1). 3D models of the maxillary

sinus reconstructed from CBCT images of the head and neck can allow accurate size measurements to be made for sex identification (1). This study found that all of the measured dimensions of the maxillary sinus were significantly greater in males than in females. Kanthem et al. similarly observed that the maxillary sinus is larger in males than in females (2). Chatterjee et al. also reported that the size of the maxillary sinus varies with sex (4). Therefore, studies of sex-related differences in the maxillary sinuses can generate reference values for use in forensic applications.

**Table 1:** Average rank of maxillary sinus of subjects in sex

<i>Measurements</i>		<i>N</i>	<i>Mean number</i>	<i>chi-square</i>	<i>P-value</i>
Distance of	Male	30	37.67	10.106	0.001*
Infraorbital	Female	30	23.33		
Formina					
Distance of Sinus-	Male	30	36.03	6.023	0.014*
es	Female	30	24.97		
L Width	Male	30	36.55	7.201	0.007*
	Female	30	24.45		
L Length	Male	30	38.12	11.413	0.001*
	Female	30	22.88		
L Height	Male	30	37.33	9.186	0.002*
	Female	30	23.67		
R Width	Male	30	35.20	4.346	0.037*
	Female	30	25.80		
R Length	Male	30	39.42	15.641	0.000**
	Female	30	21.58		
R Height	Male	30	37.80	10.483	0.001*
	Female	30	23.30		

\* *P* -value were obtained by Kruskal-Wallis ( $P < 0.05$ )

\*\* *P* -value were obtained by Kruskal-Wallis ( $P < 0.001$ )

### Conflict of interest

The authors declare that there is no conflict of interests.

### References

1. Kanthem RK, Guttikonda VR, Yeluri S, Kumari G (2015). Sex determination using maxillary sinus. *J Forensic Dent Sci*, 7(2), 163.
2. Saccucci M, Cipriani F, Carderi S, et al (2015). Gender assessment through three-dimensional analysis of maxillary sinuses by means of cone beam computed tomography. *Eur Rev Med Pharmacol Sci*, 19(2), 185-93.
3. Sidhu R, Chandra S, Devi P, Taneja N, Sah K, Kaur N (2014). Forensic importance of maxillary sinus in gender determination: a morphometric analysis from Western Uttar Pradesh, India. *European Journal of General Dentistry*, 3(1), 53.
4. Chatterjee D, Ghosh TB, Ghosh BB (1990). Size variation of mastoid air cell system in Indian people at different age groups: a radiographic planimetric study. *J Laryngol Otol*, 104(8), 603-605.