



New and Inherited *STAT1* Mutations in a Chinese Family with Chronic Mucocutaneous Candidiasis: A Case Report

*Xiaoheng XU, *Wenxia MENG, Lu FENG, Wei GUO*

Stomatological Hospital, Southern Medical University, Guangdong, Guangzhou, P.R. China

***Corresponding Author:** Email: mengwx2008@foxmail.com

(Received 10 Jul 2019; accepted 21 Sep 2019)

Abstract

A mild clinical Chronic Mucocutaneous Candidiasis (CMC) phenotype with *STAT1* transcription factor mutation has been identified in a Chinese family. It is a rare variant in *STAT1* (NM_0073315.3c.1175T>C Met392Thr). Specifically, it is a heterozygous mutation. To date, the pathogenicity of this variant in *STAT1* (NM_0073315.3c.1175T>C Met392Thr) for CMC has not been reported in the Human Gene Mutation Database. Thus, this is the first report about *STAT1* mutation found in CMC patients from Chinese ethnic group. This study also shows the mutation on the DNA-binding domain of *STAT1* for the first time. The findings will broaden the spectrum of *STAT1* mutations and facilitate genetic diagnosis by the oral medicine specialists.

Keywords: Chronic Mucocutaneous Candidiasis (CMC); *STAT1* transcription factor; Mutation; China

Introduction

Chronic Mucocutaneous Candidiasis (CMC) is a hereditary primary immunodeficiency disease. It was first reported in 1960, and the incidence was 1/100 000 (1). CMC presents heterogeneously in both clinical manifestation and genetic background. The oral mucosa shows recurrent oral thrush infection by *Candida*; when affecting the nails and skin, it can cause dermatophytosis and onychomycosis (2). Some patients display bacterial infections in the respiratory tract and even thyroid autoimmunity (3). It may also be life threatening, due to the associated risks of esophageal squamous cell carcinoma (4, 5). The genetic cause of CMC has remained unknown until very recently. In 2011, mutations in signal transducer and activator of transcription 1 (*STAT1* transcription factor) have been identified as a high frequency cause of autosomal dominant CMC or sporadic CMC (3, 6).

In this study, we have explored a clinical CMC phenotype with *STAT1* mutation in a family.

Two patients presented with recurrent or persistent mucocutaneous candidiasis, chronic bronchitis and onychomycosis. Human immunodeficiency virus (HIV) and syphilis infection were excluded. Since this routine immunological evaluation did not explain the infectious phenotype, whole exome sequencing (WES), targeting at mutations in genes associated with Th17 defects was performed. Finally, a rare variant in *STAT1* (NM_0073315.3c.1175T>C Met392Thr) was identified. The amino acid substitution in our case study has never been reported.

More importantly, we emphasize the primary role of the oral medicine specialists and dentists in the diagnosis of CMC and the possible necessity of genetic analysis to prevent misdiagnosis.

Case presentation

A 30-yr-old woman (patient 1) was presented to the Guangdong Province Stomatological Hospi-

tal, China in June 2016 with an oral pseudomembrane lesion at buccal, tongue and palate. She

also suffered from recurrent angular stomatitis (Fig. 1a-f).

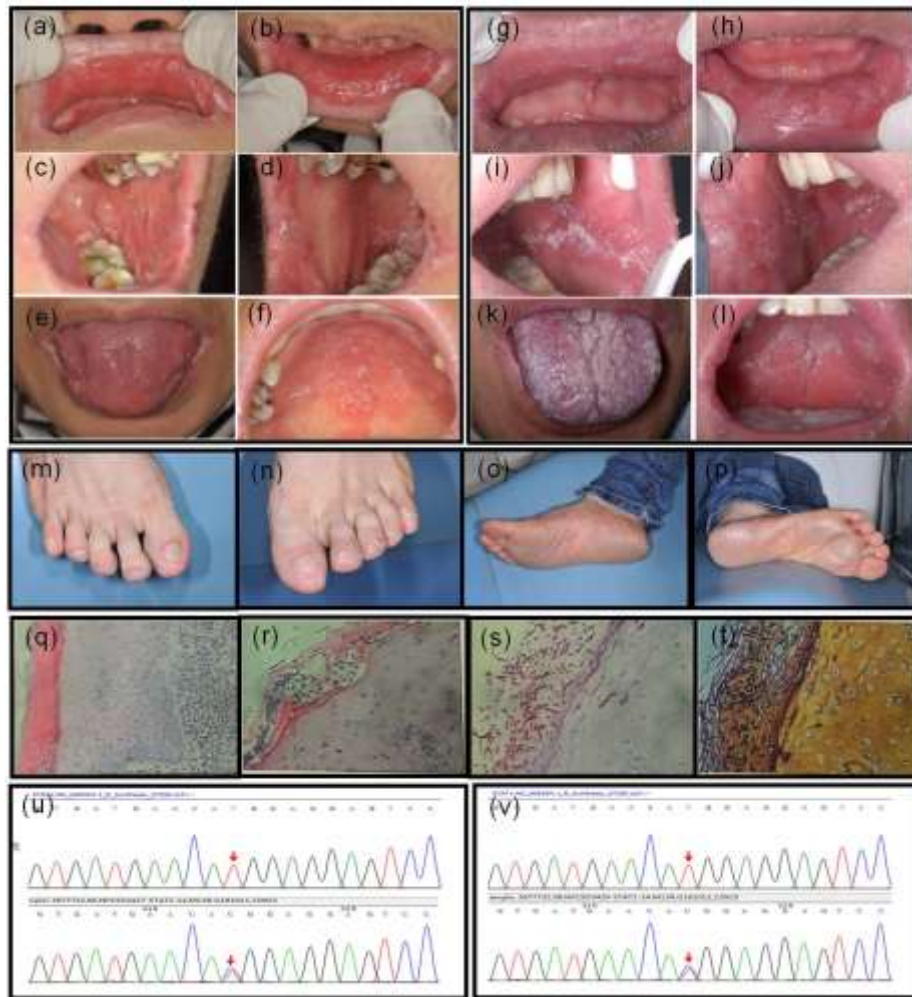


Fig. 1: (a-f) Clinical examination of the woman showed oral pseudomembrane lesions on the buccal, tongue and palate surface, surrounded by contiguous extensive erythematous and inflamed lesions. (g-l) Clinical examination of her brother also showed extensive oral pseudomembrane lesions on the buccal, tongue and palate surface. (m-p) Feet of the woman showed excessive hyperkeratosis and dermatophytosis. (q-t) Pathologic examination showed squamous epithelial dysplasia and a diffuse infiltrate of lymphoma and plasmacyte after H&E staining. Periodic-acid-Schiff (PAS) staining and Grocott's methenamine silver stained fungal hyphae in tissue. (u-v) Genetics results: whole exome sequencing was performed by TruSeq DNA sample preparation (12). The identified *STAT1* mutation at position c.1175T>C results in amino acid substitution at position 392 (Met392Thr) within the CC-domain of the *STAT1* molecule

Informed consent was taken from the patient before the study and the study was approved by the local Ethics Committee. Clinical examination of the skin appearance revealed excessive vegetative hyperkeratosis on her toe nails (Fig. 1m-p). No anogenital and other

cutaneous lesions were found. Laboratory investigations were normal. Bacterial cultures from tongue were negative while fungal cultures showed the presence of *Candida albicans*. In histologic examination, squamous epithelial dysplasia, superficial hyperkeratosis, and a diffuse infiltrate

of lymphoma and plasmocyte were noted. Neutral leukocyte accumulation and suspected fungal hyphae in cuticle were also observed. Periodic Acid-Schiff (PAS) and Gomori Methenamine-Silver (GMS) stain indicated *Candida albicans* infection (Fig. 1q-t).

She told us that her brother (patient 2) also suffered from the same symptom since early childhood. Clinical examination of her brother also revealed the recurrent oral thrush (Fig. 1g-l). He suffered from recurrent respiratory infection. However, he never went to the hospital for treatment because of the mild symptoms. A chest computed tomography (CT)-scan showed bron-

chiectasis in the right middle and the right upper lobe and the lingual. Fungal culture results from his lung were negative.

Since this routine immunological evaluation did not explain the infectious phenotype, we proceeded to perform WES with special attention to mutations in specified genes. We identified a rare variant in *STAT1* (NM_0073315.3) at nucleotide position 1175 with a T to C substitution (c.1175T>C) resulting in amino acid substitution from methionine to threonine at position 392 (Met392Thr) by 4000 genes sequencing (Fig. 1u-v) (Table 1).

Table 1: The identified *STAT1* mutation at position c.1175T>C results in amino acid substitution at position 392 (Met392Thr) within the CC-domain of the *STAT1* molecule

<i>Cases</i>	<i>Transcript variant</i>	<i>Protein variant</i>
Patient 1	c.1175T;c.1175C	p.392Met; p.392Thr
Patient 2	c.1175T;c.1175C	p.392Met; p.392Thr

It is a missense mutation in exon14. Based on the clinical and histological features, as well as the gene assay, the diagnosis of CMC was made. The amino acid substitution in our case has never been reported. It is within the DNA-binding domain of *STAT1*. According to the guidelines of the American College of Medical Genetics and Genomics and the Association of Molecular Pathology (7), this variant should be classified as uncertain significance because other criteria are unmet (PM2+PP3). This variant also is not included in the ESP6500, human genome and

dbSNP database and it is a rare variant, which is a moderate evidence of pathogenicity (PM2). The bioinformatics software indicated higher likely pathogenicity of this variant, which is a supporting evidence of pathogenicity (PP3).

Patient 1 was given oral fluconazole for 4 weeks (100 mg/d on days 1-14; 50 mg/d on days 14-28), after which she experienced an almost complete normalization of the oral mucosa within 4 weeks (Fig. 2). Unfortunately, patient 2 refused to be given a treatment because of the mild symptom.

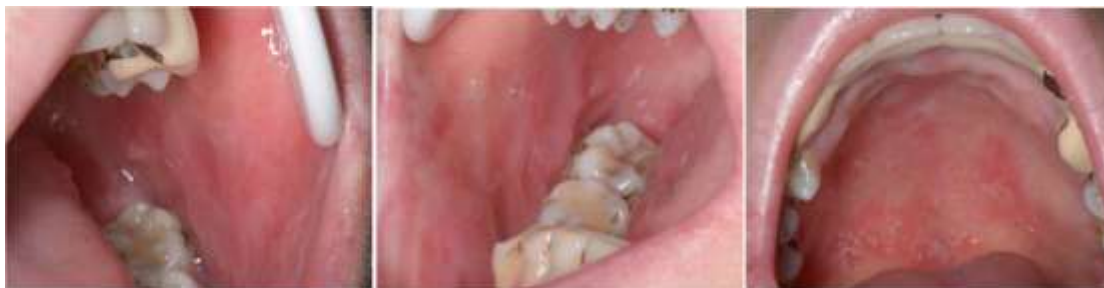

Fig. 2: Representative clinical images for patient 1 after a 4-week of antifungal fluconazole treatment. Oral pseudo-membrane lesions was obviously relieved in the buccal and palate mucosa

Discussion

The main features of this family's phenotype were chronic mucocutaneous fungal infections with *Candida*, and respiratory tract infection in the absence of other immunodeficiency. To avoid a misdiagnosis, the oral medicine specialists should be careful when evaluating a patient with recurrent or persistent mucocutaneous candidiasis without other serious clinical manifestation. Generally, patients with poor resistance and extensive oral *Candida* infections, the first thing to do for an oral medicine doctor is to exclude HIV infection. In the present cases, HIV and syphilis infection were excluded. The infectious phenotype typically presents in early infancy and in an inherited family suggests that this might be a hereditary primary immunodeficiency disease.

In the past years, at least 30 different amino acid changes are known to cause CMC (8, 9). Heterozygous gain-of-function (GOF) mutations in the transcription factor *STAT1* result in CMC, but the molecular basis of this pathogenic missense mutations is unknown. Jana et al. indicated a CMC-related GOF substitution mutation of arginine to tryptophan at position 274 (R274W) of *STAT1*, and a mutation of glutamine to alanine adjacent to position 275 (Q275A) (10). Tariq et al. reported a case of CMC/ combined immunodeficiency (CID) in a 10-yr-old boy, due to a new mutation in the small ubiquitin molecule (SUMO) consensus site in the C-terminal region of *STAT1*, thus identified heterozygous missense variants (c.2113G> C p. Glu705Gln E705Q) (11). The abovementioned studies pointed out the mutations found at *STAT1* region before. Thereafter, our gene assay indicated that *STAT1* variants phenotype (Met392Thr) have not been reported before in CMC patients. To our knowledge, this study also shows its novelty, by demonstrating that a DNA-binding domain mutation of c.1175C>T in exon 14 of *STAT1* (p. Met392Thr) is the genetic cause of autosomal dominant CMC in two related Chinese patients. The genetic testing report pointed out, if the *STAT1* gene is mutated, it can cause immunodeficiency type 31A

and immunodeficiency type 31C, all of which are inherited in an autosomal dominant manner. Their children may be genetically affected, and their relatives may also be at risk of carrying the same genetic mutant. However, its clinical significance is still not clear and it also need to be more clinical cases to confirm. As the database and guidelines are continuously updated, the analysis and ratings of variants may be re-acquired.

Conclusion

STAT1 is the most probable candidate gene in CMC patients but not the only gene responsible for autosomal dominant inherited CMC. This case illustrates the complex picture and spectrum of CMC. Nevertheless, the cellular and molecular mechanisms responsible for the increased susceptibility to fungal infections in patients with AD-CMC and *STAT1* mutations remain to be deciphered.

Ethical considerations

Ethical issues (including plagiarism, informed consent, misconduct, data fabrication and/or falsification, double publication and/or submission, redundancy, etc.) have been completely observed by the authors.

Acknowledgements

We sincerely appreciate Gayatri XR for the writing assistance with this article. We thank the patients and their families for their anticipation. We also thank professor Xin Zeng, West China Hospital of Stomatology, for her help. This work was supported by grants from the National Natural Science Foundation of China (No.81500850), Nonprofit Industry Research Specific Fund of National Health and Family Planning Commission of China (No.201502018).

Conflict of interest

The authors declare that there is no conflict of interest.

References

1. Puel A, Picard C, Cypowyj S, et al (2010). Inborn errors of mucocutaneous immunity to *Candida albicans* in humans: a role for IL-17 cytokines? *Curr Opin Immunol*, 22:467-474.
2. Puel A, Cypowyj S, Bustamante J, et al (2011). Chronic Mucocutaneous Candidiasis in humans with inborn errors of interleukin-17 immunity. *Science*, 332:65-68.
3. Liu L, Okada S, Kong XF, et al (2011). Gain-of-function human STAT1 mutations impair IL-17 immunity and underlie Chronic Mucocutaneous Candidiasis. *J Exp Med*, 208:1635-1648.
4. Koch D, Lilic D, Carmichael AJ (2009). Autosomal dominant Chronic Mucocutaneous Candidiasis and primary hypothyroidism complicated by oesophageal carcinoma. *Clin Exp Dermatol*, 34:e818-820.
5. McGurk M, Holmes M (1998). Chronic mucocutaneous candidiasis and oral neoplasia. *J Laryngol Otol*, 102:643-645.
6. van de Veerdonk FL, Plantinga TS, Hoischen A, et al (2011). STAT1 mutations in autosomal dominant Chronic Mucocutaneous Candidiasis. *N Engl J Med*, 365:54-61.
7. Richards S, Aziz N, Bale S, et al (2015). Standards and guidelines for the interpretation of sequence variants: a joint consensus recommendation of the American College of Medical Genetics and Genomics and the Association for Molecular Pathology. *Genet Med*, 17:405-24.
8. Dotta L, Scomodoni O, Padoan R, et al (2016). Clinical heterogeneity of dominant Chronic Mucocutaneous Candidiasis disease: presenting as treatment-resistant candidiasis and chronic lung disease. *Clin Immunol*, 164:1-9.
9. van de Veerdonk, FL, Netea MG (2016). Treatment options for Chronic Mucocutaneous Candidiasis. *J Infect*, 72:S56-S60.
10. Jana P, Julia S, Oliver B, et al (2019). Identification of a distinct subset of disease-associated gain-of-function missense mutations in the *STAT1* coiled-coil domain as system mutants. *Mol Immunol*, 114:30-40.
11. Tariq Al, Kimberly G, Florian G et al (2019). Novel Gain-of-Function Mutation in Stat1 Sumoylation Site Leads to CMC/CID Phenotype Responsive to Ruxolitinib. *J Clin Immunol*, 39(8):776-785.
12. Glenn TC, Nilsen RA, Kieran TJ, et al (2019). Adapterama I: universal stubs and primers for 384 unique dual-indexed or 147,456 combinatorially-indexed Illumina libraries (iTru & iNext). *PeerJ*, 7: e7755.