



# Tracking of Infectious Diseases in Shahr-i Sokhta (Burnt City) during the Bronze Age (ca. 3200-2200 BCE) through Anemic Signs Observed in Excavated Human Skeletons

Negar Bizhani<sup>1,2</sup>, Giorgia Vincenti<sup>3</sup>, Seyyed Mansur Seyyed Sajjadi<sup>4</sup>, Jean Dupouy-Camet<sup>5</sup>,  
Rouhollah Shirazi<sup>6</sup>, Mehdi Nateghpour<sup>1,2</sup>, Faranak Kargar<sup>7</sup>, Vahid Shariati<sup>8</sup>,  
\*Pier Francesco Fabbri<sup>9</sup>, \*Gholamreza Mowlavi<sup>1,2</sup>

1. Department of Medical Parasitology and Mycology, School of Public Health, Tehran University of Medical Sciences, Tehran, Iran
2. Center for Research of Endemic Parasites of Iran, Tehran University of Medical Sciences, Tehran, Iran
3. Cultural Heritage Department, Physical Anthropology Laboratory, University of Salento, Lecce, Italy
4. Iranian Center for Archaeological Research (ICAR), Tehran, Iran
5. Parasitology-Mycology Department, Cochon Public Assistance Hospital Paris Hospitals, Paris Cité University, Paris, France
6. Department of Archaeology, Faculty of Literature and Humanities, University of Sistan and Baluchestan, Zabadan, Iran
7. Rajaie Cardiovascular Medical and Research Center, Iran University of Medical Sciences, Tehran, Iran
8. National Institute of Genetic Engineering and Biotechnology, Tehran, Iran
9. Museo e Istituto Fiorentino di Preistoria, via S. Egidio 21, 50122 Firenze, Italy

\*Corresponding Authors: Emails: molavig@yahoo.com, pierfrancesco.fabbri@unisalento.it

(Received 19 Jul 2023; accepted 14 Sep 2023)

## Abstract

**Background:** The intriguing area of paleopathology merges the disciplines of archeology and biological studies. Using this line of research, it is possible to identify diseases that have left skeletal traces in the past. In addition, diseases such as various anemia that occur in childhood, when bone tissue is soft and retains evidence, can be identified in ancient bones. Cribra orbitalia (Co), cribra cranii (Cc), and porotic hyperostosis (Ph) were ancient skeletal remains' most common degenerative anomalies.

**Methods:** Shahr-i Sokhta dated back to 3200-1800 BCE, is the subject of our research; it is located in Sistan and Baluchistan province (Iran). The research was done on the archaeological data collected during the MAIPS expeditions at Shahr-i Sokhta (2017–2021) kept at the storage of the excavated materials on the site. The skeletal remains were examined for bone abnormalities such as Co, Cc, and Ph. These symptoms were analyzed to obtain traces of anemia-related diseases at this site. Data has been utilized following the Data Collection Codebook

**Results:** Ninety-six adults were studied while the anemic signs of CC and Co are respectively seen in 27/72 (37.5 %) and 10/57 (17; 5 %), and these samples have been kept for future analysis.

**Conclusion:** Bones may narrate a person's life, their gender and how old they were when they died besides the diseases they had. Some of the skeletons show signs of anemia, Classical paleopathology lets us to re-confirm studying diseases by further targeted sampling using molecular methods.

**Keywords:** Paleopathology; Human remains; Ancient skeletons; Infectious diseases, Iran

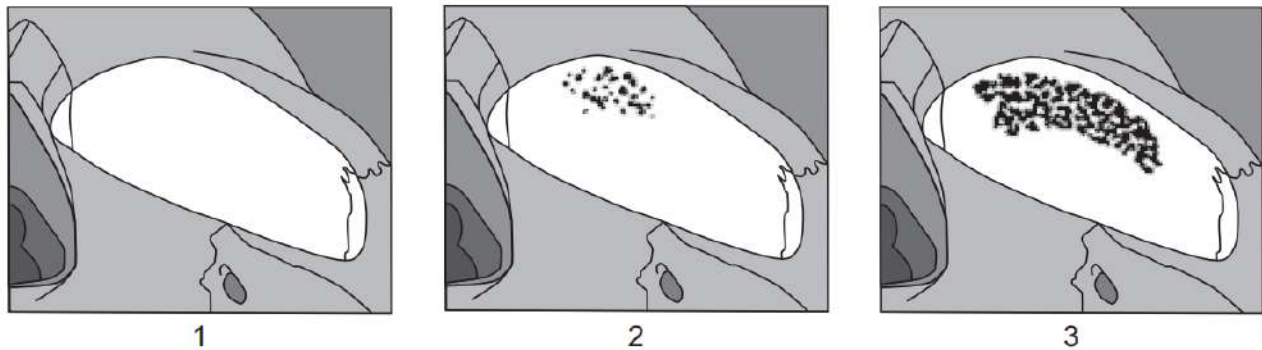


## Introduction

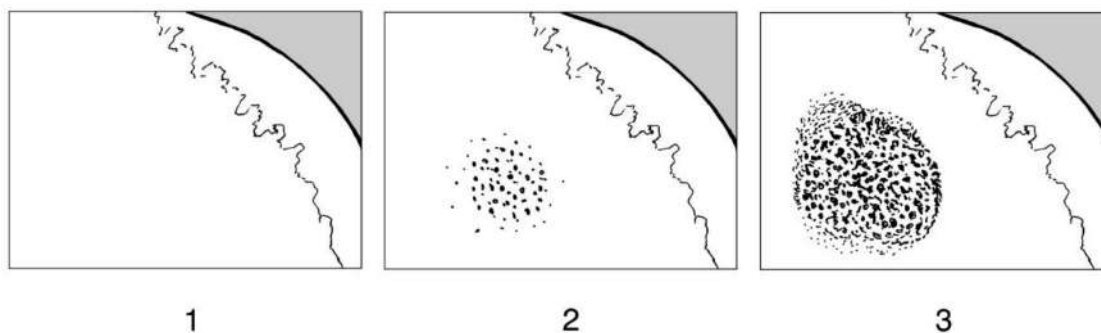
Paleopathology is the study of disease signs in ancient humans and animal remains. Abnormalities, injuries, and diseases can be found in these remains. This research helps answer multidisciplinary questions in medicine, anthropology, biology, and archaeology. Some, such as anemias in childhood when bone tissue is soft and retains evidence, can be identified in ancient human bones. By using careful archaeological analysis of ancient skeletons or mummy tissues, paleopathologists can sometimes preliminarily diagnose infectious diseases and determine some causes of death (1). Here, Cribra orbitalia (Co) (Fig. 1), Porotic hyperostosis (Ph) (Fig. 2), and Cribra cranii (CC) (Fig. 3) are among the most common degenerative skeletal anomalies that can be witnessed. (2) Co refers to lesions on the orbital roof, and Cc refers to vault lesions on the parietal and occipital bones (3): Co and Cc can be considered variants of Ph (4). Ph is an over-

growth of the skull's spongy bone marrow space (5). In anemia, the hemoglobin concentration decreases, resulting in lower oxygen levels. (6) Furthermore, the increase of erythropoietin hormone results in hypertrophy or hyperplasia due to the expansion of the bone marrow, leading to atrophy, bone loss, and holes (7, 8). In moderate cases, lesions appear as holes in the outer cortical layer of the bone in childhood and may even persist into adulthood (9) (10).

Porotic hyperostosis (Ph) is characterized by minor pitting or severe porosity on non-orbital, external surfaces of the skull (ectocranial surfaces), and orbital lesions called Cribra orbitalia (Co) (11). Chronic iron deficiency anemia is a possible cause of Ph. Researchers suspect that dietary iron deficiency, iron malabsorption, and blood loss from diarrheal diseases and intestinal parasites in ancient populations may have contributed to the prevalence of these disorders. (12)



**Fig.1:** Standard for Scoring *Co*. Modified after Steckel et al (11) *Co* is characterized by slight pitting or extensive porosity of the eye orbits' roofs. Researchers have linked these alterations to diseases most frequently acquired and inherited anemia, infections, and vitamin deficiencies. When macroscopically diagnosed, this sign is probably best regarded as a stress indicator rather than a specific disease. To qualify for the condition, at least one eye's orbital roof must be present



**Fig. 2:** Standard for scoring *Porotic hyperostosis*. Modified after Steckel et al(11) Porotic hyperostosis (Ph) involves slight pitting or extensive porosity on non-orbital, ectocranial surfaces. Porotic changes are most prevalent in the squamosal portions of the occipital and parietal bosses and occur less frequently on the frontal, temporal, sphenoid, and maxillary bosses. Porotic hyperostosis, like *cribra orbitalia*(Co) and *cribra carinii* (Cc), has been linked to various conditions, including anemia (acquired and inherited), infections, and vitamin deficiencies

Determining the origin of some anemia disorders such as iron deficiency anemia (IDA), anemia of chronic disease, megaloblastic anemia, and genetic hemolytic anemias such as thalassemia and sickle cell anemia can be challenging in some cases (13, 14). Among different causes of anemia that can appear as skeletal signs, infectious diseases are of particular importance (15). Since diverse affecting agents may produce direct and indirect changes in the skeleton, bone remains represent significant sources in studying these items (15). According to available archaeological documents, the Shahr-i Sokhta archaeological site, the "burnt city" in our present study area, has been burned three times. It is worth mentioning that few wars are recorded in this ancient city, and no war tools have been excavated there (16). The burnt bodies and towns have always been seen as historical reminders of the importance of preventing epidemic infectious diseases, mainly plague (17, 18), the deadly infection caused by *Yersinia pestis* since the Bronze Age (19). Regarding the name of this ancient site, the "burnt city," the probability of burning caused by infectious diseases has always been speculated from the perspective of paleopathology. Nevertheless, there is no shred of evidence concerning the use of fire on this site in the Bronze Age against epidemics with the exception of one skeleton show-

ing signs of combustion, most probably indicating an unintentional building fire. To know more about this issue, a precise molecular investigation relying on modern techniques using more samples is needed in our future ongoing programs. Malaria due to its causative agent *Plasmodium falciparum* has afflicted Southeast Asia for at least 7,000 years, or much longer, and could lead to anemia by destroying red blood cells (20). Previous studies have documented the link between malaria, anemia, iron deficiency, and the development of both *Cribrra cranii* (Cc) and *Porotic hyperostosis* (Ph) (21-23). Notably, Ph was more prevalent among early farmers (7th-2nd millennia BC) living in marshy areas of Anatolia, Greece, and Cyprus – environments suitable for the *Anopheles* mosquito, a malaria vector. In contrast, Ph was less common among people living in dry or rocky areas, or those who were Paleolithic hunters. This distribution pattern aligns with the spread of *Plasmodium falciparum*, the malaria parasite, through the Old World's anopheline belts, where many cases of Ph are observed in ancient skeletons (5). Our current study in Sistan and Baluchistan, a well-known malarial endemic region in Iran (24-26), aimed to investigate the expected prevalence of malaria and other historical infectious diseases that might leave bone markers like *Cribrra orbitalia* (Co) (27).



**Fig. 3:** Signs of Cc. Skull with Cc. Porotic hyperostosis is consequent in the diploic layer's hypertrophy and cortical tissue thinning due to increased red blood cell production activity induced by the anemic conditions (burial number 9606). Cc and Co are external manifestations of Ph.

### **Material and Methods**

Shahr-i Sokhta (Fig. 4) or also called "Burnt City," is located 56 kilometers southwest of Zabol alongside the road to Zahedan. The site is located in Sistan and Baluchistan province (Fig. 5), which forms a part of the Indo-Iranian Borderlands. Climatologically speaking, it is among the driest parts of the eastern Iranian Plateau (28). Firstly, from 1967 to 1978, excavations were conducted by the Italians and later Iranian researchers resumed the excavations from 1997 up to now, uncovering approximately 1,100 burials out of about 40,000 inhumations (29, 30) in the cemetery (Fig. 6). The site's cultural sequence covers about 1400 years and is divided into four

main chronological periods. The graveyard, separated from the residential areas, consists of about 25 ha, which could be considered among the largest cemeteries of the ancient world. The dating has been done according to the styles of pottery in the burials. The pottery styles correspond to the four periods that have been identified within the site and that have been dated in this way (31). The research was done on the archaeological data collected during the MAIPS (Multi-disciplinary Archaeological Italian Project at Shahr-i Sokhta) expeditions at Shahr-i Sokhta (2017–2021) kept at the storage of the excavated materials on the site.



**Fig. 4:** Aerial photo of Shahr -i Sokhta

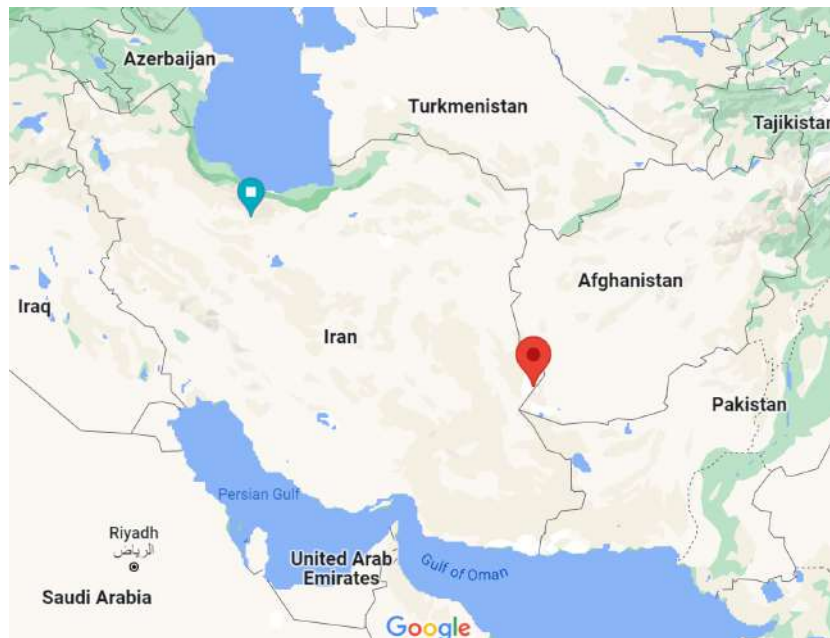

Fig. 5: The location of Burnt City in eastern Iran



Fig. 6: Shahr-i Sokhta cemetery

Out of 96 adult individuals we studied: 33 are males and 55 are females, 8 individuals were undetermined and all have been determined over 18 years of age. The high number of females compared to males respects the percentage present in the necropolis as confirmed by recent studies (32). Due to the significance of these lesions on bones, scientists have worked on grading these

lesions. The *CC* and *CO* were taken following the indications of Steckel et al (11) (Table 1). Data has been utilized following the Data Collection Codebook. This book for the Global History of Health Project (GHHP) aids in documenting and analyzing health records in different groups from the late Paleolithic to the modern era.

**Table 1:** Standard for scoring *Co* and *Cc* after Steckel et al (11)

<i>Co</i>	
0	No orbits present for observation
1	Absent with at least one observable orbit
2	A cluster of mostly fine foramina covering a small area ( $\leq 1$ cm <sup>2</sup> )
3	Substantial area ( $> 1$ cm <sup>2</sup> ) covered by small and/or larger foramina with a tendency to cluster together.
<i>Cc</i>	
0	No parietals present for observation
1	Absent with at least one observable parietal
2	Presence of slight pitting or severe parietal porosity
3	Gross parietal lesion with excessive expansion and exposed diploe

## Results

We detected the presence of *Cc* on the parietals and *Co* (Fig. 7) on the eye sockets on 96 skeletons. In the first step, we checked whether a skull bone existed to check the cribras. In some samples, there were no suitable items for examination. We found 27/72 *Cc* (Tab. 2) and 10/57 *Co* (Tab. 3) :considering that the *cribra* are bilateral, we have considered the detectability for each in-

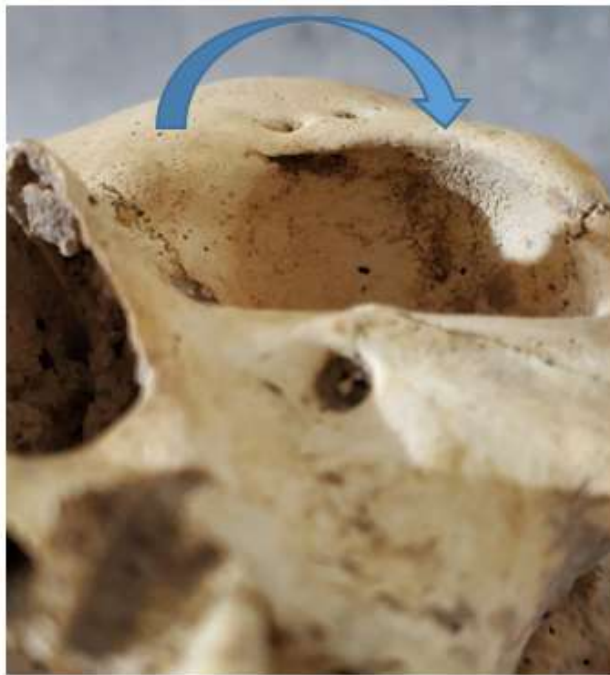dividual, even with only one parietal or orbital *Cc* was observable in 45 females, which means we could search for it, and was present in 14 females; this sign was observable in 24 males and present in 12; of 3 unsexed, it was present in 1. *Co* was observable in 38 individual's female and was present in 7 individuals; in males, they were observable in 14 individuals and were present in 2 individuals; in 5 individuals, unsexed and were present in 1 case.

**Table 2:** *Cribra cranii* detected in the sample. n indicate the number of parietals present; n=0 indicates the number of absent or unobservable sites; n (=1) the number of observed sites where cribras were absent; n(=2) the number of sites where *cribra* were mildly present; n(=3) severe forms of *cribra*. Composition of the samples. % n = Percentage of signs present. Percentages are made from observable sites

<i>Cribra cranii</i>	n	n (=0)	n (=1)	n (=2)	n (=3)	%n (=1)	%n (=2)	%n (=3)
Female	110	23	60	25	2	68.96	28.73%	2.29
Male	66	19	24	23	0	51.06	48.93%	0.00
unsexed	16	11	3	2	0	60.00	40.00%	0.00
Total	192	53	87	50	2	62.59	35.97%	1.44

**Table 3:** *Cribra orbitalia* detected in the sample. n indicates the number of orbital present; n=0 indicates the number of absent or unobservable sites; n (=1) the number of observed sites where cribras were absent; n(=2) the number of sites where *cribra* were mildly present; n(=3) severe forms of *cribra*. Composition of the samples. % n = Percentage of signs present. Percentages are made from observable sites

<i>Cribra orbitalia</i>	n	n (=0)	n (=1)	n (=2)	n (=3)	%n (=1)	%n (=2)	%n(=3)
Female	110	37	59	14	0	80.82	19.17%	0.00
Male	66	36	26	4	0	86.66	13.33%	0.00
unsexed	16	7	7	2	0	77.77	22.23%	0.00
Total	192	80	92	20	0	82.14	17.85%	0.00



**Fig .7:** Signs of *Co*. This skeleton was discovered in 2005 during the excavation of the burnt city (trench number HYA 10; burial number: 5603). The holes present on the orbital roof of this skeleton can indicate traces of anemia during its life.

## Discussion

The presence of anemia markers in Bronze Age skeletons from the "burnt city" suggests the people may have suffered from infectious or congenital diseases, improper diet, or other health conditions.

According to available publications, studying skeletal remains from 5,000 years ago or even earlier can provide insights into the prevalence of ancient infectious diseases using advanced modern techniques (33, 34). By leveraging interdisciplinary research, we can answer a wide range of questions concerning the health and disease burden of our ancestors. Macroscopic examination of excavated bones with signs of disease can guide researchers to select appropriate specimens for further, more precise molecular tests. These tests, however, are expensive and time-consuming (35, 36).

In this study, during a wide observation of stored excavated bones of Shahr-i Sokhta, some of the available human skeletons were precisely examined to identify the possible existence of infec-

tious diseases on that time. *Co*-described upper orbital lesions are typically in an active state of bone remodeling in children, while they may have begun to recover in affected adults (12). Although a recent research indicates that *Co* might not be related to anemia [38], this skeletal sign that frequently were observing among ancient humans' pathological lesions for years has been widely accepted as the probable cause of chronic iron-deficiency (12) although a recent research indicates that *Co* might not be related to anemia (37). Examining *Co* is however valuable even for anatomists and radiologists in interpreting the radiographs (38). Hominins and non-human primates have also exhibited porotic lesions of the skull, including *Co* and *Ph* that might be due to anemia (2). Infectious diseases could induce *Co* in humans, which has been the main core of several articles in paleopathology as a practical aspect to study ancient infectious diseases (5, 15, 39-41). Meanwhile, researchers have stated that although the *Ph* and *Co* lesions that can be attributed to anemia and infectious diseases the

evidence of bone marrow expansion is also required to confirm it (2).

In this meantime the initial reason that attract our attention to look for infectious diseases in the Shahr i Sokhta archeological site is the ash layers observable throughout the city, which was revealed by archaeologists demonstrating the background of burning led to call there the burnt city (42). Concerning the studied archeological site that has apparently burned three times (43), archaeologists have not yet definitely answered the cause of this puzzle despite of a large range of wooden appliances has been obtained in the Shahr-i Sokhta (44). Nevertheless, only one individual's skeleton in this site exhibits burning signs, suggesting dying in an unintended structure fire (45). Conclusively and according to archeo-

logical excavations over the years and the revealing of diverse types of unearthed objects, the hypothesis of the cause of an ancient infectious epidemic in burning in this city can be overlooked.

Using the criteria of the Data Collection Codebook (11), the morphology of ancient bones has been examined in some research studies. For example, in a study, skeletons belonging to 4780–5450 BC were examined macroscopically according to the standard published criteria in the data code book, and rib lesions were graded in five categories (0–4) for the presence of tuberculosis (46). In another study, changes and joint degeneration of upper limb bones in males and females in medieval Giecz, Poland, were investigated with the use of this book (47).

**Table 4:** Stratigraphy of Shahr-I Sokhta After: Gunnar Heinsohn Thrice Burned: Shahr-I Sokhta in the Sistanbasin (42)

<i>Variable</i>	<i>Conventional Dating</i>	<i>Dating from evidence</i>
After unexplained gap of 1500 years until building of nearby Achaemenid city of Dahan-i Gulaman	6 centuries	6 centuries
Period IV Use ruins reduced to max. 20 ha parallel to UR-III-"sumer"	from 2100	7 century Medes
Third, last and most thorough FIRE Period III	until 2100	Fall of Assyrian empire of Ninus. 8/7 century
Cultural climax parallel to period of Akkad on surface over 100 ha. Imported ceramics from Mundigak (Afganistan) and the Quetta-Valley (Pakistan) Linen, preserved under a salt-crust, contemporaneous with Troy II; Ugarit II	From 2500/2400	
Period II	Second FIRE until 2500/2400 from 2800	9 centuries
Parallel with early dynastic period II/III on 45 ha. Making of beads of semi-precious stone. Spinning and weaving of wool. Artificial eye		
Period I parallel with early dynastic time I Late neolithic	First Fire until 2800	9 centuries
Early urban on maximum 20 ha. Proto-elamic cuneiform table and seal	from 3200	



The advanced approach in paleopathology frequently inspire the implementing of new, sophisticated technical methods. The development of new, sophisticated technical methods. However, data gathering and macroscopic interpretation form the foundation of all skeletal analyses (48). Anemia, stress, and mortality in a historic Portuguese skeletal sample were identified using the Global Health History Project (GHHP) (11). This study determined the incidence and prevalence of porotic hyperostosis and cribra orbitalia as a measure of population health in a Portuguese sample with known demographic information (49).

The main focus on this study was to look for the status of infectious diseases with specific regard to malaria by finding the signs of anemia by successful tracking of few paleopathological indications among 96 individuals. Although the increase in sample size could have tracked more signs of the presence of infectious diseases like malaria in this archeological site, we should not ignore the heritage and cultural limitations faced by the researchers. A message whose role is to preserve ancient works. This is when paleoparasitological investigations in 2017, has documented only one *Physaloptera* spp. parasite out of 320 studied skeletons in this archeological site (50). Releasing the present paper indicates more investigations still needed to be conducted to achieve more information on the health status of this ancient site. Many skeletons are still underground and have not been excavated. In addition, many of the skeletons examined in this study were incomplete in anatomical structure.

## Conclusion

In this study, the presence and severity of the most frequent degenerative skeletal anomalies, including *Co*, *Ci*, and *Pb*, were evaluated in skeletons. These characteristics can guide researchers in obtaining samples appropriate for further excavations in future plans. Bones include information about a person's life, such as their origin, their age at death, and the diseases they endured.

Researchers can infer much about a person's life and human evolution from them. Tracing the diseases of the distant past is actually indebted to the visible pathological signs in the excavated skeletons which the causative pathobiological agents of these disorders can also be confirmed using modern diagnostic techniques. In addition, having information about the past and the epidemics and diseases that we can find evidence of is a powerful tool to understand the conditions of the world today. These findings are also helpful to predict the possible emerging and/or reemerging diseases in the future. With more specialized studies and biological investigations of ancient skeletons, we hope to answer several of basic and challenging questions for archaeologists. Paleopathology has made a lot of progress, but future research can do a lot more to help make sense of what has been learned about health and disease in the past.

## Journalism Ethics considerations

Ethical issues (Including plagiarism, informed consent, misconduct, data fabrication and/or falsification, double publication and/or submission, redundancy, etc.) have been completely observed by the authors.

## Acknowledgements

Heartfelt thanks go to Professor Enrico Ascalone, director of the MAIPS mission at the University of Salento, and to MAECI (Ministry of Foreign Affairs for International Cooperation) and Tehran University of Medical Sciences, which supported this research project.

## Conflict of interest

The authors declare that they have no conflicts of interest.

## References

1. Metcalfe NH (2007). In what ways can human skeletal remains be used to understand health

- and disease from the past? *Postgrad Med J*, 83 (978):281-284.
2. Brickley MB (2018). Cribra orbitalia and porotic hyperostosis: A biological approach to diagnosis. *Am J Phys Anthropol*, 167 (4):896-902.
  3. Scaffidi BK (2020). Spatial paleopathology: A geographic approach to the etiology of cribrotic lesions in the prehistoric Andes. *Int J Paleopathol*, 29:102-116.
  4. Buikstra JE (1994). Standards for data collection from human skeletal remains. *Arkansas archaeological survey research series*, 44.
  5. Angel JL (1966). Porotic hyperostosis, anemias, malaras, and marshes in the prehistoric eastern Mediterranean. *Science*, 153 (3737):760-763.
  6. Brauner CJ, Wang T (1997). The optimal oxygen equilibrium curve: a comparison between environmental hypoxia and anemia. *Am Zool*, 37 (1):101-108.
  7. Jelkmann W (1992). Erythropoietin: structure, control of production, and function. *Physiol Rev*, 72 (2):449-489.
  8. Bhoopalan SV, Huang LJ-s, Weiss MJ (2020). Erythropoietin regulation of red blood cell production: From bench to bedside and back. *F1000Res*, 9:F1000 Faculty Rev-1153.
  9. Rivera F, Mirazón Lahr M (2017). New evidence suggesting a dissociated etiology for cribra orbitalia and porotic hyperostosis. *Am J Phys Anthropol*, 164 (1):76-96.
  10. Mays S (2018). How should we diagnose disease in palaeopathology? Some epistemological considerations. *Int J Paleopathol*, 20:12-19.
  11. Steckel RH, Larsen CS, Sciulli PW, et al (2006). Data collection codebook. *The global history of health project*, 1-41.
  12. Walker PL, Bathurst RR, Richman R, et al (2009). The causes of porotic hyperostosis and cribra orbitalia: A reappraisal of the iron-deficiency-anemia hypothesis. *Am J Phys Anthropol*, 139 (2):109-125.
  13. Hoffbrand AV, Moss P (2018). *Fundamentos em hematologia de Hoffbrand*. 7th ed. Artmed Editora, Spagna.
  14. Kujovich JL (2016). Evaluation of anemia. *Obstet Gynecol Clin North Am*, 43 (2):247-264.
  15. Carlson DS, Armelagos GJ, Van Gerven DP (1974). Factors influencing the etiology of cribra orbitalia in prehistoric Nubia. *J Hum Evol*, 3 (5):405-410.
  16. Fabbri PF, Vincenti G (2022). Excavations and Researches at Shahr-i Sokhta 3. Traumatology in a Human Sample from the Necropolis of Shahr-i Sokhta. In: *Excavations and Researches at Shahr-i Sokhta 2*. Eds, Ascalone and Sajjadi, Pishin Pajouh, Teheran, pp. 623-644.
  17. Mohr JC (2004). *Plague and Fire: Battling Black Death and the 1900 Burning of Honolulu's Chinatown*. Oxford University Press, Oxford.
  18. Leason J (2001). *The plague and the fire*. House of Stratus, Cornwall.
  19. Glatzer KA, Finkelman P (2021). History of the Plague: An Ancient Pandemic for the Age of COVID-19. *Am J Med*, 134 (2):176-181.
  20. Ferrando-Bernal M (2023). Ancient DNA confirms anaemia as the cause for Porotic Hyperostosis in ancient Neolithics together with a genetic architecture for low bone mineral density. *medRxiv*: 23284324.
  21. Adam I (2016). Anemia, iron supplementation and susceptibility to Plasmodium falciparum malaria. *EBioMedicine*, 14:13-14.
  22. Spottiswoode N, Duffy PE, Drakesmith H (2014). Iron, anemia and hepcidin in malaria. *Front Pharmacol*, 5:125.
  23. Oxenham MF, Cavill I (2010). Porotic hyperostosis and cribra orbitalia: the erythropoietic response to iron-deficiency anaemia. *Anthropol Sci*, 118 (3):199-200.
  24. Edrisian GH (2006). Malaria in Iran: Past and present situation. *Iran J Parasitol*, 1:1-14.
  25. Sargolzaie N, Salehi M, Kiani M, et al (2014). Malaria Epidemiology in Sistan and Balouchestan Province during. *Zabedan Journal of Research in Medical Sciences*, 16 (4):41-43.
  26. Mohammadkhani M, Khanjani N, Bakhtiari B, et al (2019). The relation between climatic factors and malaria incidence in Sistan and Baluchestan, Iran. *Sage Open*, 9 (3):2158244019864205.
  27. Smith NE (2015). *The paleoepidemiology of malaria in the Ancient Near East*. University of Arkansas.
  28. Biscione R, Salvatori S, Tosi M (1977). Shahr-i Sokhta: l'abitato protostorico e la sequenza cronologica. In In G. Tucci, La Città Bruciata nel Deserto Salato. Ed Tucci, Erizzo, pp77-112.
  29. Sajjadi S, Foruzanfar F, Shirazi R, et al (2003). Excavations at Shahr-i Sokhta first

- preliminary report on the excavations of the graveyard, 1997–2000. *Iran*, 41 (1):21-97.
30. Ascalone E, Fabbri P.F (2022). Demographic Considerations Regarding the Settlement and Necropolis of Shahr-i Sokhta. In: *Excavations and Researches at Shahr-i Sokhta 2*. Eds, Ascalone and Sajjadi, Pishin Pajouh, Teheran, pp 523-554.
  31. Ascalone E (2022). Preliminary Report on the 2018-2019 Excavations in Area 33 at Shahr-i Sokhta. In: *Excavations and Researches at Shahr-i Sokhta 3*. Eds, Ascalone and Sajjadi, Pishin Pajouh, Teheran, pp.143-232.
  32. Fabbri PF, Vincenti G (2021). Adult sex ratio in the necropolis of Shahr-i Sokhta and in Bronze Age Bactria Margiana, and Indus Valley sites. *Journal of Sistan and Baluchistan Studies*, 1 (1):11-19.
  33. Jörg F, Samida S (2016). Why archaeologists, historians and geneticists should work together—and how. *Medieval Worlds*, 4:5-21.
  34. Grauer AL (2018). Paleopathology: from bones to social behavior. *Biological anthropology of the human skeleton*:447-465.
  35. Kontopoulos I, Penkman K, Mullin VE, et al (2020). Screening archaeological bone for palaeogenetic and palaeoproteomic studies. *PLoS One*, 15 (6):e0235146.
  36. Schultz M (2001). Paleohistopathology of bone: a new approach to the study of ancient diseases. *Am Phys Anthropol*, Suppl 33:106-47.
  37. Rothschild BM, Zdilla MJ, Jellema LM, et al (2021). Cribra orbitalia is a vascular phenomenon unrelated to marrow hyperplasia or anemia: Paradigm shift for cribra orbitalia. *Anat Rec (Hoboken)*, 304 (8):1709-1716.
  38. Chaichun A, Yurasakpong L, Suwannakhan A, et al (2021). Gross and radiographic appearance of porotic hyperostosis and cribra orbitalia in thalassemia affected skulls. *Anat Cell Biol*, 54 (2):280-284.
  39. Smith-Guzman NE (2015). Cribra orbitalia in the ancient Nile Valley and its connection to malaria. *Int J Paleopathol*, 10:1-12.
  40. O'Donnell L, Hill EC, Anderson ASA, et al (2020). Cribra orbitalia and porotic hyperostosis are associated with respiratory infections in a contemporary mortality sample from New Mexico. *Am J Phys Anthropol*, 173 (4):721-733.
  41. Godde K, Hens SM (2021). An epidemiological approach to the analysis of cribra orbitalia as an indicator of health status and mortality in medieval and post-medieval London under a model of parasitic infection. *Am J Phys Anthropol*, 174 (4):631-645.
  42. Heinsohn G (2011). Thrice Burned: Shahr-i Sokhta in the Sistanbasin.
  43. Mortazavi M (2007). Mind the Gap: Continuity and Change in Iranian Sistan Archaeology. *Near Eastern Archaeology*, 70 (2):109-110.
  44. Sajjadi SMS, Moradi H (2014). Excavation at Buildings Nos. 1 and 20 at Shahr-i-Sokhta. *International Journal of the Society of Iranian Archaeologists*, 1 (1):77-90.
  45. Tosi M (1983). Excavations at Shahr-i Sokhta 1969-70. *Prehistoric Sistan*, 1:73-125.
  46. Nicklisch N, Maixner F, Ganslmeier R, et al (2012). Rib lesions in skeletons from early neolithic sites in Central Germany: on the trail of tuberculosis at the onset of agriculture. *Am J Phys Anthropol*, 149 (3):391-404.
  47. Brzezinski ET, Agnew AM (2022). Enthesal Changes and Joint Degeneration of Upper Limb Bones in Males and Females in Medieval Giecz, Poland. *Am J Biol Anthropol*, 111: 24-24.
  48. Grauer AL (2007). Macroscopic analysis and data collection in palaeopathology. In: *Advances in human palaeopathology*: 57-76.
  49. Macak KM (2013). Anemia, stress, and mortality in an historic Portuguese skeletal sample. California State University, Sacramento.
  50. Makki M, Dupouy-Camet J, Sajjadi SMS, et al (2017). Human spiruridiasis due to *Physaloptera* spp.(Nematoda: Physalopteridae) in a grave of the Shahr-e Sukhteh archeological site of the Bronze Age (2800–2500 BC) in Iran. *Parasite*, 24:18.