



# Comparison of the Effect of Sling and Single Interrupted Sutures on Periodontal Parameters after Surgical Extraction of Impacted Mandibular Third Molars

Farzad Aghdashi<sup>1</sup>, Nasrin Roohandeh<sup>2\*</sup>, Majid Nemati<sup>1</sup>, Reza Tabrizi<sup>1</sup>

1. Department of Oral and Maxillofacial Surgery, Dental School, Shahid Beheshti University of Medical Sciences, Tehran, Iran
2. Private Practice, Tehran, Iran

## Article Info

**Article type:**  
Original Article

**Article History:**  
Received: 4 Oct 2019  
Accepted: 23 Mar 2020  
Published: 25 Aug 2020

**\* Corresponding author:**  
Private Practice, Tehran, Iran

Email: nassrin.rhnd@gmail.com

## ABSTRACT

**Objectives:** This study aimed to compare the sling and single interrupted sutures regarding dehiscence, probing pocket depth (PPD), and clinical attachment loss (CAL) of adjacent second molars after surgical extraction of impacted or semi-impacted mandibular third molars.

**Materials and Methods:** This randomized clinical trial, with a split-mouth design, involved 25 patients with similar bilateral impaction of their mandibular third molars. The same surgeon performed surgical procedures, including a triangular flap and osteotomy. After surgical extraction of third molars, the distal surface of the flap was sutured with sling sutures on one side and single interrupted sutures on the other side. The allocation of suture type to the side of the jaw was random, and the patient was blinded to it. Patients were examined for dehiscence after 7 and 14 days. The PPD and CAL were recorded at the baseline and after 17 weeks. Data were analyzed using the Wilcoxon signed-rank test and generalized estimating equation (GEE) regression model.

**Results:** The sling suture was significantly superior regarding the improvement of PPD ( $P=0.041$ ) and CAL ( $P=0.016$ ). The dehiscence was significantly smaller in the single interrupted suture group 7 days postoperatively ( $P=0.059$ ). This difference was not significant 14 days postoperatively ( $P=0.852$ ).

**Conclusion:** The results of this study show that the sling suture was superior to the single interrupted suture regarding PPD and CAL. However, the technique of suturing does not seem to have a significant long-term effect on wound dehiscence.

**Keywords:** Suture Techniques; Periodontal Attachment Loss; Periodontal Pocket

- **Cite this article as:** Aghdashi F, Roohandeh N, Nemati M, Tabrizi R. Comparison of the Effect of Sling and Single Interrupted Sutures on Periodontal Parameters after Surgical Extraction of Impacted Mandibular Third Molars. *Front Dent.* 2020;17:15. doi:

## INTRODUCTION

In general, 90% of the world's population have third molar teeth, which are impacted in 33% of the cases [1]. Surgical extraction of impacted third molars traumatizes the hard and soft tissues. Resultantly, patients often experience pain, edema, and trismus postoperatively, which decrease their quality

of life [2-7].

Wound dehiscence (separation of wound edges) is among the complications that can delay wound healing. Dehiscence often occurs due to two main reasons, namely the absence of a sufficient amount of bone beneath the flap and suturing the wound under tension [8]. Primary closure of the flap decreases the

incidence of dehiscence after suturing and improves wound healing. In some cases, dehiscence may occur secondarily and heal with no complication. However, patients experience discomfort and constant pain during this period. Moreover, dehiscence may result in alveolar osteitis or clinical attachment loss (CAL) at the distal surface of the adjacent second molar tooth [9]. Periodontal problems at the distal surface of the second molars are among other possible complications following surgical extraction of impacted mandibular third molars [10]. Age, third molar inclination, large contact area, visible plaque on the distal surface of second molars, and pathologically enlarged third molar follicles are among the risk factors related to periodontal pocket formation around second molars adjacent to impacted third molars [11]. Surgeons can take measures to minimize the risk of postoperative complications [8].

There is controversy regarding the effects of techniques of wound closure following third molar extraction surgery on the rate of complications. Wound closure can be categorized into two types of primary and secondary closure. Primary closure is defined as primary complete coverage of the surgical site with the mucoperiosteum. In secondary closure, a window remains, which is managed secondarily [12]. Plaque accumulation affects wound healing, and dehiscence occurs due to the presence of inflammation. Unlike the single interrupted suture, the knot in the sling technique is located far from the distal surface of second molars where dehiscence mostly occurs [13-15]. Different suturing techniques are employed for advanced soft tissue closure [16]. The single interrupted suture is used to approximate the buccal and lingual flaps. The sling suture is also used to prevent gingival recession around teeth and dental crowns [8]. Sling sutures are used to cover the exposed root surfaces in advanced flap surgeries and to attach the papilla to the interdental connective tissue [17]. The efficacy of single interrupted and sling sutures after impacted third molar extraction surgery has not been compared so far. Considering the advantages of sling

sutures in decreasing postoperative complications, this study aimed to compare sling and single interrupted sutures in terms of dehiscence, probing pocket depth (PPD), and CAL around the adjacent second molar tooth after surgical extraction of third molars to find out whether the sling suturing technique can decrease postoperative complications.

## MATERIALS AND METHODS

This split-mouth randomized clinical trial involved patients with impacted mandibular third molars requiring surgical extraction. The study has been approved by the Ethics Committee of Shahid Beheshti University of Medical Sciences (IR.SBMU.RIDS.REC.1396.523) and was registered on October 17, 2017. This trial has been approved by the Iranian Registry of Clinical Trials (IRCT2017100436551N1). The variables were PPD, CAL, and dehiscence, which were evaluated after surgical procedures.

The inclusion criteria were as follows: patients with equal bilateral soft tissue coverage over their bilateral semi-impacted or impacted mandibular third molars. The degree of impaction was determined according to a classification by Pell and Gregory [18]. The soft tissue coverage over the teeth was determined using a probe. Patients were between 18 to 25 years of age, non-smokers, systemically healthy, not pregnant or nursing, and not taking any medication within the past six months; they had no inflammatory condition (such as acute pericoronitis or periodontal disease). The Simplified Oral Health Index (OHI-S) was calculated through the sum of two other indicators (debris index and calculus index) on six specific teeth. The index was interpreted based on the intervals of the final score as follows: 0-1.2 (good hygiene), 1.3-3 (moderate hygiene), and 3.1-6 (poor hygiene) [19].

In this study, we used the OHI-S for the evaluation of the patients' oral hygiene; patients with good hygiene were included in the study. The plaque index was used for the evaluation of plaque, and patients with scores

0 and 1 were accepted [20]. After the surgical procedure, oral hygiene instructions were emphasized; the patients had the same index in recall meetings.

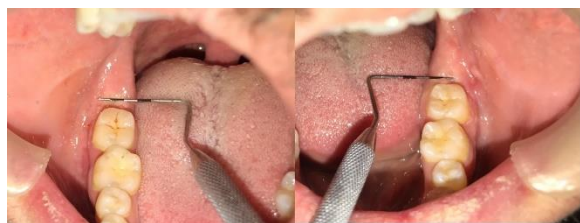The exclusion criteria included patients with asymmetrically impacted teeth, the presence of inflammation in the oral cavity, poor oral hygiene, and a high plaque index.

The sample size was calculated to be 18 to 20 according to a previous study by Cetinkaya et al [21], assuming a minimum of 1mm difference in CAL between the two suturing techniques, a standard deviation (SD) of 0.9 mm,  $\alpha=0.05$ , and  $\beta=0.1$ . Patients who were candidates for surgical extraction of impacted mandibular third molars were subjected to clinical and radiographic (panoramic view) examinations. Patients had to have bilateral impacted or semi-impacted mandibular third molars with a similar radiographic appearance and clinical conditions. Semi-impacted teeth were defined as teeth that soft tissue covered at least half of their occlusal surface while the other half was exposed to the oral environment.

All patients received information about the surgical procedure and possible complications in addition to postoperative instructions. All patients signed informed consent forms.

#### *Measurement of clinical parameters:*

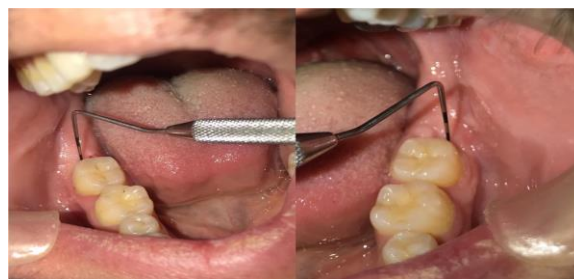Dehiscence is defined as a distance between the lingual and buccal mucosa. Dehiscence was measured using a Michigan O probe with Williams markings (1, 2, 3, 5, 7, 8, 9, 10 mm; Hu-Friedy Instrument Co., Chicago, IL, USA), and its maximum size was recorded (Fig. 1) [20,22].



**Fig. 1.** Dehiscence was measured and its maximum value was recorded

PPD is defined as the distance between the gingival margin and the depth of the pocket expressed in millimeters (mm).

CAL is defined as the distance between the cemento-enamel junction (CEJ) and the depth of the pocket expressed in millimeters (mm). Periodontal parameters (PPD and CAL) were measured at the distobuccal point of the adjacent second molar tooth (Fig. 2).



**Fig. 2.** Periodontal parameters (PPD and CAL) were measured at distobuccal point of the adjacent second molar tooth

PPD and CAL were recorded preoperatively and averagely 22 weeks (median of 17 weeks) postoperatively according to Baqain et al [23]. Dehiscence was evaluated 7 and 14 days postoperatively. All assessments were made by a dental student who was blinded to the protocols done before, using the Michigan O probe with Williams markings [19].

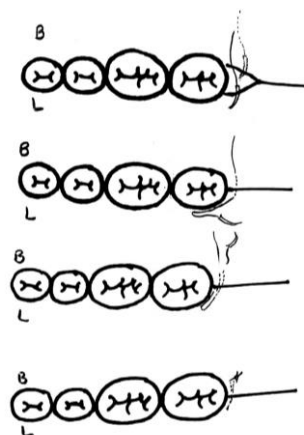
#### *Surgical phase:*

Surgical procedures of the right and left sides were performed under local anesthesia by the same surgeon and under the same conditions. Local anesthesia was induced by the injection of lidocaine plus epinephrine (Persocaine-E, DaruPakhsh Pharmaceutical Co., Tehran, Iran) using the conventional inferior alveolar nerve block technique. Next, a full-thickness flap was elevated using a #15 scalpel (Morris Dental Co. Ltd., Dublin, Ireland). A sulcular incision was made from the mesiobuccal line angle of the first molar to the buccal surface of the second molar. In case of complete impaction of the third molar tooth, this incision was extended to the distobuccal line angle of the second molar tooth. A horizontal incision was made from the distal surface of the distobuccal cusp of the second molar, extending to the mandibular ramus. A flap was elevated to the external oblique ridge using a periosteal elevator (Meridian, Pakistan). An osteotomy was performed using a rotary instrument (a micro-

motor operating at 15000 revolutions per minute (rpm); Mio Nakanishi, Tokyo, Japan) and a round carbide bur (size 2; Meisinger, USA). Minimal bone was removed on both sides, and the third molars were extracted under irrigation with sterile saline. After the removal of impacted third molars, the sockets were curetted and thoroughly rinsed to remove residual follicles. Scaling and root planing (SRP) of the distal root of the second molar was not performed. Our study had a split-mouth design such that the distal surface of the flap was sutured with sling sutures on one side and single interrupted sutures on the other side. The allocation of the technique of suturing to the side of the jaw was random. Randomization was done by flipping a coin. The interval between the two surgeries was two weeks. None of the procedures were performed after three weeks. Besides, 3-0 silk sutures (Supasil Braided Silk, circle 3/8 needle 19mm, Supa Medical Devices Co., Tehran, Iran) were used in both techniques.

#### *Suturing:*

For sling suturing, the needle was inserted into the flap from the vestibular side and exited from the distolingual surface. At the mesial aspect of the second molar tooth, the needle was inserted from the mesiolingual surface and exited from the mesiobuccal area. It was then returned to its baseline location, and after the coronal positioning of the flap, it was fixed and knotted (Fig. 3). For single interrupted suturing, the needle was inserted from the external surface of the flap and extended below the other flap. It was then returned to its primary location and knotted. All patients were then provided with postoperative instructions, which included placement of an ice pack for 30 minutes over the surgical site, removing it for 30 minutes, and placing it again (repeat for 6 hours), soft and cold diet in the first 24 hours after surgery, normal oral hygiene from the day after surgery, and rinsing with a 0.2% chlorhexidine mouthwash twice a day starting from the first day after the surgical procedure. Antibiotics were not administered but analgesics were prescribed for three days (Gelofen 400 mg, every 6 hours). Sutures were removed 7 days postoperatively for all patients.



**Fig. 3.** Sling suture. The needle was inserted into the flap from the vestibular side and exited from the distolingual surface. At the mesial of the second molar tooth, the needle was inserted from the mesiolingual and exited from the mesiobuccal area. It was then returned to its baseline location and after coronal positioning of the flap, it was fixed and knotted

#### *Statistical analysis:*

Data were analyzed using SPSS version 19 (SPSS Inc., Chicago, IL, USA). The mean and SD of clinical parameters were reported for the two techniques at two time points. To assess the effect of time and technique of suturing on clinical parameters, the Wilcoxon signed-rank test and generalized estimating equation (GEE) regression model were applied. The Wilcoxon signed-rank test was used for intergroup and intragroup comparisons. The variables did not have a normal distribution.

## RESULTS

Fifty impacted third molars were surgically extracted, out of which, 10 had complete impaction and 40 were semi-impacted. Table 1 shows periodontal parameters in 25 patients at the baseline and 17 weeks postoperatively. At the baseline, no significant difference was noted in PPD and CAL on the two sides ( $P=0.297$  for PPD and  $P=0.48$  for CAL). According to the Wilcoxon test, the two suturing techniques were significantly different in terms of PPD ( $P=0.041$ ) and CAL ( $P=0.016$ ) 17 days postoperatively.

**Table 1.** Clinical attachment loss and probing pocket depth at baseline and after 17 weeks (w) in the two groups

	Clinical attachment loss (mm)						Probing pocket depth (mm)					
	Baseline		17w later		Difference		Baseline		17w later		Difference	
	Mean±SD	Md	Mean±SD	Md	Mean±SD	Md	Mean±SD	Md	Mean±SD	Md	Mean±SD	Md
<b>Single suture</b>	0.24±0.66	0	1.20±0.76	1	0.96±0.54	1	3.12±0.93	3	3.00±0.5	3	0.12±0.67	0
<b>Sling suture</b>	0.16±0.37	0	0.68±0.63	1	0.52±0.59	0	3.36±1.08	3	2.76±1.6	3	0.6±1	0

SD: Standard Deviation; Md: Median

The difference in CAL between the two groups for teeth with complete impaction was not significant ( $P=0.317$ ) but this difference was significant for semi-impacted teeth ( $P=0.021$ ). The difference in PPD between the two groups for teeth with complete impaction was not significant ( $P=0.564$ ) while this difference was significant for semi-impacted teeth ( $P=0.048$ ). According to the GEE model, the comparison of the two techniques, by taking into account the degree of impaction and PPD at the baseline, revealed that PPD at the end of 17 weeks in the single suture group was 0.310 mm deeper than that in the sling suture group ( $P=0.003$ ).

**Table 2.** The mean size of dehiscence (mm), 7 and 14 days postoperatively in the sling and single interrupted suture groups

Suture technique	Dehiscence
Single interrupted suture 7 days	0.92
Single interrupted suture 14 days	0.28
Sling suture 7 days	1.28
Sling suture 14 days	0.32

According to the GEE model, the comparison of the two techniques, by taking into account the degree of impaction and CAL at the baseline, revealed that CAL at the end of 17 weeks in the single suture group was 0.458 mm more than that in the sling suture group ( $P=0.003$ ). Considering the degree of

impaction, the change in CAL during 17 weeks in the single suture group was 0.440 mm more than that in the sling suture group ( $P=0.006$ ). Also, considering the degree of impaction, the change in PPD during 17 weeks in the single suture group was 0.480 mm more than that in the sling suture group ( $P=0.029$ ).

Measurement of dehiscence after 7 days showed that its size in the single suture technique was 0.36 mm smaller than that in the sling suture technique, and this difference was significant ( $P=0.059$ ). However, this difference was not significant after 14 days ( $P=0.852$ ; Table 2).

Fully impacted and semi-impacted teeth were not significantly different in terms of dehiscence after 7 and 14 days ( $P=0.157$  and 0.131 for fully impacted and semi-impacted teeth after 7 days, respectively, and  $P=0.317$  and 1.00 for fully impacted and semi-impacted teeth after 14 days, respectively).

## DISCUSSION

Third molar impaction can cause cystic and neoplastic changes, orthodontic and prosthodontic problems, and even temporomandibular joint (TMJ) symptoms [24-28]. This study compared the efficacy of single interrupted and sling sutures following third molar extraction surgery regarding dehiscence, PPD, and CAL. This study had a split-mouth design and the same surgeon performed all surgical procedures. Thus, the effect of confounders such as age, gender, the technique of surgery, and the experience and expertise of the surgeon on the results was

eliminated. Because the preoperative impaction and parameters were reported very wide range, the results and mean parameters ranged over many amounts.

At the baseline, no significant difference was noted in PPD and CAL on the two sides. The mean preoperative CAL was  $0.24 \pm 0.663$  mm. The results showed that CAL and PPD were not significantly different between the two groups at the baseline, which indicates the equal distribution of samples in the two groups. In the current study, PPD decreased by 0.12 mm postoperatively in the single interrupted suturing group; this value was 0.6 mm in the sling suturing group. This difference was statistically significant between the two groups. The difference in PPD was not significant between the two groups in completely impacted teeth but this difference for semi-impacted teeth was statistically significant. CAL improved by 0.96 mm postoperatively in the single interrupted suturing group; this value was 0.52 mm in the sling suturing technique. This difference was statistically significant between the two groups. The difference in CAL was not significant between fully impacted teeth in the two groups but the difference for semi-impacted teeth was significant.

Rosa et al [2] evaluated the effect of flap design on periodontal parameters and healing of soft tissue around second molars following surgical extraction of impacted mandibular third molars. They compared envelope and Szmyd flap designs and found no significant difference in PPD or CAL. This finding was probably because similar incisions were made at the distal of the second molar tooth in both methods. Cetinkaya et al [21] evaluated the effect of suturing technique on periodontal health of the adjacent second molar after extraction of impacted third molars and reported that PPD and CAL at the distal of the second molar tooth significantly increased in the single suture group after 6 months while no significant change was noted in the anchor suture group. Their findings were in agreement with ours and supported the hypothesis that the use of hard tissue anchorage for surgical wound closure would

improve periodontal parameters. Baqain et al [23] evaluated the effect of two types of flaps, namely the envelope and triangular flaps, on postsurgical complications. PPD was significantly greater in the envelope flap group at follow-up. The reason was surgical wound closure under tension in the envelope group and decreased tension in the triangular flap group [23].

In our study, dehiscence in the single suture group was 0.36 mm smaller than that in the sling suture group after 7 days; the difference was statistically significant. After 14 days, this difference was not significant. The effect of degree of impaction on the size of dehiscence was not significant.

Jakse et al [9] compared the envelope and modified triangular flaps in terms of primary wound healing following mandibular third molar extraction surgery. They reported dehiscence in 33% of the cases. This rate was 57% in the envelope flap group but the open wound was only seen in 10% of the cases in the modified triangular flap group because, in the latter technique, tension at the distal part of the wound is less and primary periodontal healing occurs faster [9]. Rafetto [29] compared the bayonet and envelope flaps in terms of pain, swelling, trismus, and dehiscence following bilateral surgical extraction of mandibular third molars and reported that the frequency of wound dehiscence in the envelope group was significantly higher than that in the bayonet flap group. The reason was explained to be the intersulcular suture anterior to the envelope flap and soft tissue tension [29]. Rahpeyma et al [22] compared the triangular transposition and envelope flaps regarding wound dehiscence following surgical extraction of mandibular third molars with Class 1B impaction.

Dehiscence occurred in 43% of the cases in the envelope group during the first week postoperatively, out of which, 67% had large dehiscence (diameter > 5 mm). Dehiscence was noted in 19% of the cases in the triangular transposition group during the first week, out of which, 65% had large dehiscence. Because the single interrupted suturing is a simple

technique and the length of the thread is shorter than that of the sling suture, it might be a better technique for the adaptation of wound edges. In addition, it shows resistance against tensile forces [22].

One limitation of this study was the small sample size. Thus, future studies with larger sample sizes and longer follow-up periods are required to better elucidate this topic.

## CONCLUSION

Within the limitations of this study, the results indicated that the sling suturing technique in surgical extraction of mandibular third molars improves PPD and CAL of the adjacent second molar compared to the single interrupted suturing technique. However, the technique of suturing does not seem to have a significant long-term effect on wound dehiscence.

## CONFLICT OF INTEREST STATEMENT

None declared.

## REFERENCES

- Scherstén E, Lysell L, Rohlin M. Prevalence of impacted third molars in dental students. *Swed Dent J*. 1989;13(1-2):7-13.
- Rosa AL, Carneiro MG, Lavrador MA, Novaes AB Jr. Influence of flap design on periodontal healing of second molars after extraction of impacted mandibular third molars. *Oral Surg Oral Med Oral Pathol Oral Radiol Endod*. 2002 Apr;93(4):404-7.
- McGrath C, Comfort MB, Lo EC, Luo Y. Changes in life quality following third molar surgery--the immediate postoperative period. *Br Dent J*. 2003 Mar 8;194(5):265-8; discussion 261.
- Kim K, Brar P, Jakubowski J, Kaltman S, Lopez E. The use of corticosteroids and non-steroidal anti-inflammatory medication for the management of pain and inflammation after third molar surgery: a review of the literature. *Oral Surg Oral Med Oral Pathol Oral Radiol Endod*. 2009 May;107(5):630-40.
- Üstün Y, Erdoğan Ö, Esen E, Karsli ED. Comparison of the effects of 2 doses of methylprednisolone on pain, swelling, and trismus after third molar surgery. *Oral Surg Oral Med Oral Pathol Oral Radiol Endod*. 2003 Nov;96(5):535-9.
- Blondeau F, Daniel NG. Extraction of impacted mandibular third molars: postoperative complications and their risk factors. *J Can Dent Assoc*. 2007 May;73(4):325.
- Mohajerani H, Esmaeelinejad M, Sabour S, Aghdashi F, Dehghani N. Diagnostic Factors of Odontogenic Cysts in Iranian Population: A Retrospective Study Over the Past Two Decades. *Iran Red Crescent Med J*. 2015 Jun 30;17(6):e21793.
- Pourdanesh F, Esmaeelinejad M, Aghdashi F. Clinical outcomes of dental implants after use of tenting for bony augmentation: a systematic review. *Br J Oral Maxillofac Surg*. 2017 Dec;55(10):999-1007.
- Jakse N, Bankaoglu V, Wimmer G, Eskici A, Pertl C. Primary wound healing after lower third molar surgery: evaluation of 2 different flap designs. *Oral Surg Oral Med Oral Pathol Oral Radiol Endod*. 2002 Jan;93(1):7-12.
- Richardson DT, Dodson TB. Risk of periodontal defects after third molar surgery: An exercise in evidence-based clinical decision-making. *Oral Surg Oral Med Oral Pathol Oral Radiol Endod*. 2005 Aug;100(2):133-7.
- Kugelberg CF, Ahlström U, Ericson S, Hugoson A, Thilander H. The influence of anatomical, pathophysiological and other factors on periodontal healing after impacted lower third molar surgery. A multiple regression analysis. *J Clin Periodontol*. 1991 Jan;18(1):37-43.
- Pasqualini D, Cocero N, Castella A, Mela L, Bracco P. Primary and secondary closure of the surgical wound after removal of impacted mandibular third molars: a comparative study. *Int J Oral Maxillofac Surg*. 2005 Jan;34(1):52-7.
- Khan MA, Ahmad T, Khadija SH. Frequency of dry socket, pain, wound dehiscence and swelling one week after removal of mandibular third molar impaction. *J Khyber Coll Dent*. 2015 Jun;5(2):20-23.
- Bello SA, Olaitan AA, Ladeinde AL. A randomized comparison of the effect of partial and total wound closure techniques on postoperative morbidity after mandibular third molar surgery. *J Oral Maxillofac Surg*. 2011 Jun;69(6):e24-30.
- Zuhr O, Rebele SF, Thalmeier T, Fickl S, Hurzeler MB. A modified suture technique for plastic periodontal and implant surgery--the double-crossed suture. *Eur J Esthet Dent*. 2009 Winter;4(4):338-47.
- Akkaya M, Böke F. Shallow localized gingival recession defects treated with modified coronally repositioned flap technique: A case series. *Eur J Dent*. 2013 Jul;7(3):368-372.
- Huang LH, Wang HL. Sling and tag suturing technique for coronally advanced flap. *Int J*

Periodontics Restorative Dent. 2007 Aug;27(4):379-85.

18. Pell GJ, Gregory GT. Impacted mandibular third molars: classification and modified technique for removal. Dent Digest. 1933;39:330-8.

19. Greene JC, Vermillion JR. The oral hygiene index: a method for classifying oral hygiene status. J Am Dent Assoc. 1960 Aug;61(2):172-179.

20. Löe H. The Gingival Index, the Plaque Index and the Retention Index Systems. J Periodontol. 1967 Nov-Dec;38(6):Suppl:610-6.

21. Cetinkaya BO, Sumer M, Tutkun F, Sandikci EO, Misir F. Influence of different suturing techniques on periodontal health of the adjacent second molars after extraction of impacted mandibular third molars. Oral Surg Oral Med Oral Pathol Oral Radiol Endod. 2009 Aug;108(2):156-61.

22. Rahpeyma A, Khajehahmadi S, Ilkhani S. Wound Dehiscence after Wisdom Tooth Removal in Mandibular Mesioangular Class IB Impactions: Triangular Transposition Flap versus Envelope Flap. J Dent Res Dent Clin Dent Prospects. 2015 Summer;9(3):175-80.

23. Baqain ZH, Al-Shafii A, Hamdan AA, Sawair

FA. Flap design and mandibular third molar surgery: a split mouth randomized clinical study. Int J Oral Maxillofac Surg. 2012 Aug;41(8):1020-4.

24. Nemcovsky CE, Tal H, Pitaru S. Effect of non-erupted third molars on roots of approximal teeth. A radiographic, clinical and histologic study. J Oral Pathol Med. 1997 Nov;26(10):464-9.

25. Güven O, Keskin A, Akal UK. The incidence of cysts and tumors around impacted third molars. Int J Oral Maxillofac Surg. 2000 Apr;29(2):131-5.

26. Knutsson K, Brehmer B, Lysell L, Rohlin M. Pathoses associated with mandibular third molars subjected to removal. Oral Surg Oral Med Oral Pathol Oral Radiol Endod. 1996 Jul;82(1):10-7.

27. Walters H. Reducing lingual nerve damage in third molar surgery: a clinical audit of 1350 cases. Br Dent J. 1995 Feb 25;178(4):140-4.

28. Eliasson S, Heimdahl A, Nordenram Å. Pathological changes related to long-term impaction of third molars: A radiographic study. Int J Oral Maxillofac Surg. 1989 Aug 1;18(4):210-2.

29. Rafetto LK. Managing Impacted Third Molars. Oral Maxillofac Surg Clin North Am. 2015 Aug;27(3):363-71.