



Endodontic Management of Various Canal Morphologies in Maxillary First Molars: A Series of Four Case Reports

Izaz Shaik^{1*}, Nagesh Bolla¹, Bhargavi Dasari², Arka Prova Bhattacharjee¹

1. Department of Conservative Dentistry and Endodontics, Sibar Institute of Dental Sciences, Guntur, India
2. Oral and Maxillofacial Radiology, Rutgers School of Dental Medicine, Newark, New Jersey, USA

Article Info

Article type:
Case Report

Article History:

Received: 18 July 2018
Accepted: 8 January 2019
Published: 29 June 2019

* Corresponding author:

Department of Conservative Dentistry
and Endodontics, Sibar Institute of
Dental Sciences, Guntur, India

Email: shaik.ajas@gmail.com

ABSTRACT

The success of nonsurgical endodontic management depends on the complete elimination of infection that compromises the tooth function. Thorough knowledge about the root canal anatomy is one of the principal factors in achieving a successful outcome. The morphology of root canals is not always typical. Maxillary molars, known for varied morphology, require advanced imaging modalities such as cone-beam computed tomography. This case report describes a series of four maxillary molars with different forms, numbers, and configurations of root canals and with unusual morphology, including a case of a third mesiobuccal canal, a case of a second mesiobuccal canal with two palatal canals (mesiopalatal and distopalatal), a case of three mesiobuccal canals, three distobuccal canals, and two palatal canals (mesiopalatal and distopalatal), and a case of taurodontism, where different access cavity modifications, diagnostic methods, and magnifications were considered.

Keywords: Anatomy; Root Canals; Cone-Beam Computed Tomography; Permanent Dentition; Maxillary Molar Teeth

- **Cite this article as:** Shaik I, Bolla N, Dasari B, Bhattacharjee AP. Endodontic Management of Various Canal Morphologies in Maxillary First Molars: A Series of Four Case Reports. *Front Dent.* 2019;16(3):231-238. doi: 10.18502/fid.v16i3.1595

INTRODUCTION

Endodontic treatment intends to eliminate the bacterial load from root canal space and to provide a hermetic filling. Sound knowledge of the root canal anatomy and its variations, the presence of extra roots, and unusual root canal morphology and the use of diagnostic tools to detect such abnormalities are the prerequisites of a favorable outcome [1]. Treatment of maxillary molars is more

difficult because of the complex root canal anatomy and the higher tooth volume [1-5]. Taurodontism and C-shaped and O-shaped canal morphologies have also been reported with lower incidence rates [6,7]. In such cases, the use of advanced three-dimensional (3D) imaging modalities, such as cone-beam computed tomography (CBCT), is recommended to overcome the limitations of conventional imaging techniques [7].

CASE REPORT**CASE REPORT 1**

Maxillary right first molar (tooth #16) with a third mesiobuccal canal (MB3):

A 25-year-old female reported with a chief complaint of pain in the upper right back tooth for the past one week. The pain was sudden in onset, intermittent, and pricking. This was her first dental visit. The medical history was not significant.

Clinically, tenderness on vertical percussion was evident in tooth #16, and radiographic examinations revealed dental caries involving the pulp. Pulp sensitivity tests with an electric pulp tester (Ashoo Sons API Pulp Tester, Delhi, India) rendered negative response. Based on the clinical and radiographic findings (Fig. 1a), the diagnosis was given as asymptomatic irreversible pulpitis with symptomatic apical periodontitis for which endodontic treatment was initiated. Middle superior alveolar (MSA) and posterior superior alveolar (PSA) nerve infiltration were administered using 2% Lignocaine (Lignox 2% A; Indoco Remedies Ltd., Mumbai, India) with 1:80,000 epinephrine. Under rubber dam isolation (Hygenic Dental Dam, Coltene/Whaledent, Ohio, USA) coronal access was prepared using the Endo Access kit (Dentsply Tulsa Dental Specialties, Tulsa, USA). The canal anatomy had three canal orifices: mesiobuccal (MB), distobuccal (DB), and palatal (P). With DG-16 endodontic explorer (Hu-Friedy, Chicago, IL, USA), a catch point revealed a bleeding spot. The access cavity was modified in shape from triangular to trapezoidal, which divulged the mesiobuccal-2 (MB2) canal. After confirming two canal orifices mesially, one distally and one palatally, a hemorrhagic point was noted beneath the MB2 canal, confirming MB3. Then, #6 K-file (Dentsply Maillefer, Ballaigues, Switzerland) was inserted in the MB3 canal, and the canal was cleaned up to #15 K-file. The working length (WL) was established and confirmed by intraoral periapical radiography (Fig. 1b and 1c). The X-Smart rotary handpiece (Dentsply, Maillefer, Ballaigues, Switzerland) with the engine settings of 500 revolutions per minute (rpm) and 2.5 N/cm was used for instrumentation. The HyFlex controlled

memory (CM) rotary instrument (Coltene/Whaledent Inc., Ohio, USA) with the sequence of .04/15 and .04/20 was inserted in the MB3 canal to the WL. For other canals, ProTaper Universal (Dentsply Maillefer, Ballaigues, Switzerland) was used for cleaning and shaping (Fig. 1d) according to the manufacturer instructions. Irrigation was performed with 0.9% normal saline (Baxter India Pvt. Ltd.), 3% sodium hypochlorite (NaOCl; Prime Dental Products Pvt. Ltd., Bhiwandi, India), and 17% ethylenediaminetetraacetic acid (EDTA; Smear Clear, Kerr, CA, USA) upon changing the instruments. The canals were dried with absorbent points (Dentsply Tulsa, OK, USA). Obturation was done using the thermoplasticized technique (Obtura II; SybronEndo, Orange, CA, USA) with AH-Plus sealer (Dentsply, Maillefer, Tulsa, USA), and the tooth was restored temporarily using Coltosol F (Coltene/Whaledent Inc., Ohio, USA) in the same visit. The tooth was restored with amalgam 15 days later (Fig. 1e and 1f).

CASE REPORT 2

Tooth #16 with MB2, DB, and two palatal (MP and DP) canals:

A 28-year-old male reported with a chief complaint of pain in the upper right back tooth for the past 15 days. The pain was gradual in onset, dull, and intermittent. The clinical dental medical history, diagnostic test results, and diagnosis were similar to those of case report 1 for which endodontic treatment was planned (Fig. 2a). Middle- and posterior-superior alveolar nerve infiltration was administered using 2% Lignocaine (Lignox 2% A; Indoco Remedies Ltd., Mumbai, India) with 1:80,000 epinephrine. The access cavity was prepared under rubber dam isolation. Foremost, the canal anatomy had three orifices, i.e., mesial, distal, and palatal. A catch was felt just near the junction of the mesial and palatal canals with a DG-16 explorer, identifying the MB2 canal. The access cavity shape was modified from triangular to trapezoidal in a search for extra canals. Microscopic observation at $\times 3.5$ magnification (Seiler Microscope, St. Louis, MO, USA) revealed an additional hemorrhagic point mesial to the palatal canal, which was found

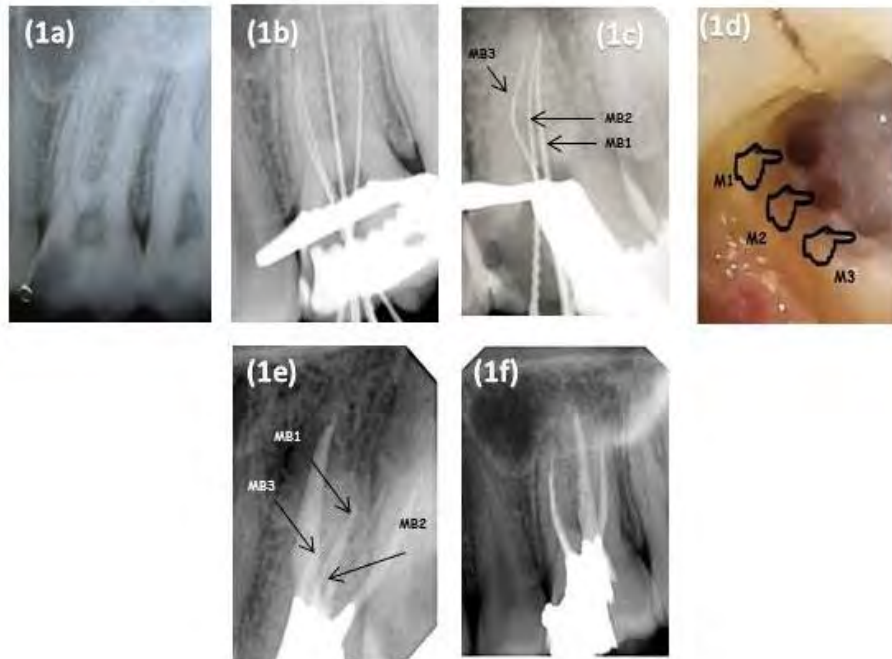


Fig. 1: Tooth #16. (1a) Pre-operative IOPAR, (1b, 1c) WL IOPAR, (1d) MB1, MB2, MB3 canal orifices, (1e, 1f) Angulated Post-operative IOPAR'S

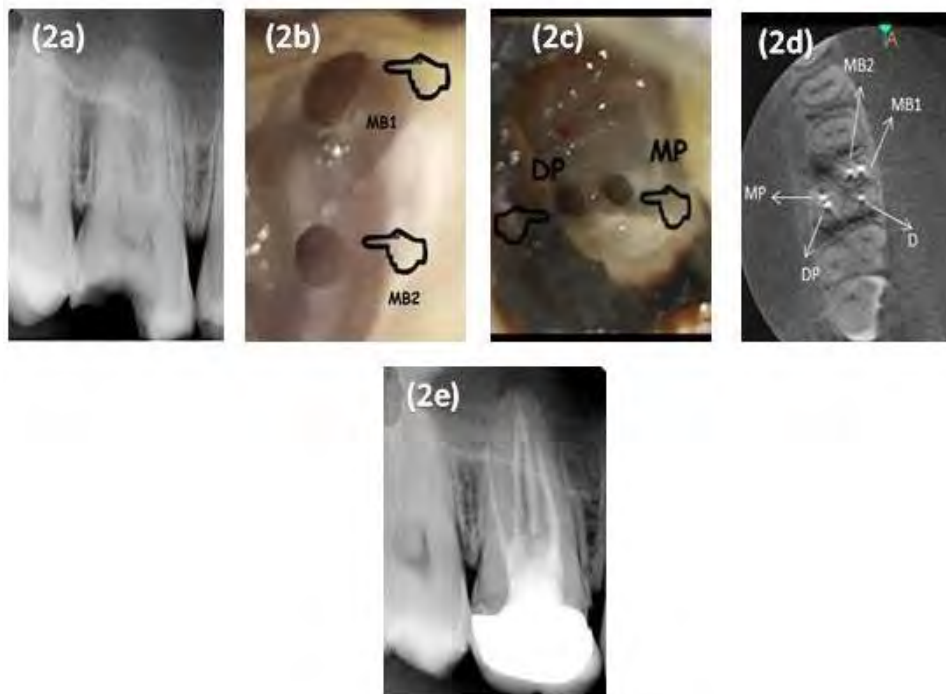


Fig. 2: Tooth #16. (2a) Pre-operative IOPAR, (2b, 2c) MB1, MB2 and MP, DP canal orifices, (2d) Post-operative CBCT axial view, (2e) Post-operative IOPAR with crown

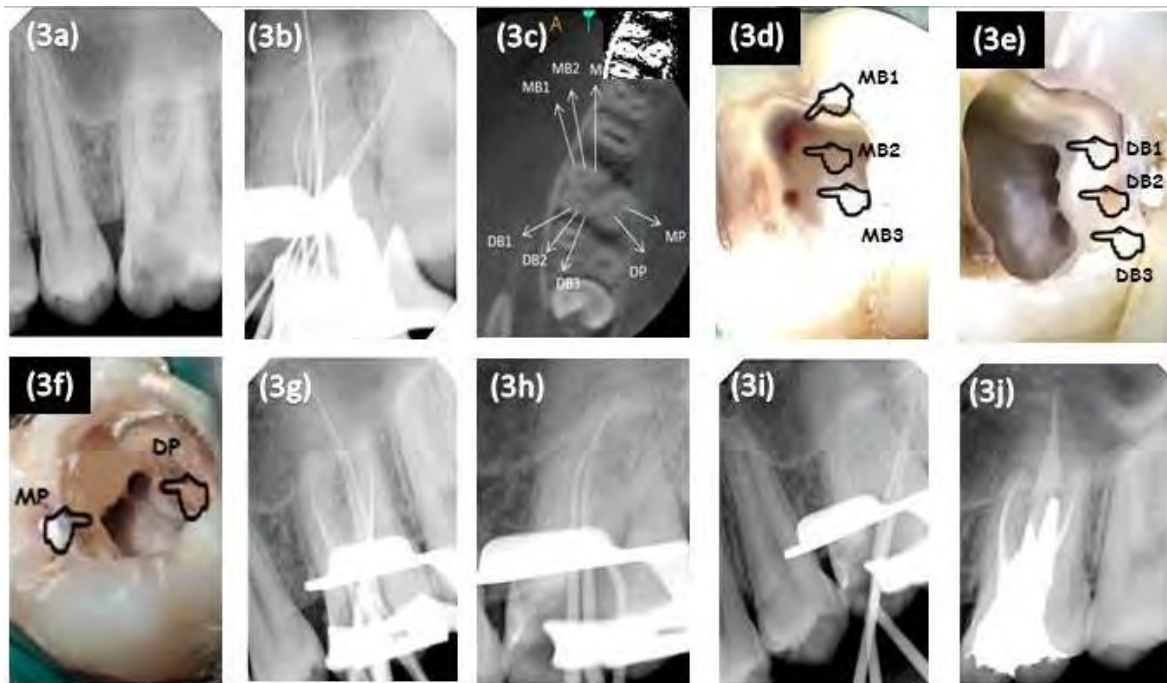


Fig. 3: Tooth #16. (3a) Pre-operative IOPAR, (3b) WL IOPAR (3c) Pre-operative CBCT axial view, (3d , 3e, 3f), MB1, MB2, MB3, DB1, DB2, DB3, MP & DP canal orifices, (3g, 3h, 3i) Master cone IOPAR, (3j) Post-operative IOPAR

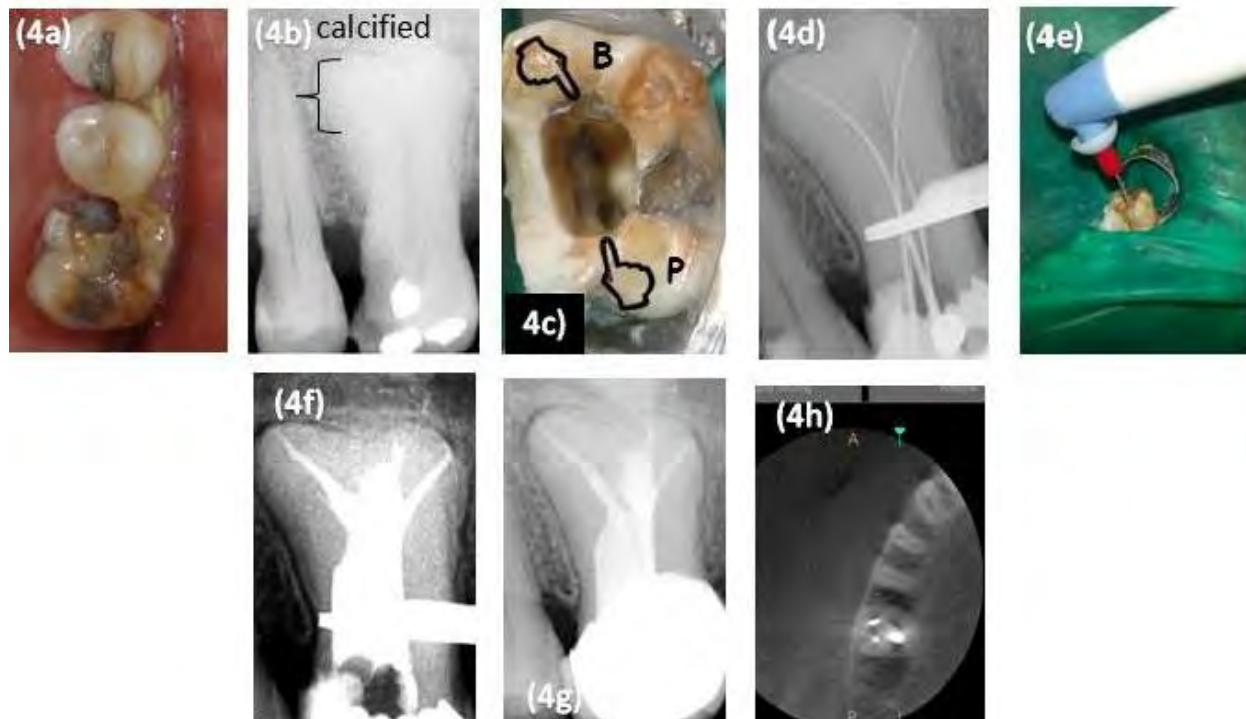


Fig. 4: Tooth #16. (4a) Intraoral view (4b) Pre-operative IOPAR, (4c) Buccal and palatal canal orifices, (4d) WL IOPAR, (4e) Sonic activation with Endoactivator, (4f) Obturation done using obtura II (4g) Post-operative IOPAR with crown, (4h), Post-operative CBCT axial view

to be a second palatal canal. Hence, a total of five canal orifices were located, which were named as MB1, MB2, DB, MP, and DP (Fig. 2b and 2c).

After locating all the orifices, the WL was confirmed with an apex locator (Root ZX, J. Morita Co., Kyoto, Japan). Instrumentation and obturation procedures were performed similarly to case report 1. To avoid multiple radiographic exposures, post-operative CBCT with an ultra-low radiation dose was done as two-dimensional (2D) intraoral periapical imaging could not reveal the complex 3D structure of the two palatal canals (Fig. 2d). A porcelain-fused-to-metal (PFM) crown was placed as the final restoration (Fig. 2e).

CASE REPORT 3

Tooth #16 with MB3, DB3, MP, and DP canals:

A 22-year-old male reported with pain in the upper right back tooth since one week previously, which was sudden, continuous, and dull. He gave a history of onset of pain since the initiation of root canal treatment in the tooth, which aggravated during the night and relieved by analgesics. The medical history was non-contributory. Clinical examinations revealed incomplete access cavity preparation. Tooth #16 was tender on vertical percussion. Radiographic examinations revealed dental caries involving the pulp. Based on the clinical and radiographic findings (Fig. 3a), the diagnosis was given as previously initiated root canal treatment with symptomatic apical periodontitis, and endodontic treatment was re-initiated. After administering local anesthesia under rubber dam isolation, coronal access was prepared. The canal anatomy revealed two mesial canals (MB1 and MB2), two distal canals (DB1 and DB2), and one palatal canal. Suspecting variation in the dentinal map, the champagne bubbling test was done during which MB3 was found. At $\times 3.5$ magnification, using DG-16 explorer, two additional sticky points were felt: one near the mesiopalatal region, which revealed the second palatal canal, and the other 2 mm beneath the second distal canal, which revealed DB3. The WL was established (Fig.

3b). Irrigation was performed similarly to that of case report 1. Inter-appointment calcium hydroxide dressing (ApexCal®, Ivoclar Vivadent AG Schaan, Liechtenstein) was given. To confirm the presence of extra canals, a CBCT scan was taken. The image revealed three mesial, three distal, and two palatal canals (Fig. 3c). During the second visit, cleaning, shaping (Fig. 3d, 3e, and 3f), and obturation (Fig. 3g, 3h, 3i, and 3j) were performed similarly to those related to case report 1.

CASE REPORT 4

Tooth #16 with hypertaurodontism:

A 58-year-old male patient reported with a chief complaint of pain in the right upper back region since one month previously. The patient claimed that the pain aggravated while having hot and cold food during the past one week. The pain was gradual, sharp, and continuous. The patient's medical history was non-contributory. Intraoral examinations revealed the presence of an occlusal amalgam restoration with proximal caries (the mesial aspect) in tooth #16. The tooth was tender on percussion and palpation. Intraoral periapical radiography revealed an ill-defined radiolucency involving the pulp with slight widening of the periodontal ligament (PDL) space and a deep pulp chamber with calcification extending beyond the cervical area, reaching the apical third of the root with a huge (wider mesiodistally) single root suggestive of hypertaurodontism (Fig. 4a and 4b). Vitality tests with heated gutta-percha (Dentsply, Maillefer, Switzerland) and dry ice (RC Ice; Prime Dental Products Pvt. Ltd., Mumbai, India) rendered a delayed response; this supported the diagnosis of symptomatic irreversible pulpitis with symptomatic apical periodontitis in tooth #16. Following local anesthesia, the pulp chamber was accessed under rubber-dam isolation. At $\times 3.5$ magnification, the access cavity was extended deep to locate the canals as the pulp chamber was calcified. Instrumentation was carried out using the balanced force technique. Clinically, two orifices were seen; the buccal orifice had two separate canals (MB and DB), and the

palatal orifice had one canal (Fig. 4c). The WL was established (Fig. 4d). Cleaning and shaping of the canals were done using the HyFlex CM rotary instruments according to the manufacturer instructions up to .04/40. Final irrigation was performed with 5.25% NaOCl and sonic activation for 30 seconds at 10,000 rpm (EndoActivator, Dentsply, Tulsa, OK, USA; Fig. 4e). Obturation was done using the backfill technique (Obtura II; Fig. 4f and 4g). Post-operative CBCT confirmed the complete obturation of all the canals (Fig. 4h).

DISCUSSION

This case series describes four cases of varied root canal morphologies in permanent maxillary first molars. The higher prevalence of additional root canals has been reported by several authors [8,9]. According to a study by Guo et al [10], in the mesiobuccal roots, Vertucci's type IV was the most common type of canal in a North American population. In a study by Ghobashy et al [11], root canal configurations of an Egyptian population showed that the most common Vertucci's classification for the mesiobuccal root was type II. Similar results have been reported for a Spanish population according to Perez-Heredia et al [12]. Olczak and Pawlicka [13] concluded that there are differences in the number and configuration of roots and root canals between maxillary first and second molars in the studied patients of a Polish population. According to a clinical study by Pattanshetti et al [14], the incidence of a second canal in the distal roots was 49% in a Kuwait population, which was similar to other Asian populations.

The incidence of MB3 canal in maxillary molars has been reported to be 1.1%-10% [8]. However, very few cases with MB3 canal have been documented [15]. In case report 1, the hemorrhagic point and exploring with DG-16 hinted the presence of an extra canal. The WL radiograph showed a separate third mesiobuccal canal, while the MB1 joined the MB2 canal at the middle third and continued as a single canal. This variation has been included in the Sert and Bayirli classification as type XV (3-2) [16].

The incidence of two palatal canals has been reported to be 0.62% (clinical results), 2.05% (ex-vivo results), and 4.55% (CBCT results) [16]. In case report 2, the CBCT image exhibited that both MB1 and MB2 canals had separate orifices, and the canals joined at the middle third of the root, whereas in the palatal root, MP and DP canals joined at the middle third and continued as a single canal. This variation has been included in the Vertucci's classification as type II (2-1) [9] for mesial and palatal roots.

In case report 3, the CBCT scan confirmed the diagnosis of three roots and eight canals. The CBCT axial view of the mesiobuccal and distobuccal roots was in accordance with Sert and Bayirli type XV (3-2) and type XVII canal configurations (3-1) [16]. The palatal root showed Vertucci's type II canal pattern (2-1) [9].

A hypertaurodont usually appears as a cylindrical pattern where the pulp chamber reaches the middle third of the root apex and then breaks up into two or more canals [17]. In case report 4, the pulp chamber was calcified and it was more difficult to locate the canals. A study on taurodontism has mentioned that its frequency is associated with hereditary or genetic malformations and affect both arches unilaterally or bilaterally [18]. In this case, the patient was a healthy male with no other known diseases, and the occurrence was unilateral. This diversification has been included in the Sert and Bayirli classification as Type XVI (2-3) [16].

The clinician must rely on sound knowledge of tooth anatomy, proper design, and preparation of the access cavity. Exploring the floor with an endodontic explorer, troughing the floor with round burs or ultrasonic tips, staining the pulpal floor with a dye, performing the champagne bubble test with NaOCl in a search for canal bleeding points, capturing multiple-angled periapical radiographs, and using disinfecting protocols are some of the techniques for negotiating the hidden canal anatomy. Use of current nickel-titanium (Ni-Ti) rotary instruments, magnification aids such as loupes, dental operating microscopes, and advanced radio-

graphic techniques such as CBCT play a major role in the success of endodontic treatment [19]. CBCT allows the 3D visualization of the tooth structure and the number and morphology of root canals. CBCT also reveals occult fracture lines. The slicing technique of CBCT provides minute details that aid in the completion of endodontic treatment.

CONCLUSION

This case series enlightens about diverse morphologies of maxillary first molars and implies that clinicians should not hold on to the known anatomy that usually has a dental map of three canals for maxillary molars. Clinicians must focus on advanced tools, such as dental operating microscopes and CBCT, for a careful examination of the pulpal floor to negotiate the hidden root canal anatomy.

CONFLICT OF INTEREST STATEMENT

None declared.

REFERENCES

1. Vertucci FJ, Haddix JE, Britto LR. Tooth morphology and access cavity preparation. In: Cohen S, Hargreaves KM (editors). *Pathways Of The Pulp*. St. Louis: Mosby Elsevier, 2006:203.
2. Fogel HM, Peikoff MD, Christie WH. Canal configuration in the mesiobuccal root of the maxillary first molar: a clinical study. *J Endod*. 1994 Mar;20(1):135-7.
3. Martínez-Berná A, Ruiz-Badanelli P. Maxillary first molars with six canals. *J Endod*. 1983 Sep;9(9):375-81.
4. Neelakantan P, Subbarao C, Ahuja R, Subbarao CV, Gutmann JL. Cone-beam computed tomography study of root and canal morphology of maxillary first and second molars in an Indian population. *J Endod*. 2010 Oct;36(10):1622-7.
5. Sert S, Bayrl G. Taurodontism in six molars: a case report. *J Endod*. 2004 Aug;30(8):601-2.
6. Shin Y, Kim Y, Roh BD. Maxillary first molar with an O-shaped root morphology: report of a case. *Int J Oral Sci*. 2013 Dec;5(4):242-4.
7. Verma P, Love RM. A micro CT study of the mesiobuccal root canal morphology of the maxillary first molar tooth. *Int Endod J*. 2011 Mar;44(3):210-7.
8. Adanir N. An unusual maxillary first molar with four roots and six canals: a case report. *Aust Dent J*. 2007 Dec;52(4):333-5.
9. Vertucci FJ. Root canal anatomy of the human permanent teeth. *Oral Surg Oral Med Oral Pathol*. 1984 Nov;58(5):589-99.
10. Guo J, Vahidnia A, Sedghizadeh P, Enciso R. Evaluation of root and canal morphology of maxillary permanent first molars in a North American population by cone-beam computed tomography. *J Endod*. 2014 May;40(5):635-9.
11. Ghobashy AM, Nagy MM, Bayoumi AA. Evaluation of Root and Canal Morphology of Maxillary Permanent Molars in an Egyptian Population by Cone-beam Computed Tomography. *J Endod*. 2017 Jul;43(7):1089-1092.
12. Pérez-Heredia M, Ferrer-Luque CM, Bravo M, Castelo-Baz P, Ruíz-Piñón M, Baca P. Cone-beam computed tomographic study of root anatomy and canal configuration of molars in a Spanish population. *J Endod*. 2017 Sep;43(9):1511-1516.
13. Olczak K, Pawlicka H. The morphology of maxillary first and second molars analyzed by cone-beam computed tomography in a polish population. *BMC Med Imaging*. 2017 Dec 29;17(1):68.
14. Pattanshetti N, Gaidhane M, Al Kandari AM. Root and canal morphology of the mesiobuccal and distal roots of permanent first molars in a Kuwait population--a clinical study. *Int Endod J*. 2008 Sep;41(9):755-62.
15. Cleghorn BM, Christie WH, Dong CC. Root and root canal morphology of the human permanent maxillary first molar: a literature review. *J Endod*. 2006 Sep;32(9):813-21.
16. Sert S, Bayirli GS. Evaluation of the Root Canal Configurations of the Mandibular and Maxillary Permanent Teeth by Gender in the Turkish Population. *J Endod*. 2004 Jun;30(6):391-8.
17. Barker BC. Taurodontism: the incidence and possible significance of the trait.

Aust Dent J. 1976 Jun;21(3):272-6.

18. Hayashi Y. Endodontic treatment in taurodontism. J Endod. 1994 Jul;20(7):357-8.

19. American Association of Endodontists; American Academy of Oral and Maxillofacial Radiology. Use of cone-beam computed

tomography in endodontics Joint Position Statement of the American Association of Endodontists and the American Academy of Oral and Maxillofacial Radiology. Oral Surg Oral Med Oral Pathol Oral Radiol Endod. 2011 Feb;111(2):234-7.