

# Modified Tray with Mesh Design for the Management of Flabby Ridge: A Case Report

Sudhanshu Srivastava\*, Sumit Mishra, Devendra Chopra

Department of Prosthodontics, Saraswati Dental College, Lucknow, India

Article Info	ABSTRACT
<p><b>Article type:</b> Case Report</p> <hr/> <p><b>Article History:</b> Received: 13 April 2018 Accepted: 20 July 2018 Published: 30 April 2019</p> <hr/> <p><b>* Corresponding author:</b> Department of Prosthodontics, Saraswati Dental College, Lucknow, India E-mail: dr.sudhanshu101@gmail.com</p>	<p>Flabby ridge is an excessive movable fibrous tissue, usually affecting the maxillary and mandibular edentulous ridges. It is a typical finding frequently observed in the maxillary anterior region. It usually occurs when natural teeth oppose an edentulous ridge or in long-term denture wearers. The management of flabby ridges includes surgical intervention, implant-retained prostheses, and conventional dentures fabricated using the modified impression technique. This case report depicts a modified technique with the utilization of an aluminum mesh double tray and polyvinylsiloxane impression material for the management of a flabby ridge in the maxillary arch.</p> <p><b>Keywords:</b> Dental Impression Technique; Complete Denture; Aluminum; Polyvinylsiloxane</p>
<p>➤ <b>Cite this article as:</b> Srivastava S, Mishra S, Chopra D. Modified Tray with Mesh Design for the Management of Flabby Ridge: A Case Report. <i>Front Dent.</i> 16(2):149-152. doi: 10.18502/ffd.v16i2.1367</p>	

## INTRODUCTION

Retention and support are the two major pillars of a successful complete denture. The final impression of an edentulous arch should replicate the entire functional denture-bearing area. Such a record is made to establish maximum support, retention, and stability [1-3]. However, complications arise in certain situations where denture-bearing tissues are fibrous or flabby in nature. Flabby ridge is an excessive movable tissue which is fibrous in nature and primarily occurs due to replacement of alveolar bone by hyperplastic soft tissue. It is a common finding frequently observed in the maxillary anterior region [1-3]. It usually occurs when natural teeth oppose an edentulous ridge or in long-term denture wearers [4].

Prosthetic rehabilitation in these patients can be challenging. Major problems encountered in such patients are loss of stability, inadequate retention of the dentures, and complaints of pain or looseness related to a complete denture.

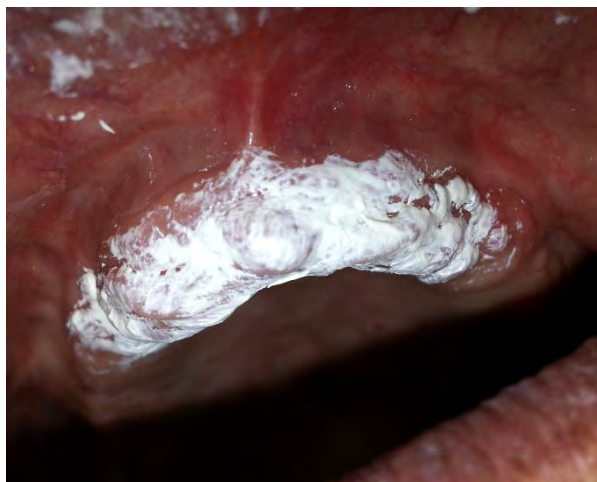These problems occur because of easy distortion of flabby tissues during impression taking.

Treatment options for these patients include surgery, implant-retained prostheses or conventional prostheses. In most situations, surgical intervention or use of implants is not possible, and conservative management is the treatment of choice. There are a number of techniques available for overcoming the problems related to a flabby ridge but they are difficult to perform and time-consuming. Liddelow [5] advised the use of two different impression materials with two custom built trays. Osborne [6] advocated the use of a custom tray with a window over the flabby tissue. He used zinc oxide eugenol (ZOE) for taking an impression of the normal tissue and impression plaster through the window to record the flabby tissue. Watson [7] used a modified custom tray with impression compound for the management of flabby tissue. Many authors

have indicated the use of polyvinylsiloxane for the management of flabby ridges [8-10]. This case report describes the use of an aluminum mesh double tray in a patient with a completely edentulous maxillary arch with flabby tissue in the anterior region, opposing an edentulous mandibular arch, to record the flabby tissue with minimal compression.

### CASE REPORT

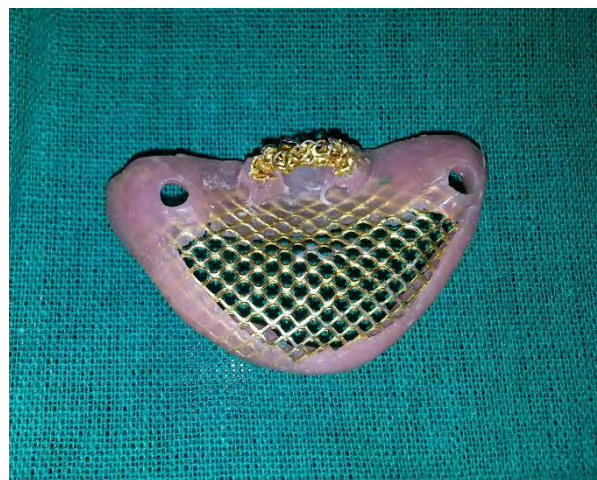
A 51-year-old male patient visited the Postgraduate Department of Prosthodontics, Saraswati Dental College, Lucknow, with the chief complaint of an ill-fitting upper denture since 2 years previously. The patient had a history of wearing a denture for the past 10 years. The patient was hypertensive and on the same medication since 8 years previously. The intraoral inspection revealed a flabby maxillary canine-to-canine region (Fig. 1) and a severely resorbed mandibular ridge. A treatment plan was designed for fabricating a complete denture with a modified impression technique, causing minimal displacement of the denture during function with maximum retention and stability.



**Fig. 1.** Flabby tissue in the anterior maxillary region

Treatment modalities like implant-supported prostheses and surgery were explained to the patient but he was not interested in any surgical procedure; thus, the possibility of using an implant-supported prosthesis was ruled out. It was planned to record the flabby tissue in an undisplaced status using a modification of the Window impression technique (two trays) for the maxillary ridge described by Filler [11]. To ensure minimal distortion of the underlying

tissue, an irreversible hydrocolloid material (Zelgan, Dentsply, India) was used to take the primary impression. Once the impressions were taken, the diagnostic casts were poured. Custom trays were fabricated on primary models for making the final impression using an auto-polymerizing acrylic resin. The mandibular custom tray was made in a conventional manner. There was a modification in the fabrication of the custom tray for the maxillary arch such that two trays were fabricated (Fig. 2).

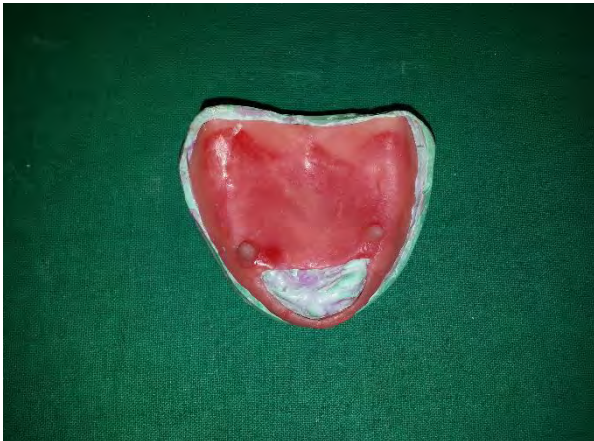

**Fig. 2.** First tray with a window and a vertical post

The first tray for the maxillary arch was fabricated with a window over the flabby tissue area along with acrylic projections, one on either side, in the premolar region, and then, the second maxillary tray was fabricated with guiding holes so that it can be keyed onto the first tray; this second tray was fabricated with an aluminum mesh so that the light body material could be easily injected to record the tissue with minimal displacement. A handle was constructed over this second tray for ease of handling.

Maxillary border molding was done conventionally using the first tray, fabricated with a window in it, using a low-fusing modeling compound (Tracing Sticks, DPI PINNACLE, The Bombay Burmah Trading Corp., Mumbai). After border molding, the wax spacer was removed from the tray, and holes were drilled in the tray; two holes were made along the region of the mid-palatine raphe, and two holes were made bilaterally on the posterolateral region of the hard palate. Medium body polyvinylsiloxane (Aquasil ultra, Dentsply, Konstanz, Germany)

was used as the final impression material on the first tray with a window in it. The second tray with aluminum mesh was placed over the first tray, and light body polyvinylsiloxane (Aquasil ultra, Dentsply) was injected into the mesh. Light body polyvinylsiloxane was used as the final impression material for the second impression as it causes the least displacement of tissues. Both trays were removed together after the impression material had polymerized (Fig. 3).



**Fig. 3.** Second tray with mesh and two holes for positioning into the post

The master cast was poured on which the denture base was fabricated. The relation of the mandible to the maxilla was established. Non-anatomic teeth were arranged in monoplane occlusion to allow the patient to clench and grind in and around maximum intercuspation during both functional and non-functional activities and to provide denture stability. Denture processing was done in a conventional manner. Finishing and polishing were done followed by denture insertion. The patient was recalled after 24 hours, one week, monthly, and every 6 months thereafter. The patient was satisfied and comfortable using the denture.

## DISCUSSION

A flabby ridge has been a critical prosthodontic challenge for the achievement of a stable and retentive dental prosthesis. Standard mucocompressive impression techniques are likely to result in a non-retentive and unstable denture. The precise reproduction of the ridge tissue in an undisplaced condition is most important to the patient not only for comfort but also to provide maximum retention and

stability. The use of minimally displacive impression techniques helps to overcome some of these limitations. The present technique eliminates the excessive displacement of the soft tissues at the secondary impression stage. Thus, physiologic and anatomic registration of the attached and the unattached tissue of the denture-bearing areas are attained.

The technique described in this paper is not very complex and does not involve any extra clinical visits for the construction of a complete denture, thereby keeping the chairside time to a minimum. The modified tray design offers an undisplaced impression of the flabby area with convenience. The impression-taking procedure described by Filler [11] was used in this case for recording the flabby tissue. He used two custom trays with one tray consisting of windows, which forms the latticework for cold-cure resin, as well as trays that consisted of numerous escape holes. Both trays were keyed together. He also advocated the use of two different impression materials to record a flabby tissue with minimal pressure. The modification made to the described technique was that the second tray was designed with an aluminum mesh and a handle; consequently, light body polyvinylsiloxane (injected through the mesh) would flow and adapt to the tissue without distorting them. The advantage of the above modification was that the tissue was recorded in the most mucostatic form with the reproduction of more intricate details.

## CONCLUSION

Management of a patient with gingival plasma cell granuloma is an arduous task. Conventional impression-taking techniques would result in the fabrication of a prosthesis with compromised retention and stability. Thus, the use of minimally displacive impression technique with modified custom-made impression trays provides an alternative and promising approach for the management of such patients.

## CONFLICT OF INTEREST STATEMENT

None declared.

## REFERENCES

1. Carlsson GE. Clinical morbidity and sequelae of treatment with complete dentures. *J Prosthet Dent.* 1998 Jan;79(1):17-23.

2. Zarb GA, Carlsson GE, Bolender CL. Boucher's Prosthodontic Treatment for Edentulous Patients. London, St. Louis/Mosby, 1997:36.
3. Basker RM, Davenport JC, Thomason JM. Prosthetic Treatment of the Edentulous Patient. Oxford, Wiley-Blackwell, 2002:286-9.
4. Crawford RW, Walmsley AD. A review of prosthodontic management of fibrous ridges. Br Dent J. 2005 Dec10;199(11):715-9.
5. Liddelow KP. The prosthetic treatment of the elderly. Br Dent J. 1964 Jan;117(5):307-315.
6. Osborne J. Two impression methods for mobile fibrous ridges. Br Dent J. 1964;117(6):392-4.
7. Watson RM. Impression technique for maxillary fibrous ridge. Br Dent J. 1970 Jun 2;128(11):552.
8. Lynch CD, Allen PF. Management of the flabby ridge: using contemporary materials to solve an old problem. Br Dent J. 2006 Mar 11;200(5):258-61.
9. Keni NN, Aras MA, Chitre V. Management of flabby ridges using liquid supported denture: a case report. J Adv Prosthodont. 2011 Mar;3(1):43-6.
10. Labban N. Management of the flabby ridge using a modified window technique and polyvinylsiloxane impression material. Saudi Dent J. 2018 Jan;30(1):89-93.
11. Filler WH. Modified impression technique for hyperplastic alveolar ridges. J Prosthet Dent. 1971 Jun;25(6):609-12.