



Efficacy of Oral Mucoadhesive N-acetylcysteine Tablets in Treatment of Recurrent Aphthous Stomatitis: A Randomized Double-Blind, Placebo-Controlled Clinical Trial

Gohar Eslami^{1,2}, Anahita Ghorbani^{3*}, Jafar Akbari⁴, Ali Farmoudeh⁴, Fereshteh Faghih³, Minoo Moghimi²

1. Cardiovascular Research Center, Mazandaran University of Medical Sciences, Sari, Iran
2. Department of Clinical Pharmacy, Faculty of Pharmacy, Mazandaran University of Medical Sciences, Sari, Iran
3. Department of Oral Medicine, Faculty of Dentistry, Mazandaran University of Medical Sciences, Sari, Iran
4. Department of Pharmaceuticals, Faculty of Pharmacy, Mazandaran University of Medical Sciences, Sari, Iran

Article Info

Article type:
Original Article

Article History:

Received: 22 Jan 2022
Accepted: 10 Sep 2022
Published: 31 May 2023

* Corresponding author:

Department of Oral Medicine, Faculty of Dentistry, Mazandaran University of Medical Sciences, Sari, Iran

Email: anahita1802@yahoo.com

ABSTRACT

Objectives: This study aimed to assess the efficacy of oral mucoadhesive N-acetylcysteine (NAC) tablets for treatment of recurrent aphthous stomatitis (RAS).

Materials and Methods: Forty-nine patients with RAS were randomized to receive mucoadhesive NAC tablets (n=25) or placebo (n=24). Tablets were prescribed three times a day for 7 days in each group. Pain intensity was evaluated with visual analog scale (VAS) three times a day from day 1 to day 7. Also, patients were clinically examined on days 0 (before entering the study), 3, 5, and 7 using a metal caliper to measure the diameter of the lesions. The data were statistically analyzed and $P < 0.05$ was considered statistically significant.

Results: Regarding the VAS score, all participants in the treatment group showed complete recovery on day 7 ($P < 0.01$). Also, the diameter of the lesions was significantly smaller in the treatment group than the placebo group at the end of the study ($P < 0.001$).

Conclusion: The results of this clinical trial showed for the first time that mucoadhesive NAC tablets can significantly decrease pain and the diameter of RAS lesions without any systemic complications.

Keywords: Acetylcysteine; Stomatitis, Aphthous; Visual Analog Scale

- **Cite this article as:** Eslami G, Ghorbani A, Akbari J, Farmoudeh A, Faghih F, Moghimi M. Efficacy of Oral Mucoadhesive N-acetylcysteine Tablets in Treatment of Recurrent Aphthous Stomatitis: A Randomized Double-Blind, Placebo-Controlled Clinical Trial. *Front Dent.* 2023;20:18.

INTRODUCTION

Recurrent aphthous stomatitis (RAS) is the most common oral lesion with the annual and lifelong prevalence rates of 20% and 40%, respectively [1]. RAS appears as circular, yellow-grey center lesions, with a pseudo-membrane and inflamed edges [2]. RAS lesions start with a burning sensation for 24 to 48 hours before the onset, and usually involve

the buccal and labial mucosa and the tongue. Involvement of highly keratinized mucous membranes such as the palate and gingiva is unusual [3]. Sometimes, the pain caused by RAS is very severe and interferes with eating, swallowing, speech, and oral health practice in patients, and significantly decreases the quality of life [4-7]. The etiology of RAS is unknown but factors such as immune

dysfunction, genetic allergies, foods, and bacterial agents may be involved [8,9]. Recently, many studies support the role of oxidative stress in the etiology of RAS [10-13]. Also, impaired cellular immunity may be seen in patients with RAS [14]. RAS can be topically or systemically treated, depending on the severity of symptoms, frequency of relapse, and size and number of ulcers [11]. It should be noted that the best treatment for RAS is topical therapy because of its direct contact with the ulcer and lower systemic adverse effects [15]. The goals of treatment include reducing the pain severity, wound size, and frequency of relapse, and speeding up the course of recovery [2].

N-acetylcysteine (NAC) is a FDA-approved agent that is available as a dietary supplement. NAC is converted to amino acid cysteine by deacetylation in the human body [16]; cysteine is metabolized to glutathione, an important antioxidant in the body [17]. NAC has multiple pharmacological effects that support its therapeutic benefits. For example, it has potent anti-inflammatory, immunomodulatory, anti-biofilm, and antimicrobial effects [18]. Also, it is a well-known antioxidant agent [19]. NAC is clinically used in cases with glutathione deficiency and oxidative stress such as acetaminophen poisoning [20]. It is also used as a mucolytic agent in pulmonary diseases. There is a reduction in total antioxidant status against an increase in total oxidative status in RAS patients [10-13, 21]. Therefore, NAC, as a potent antioxidant can be used in such patients. It has been shown that dysregulation of the immune system and inflammatory mediators is involved in development of RAS; thus, NAC can have beneficial effects due to its immunomodulatory and anti-inflammatory properties [22-25]. The effectiveness of topical NAC for wound healing has been previously documented [26]. In addition, a recent study showed clinically significant reduction of RAS-associated pain with a single application of NAC mouthwash and the superiority of it over chlorhexidine digluconate mouthwash. However, the use of related formulations was not simple in their

study [27]. Thus, it was hypothesized that the problem may be solved by making mucoadhesive tablets. Regarding the effects of NAC, and considering the lack of studies on the effect of NAC mucoadhesive tablets on RAS, the aim of this study was to evaluate the effectiveness of NAC mucoadhesive tablets for treatment of RAS. The null hypothesis was that use of NAC mucoadhesive tablet would not significantly promote healing of RAS at 7 days.

MATERIALS AND METHODS

Research design and ethics:

The present study was a randomized double-blind placebo-controlled clinical trial (IRCT code: IRCT2018072804614N1). This project was approved by the Medical Ethics Committee of the Research Deputy (Ethical code: IR.MAZUMS.REC.1397.2955).

Participants and selection criteria:

The sample size was calculated to be 46 cases (23 cases in the treatment group and 23 cases in the placebo group) using the results of Babaei et al, [28] assuming the baseline mean lesion diameter in the intervention and placebo groups to be 2.53 ± 0.66 mm and 2.65 ± 0.82 mm, respectively, 99% confidence level, study power of 90% by two-tailed test, 4% dropouts, and evaluation of the difference between the two means by G-power software.

The inclusion criteria were patients with RAS between 16-45 years with a history of minor aphthous ulcers in specific areas such as labial and buccal mucosa. Presence of any traumatic factor such as denture was assessed to rule out the traumatic wounds, because denture wearers do not have a high prevalence of RAS although they are three times more susceptible to oral mucosal ulceration. Also, the erythematous margin in RAS was a critical criterion in distinguishing aphthous ulcers from traumatic wounds [2]. The exclusion criteria were individuals taking immunosuppressive drugs during the past month, systemic syndromes such as Behcet's syndrome, one of the manifestations of which is aphthous ulcers, aphthous ulcers in areas other than the labial and buccal mucosa, herpetiform recurrent aphthous ulcers, recurrent major stomatitis, poor general health status, pregnancy, antibiotic

therapy, denture wearers, taking other medications for treatment of aphthous ulcers or in general, and patients who could not cooperate until the end of the study due to personal or social reasons [29]. Information about the treatment process and possible complications was given to all patients. The patients had to be able to understand the provided explanations for the treatment process, had to meet the eligibility criteria, and had to sign the consent form.

Formulation preparation:

In this study, 25 mg of NAC was considered as the appropriate treatment dose to evaluate the effects of this agent on RAS [30]. Other excipients of the mucoadhesive tablet included Carbopol 942 and sodium alginate as tablet binding agents to the oral mucosa, and starch as filler and also for adjustment of the disintegration time. Sucrose was also added to create a pleasant flavor and accelerate the disintegration of oral tablet. These components were sieved with mesh NO. 80, mixed and pressed with a single punch tablet press. The placebo was designed with the same appearance and weight as the NAC mucoadhesive tablets but without any active substance [31].

Study protocol:

The patients were asked to go to the clinic within 24 hours of the onset of aphthous lesion which was considered as baseline. At the initial meeting, patients were asked to complete the consent form and complete a questionnaire regarding the history of the disease. Once eligible, the participant was randomly assigned to either NAC or placebo group based on a draw from two envelopes: one for NAC and the other for placebo. Patients in NAC group received mucoadhesive tablets of NAC and those in the placebo group received placebo tablets for use 3 times a day (in the morning, noon, and night). The patients were instructed on how to use a mucoadhesive tablet so that they should avoid eating and drinking for 30 minutes after using it. The patients had to keep the mucoadhesive tablet in place for 15 minutes. In the placebo group, the same was done with the placebo tablet. In order to evaluate the severity of pain and recovery of lesions, patients were clinically

examined on days 0 (before entering the study), 3, 5, and 7 using a metal caliper to measure the diameter of the lesions and the surrounding inflamed area [32]. The participants were also instructed to quantify the severity of pain using a visual analog scale (VAS). This scale consists of a 10-cm line, in which zero indicates no pain and 10 shows maximum pain. Patients were asked to record their VAS pain score three times a day after each meal. For easy calculation, the mean of the three values was calculated. Those with a VAS score ≤ 1 and a lesion diameter ≤ 1 mm were considered as complete recovery [33].

Data analysis:

Data were entered into SPSS version 24 for analysis. After refinement, distribution of data was analyzed by the Kolmogorov-Smirnov test. The mean, standard deviation, and frequency were reported for demographic variables. Gender, history of diabetes mellitus, and number of RAS episodes as the categorical variables were compared with Fisher's exact test, and the continuous variable of age was compared using unpaired t-test. In order to compare the mean values before and after the intervention, paired t-test (or the Kruskal-Wallis test) was used. Independent t-test (or Mann-Whitney test) was used to compare the two groups. Also, to compare the outcome in the treatment process (days 0, 3, 5, and 7), repeated measure ANOVA and Friedman test were applied. $P < 0.05$ was considered statistically significant.

RESULTS

Demographic information of patients:

Of 60 patients referred to the Dental Clinic of Mazandaran University of Medical Sciences, 11 patients were excluded because of not meeting the inclusion criteria, refusing to continue treatment or other reasons. Forty-nine patients were randomly divided into two groups (25 patients in the treatment group and 24 patients in the placebo group) and eventually, 46 patients successfully completed the study (Fig. 1).

There was no statistically significant difference between the treatment (12 women and 11 men) and placebo (14 women and 9 men) groups in terms of gender ($P=0.76$).

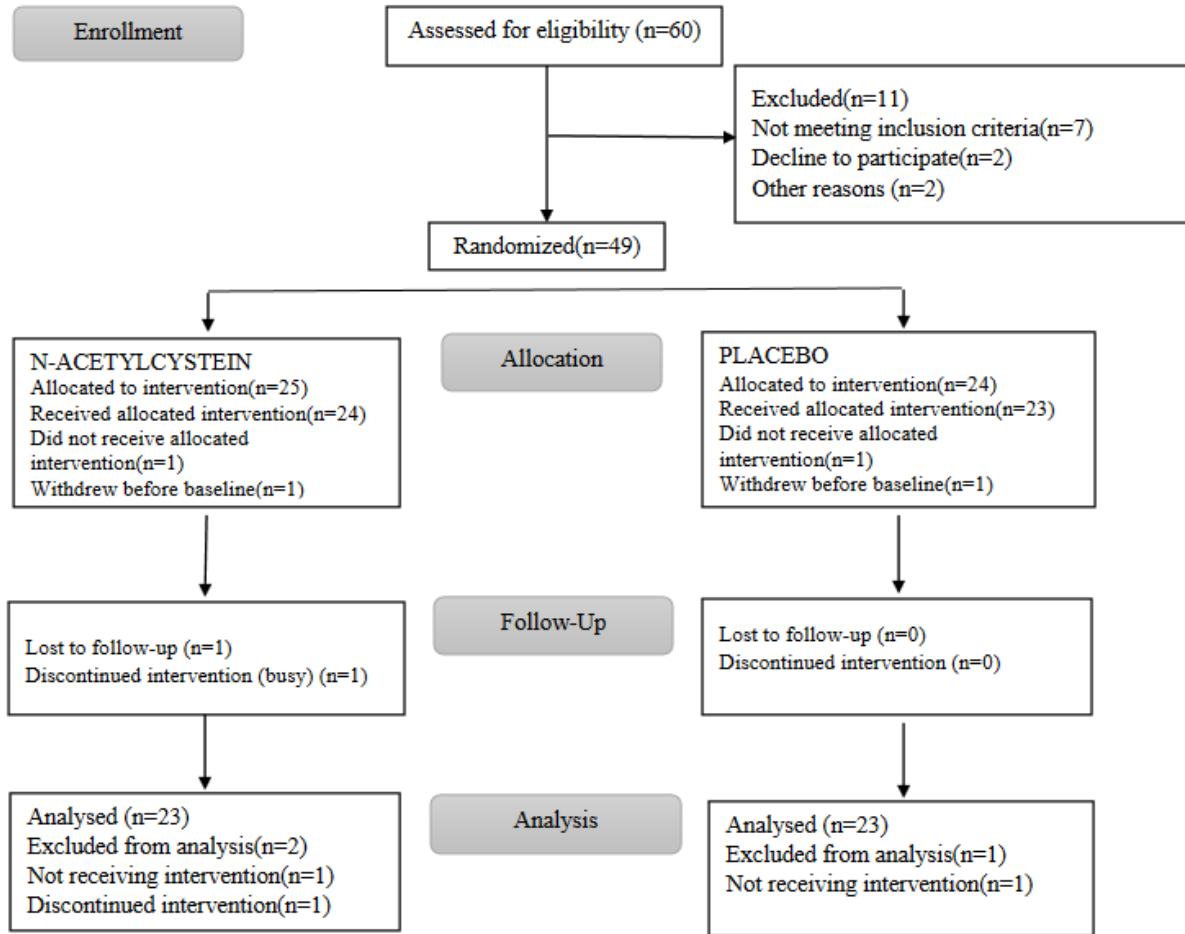


Fig. 1. Flow diagram of patient selection and allocation

The mean age (\pm standard deviation) was 33.52 ± 6.78 years in the treatment group and 34.08 ± 7.3 years in the placebo group, which were not significantly different ($P=0.78$). There were one and three patients with diabetes mellitus in the treatment and placebo groups, respectively; which was not significantly different between the two groups ($P=0.6$). Also, the frequency of aphthous episodes in the treatment and placebo groups was not significantly different at baseline ($P=0.05$, Table 1).

Wound healing process (diameter of lesions and pain intensity):

According to the results, the mean time (day) to improvement for pain and diameter of lesions was 6.52 ± 6.13 days and 6.65 ± 0.57 days in the placebo group, respectively and

4.21 ± 1.2 days and 4.73 ± 1.32 days in the treatment group, respectively; which were significantly different ($P < 0.05$).

Diameter of lesions:

At baseline, the mean diameter of lesions was not significantly different between the two groups ($P=0.09$). But, at 3, 5 and 7 days, it was significantly smaller in the treatment group compared with the placebo group ($P < 0.001$, Fig. 2).

Severity of pain (based on VAS score):

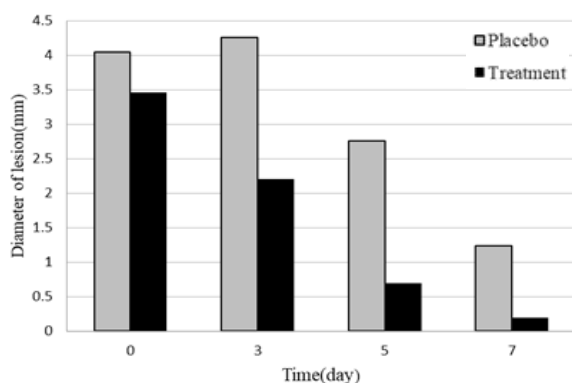
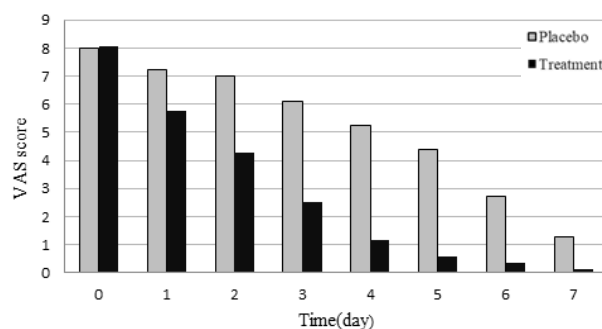
Before the start of the trial, pain severity was not significantly different between the two groups ($P=0.853$), but NAC mucoadhesive tablet showed superior effects on pain of RAS from the first day compared with the placebo ($P < 0.013$) such that for 22 out of 23 patients in the treatment group, complete recovery was

Table 1: Demographic information of patients at baseline (N=23 in each group)

	Treatment N(%)	Placebo N(%)	P
Female	12(52.17)	14(60.87)	0.76
Male	11(47.83)	9(39.13)	
History of DM	1(4.34)	3(13.04)	0.6
RAS episodes	≤6/y	4(17.39)	0.05
	1-2/m	11(47.82)	
	3-4/m	8(34.78)	

RAS: Recurrent aphthous stomatitis); DM: diabetes mellitus

achieved on day 7. The difference in the mean VAS score between the two groups was statistically significant at all-time points ($P < 0.01$, Fig. 3).

**Fig. 2.** Comparison of the mean diameter of lesions in the treatment and placebo groups at baseline and 3, 5 and 7 days**Fig. 3.** Comparison of the mean pain intensity based on VAS score between the treatment and placebo groups at baseline and days 1, 2, 3, 4, 5, 6, and 7

Safety assessment:

There was only one patient in the treatment group that reported severe burning in the

wound area and severe pain, but the diameter of the lesion significantly decreased from baseline to day 7.

DISCUSSION

This study is the first placebo-controlled clinical trial on the efficacy of NAC oral mucoadhesive tablet for treatment of RAS. The null hypothesis that use of NAC mucoadhesive tablet would not significantly promote healing of RAS at 7 days was rejected.

The primary outcome of this study was complete resolution of pain and reduction in diameter of RAS lesions in the treatment group at the end of the study. The results of the present study showed that the NAC mucoadhesive tablet was very effective in treatment of RAS. RAS is characterized by painful recurring ulcers limited to the oral mucosa [29]. There are some predisposing factors for RAS such as trauma, stress, and hormonal imbalance [34, 35]. Because of no definite evidence about the etiopathogenesis of RAS, therapy is only symptomatic. An efficient treatment option should control aphthous ulcers with minimal adverse effects on the body organs [35].

It seems that free radicals are effective in pathogenesis of RAS. Oxidative stress occurs when free radicals are produced more than physiological requirements of the body [21,36,37].

NAC is a potent antioxidant agent that has anti-inflammatory, anti-bacterial and immunomodulatory effects. It is very effective in treating inflammation of ulcerative lesions as an adjunctive therapy [16]. The notable antioxidant effect of NAC is due to its action as a precursor of glutathione. It prevents free radical activity that can lead to trauma, tissue damage, and chronic malignant diseases [38]. Halboub et al. [27] revealed a significant reduction in RAS-associated pain with one single application of NAC mouthwash in comparison with 0.12% chlorhexidine. Although the efficacy of NAC mouthwash was confirmed in their study, it was suggested that repeated doses of NAC could have even better effects as indicated in the present study. Also, our study had a placebo control group, which

was not present in their study. Abdulrab et al. [16] recommended NAC for active RAS. It was suggested that NAC can be systemically or topically (powder, paste, adhesive tablets, chewing tablets, lozenges, or mouthwash) used for treatment of active RAS or for prevention in cases with repeated attacks.

Mao et al. [39] evaluated the effects of NAC on normal human skin fibroblasts and level of manganese superoxide dismutase activity.

NAC-treated cells demonstrated decreased steady state levels of reactive oxygen species as well as increased protein and activity levels of manganese superoxide dismutase; thus, it could inhibit oxidative stress and related tissue damage. It was suggested that NAC as a dietary intervention can have a great impact on treatment of human and animal tissue injuries. Aphthous stomatitis is also an ulcerative lesion and the efficacy of NAC on its improvement was proven in the present study. Although there is still no definitive treatment for aphthous stomatitis, various supportive treatments have been proposed [40]. The results of the present study also suggest NAC as a supportive treatment in reducing pain and diameter of RAS lesions.

Tsai et al. [26] conducted a study on the mechanism of NAC in treatment of burn injuries in vitro and in vivo. NAC was used as topical formulations with concentrations of 0.1mM, 0.5mM and 1mM. It was shown that NAC increased the glutathione level in CCD-966SK cells, which could reduce the free radical damage and inhibit oxidative stress. In vivo, significant epithelialization was observed by using 3% concentration. The results of Tsai et al. demonstrated that NAC had great potential for wound healing, and may be a promising drug for healing of burn wounds. The etiology of RAS is also related to oxidative stress; therefore, NAC can have beneficial effects on RAS which was shown in the present study.

Arrangement of frequent visits for patients to measure the diameter of lesion during the study was one of the limitations of this study. Also, according to variations in pain tolerance thresholds of different individuals, reporting the pain score by patients themselves was

another limitation. Finally, despite daily calls to remind using the tablets, it was not possible to directly observe medication use by patients. Further multicenter studies are recommended with direct observation of medication use by patients to obtain more reliable results.

CONCLUSION

This study showed that the pain and diameter of RAS lesions as well as the duration of wound healing significantly decreased with the use of NAC mucoadhesive tablet. High safety, low side effects, and high compliance of patients in using NAC mucoadhesive tablet compared with the systemic form are the advantages of this formulation. According to these findings, NAC mucoadhesive tablet is recommended as one of the optimal options for RAS treatment.

ACKNOWLEDGMENTS

The authors would like to thank the Dental Clinic of Mazandaran University of Medical Sciences for cooperation in the study process.

CONFLICT OF INTEREST STATEMENT

None declared.

REFERENCES

1. Çiçek Y, Canakçi V, Ozgöz M, Ertas U, Canakçi E. Prevalence and handedness correlates of recurrent aphthous stomatitis in the Turkish population. *J Public Health Dent.* 2004 Summer;64(3):151-6.
2. Akintoye SO, Greenberg MS. Recurrent aphthous stomatitis. *Dent Clin North Am.* 2014 Apr;58(2):281-97.
3. Tarakji B, Gazal G, Al-Maweri SA, Azzeghaiby SN, Alaizari N. Guideline for the diagnosis and treatment of recurrent aphthous stomatitis for dental practitioners. *J Int Oral Health.* 2015 May;7(5):74-80.
4. Al-Omiri MK, Karasneh J, Alhijawi MM, Zwiri AM, Scully C, Lynch E. Recurrent aphthous stomatitis (RAS): a preliminary within-subject study of quality of life, oral health impacts and personality profiles. *J Oral Pathol Med.* 2015 Apr;44(4):278-83.
5. Hapa A, Aksoy B, Polat M, Aslan U, Atakan N. Does recurrent aphthous stomatitis affect quality of life? A prospective study with 128 patients evaluating different treatment modalities. *J Dermatolog Treat.* 2011 Aug;22(4):215-20.

6. Krisdapong S, Sheiham A, Tsakos G. Impacts of recurrent aphthous stomatitis on quality of life of 12- and 15-year-old Thai children. *Qual Life Res.* 2012 Feb;21(1):71-6.
7. McCullough MJ, Abdel-Hafeth S, Scully C. Recurrent aphthous stomatitis revisited; clinical features, associations, and new association with infant feeding practices? *J Oral Pathol Med.* 2007 Nov;36(10):615-20.
8. Sun A, Chen HM, Cheng SJ, Wang YP, Chang JY, Wu YC, et al. Significant association of deficiencies of hemoglobin, iron, vitamin B12, and folic acid and high homocysteine level with recurrent aphthous stomatitis. *J Oral Pathol Med.* 2015 Apr;44(4):300-5.
9. Babaei Hatkehlouei M, Dadgar S, Shokrzadeh M, Mousavi J, Sobouti F. A Review of the Requirements and Hazards of Toxic Metals From Orthodontic Wires. *Pharm Biomed Res* 2020; 6 (4) :251-260
10. Akoglu G, Metin A, Kilinc F, Pektas SD, Isikoglu S, Akbas A, et al. Total serum oxidant/antioxidant status and arylesterase activity in recurrent aphthous stomatitis. *Ann Dermatol.* 2013 Aug;25(3):273-7.
11. Bagan J, Saez G, Tormos C, Gavalda C, Sanchis JM, Bagan L, et al. Oxidative stress and recurrent aphthous stomatitis. *Clin Oral Investig.* 2014 Nov;18(8):1919-23.
12. Bilgili SG, Ozkol H, Takci Z, Ozkol HU, Karadag AS, Aslan M. Assessment of the serum paraoxonase activity and oxidant/antioxidant status in patients with recurrent aphthous stomatitis. *Int J Dermatol.* 2013 Oct;52(10):1259-64.
13. Tugrul S, Koçyiğit A, Doğan R, Eren SB, Senturk E, Ozturan O, et al. Total antioxidant status and oxidative stress in recurrent aphthous stomatitis. *Int J Dermatol.* 2016 Mar;55(3):e130-5.
14. Sawair FA. Does smoking really protect from recurrent aphthous stomatitis? *Ther Clin Risk Manag.* 2010 Nov 22;6:573-7.
15. Hamed S, Sadeghpour O, Shamsardekani MR, Amin G, Hajighasemali D, Feyzabadi Z. The Most Common Herbs to Cure the Most Common Oral Disease: Stomatitis Recurrent Aphthous Ulcer (RAU). *Iran Red Crescent Med J.* 2016 Feb 13;18(2):e21694.
16. Abdulrab S, Halboub E, Barnkgkei I, Al-Hebshi N. N-acetylcysteine as a candidate therapeutic for recurrent aphthous and aphthous-like ulcers. *Dent Hypotheses.* 2017 Jan 1;8(1):17.
17. Rushworth GF, Megson IL. Existing and potential therapeutic uses for N-acetylcysteine: the need for conversion to intracellular glutathione for antioxidant benefits. *Pharmacol Ther.* 2014 Feb;141(2):150-9.
18. Bémour C, Vaquero J, Desjardins P, Butterworth RF. N-acetylcysteine attenuates cerebral complications of non-acetaminophen-induced acute liver failure in mice: antioxidant and anti-inflammatory mechanisms. *Metab Brain Dis.* 2010 Jun;25(2):241-9.
19. Sansone RA, Sansone LA. Getting a Knack for NAC: N-Acetyl-Cysteine. *Innov Clin Neurosci.* 2011 Jan;8(1):10-4.
20. Heard K, Rumack BH, Green JL, Bucher-Bartelson B, Heard S, Bronstein AC, et al. A single-arm clinical trial of a 48-hour intravenous N-acetylcysteine protocol for treatment of acetaminophen poisoning. *Clin Toxicol (Phila).* 2014 Jun;52(5):512-8.
21. Çağlayan F, Miloglu O, Altun O, Erel O, Yilmaz AB. Oxidative stress and myeloperoxidase levels in saliva of patients with recurrent aphthous stomatitis. *Oral Dis.* 2008 Nov;14(8):700-4.
22. Albanidou-Farmaki E, Markopoulos AK, Kalogerakou F, Antoniadis DZ. Detection, enumeration and characterization of T helper cells secreting type 1 and type 2 cytokines in patients with recurrent aphthous stomatitis. *Tohoku J Exp Med.* 2007 Jun;212(2):101-5.
23. Dalghous AM, Freysdottir J, Fortune F. Expression of cytokines, chemokines, and chemokine receptors in oral ulcers of patients with Behçet's disease (BD) and recurrent aphthous stomatitis is Th1-associated, although Th2-association is also observed in patients with BD. *Scand J Rheumatol.* 2006 Nov-Dec;35(6):472-5.
24. Freysdottir J, Lau S, Fortune F. Gammadelta T cells in Behçet's disease (BD) and recurrent aphthous stomatitis (RAS). *Clin Exp Immunol.* 1999 Dec;118(3):451-7.
25. Ozyurt K, Celik A, Sayarlioglu M, Colgecen E, Inci R, Karakas T, et al. Serum Th1, Th2 and Th17 cytokine profiles and alpha-enolase levels in recurrent aphthous stomatitis. *J Oral Pathol Med.* 2014 Oct;43(9):691-5.
26. Tsai ML, Huang HP, Hsu JD, Lai YR, Hsiao YP, Lu FJ, et al. Topical N-acetylcysteine accelerates wound healing in vitro and in vivo via the PKC/Stat3 pathway. *Int J Mol Sci.* 2014 May 2;15(5):7563-78.
27. Halboub E, Alkadasi B, Alakhali M, AlKhairat A, Mdabesh H, Alkhasah S, et al. N-acetylcysteine versus chlorhexidine in treatment of aphthous ulcers: a preliminary clinical trial. *J Dermatolog Treat.* 2021 Sep;32(6):649-653.
28. Babae N, Zabihi E, Mohseni S, Moghadamnia AA. Evaluation of the therapeutic

- effects of Aloe vera gel on minor recurrent aphthous stomatitis. *Dent Res J (Isfahan)*. 2012 Jul;9(4):381-5.
29. Glick M. *Burket's oral medicine*. PMPH USA; 2015.
30. Slebioda Z, Szponar E, Kowalska A. Etiopathogenesis of recurrent aphthous stomatitis and the role of immunologic aspects: literature review. *Arch Immunol Ther Exp (Warsz)*. 2014 Jun;62(3):205-15. doi: 10.1007/s00005-013-0261-y. Epub 2013 Nov 12.
31. Deshmukh VN, Jadhav JK, Sakarkar DM. Formulation and in vitro evaluation of theophylline anhydrous bioadhesive tablets. *Asian J Pharm*. 2009;3:54-8.
32. Kiraz S, Akdogan A, Karadag O, Erden AB, Kilic L, Kalyoncu U, et al. AB1173 Prevalence of Recurrent Aphthous Stomatitis and Related Factors: Outcomes of Cappadocia Chronic Diseases Epidemiological Study. *Annals of the Rheumatic Diseases* 2015;74:1295.
33. Dixit V, Dixit M, Hegde V, Sathe S, Jadhav S. Clinical evaluation of conventional and laser tooth preparation using visual analogue scale. *J Dent Lasers*. 2013 Jan 1;7(1):27.
34. Pedersen A. Psychologic stress and recurrent aphthous ulceration. *J Oral Pathol Med*. 1989 Feb;18(2):119-22.
35. Scully C, Gorsky M, Lozada-Nur F. The diagnosis and management of recurrent aphthous stomatitis: a consensus approach. *J Am Dent Assoc*. 2003 Feb;134(2):200-7.
36. Saral Y, Coskun BK, Ozturk P, Karatas F, Ayar A. Assessment of salivary and serum antioxidant vitamins and lipid peroxidation in patients with recurrent aphthous ulceration. *Tohoku J Exp Med*. 2005 Aug;206(4):305-12.
37. Momen-Beitollahi J, Mansourian A, Momen-Heravi F, Amanlou M, Obradov S, Sahebamee M. Assessment of salivary and serum antioxidant status in patients with recurrent aphthous stomatitis. *Med Oral Patol Oral Cir Bucal*. 2010 Jul 1;15(4):e557-61.
38. Kuyumcu A, Akyol A, Buyuktuncer Z, Ozmen MM, Besler HT. Improved oxidative status in major abdominal surgery patients after N-acetyl cystein supplementation. *Nutr J*. 2015 Jan 6;14:4.
39. Mao G, Goswami M, Kalen AL, Goswami PC, Sarsour EH. N-acetyl-L-cysteine increases MnSOD activity and enhances the recruitment of quiescent human fibroblasts to the proliferation cycle during wound healing. *Mol Biol Rep*. 2016 Jan;43(1):31-9.
40. Li CL, Huang HL, Wang WC, Hua H. Efficacy and safety of topical herbal medicine treatment on recurrent aphthous stomatitis: a systemic review. *Drug Des Devel Ther*. 2015 Dec 31;10:107-15.