

## Left Ventricle Blood Attenuation in Non-Contrast Chest CT Scan as a Clue for Prediction of Anemia

Hamid Dahmardeh<sup>1</sup>, Aynaz Gerami<sup>2</sup>, Mahmoud Khansari<sup>3</sup>, Leyla Abdolkarimi<sup>4</sup>, Seyede Sara Pakdaman Kolour<sup>5</sup>, Majid Ghodsi<sup>6</sup>, Hoseinali Danesh<sup>7\*</sup> , Mohamad Ghazanfari Hashemi<sup>8\*</sup> 

<sup>1</sup>Department of Radiology, School of Medicine, Zahedan University of Medical Sciences, Zahedan, Iran

<sup>2</sup>School of Medicine, Tehran University of Medical Sciences, Tehran, Iran

<sup>3</sup>Department of General Surgery, School of Medicine, Tehran University of Medical Sciences, Tehran, Iran

<sup>4</sup>Rajaie Cardiovascular Medical and Research Center, Iran University of Medical Sciences, Tehran, Iran

<sup>5</sup>Department of Internal Medicine, Faculty of Medicine, Guilan University of Medical Sciences, Rasht, Iran

<sup>6</sup>Department of Surgery, School of Medicine, Sabzevar University of Medical Sciences, Sabzevar, Iran

<sup>7</sup>Plastic, Reconstructive & Aesthetic Surgeon, Associate professor of Zahedan University of Medical Sciences, Clinical Immunology Research Center, Zahedan University of Medical Sciences, Zahedan, Iran

<sup>8</sup>Department of Radiology, Cancer Institute, Tehran University of Medical Sciences, Tehran, Iran

\*Corresponding Authors: Hoseinali Danesh, Mohamad Ghazanfari Hashemi  
Email: [drdaneshha@yahoo.com](mailto:drdaneshha@yahoo.com), [mohamadghashemi@gmail.com](mailto:mohamadghashemi@gmail.com)

Received: 11 August 2023 / Accepted: 21 October 2023

### Abstract

**Purpose:** One of the indirect methods that has been proposed as a way of the detection of anemia is blood attenuation in non-contrast Computed Tomography (CT) scans. Some indices of non-contrast CT scans have been studied as a clue. Most known of such indices include aortic blood density and the difference between blood density and aortic wall density. In the current study, we aimed to evaluate the left ventricle blood attenuation and its relation to patients' hemoglobin levels.

**Materials and Methods:** A total of 523 patients who underwent non-contrast chest CT scan with available hemoglobin levels within 48 hours of interval from CT scan acquisition were recruited for this study. Left ventricle blood attenuation was measured and the correlation with hemoglobin levels was evaluated.

**Results:** There was found to be a linear correlation between blood attenuation in the left ventricle and hemoglobin levels ( $r=0.33$ ). Our results showed that the highest level of accuracy for diagnosis of anemia is in the Hounsfield Unit of 37.5 for women and 38.5 for men (with 68% sensitivity and 60% specificity) which can be regarded as a reliable threshold.

**Conclusion:** It can be concluded that the attenuation of the blood in the left ventricle can potentially be a hint for anemia and further evaluation for Hb levels.

**Keywords:** Non-Contrast Computed Tomography Scan; Anemia; Anemia Prediction; Hounsfield Unit; Left Ventricle Attenuation.

## 1. Introduction

Indirect data achieved from Computed Tomography (CT) scans has been sought for the prediction of several conditions from bone mineralization to risk assessment of pulmonary embolism [1, 2]. One kind of the subsidiary information attained by CT studies is the density of different tissues. Blood density is one of those quantitatively-assessable markers that can be utilized for a vast variety of purposes.

Anemia is reliably diagnosed via a Complete Blood Count (CBC) test and includes indices like Hemoglobin level, hematocrit, MCV (Mean Corpuscular Volume), MCH (Mean Corpuscular Hemoglobin), etc. either in symptomatic or asymptomatic individuals.

Although the diagnosis of anemia is not the main goal of performing CT scans, detecting subjects with anemia respecting CT markers had been previously studied to some extent, and a number of indices had been described as surrogates of anemia [3]. “Aortic ring sign”, as visibility of aortic wall in contrast with hypo attenuated aortic blood [4], and “Interventricular septum sign”, as sharp visibility of interventricular septum [5], are of the firstly-described markers for the prediction of anemia in CT scan. Besides the subjective nature of the aforementioned markers, interference of such markers with some pathologic conditions like hemochromatosis or glycogen storage diseases can have potential impacts on the final decision [6, 7]. As so, objective indices like CT Hounsfield Unit (HU) of aortic artery blood or the difference between HU of the interventricular septum and intraventricular blood have been proposed [8]. Moreover, some comparative studies have been conducted between such indices, the result of which revealed the superiority of “blood-interventricular septum density difference” over others [9].

In the current study, we focused on the left ventricular blood HU and its correlation with Hemoglobin (Hb) levels, as a clue for the detection of anemia, in patients who underwent chest CT scans.

## 2. Materials and Methods

### 2.1. Patients

All patients who underwent non-contrast chest CT scan for any indication with available CBC (Complete

Blood Count) with a 48-hour interval from the CT scan, from January 2017 to January 2019 were recruited for this cross-sectional study implemented in Imam Ali Hospital, Zahedan, Iran. Trauma patients and those with acute blood loss or transfusion, as well as those with ages less than 18 and more than 90 years, were kept out from the study sample. After consideration of inclusion and exclusion criteria, 523 patients were selected for the study.

Because this was a retrospective study, written informed consent was waived from the process. Also, all ethical considerations of Helsinki [10] were observed.

### 2.2. CT Acquisition

All CT scans were obtained utilizing a 64-slice CT machine (Siemens Medical System Inc., Erlangen, Germany). During CT acquisition, patients were in a supine position, the scans covered lung apices to the diaphragm, the caudocranial direction was applied and images were taken during patients’ inspiration [11]. The routine protocol for image acquisition includes items such as: tube voltage considered less than 120 kVp, the tube current as recommended by the automated current adjustment mode, and low dose variant adjust CTDI<sub>vol</sub> to less than 3 mGy.

After CT acquisition, an expert radiologist checked the images using the INFINIIT PACS System (INFINIIT Healthcare Co. Ltd., Seoul, South Korea). All studies were evaluated in standard mediastinal view in an axial plane. For achieving the HU of the blood in the left ventricle, an area (Region of Interest) with an approximate diameter of 10 mm was selected using “area” tools. The Mean HU given by the system was collected for each subject.

### 2.3. Hemoglobin

Hemoglobin levels were extracted from patients’ CBC examinations with a maximum interval of 48 hours from the CT scan. Also, all Hb levels were measured using the same protocol with the Sysmex machine (Sysmex Corporation, Kobe, Japan) [12].

Anemia was determined as Hb level less than 12 g/dL in men and less than 14 g/dL in women considering WHO guidelines [13].

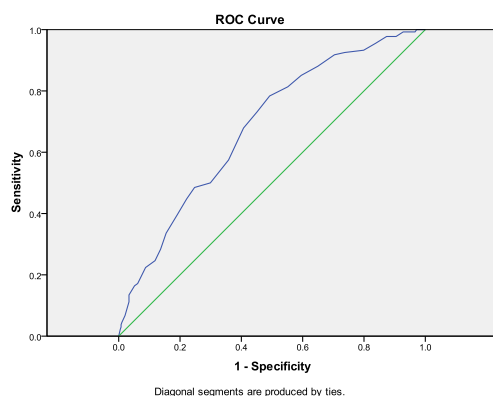
## 2.4. Statistical Analysis

The data were analyzed employing SPSS v21 (SPSS Inc., Chicago, Ill., USA) for Windows (Microsoft Corporations, Washington D.C, USA) with a significance level of 0.05 or less. Quantitative data were documented as numbers and percentages. The Pearson correlation method was applied for the comparison of the two variables. Receiver Operating Characteristic (ROC) curves were assessed for quantitative parameters to predict anemia comprehensively and define true positive versus false positive rates. Also, the Area Under the Curve (AUC) defined the average sensitivity value for all possible feature values.

## 3. Results

A total number of 523 subjects were recruited for this study including 276 males and 247 females. The average ages of men and women were 55 and 51, respectively. The average hemoglobin level in men was 11.5 and in women 10.8, and in total it was 11.1, and this difference in the level of hemoglobin was statistically significant (P-value=0.04).

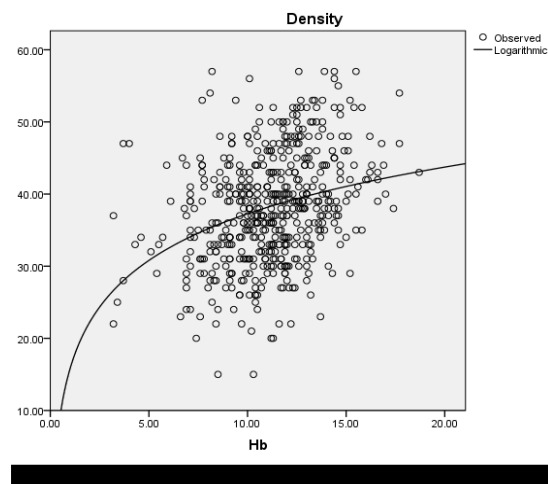
There was found to be a linear correlation between blood attenuation in the left ventricle and Hb levels ( $r=0.33$ ). This means that with the increase in the level of hemoglobin, the HU of the blood in the left ventricle also increases (Figure 1).



**Figure 1.** ROC chart for evaluation of correlation between left ventricle blood attenuation and Hemoglobin levels

In order to evaluate the diagnostic value of left ventricle HU for prediction of anemia and defining a cut-off point, our results showed that the highest level of accuracy for diagnosis of anemia is in HU of 37.5

for women and 38.5 for men (with 68% sensitivity and 60% specificity) and was not significantly different between either gender. Also, this correlation was consistent, as the age increased or decreased (Figure 2).



**Figure 2.** Hemoglobin level (g/dL) distribution with regard to left ventricular blood attenuation (HU)

## 4. Discussion

The results of the current study demonstrate that attenuation measurement is significantly more reliable than the subjective visual analysis for the recognition of anemia with respect to non-contrast CT because of the subjective nature of the visual assessment and lack of sufficient accuracy.

In this study, a linear correlation between Hb levels and left ventricular blood attenuation was found ( $r=0.33$ ) with a sensitivity and specificity of 66% and 60%, respectively.

In similar studies, a higher correlation rate was reported ( $r=0.77$ ) and the sensitivity and specificity were close to 100%. Although some other similar studies have reported lower sensitivity and specificity (90%), the correlation rate has always been high ( $r=0.7$ ) [14].

In previous articles, there was a difference in the intensity of the correlation between anemia and blood density in men and women, but this was not confirmed in our study [15].

The attenuation threshold for the detection of anemia in our investigation was 37.5 for women and 38.5 for men, while another study suggested a threshold of 35

[16]. The aforementioned difference in results may originate from such reasons: 1) The difference in the number of examined subjects; In our study, 523 patients were investigated, while in the other studies, only 100 or 40 patients were examined which were of lower sample size compared to ours. 2) The difference in the definitions of anemia; the WHO definition is considered for anemia in this review, whilst others have used different cut-offs (such as 10 g/dL for Hb). 3) In our study, due to the different definitions of anemia in men and women, the investigation was done separately, but other studies have considered all cases the same and analyzed them. 4) Differences in CT scan machines and protocols and also differences in blood biochemistry devices in different studies.

This study was a single-center study and selection bias was inevitable. Although the sample size was large enough to achieve a sufficient outline of the study's objectives, the larger the sample size is, the more accurate the results would be; Hence, studies with larger sample sizes are recommended in order to increase the reliability of the proposed results.

## 5. Conclusion

It can be concluded that the attenuation of the blood in the left ventricle can potentially be a hint for anemia and further evaluation for Hb levels. Nonetheless, direct examination of blood Hb is essential for confirmation.

## Acknowledgments

This article contains studies with human participants and the ethical code is [IR.ZAUMS.REC.1396.020].

## References

- 1- K. Y. Choi *et al.*, "Dual-Energy CT-Based Bone Mineral Density Has Practical Value for Osteoporosis Screening around the Knee." (in eng), *Medicina (Kaunas)*, Vol. 58 (No. 8), Aug 11 (2022).
- 2- Dahmardeh Hamid *et al.*, "Evaluation of Predictive Value of CT Pulmonary Angiography for Right Ventricular Failure in Patients with Pulmonary Embolism." *Frontiers in Biomedical Technologies*, Vol. 0 (No. 0), 06/20 (2023).
- 3- J. D. Dodd and R. MacDermott, "Anemia Detection with Contrast-enhanced Photon-counting CT." (in eng), *Radiology*, Vol. 305 (No. 3), pp. 653-54, Dec (2022).
- 4- P. Desaint, C. Bernard, and D. Contou, "Diagnosing Anemia with Chest CT-Scan: The Aortic Ring Sign." (in eng), *Am J Med Sci*, Vol. 363 (No. 2), p. e17, Feb (2022).
- 5- B. Abbasi, M. Seyed Hosseini, A. Moodi Ghalibaf, R. Akhavan, M. Emadzadeh, and E. Bolvardi, "Evaluating anemia on non-contrast thoracic computed tomography." (in eng), *Sci Rep*, Vol. 12 (No. 1), p. 21380, Dec 10 (2022).
- 6- T. Y. Kim, J. I. Jung, Y. J. Kim, H. W. Kim, and H. G. Lee, "CT and MRI evaluation of cardiac complications in patients with hematologic diseases: a pictorial review." (in eng), *Int J Cardiovasc Imaging*, Vol. 31 Suppl 2pp. 159-67, Dec (2015).
- 7- C. Manca, M. Claudin, A. Belle, P. Y. Marie, and A. Verger, "FDG PET/CT in Type I Glycogen Storage Disease." (in eng), *Clin Nucl Med*, Vol. 41 (No. 4), pp. e200-1, Apr (2016).
- 8- R. S. Tittle, K. Harper, E. Nelson, T. Evans, and R. Tello, "Observer performance in assessing anemia on thoracic CT." (in eng), *AJR Am J Roentgenol*, Vol. 185 (No. 5), pp. 1240-4, Nov (2005).
- 9- M. Foster, R. L. Nolan, and M. Lam, "Prediction of anemia on unenhanced computed tomography of the thorax." (in eng), *Can Assoc Radiol J*, Vol. 54 (No. 1), pp. 26-30, Feb (2003).
- 10- M. Czarkowski, "[Helsinki Declaration--next version]." (in pol), *Pol Merkur Lekarski*, Vol. 36 (No. 215), pp. 295-7, May (2014). Kolejna nowelizacja Deklaracji Helsińskieij.
- 11- T. Kubo *et al.*, "Low dose chest CT protocol (50 mAs) as a routine protocol for comprehensive assessment of intrathoracic abnormality." (in eng), *Eur J Radiol Open*, Vol. 3pp. 86-94, (2016).
- 12- G. Gulati, J. Song, A. D. Florea, and J. Gong, "Purpose and criteria for blood smear scan, blood smear examination, and blood smear review." (in eng), *Ann Lab Med*, Vol. 33 (No. 1), pp. 1-7, Jan (2013).
- 13- T. Milovanovic *et al.*, "Anemia as a Problem: GP Approach." (in eng), *Dig Dis*, Vol. 40 (No. 3), pp. 370-75, (2022).
- 14- J. A. Decker *et al.*, "Anemia Detection by Hemoglobin Quantification on Contrast-enhanced Photon-counting CT Data Sets." (in eng), *Radiology*, Vol. 305 (No. 3), pp. 650-52, Dec (2022).
- 15- A. I. Iuga, L. Pennig, L. L. Caldeira, D. Maintz, T. Hickethier, and J. Doerner, "Prediction of anemia on enhanced computed tomography of the thorax using virtual non-contrast reconstructions." (in eng), *Medicine (Baltimore)*, Vol. 100 (No. 48), p. e28014, Dec 3 (2021).
- 16- Q. Q. Zhou *et al.*, "Optimal threshold for the diagnosis of anemia severity on unenhanced thoracic CT: A preliminary study." (in eng), *Eur J Radiol*, Vol. 108pp. 236-41, Nov (2018).