


The Effect of Sagittal STIR and FLAIR Sequences Compared to Sagittal T2-W for Characterizing MS Lesions in Cervical Spine MRI

Karim Sharifi ¹, Daem Roshani ², Bakhtiar Moradi ³, Jamil Abdolmohammadi ⁴, Shadi Parvizpour ⁴, Neda Charekhah ⁴, Somaye Moloudi ⁴, Mozaffar Mahmoodi ^{5*} 

¹ Department of Radiology, Faculty of Medicine, Kurdistan University of Medical Sciences, Sanandaj, Iran

² Department of Epidemiology and Biostatistics, Faculty of Medicine, Kurdistan University of Medical Sciences, Sanandaj, Iran

³ Shahid Ghazi MRI Center, Sanandaj, Iran

⁴ Department of Radiology, Faculty of Paramedical, Kurdistan University of Medical Sciences, Sanandaj, Iran

⁵ Department of Molecular Medicine and Medical Biotechnology, Faculty of Medicine, Kurdistan University of Medical Sciences, Sanandaj, Iran

*Corresponding Author: Mozaffar Mahmoodi
Email: m.mahmoodi@muk.ac.ir

Received: 09 July 2022 / Accepted: 11 August 2022

Abstract

Purpose: Multiple Sclerosis (MS) is an acute, autoimmune, and inflammatory disease in the central nervous system. This study investigated the effect of sagittal Short Tau Inversion Recovery (STIR) and T2-W Fluid Attenuated Inversion Recovery (FLAIR) sequences rather than sagittal T2-W as complementary sequences in patients with cervical spinal cord lesions and suspected MS.

Materials and Methods: This cross-sectional study was performed on all individuals referred to the Shahid Ghazi MRI center in Sanandaj for six months. Sixty patients with a cervical spine MRI request that were suspected of having MS were examined. The number of MS plaques in the sagittal T2-W FSE, sagittal STIR, and sagittal T2-W FLAIR were recorded separately. A comparison between routine sequences and sequence supplementation has been made for characterizing MS plaque in the spine.

Results: Results showed that the greatest agreement was related to sagittal STIR, and sagittal FLAIR (Cohen's kappa = 0.56). Whereas the least agreement values were from sagittal T2-W and sagittal FLAIR, STIR and FLAIR, T2-W and FLAIR, T2-W and STIR (Cohen's kappa = 0.20, 0.33, 0.48, 0.55), respectively. Sagittal STIR and sagittal FLAIR were excellent predictors for MS plaques diagnosis due to the area under the ROC curve = 0.56; sensitivity (95% CI) = [0.85 (0.73426 to 0.929044)] and specificity (95% CI) = [0.46 (0.336699 to 0.600035)].

Conclusion: Results show that FLAIR T2-W images in sagittal sequence are appropriate for detecting lesions around spinal cord lesions. Furthermore, using thresholds obtained via statistical analysis, plaques in the cervical spinal cord can be identified in sagittal STIR images.

Keywords: Magnetic Resonance Imaging; Multiple Sclerosis; Cervical Spinal Cord Lesion; Short Tau Inversion Recovery; Fluid Attenuated Inversion Recovery.

1. Introduction

Multiple Sclerosis (MS) is an acute, autoimmune, and inflammatory disease in the Central Nervous System (CNS) that results from demyelination, often resulting in synaptic dysfunction in the brain and spinal cord [1-3]. MS is the main cause of non-traumatic disability in young adults and leads to irreversible, progressive sensory and motor function impairment [4-5]. Although this progressive disease may occur at any age, diagnosis typically occurs from 20 to 50 years [3, 6, 7]. Although the cause of MS remains unknown, the transmission of peripheral immune cells and their access to CNS through disruption of the Blood-Brain Barrier (BBB) plays a crucial role in MS incidence [8]. As a result, a range of mild to severe symptoms occurs, including visual problems, sensory disturbances, muscle cramps, cerebellar disorders, urinary problems, and speech disorders. Mortality due to this disease is limited. In most cases, the cause of death is due to marginal reasons, such as infection and bed sores [9-10]. In general, no specific clinical signs or laboratory tests can confirm or eliminate MS as the causative disease. Currently, diagnosis is achieved by evaluating a combination of accurate health history, neurological examination, Magnetic Resonance Imaging (MRI), Visual Evoked Potentials (VEP) and analysis of Cerebrospinal Fluid (CSF), review and history of neurology and psychiatric counseling in cases of psychological or cognitive symptoms, and evaluation of immune system proteins present in the blood [11-12]. Because the effectiveness of treatment depends on early implementation, an accurate and fast diagnosis of multiple sclerosis is critical. Studies have shown that misdiagnosis of multiple sclerosis can have serious consequences, including the need for subsequent aggressive immunosuppressive therapy [13]. In addition, the association of atypical manifestations of MS with non-specific white matter lesions in MRI images can lead to a misdiagnosis of MS [14-16]. In previous studies, MRI was strongly emphasized, resulting in early detection with high specificity and sensitivity which allowed timely treatment [17]. Currently, MRI is the preferred diagnostic method for all soft tissue lesions and for diagnosing MS plaques in the brain and spinal cord [18-20]. MR images are obtained using a variety of pulse sequences, including T1-weighted, T2-

weighted, Inversion Recovery (IR), and Gradient Echo (GE), and by measuring the signal generated by the nucleus of hydrogen in response to a magnetic field [21]. MR images using different pulse sequences, including T1-weighted, T2-weighted, Inversion Recovery (IR), and Gradient Echo (GE), and measuring the signal produced by the hydrogen nucleus in response to the magnetic field to detect different types of the spinal cord and soft tissue lesions are obtained.

In patients with MS, there are numerous plaques (various sizes, sharp edges, round, oval, or irregular shapes) due to demyelination. MRI is helpful in differential diagnosis. Identifying the exact location of MS lesions is often difficult, as approximately 80% of cases involve the spinal cord, most often within the cervical region [22]. MS plaques may be present in the spinal cord. Approximately 80% of patients with MS are more involved in the spinal cord, especially the cervical spinal cord. For this reason, an MRI of the spinal cord is required in patients with relevant symptoms and when multiple sclerosis is diagnosed after a brain MRI [23-24]. The standard MRI protocol for MS diagnosis includes T1 weighted (T1-W), T2 weighted (T2-W), and Fluid Attenuated Inversion Recovery (FLAIR) images [25]. A key problem in assessing spinal cord injury due to MS is the occurrence of artifacts that are presented as small shadows of the spinal cord and surrounding tissue.

Sagittal T2-W and T1-W sequences are routinely evaluated; however, some plaques may not be seen with these sequences and detection may be difficult. Therefore, the present study assessed the effect of evaluating sagittal STIR and T2-W FLAIR sequences in addition to sagittal T2-W in patients with suspected MS on disease diagnosis.

2. Materials and Methods

2.1. The Study Design

This cross-sectional study was approved by the Kurdistan University of medical sciences. The present study was performed on all individuals who were referred to the Shahid Ghazi MRI center in Sanandaj for a period of six months. Data from sixty patients with suspected MS and cervical spine cord MR images were examined. Written informed consent was

obtained from all patients before entering the study. The exclusion criteria comprised MRI contraindications, including severe claustrophobia and the presence of a pacemaker (Figure 1). This study results from an approved research project in Kurdistan University of Medical Sciences No. 1395/100.

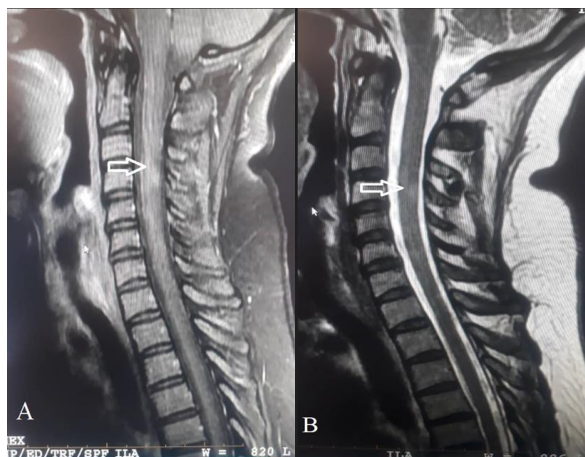


Figure 1. Demonstration of MS plaques using sagittal STIR (A), sagittal T2-W (B); as you can see, the cervical spinal cord plaques are more evident in the FLAIR sequence

2.2. MR Image Acquisition

A radio technologist performed the MRI with a GE HDxt 1.5T system embedded with an eight-channel coil (HD 8-channel CTL Array coil by GE). Routine cervical MRI sequences were performed, including sagittal T2-W FSE, sagittal T1-W FSE, and axial Multiple Echo Recombined Gradient Echo (MERGE), followed by sagittal STIR and sagittal T2-W FLAIR sequences; images were interpreted by two radiologists (Table 1). The number of MS plaques present in routine sequences was compared to those present in the additional sequences, and the radiology

report determined the effect of the use of the different sequences on the identification of the presence of MS plaques.

A comparison between routine sequences (the gold standard of MS diagnosis) and sequences supplementation is made for greater clarity of MS plaque in the spine. We used the Nayak study to analyze the results and clarify the standard Cohen's Kappa criteria [26]. Finally, the relevant radiologist, after thoroughly examining the sequences and reporting the images, announces the effect of these sequences in identifying MS plaque in the spine.

2.3. Sampling Method Calculation

The sample size was collected for six months. We used the mean comparison formula with 95% confidence and 80% power to determine the sample size. According to the correlation coefficient of the correlation studies, the number of samples is 60. It should be noted that in this study, the sample size was considered as a six-month period, and the samples were included in the study from September to March in 2016 when they referred to Shahid Ghazi Sanandaj MRI Center.

2.4. Statistical Analysis

Data was analyzed using the Receiver Operating Characteristic (ROCs) curve using a complete set of 6 parameters and statistical calculations were performed using STATA software. The agreement index between categories was reported by Cohen's kappa (Fleiss-Cusick extension). Disagreement over any category and asymmetry of disagreement was analyzed using

Table 1. MRI imaging protocol for Multiple Sclerosis according to the type of sequences and physical parameters

Sequence name	Protocol	Matrix size	Projection	Number of slices	TR (ms)	TE (ms)	Flip angle	Slice width (mm)	FOV (mm)	TI
Sagittal T2-W	FSE	320 x 224	Sagittal	9	2520	85	90	3.5	240	-
Sagittal T1-W	FSE	326 x 224	Sagittal	9	840	20	90	3.5	240	-
Axial MERGE	GRE	256 x 192	Axial	16	300	5	15	3	240	-
Sagittal STIR	STIR	256 x 192	Sagittal	9	2000	50	180	3.5	240	150
Sagittal T2-W FLAIR	FLAIR	256 x 192	Sagittal	9	6000	100	180	3.5	240	1250
Axial T2-W	FSE	256 x 192	Axial	16	2000	80	90	3.5	240	-
Sagittal T2-W +C	FSE	324 x 192	Sagittal	9	840	20	90	3.5	240	-
Axial T2-W + C	FSE	256 x 192	Axial	16	800	20	90	3	240	-

the Maxwell chi-square (Marginal homogeneity) and generalized McNemar chi-square (Symmetry). P values below 0.001 were considered statistically significant (Table 2).

The Receiver Operating Characteristic (ROC) was analyzed to compare the detection ability, sensitivity, and accuracy of all categories to determine the optimum cut-off point with the maximum ability to detect plaques. The area under the ROC curve was estimated by Wilcoxon (Figure 2-7).

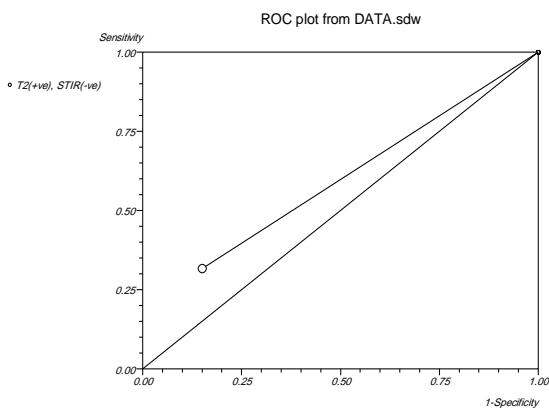


Figure 2. ROC curve analysis for T2-W and STIR, sensitivity, and specificity were 0.31 and 0.85, respectively

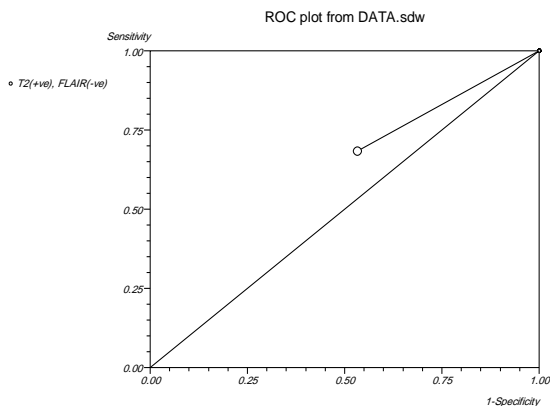


Figure 3. ROC curve analysis for T2-W and FLAIR, sensitivity, and specificity were 0.68 and 0.46, respectively

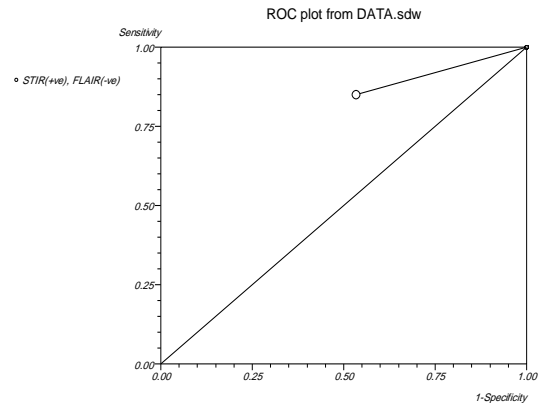


Figure 4. ROC curve analysis for STIR and FLAIR, sensitivity, and specificity were 0.85 and 0.46, respectively

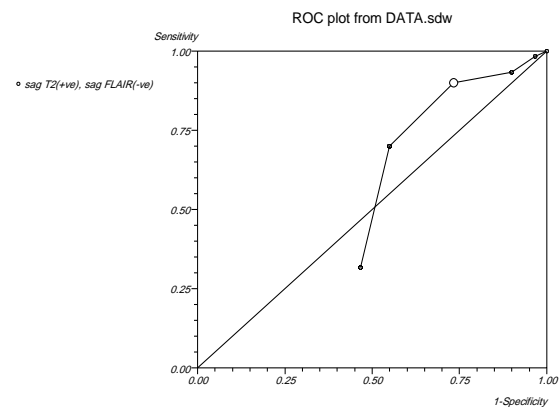


Figure 5. ROC curve analysis for sagittal T2-W and sagittal FLAIR, sensitivity, and specificity were 0.9 and 0.26, respectively

3. Results

Of the 60 patients studied, 25 (41.66%) were male (mean age, 35 years), and 35 (58.33%) were female (mean age, 33 years).

The agreement index between T2-W and FLAIR sequences evaluation (Table 3) was 0.48 with a 95% CI (0.24, 0.72; $p < 0.001$).

Table 2. The agreement index between T2-W and STIR

	Plaque not identified in STIR	Plaque identified in STIR	Cohen's kappa	95% confidence interval	P value
Plaque not identified seen in T2-W	9	10	0.55	0.32 to 0.77	<0.0001
Plaque identified in T2-W	0	41			

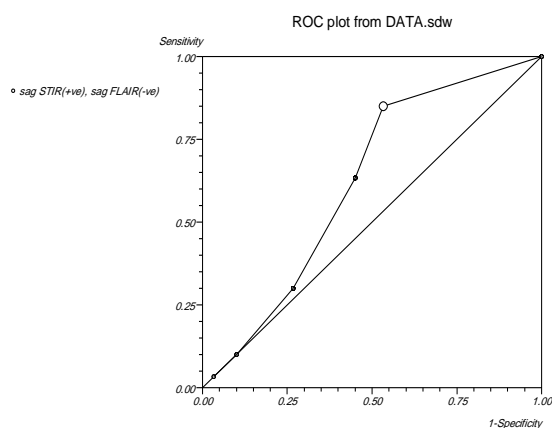


Figure 6. ROC curve analysis for sagittal STIR and sagittal FLAIR, sensitivity, and specificity were 0.85 and 0.46, respectively

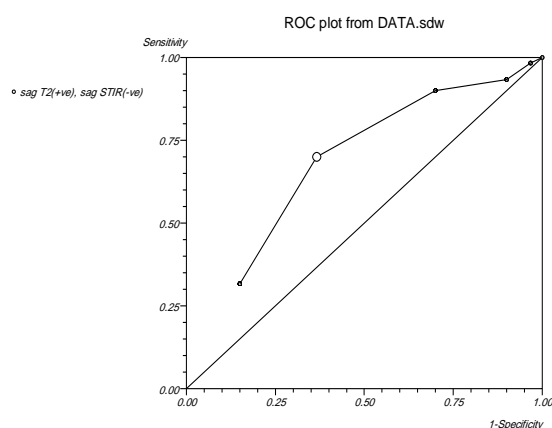


Figure 7. ROC curve analysis for sagittal T2-W and sagittal STIR, sensitivity, and specificity were 0.7 and 0.63, respectively

The agreement index between sagittal T2-W and sagittal FLAIR sequences evaluation (Table 5) was 0.20 with a 95% CI (0.08, 0.32; $p=0.0004$). As seen from Table 5, the degree of matching of the sequence FLAIR and T2-W in the visualization of MS plaques was different in various situations. For instance, 16 cases of plaques were not observed in both sequences, while there were only two cases where the plaques can be seen in FLAIR but not observed in T2-W.

Table 3. The agreement index between T2-W and FLAIR

	Plaque not identified in FLAIR	Plaque identified in FLAIR	Cohen's kappa	95% confidence interval	P value
Plaque not identified in T2-W	16	3	0.48	0.24 to 0.72	<0.0001
Plaque identified in T2-W	12	29			

Similarly, other situations are also reported in this Table.

A comparison of the ability to detect plaques in different sequences, as indicated by the agreement index between categories, is summarized (Tables 2-6). The agreement index between T2-W and STIR sequences evaluation (Table 2) was 0.55 with a 95% CI (0.32, 0.77; $p < 0.001$).

The agreement index between STIR and FLAIR sequences evaluation (Table 4) was 0.33 with a 95% CI (0.14, 0.52; $p=0.0003$).

The agreement index between sagittal STIR and sagittal FLAIR sequences evaluation (Table 6) was 0.56 with a 95% CI (0.45, 0.68; $p < 0.0001$). As can be seen from Table 6, the degree of matching of the sequence FLAIR and STIR in the visualization of MS plaques was different in various situations. For instance, 9 cases of plaques were not observed in both sequences, while there were no cases where the plaques can be seen in FLAIR but not in STIR. Similarly, other situations are also reported in this Table.

The results showed that the highest agreement was related to sagittal STIR, and sagittal FLAIR, T2-W and STIR, respectively [Cohen's kappa = 0.56, 0.55 (moderate agreement)], and the lowest values were related to sagittal T2-W and sagittal FLAIR, STIR and, FLAIR, T2-W and, FLAIR, (Cohen's kappa = 0.20, 0.33, 0.48), respectively.

ROC curve analysis further investigated the amount of agreement between different sequences to diagnose MS plaques. The area under the ROC curve was found 0.56 for sagittal STIR and sagittal FLAIR suggesting that these combinations with sensitivity of (95% CI) = [0.85 (0.73426 to 0.929044)] and specificity of (95% CI) = [0.46 (0.336699 to 0.600035)] were excellent predictors for diagnosis of MS plaques. In addition, the optimum cut-off point selected for sagittal STIR and sagittal FLAIR was 1.

Table 5. The agreement index between sagittal T2-W and sagittal FLAIR

	Plaque not identified in sagittal FLAIR	A Plaque identified in sagittal FLAIR	Two Plaque identified in sagittal FLAIR	Three Plaque identified in sagittal FLAIR	Four Plaque identified in sagittal FLAIR	Five Plaque identified in sagittal FLAIR	Cohen's kappa	95% confidence interval	P value
Plaque not identified in sagittal STIR	9	0	0	0	0	0			
Plaque identified in sagittal STIR	9	4	0	0	0	0			
Two Plaque identified in sagittal STIR	9	1	10	0	0	0			
Three Plaque identified in sagittal STIR	1	0	1	10	0	0	0.56	0.45 to 0.68	<0.0001
Four Plaque identified in sagittal STIR	0	0	0	0	4	0			
Five Plaque identified in sagittal STIR	0	0	0	0	0	2			

Table 6. The agreement index between sagittal STIR and sagittal FLAIR

	Plaque not identified in sagittal FLAIR	A Plaque identified in sagittal FLAIR	Two Plaque identified in sagittal FLAIR	Three Plaque identified in sagittal FLAIR	Four Plaque identified in sagittal FLAIR	Five Plaque identified in sagittal FLAIR	Cohen's kappa	95% confidence interval	P value
Plaque not identified in sagittal STIR	9	0	0	0	0	0			
Plaque identified in sagittal STIR	9	4	0	0	0	0			
Two Plaque identified in sagittal STIR	9	1	10	0	0	0	0.56	0.45 to 0.68	<0.0001
Three Plaque identified in sagittal STIR	1	0	1	10	0	0			
Four Plaque identified in sagittal STIR	0	0	0	0	4	0			
Five Plaque identified in sagittal STIR	0	0	0	0	0	2			

4. Discussion

This study aimed to evaluate the diagnostic value of sagittal STIR and sagittal FLAIR MRI sequences of the spinal cord versus these sequences with the standard MRI protocol for MS diagnosis. Results demonstrate that the sagittal STIR and T2-W FLAIR with a 1.5 Tesla system successfully identify MS plaques because Cohen's kappa showed high agreement in statistical analyses.

In the present study, all plaques in sagittal STIR and T2-W FLAIR images had greater signal intensity than the background. Therefore, T2-W FLAIR images in sagittal view are appropriate for detecting lesions around the ventricles and the cortex. In addition, using threshold values obtained, plaques in the spinal cord, especially the cervical spinal cord, can be identified in sagittal STIR and T2-W FLAIR images.

Alcaide-Leon *et al.* compared sagittal FSE T2-W, STIR, and T1 phase-sensitive inversion recovery sequences in the detection of cervical spinal lesions by the 3 Tesla scanners. Results showed that STIR and PSIR to detect cervical cord plaques are much more significant than FSE T2-W ($P < 0.05$), and no significant differences were observed in the sensitivity between PSIR and STIR.

In cervical and thoracic segments, the value of agreement index among the interpreters for the STIR sequence was greater than that of the FSE T2-W and PSIR [27].

In comparing MS patients to healthy controls, Absinto and co-workers [28] demonstrated that spinal cord lesions in the STIR were three times clearer than in other sequences. The total damage volume was two times larger in this sequence when including T2-W FSE, STIR, and T1-W GRE protocols at the sagittal and axial planes in the presence of MS plaque identification, spatial and contrast resolution, thereby demonstrating the importance of STIR sequence evaluation [28].

In another study to examine MS plaques using MRI imaging by Cristina Philpott *et al.* in 2010, 12 patients were reviewed in Australia using T2-W FSE and T1-W STIR at the sagittal plane to evaluate contrast and image quality. Similarly, approximately 28% of MS lesions were evident in the STIR but absent in the T2-W sequence when contrast and image quality of T2-W

FSE and T1-W STIR at the sagittal plane were compared [29].

Foroghi *et al.* from different sequences such as; used T2-W, STIR, and Phase-Sensitive Inversion Recovery (PSIR) to detect MS plaques. The MRI machine used was a 1.5 T Siemens MR scanner. Consistent with the results of our study, they stated that recovery inversion sequences were more sensitive than other sequences in detecting MS plaque lesions in the cervical spinal cord [30].

A limitation in the present study was the use of the low-power 1.5 Tesla MRI system, resulting in reduced image quality. It is recommended that future work be performed with a 3 Tesla MRI system, as the increased magnet power reduces acquisition time, increases Signal-to-Noise Ratio (SNR), and improves resolution, thereby increasing image quality.

5. Conclusion

The present study shows that when used as complementary sequences for the identification of MS plaques, sagittal STIR and T2-W FLAIR MRI sequences provide more sensitive, specific, and accurate results than the use of sagittal T2-W in cervical spinal cord lesions. In addition, our findings reveal that the sagittal STIR and T2-W FLAIR using a 1.5 Tesla system, regardless of the lower available power, can be used to identify MS plaques successfully.

Acknowledgments

The financial and credit resources of the project are provided by the Research Assistant of Kurdistan University of Medical Sciences. In addition, we would like to thank the management and radiotechnologists of Shahid Ghazi MRI center in Sanandaj who have contributed to the manuscript.

References

- 1- Freya Corfield and Dawn Langdon, "A systematic review and meta-analysis of the brief cognitive assessment for multiple sclerosis (BICAMS)." *Neurology and therapy*, Vol. 7 (No. 2), pp. 287-306, (2018).
- 2- Massimo Ralli *et al.*, "Otolaryngologic symptoms in multiple sclerosis: a review." *The International Tinnitus Journal*, Vol. 22 (No. 2), pp. 160-69, (2018).

- 3- Marisa P McGinley, Carolyn H Goldschmidt, and Alexander D Rae-Grant, "Diagnosis and treatment of multiple sclerosis: a review." *Jama*, Vol. 325 (No. 8), pp. 765-79, (2021).
- 4- Ramya Talanki Manjunatha, Salma Habib, Sai Lahari Sangaraju, Daniela Yopez, and Xavier A Grandes, "Multiple Sclerosis: Therapeutic Strategies on the Horizon." *Cureus*, Vol. 14 (No. 5), (2022).
- 5- Hyun-Yoon Ko, "Nontraumatic Spinal Cord Injuries/Lesions." in *Management and Rehabilitation of Spinal Cord Injuries: Springer*, (2022), pp. 317-51.
- 6- Naila Makhani and Helen Tremlett, "The multiple sclerosis prodrome." *Nature Reviews Neurology*, Vol. 17 (No. 8), pp. 515-21, (2021).
- 7- Ron Milo and Esther Kahana, "Multiple sclerosis: geoepidemiology, genetics and the environment." *Autoimmunity reviews*, Vol. 9 (No. 5), pp. A387-A94, (2010).
- 8- Ane CE Moor, Helga E de Vries, Albertus G de Boer, and Douwe D Breimer, "The blood-brain barrier and multiple sclerosis." *Biochemical pharmacology*, Vol. 47 (No. 10), pp. 1717-24, (1994).
- 9- J Nieves, F Cosman, J Herbert, V Shen, and R Lindsay, "High prevalence of vitamin D deficiency and reduced bone mass in multiple sclerosis." *Neurology*, Vol. 44 (No. 9), pp. 1687-87, (1994).
- 10- Mohaddeseh Azadvari, Omid Mirmosayyeb, Maryam Hosseini, Saeed Vaheb, and Seyede Zahra Emami Razavi, "The prevalence of osteoporosis/osteopenia in patients with multiple sclerosis (MS): a systematic review and meta-analysis." *Neurological Sciences*, pp. 1-14, (2022).
- 11- Ruth Ann Marrie et al., "Effect of comorbidity on mortality in multiple sclerosis." *Neurology*, Vol. 85 (No. 3), pp. 240-47, (2015).
- 12- W Ian McDonald et al., "Recommended diagnostic criteria for multiple sclerosis: guidelines from the International Panel on the diagnosis of multiple sclerosis." *Annals of Neurology: Official Journal of the American Neurological Association and the Child Neurology Society*, Vol. 50 (No. 1), pp. 121-27, (2001).
- 13- Paula Wildner, Mariusz Stasiołek, and Mariola Matysiak, "Differential diagnosis of multiple sclerosis and other inflammatory CNS diseases." *Multiple Sclerosis and Related Disorders*, Vol. 37p. 101452, (2020).
- 14- Brett S Travers, Benjamin KT Tsang, and Joshua L Barton, "Multiple sclerosis: Diagnosis, disease-modifying therapy and prognosis." *Australian Journal of General Practice*, Vol. 51 (No. 4), pp. 199-206, (2022).
- 15- DH Miller, RI Grossman, SC Reingold, and HF McFarland, "The role of magnetic resonance techniques in understanding and managing multiple sclerosis." *Brain: a journal of neurology*, Vol. 121 (No. 1), pp. 3-24, (1998).
- 16- Yang Ma et al., "Multiple sclerosis lesion analysis in brain magnetic resonance images: techniques and clinical applications." *IEEE Journal of Biomedical and Health Informatics*, (2022).
- 17- Ke-Ru Li et al., "The Key Role of Magnetic Resonance Imaging in the Detection of Neurodegenerative Diseases-Associated Biomarkers: A Review." *Molecular Neurobiology*, pp. 1-20, (2022).
- 18- Seraj Mohaghegh, Ali Tarighatnia, Yadollah Omidi, Jaleh Barar, Ayuob Aghanejad, and Khosro Adibkia, "Multifunctional Magnetic Nanoparticles for MRI-guided Co-delivery of Erlotinib and L-Asparaginase to Ovarian Cancer." *Journal of Microencapsulation*, (No. just-accepted), pp. 1-31, (2022).
- 19- Stefan Weidauer, Peter Raab, and Elke Hattingen, "Diagnostic approach in multiple sclerosis with MRI: an update." *Clinical Imaging*, Vol. 78pp. 276-85, (2021).
- 20- Karim Sharifi et al., "Investigation of the frequency of meniscal ligament injuries and other abnormal knee injuries in the patients referring to MRI Center of Shahid Ghazi Clinic in Sanandaj." *Scientific Journal of Kurdistan University of Medical Sciences*, Vol. 21 (No. 6), (2017).
- 21- Ali Tarighatnia, Gurkaran Johal, Ayuob Aghanejad, Hossein Ghadiri, and Nader D Nader, "Tips and Tricks in Molecular Imaging." *Frontiers in Biomedical Technologies*, Vol. 8 (No. 3), pp. 226-35, (2021).
- 22- Laura Emilia Toader et al., "Cerebrolysin increases motor recovery and decreases inflammation in a mouse model of autoimmune encephalitis." *Romanian journal of morphology and embryology*, Vol. 59 (No. 3), pp. 755-62, (2018).
- 23- Dragan A Stojanov, Aleksandra Aracki-Trenkic, Slobodan Vojinovic, Daniela Benedeto-Stojanov, and Srdjan Ljubisavljevic, "Increasing signal intensity within the dentate nucleus and globus pallidus on unenhanced T1W magnetic resonance images in patients with relapsing-remitting multiple sclerosis: correlation with cumulative dose of a macrocyclic gadolinium-based contrast agent, gadobutrol." *European radiology*, Vol. 26 (No. 3), pp. 807-15, (2016).
- 24- A Traboulsee et al., "Revised recommendations of the consortium of MS centers task force for a standardized MRI protocol and clinical guidelines for the diagnosis and follow-up of multiple sclerosis." *American Journal of Neuroradiology*, Vol. 37 (No. 3), pp. 394-401, (2016).
- 25- Wolfgang Krauss, Martin Gunnarsson, Margareta Nilsson, and Per Thunberg, "Conventional and synthetic MRI in multiple sclerosis: a comparative study." *European radiology*, Vol. 28 (No. 4), pp. 1692-700, (2018).
- 26- NB Nayak, R Salah, JC Huang, and GM Hathout, "A comparison of sagittal short T1 inversion recovery and T2-weighted FSE sequences for detection of multiple sclerosis spinal cord lesions." *Acta Neurologica Scandinavica*, Vol. 129 (No. 3), pp. 198-203, (2014).

- 27- Paula Alcaide-Leon *et al.*, "Comparison of sagittal FSE T2, STIR, and T1-weighted phase-sensitive inversion recovery in the detection of spinal cord lesions in MS at 3T." *American Journal of Neuroradiology*, Vol. 37 (No. 5), pp. 970-75, (2016).
- 28- Govind Nair, Martina Absinta, and Daniel S Reich, "Optimized T1-MPRAGE sequence for better visualization of spinal cord multiple sclerosis lesions at 3T." *American Journal of Neuroradiology*, Vol. 34 (No. 11), pp. 2215-22, (2013).
- 29- Cristina Philpott and Peter Brotchie, "Comparison of MRI sequences for evaluation of multiple sclerosis of the cervical spinal cord at 3 T." *European journal of radiology*, Vol. 80 (No. 3), pp. 780-85, (2011).
- 30- Amin Abolhasani Foroughi, Mahdi Saeedi-Moghadam, Banafsheh Zeinali-Rafsanjani, and Masoume Nazeri, "Comparison between T2, STIR and PSIR sequences, for detection of cervical cord MS plaques." *Iranian Journal of Radiology*, Vol. 16 (No. 3), (2019).