

# A Patient With Optic Nerve Pit Maculopathy Successfully Treated With Juxtapapillary Laser Photocoagulation



Homayoun Nikkhah<sup>1</sup> , Iman Ansari<sup>1</sup> , Kiana Hassanpour<sup>1,2\*</sup> 

1. Ophthalmic Research Center, Research Institute for Ophthalmology and Vision Science, Shahid Beheshti University of Medical Sciences, Tehran, Iran.  
 2. Department of Ophthalmology, Imam Hossein Hospital, Shahid Beheshti University of Medical Sciences, Tehran, Iran.

Use your device to scan and read the article online



**Citation** Nikkhah H, Ansari I, Hassanpour K. A Patient With Optic Nerve Pit Maculopathy Successfully Treated With Juxtapapillary Laser Photocoagulation. Case Reports in Clinical Practice. 2021; 6(4):155-159.

**Running Title:** Optic Nerve Pit Maculopathy



## Article info:

**Received:** 10 July 2021

**Revised:** 13 August 2021

**Accepted:** 25 August 2021

## Keywords:

Congenital anomaly; Optic disc pit; Maculopathy; Laser therapy

## ABSTRACT

Optic disc pits are rare and congenital or acquired anomalies of the optic disc, usually remaining asymptomatic. However, serous macular detachment or optic disc maculopathy is the most common complication, causing significant visual deterioration, without a current consensus about treatment. A 55-year-old woman with a past medical history of diabetes mellitus and systemic hypertension was referred for an abnormal finding in the retina. The Corrected Distance Visual Acuity (CDVA) was 20/40 in the right eye and 20/30 in the left eye. Marcus-Gunn was negative and Slit-lamp biomicroscopy revealed no pathologic findings in both eyes. Funduscopy examination showed an excavation in the inferotemporal part of the Optic Nerve Head (ONH) with serous macular detachment extending to the optic disc. Based on clinical examination and paraclinical imaging fluorescein Angiography (FAG) Optical Coherence Tomography (OCT), optic pit maculopathy was diagnosed and the patient underwent Juxtapapillary Laser Photocoagulation (JLP). After 2 years of follow-up, there were anatomical and functional improvements.

## Introduction

**O**ptic Nerve Pit (ONP) is a rare congenital or acquired disorder of the optic nerve head with an incidence of approximately 1 in 10,000 eyes that may progress to the ONP maculopathy in 25% to 75% of the patients [1, 2]. ONP can cause visual symptoms or can

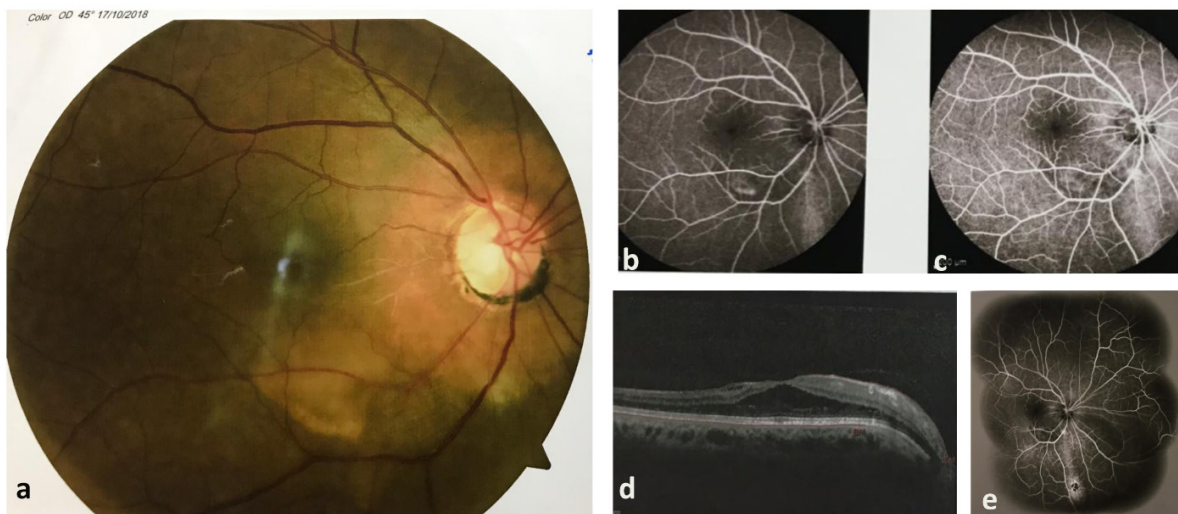
be incidentally found in ophthalmic examinations. ONP maculopathy can decrease final visual acuity less than 20/200 in 80% of eyes [2-4]. Various modalities have been proposed for the management of ONP maculopathy, including Pars Plana Vitrectomy (PPV). During PPV, laser photocoagulation and the injection of sulfur hexafluoride (SF6) or perfluoropropane (C3F8) as a tamponade have been tried in many studies [5-7].

### \* Corresponding Author:

**Kiana Hassanpour, MD, MPH.**

**Address:** Ophthalmic Research Center, Research Institute for Ophthalmology and Vision Science, Shahid Beheshti University of Medical Sciences, Tehran, Iran.

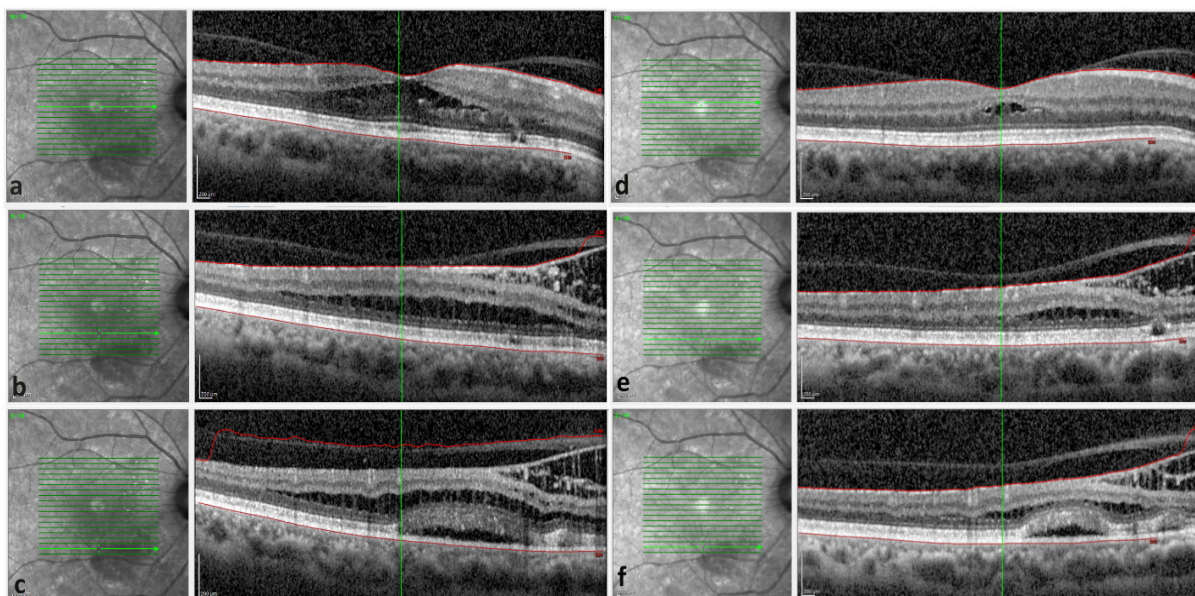
**E-mail:** [kiana.hassanpour@gmail.com](mailto:kiana.hassanpour@gmail.com)



**Figure 1.** Color fundus (a) of the right eye shows a white area of excavation in the temporal part of the optic disc. Retinal pigmentary changes are observed along the inferotemporal arcade. Early and mid-arteriovenous phases of fluorescein angiography show a blockage area adjacent to the Retinal Pigment Epithelial (RPE) alterations compatible with chronic serous retinal detachment. Mild intraretinal leakage is also noted in the inferotemporal part. (b, c) Optical Coherence Tomography (OCT) from the macula shows schisis areas separating outer nuclear and outer plexiform layers. (d) Wide-field fluorescein angiography in the late phase shows the lack of leakage confirming no cystoid macular edema associated with diabetic retinopathy.

Considering the rare nature of ONP maculopathy, various modalities have been reported with different success rates. However, the best management protocol is still a controversial issue. In a recent systematic review, investigating the best treatment modality in patients with ONP maculopathy, the authors reported a positive publication bias toward the PPV [8].

Herein, we report a case of the ONP maculopathy treated successfully with Juxtapapillary Laser Photocoagulation (JLP). The successful standalone use of JLP has been previously but not very frequently reported.



**Figure 2.** Optical coherence tomography before juxtapapillary laser photocoagulation (a, b, c) and after 6 months (d, e, and f)

The corresponding slabs have been chosen to demonstrate the exact changes. Laser scars at the level of retinal pigment epithelium-choroid (e and f).

## Case Presentation

A 55-year-old woman was referred to our retina clinic for evaluation of an abnormal finding detected in her first ophthalmic check-up examination for Diabetes Mellitus (DM). She noted DM for 5 years, which was under control with oral agents. Systemic hypertension was also present for 5 years. No other systemic or ocular history was noted.

Using a Snellen chart, the Corrected Distance Visual Acuity (CDVA) was 20/40 in the right eye refracted with -0.75 - 1.00×130 and 20/30 refracted with -0.5 - 0.5×65 in the left eye. The pupil's reactions to light were normal in both eyes. The relative afferent pupillary defect was not present. Slit-lamp biomicroscopy revealed no pathologic findings in both eyes. In the funduscopy, an excavation was observed in the inferotemporal Optic Nerve Head (ONH). Subretinal fluid and intraretinal fluid extending from the ONH to the posterior pole dominantly distributed in the inferior part was also evident. A sclerotic cilioretinal artery was also observed (Figure 1A).

The fluorescein angiography revealed the areas of blockage and retinal pigment epithelial alterations compatible with chronic SRF, most dominantly along the inferior arcade and lack of late pooling in the cystic spaces of macula compatible with schisis (Figure 1B, C, and E). Optical coherence tomography confirmed the presence of optic pit maculopathy (Figure 1B). No microaneurysm or area of capillary non-perfusion was observed in the Fluorescein Angiography (FA). The patient underwent JLP for one session. The argon laser was used and the laser parameter setting involved the argon laser with exposure duration of 100 ms, size of 100 microns, and power of 70 mW.

The patient has been followed for 2 years. The CDVA reached 20/30 after 6 months. Anatomical improvement has also been achieved (Figure 2). Both anatomical and functional improvements remained stable during the follow-up and macular edema or diabetic retinopathy have not been progressed.

## Discussion

Untreated ONP maculopathy could result in irreversible visual loss secondary to cystoid changes and Retinal Pigment Epithelial (RPE) alterations [2, 9, 10]. Macular involvement necessitates treatment to prevent visual impairment [3]. Our patient was successfully treated with the use of JLP instead of PPV. Although the reported success rates widely vary between different studies,

JLP can be considered as the first treatment modality in patients with ONP maculopathy.

The origin of the fluid and the underlying mechanism of maculopathy is still unclear. The presence of mucopolysaccharide that primarily belongs to the vitreous, and transition of silicone oil or gas in the subretinal space after PPV, can support the vitreous cavity as the origin of the fluid [11-14].

Another plausible mechanism is the accumulation of fluid in intraretinal or subretinal spaces through direct communication between subarachnoid and subretinal spaces. While this hypothesis is supported by the migration of air-bubble into the subarachnoid space and also in the OCT images, various studies failed to reveal a direct communication [15-21]. Choroid and retinal vessels have also been postulated as the potential source of the fluid [2, 22]. However, these hypotheses are not strongly supported by experimental evidence and have not been observed in other retinal pathologies.

Regardless of the origin of the fluid, different modalities have been tried in the management of ONP maculopathy, such as PPV, injection of gas tamponade, JLP, macular buckling surgery, and internal limiting membrane peeling. Recently, more novel approaches have also been successful, including the use of fibrin or autologous blood sealants over the pit, ocriplasmin, radial optic neurotomy, or inner retinal fenestration [23-28]. The rare nature of the disease and the unknown origin of the fluid are among the factors leading to uncertainty about the best treatment choice. However, it seems reasonable to start with less an invasive treatment, like laser photocoagulation. The laser scar, which is applied in the temporal part of the optic disc could serve as a barrier to the fluid entrance into the macula [2, 9, 29].

A recent systematic review, investigating the surgical treatment of ONP maculopathy reported no effects for concurrent use of tamponade. The interesting point of this systematic review was the detection of publication bias toward the positive results. It means that PPV studies with extremely positive results are published more than PPV with negative results [8]. Therefore, we postulate that the higher success rates of PPV could be attributed to this bias in the literature.

In conclusion, we reported a patient with ONP maculopathy that was successfully treated with JLP. Regarding the various treatment modalities, JLP seems a reasonable initial treatment.

## Ethical Considerations

### Compliance with ethical guidelines

There were no ethical considerations to be considered in this research.

### Funding

This research did not receive any grant from funding agencies in the public, commercial, or non-profit sectors.

### Conflict of interest

The authors declared no conflict of interest.

## References

- [1] Greear Jr JN. Pits, or crater-like holes, in the optic disk. *Archives of Ophthalmology*. 1942; 28(3):467-83. [DOI:10.1001/archophth.1942.00880090099006]
- [2] Gass JDM. Serous detachment of the macula: Secondary to congenital pit of the optic nervehead. *American Journal of Ophthalmology*. 1969; 67(6):821-41. [DOI:10.1016/0002-9394(69)90075-0] [PMID]
- [3] Sobol WM, Blodi CF, Folk JC, Weingeist TA. Long-term visual outcome in patients with optic nerve pit and serous retinal detachment of the macula. *Ophthalmology*. 1990; 97(11):1539-42. [DOI:10.1016/S0161-6420(90)32380-1] [PMID]
- [4] Wiethe T. Ein fall von angeborener deformität der sehnervpapille. *Arch Augenheilkd*. 1882; 11:14-9. <https://ci.nii.ac.jp/naid/10011032491/>
- [5] Lincoff H, Yannuzzi L, Singerman L, Kreissig I, Fisher Y. Improvement in visual function after displacement of the retinal elevations emanating from optic pits. *Archives of Ophthalmology*. 1993; 111(8):1071-9. [DOI:10.1001/archophth.1993.01090080067020] [PMID]
- [6] Akiyama H, Shimoda Y, Fukuchi M, Kashima T, Mayuzumi H, Shinohara Y, et al. Intravitreal gas injection without vitrectomy for macular detachment associated with an optic disk pit. *Retina*. 2014; 34(2):222-7. [DOI:10.1097/IAE.0b013e3182993d93] [PMID]
- [7] Lei L, Li T, Ding X, Ma W, Zhu X, Atik A, et al. Gas tamponade combined with laser photocoagulation therapy for congenital optic disc pit maculopathy. *Eye*. 2015; 29(1):106-14. [DOI:10.1038/eye.2014.245] [PMID] [PMCID]
- [8] Zheng A, Singh RP, Lavine JA. Surgical options and outcomes in the treatment of optic pit maculopathy: a meta-analysis and systematic review. *Ophthalmology Retina*. 2020; 4(3):289-99. [DOI:10.1016/j.oret.2019.10.011] [PMID]
- [9] Theodosiadis G. Evolution of congenital pit of the optic disk with macular detachment in photocoagulated and nonphotocoagulated eyes. *American Journal of Ophthalmology*. 1977; 84(5):620-31. [DOI:10.1016/0002-9394(77)90375-0] [PMID]
- [10] Theodosiadis GP, Theodosiadis PG, Ladas ID, Zafirakis PK, Kolia AC, Koutsandrea C, et al. Cyst formation in optic disc pit maculopathy. *Documenta Ophthalmologica*. 1999; 97(3-4):329-35. [DOI:10.1023/A:1002194324791] [PMID]
- [11] Ferry AP. Macular detachment associated with congenital pit of the optic nerve head: Pathologic findings in two cases simulating malignant melanoma of the choroid. *Archives of Ophthalmology*. 1963; 70(3):346-57. [DOI:10.1001/archophth.1963.00960050348014] [PMID]
- [12] Dithmar S, Schuett F, Voelcker HE, Holz FG. Delayed sequential occurrence of perfluorodecalin and silicone oil in the subretinal space following retinal detachment surgery in the presence of an optic disc pit. *Archives of Ophthalmology*. 2004; 122(3):409-11. [DOI:10.1001/archophth.122.3.409] [PMID]
- [13] Salam A, Khan-Lim D, Luff AJ. Superior retinal detachment in an oil-filled eye with a colobomatous optic disc. *Retinal Cases and Brief Reports*. 2008; 2(2):124-5. [DOI:10.1097/ICB.0b013e3180338f0f] [PMID]
- [14] Coll GE, Chang S, Flynn TE, Brown GC. Communication between the subretinal space and the vitreous cavity in the morning glory syndrome. *Graefe's Archive for Clinical and Experimental Ophthalmology*. 1995; 233(7):441-3. [DOI:10.1007/BF00180949] [PMID]
- [15] Krivoy D, Gentile R, Liebmann JM, Stegman Z, Rosen R, Walsh JB, et al. Imaging congenital optic disc pits and associated maculopathy using optical coherence tomography. *Archives of Ophthalmology*. 1996; 114(2):165-70. [DOI:10.1001/archophth.1996.01100130159008] [PMID]
- [16] Rutledge BK, Puliafito CA, Duker JS, Hee MR, Cox MS. Optical coherence tomography of macular lesions associated with optic nerve head pits. *Ophthalmology*. 1996; 103(7):1047-53. [DOI:10.1016/S0161-6420(96)30568-X] [PMID]
- [17] Ohno-Matsui K, Hiraoka A, Inoue M, Akiba M, Ishibashi T. Evaluation of congenital optic disc pits and optic disc colobomas by swept-source optical coherence tomography. *Investigative Ophthalmology & Visual Science*. 2013; 54(12):7769-78. [DOI:10.1167/iovs.13-12901] [PMID]
- [18] Irvine AR, Crawford JB, Sullivan JH. The pathogenesis of retinal detachment with morning glory disc and optic pit. *Transactions of the American Ophthalmological Society*. 1986; 84:280-92. [PMID] [PMCID]
- [19] Kuhn F, Kover F, Szabo I, Mester V. Intracranial migration of silicone oil from an eye with optic pit. *Graefe's Archive for Clinical and Experimental Ophthalmology*. 2006; 244(10):1360-2. [DOI:10.1007/s00417-006-0267-9] [PMID]
- [20] Chang S, Haik BG, Ellsworth RM, Louis LS, Berrocal JA. Treatment of total retinal detachment in morning glory syndrome. *American Journal of Ophthalmology*. 1984; 97(5):596-600. [DOI:10.1016/0002-9394(84)90379-9] [PMID]
- [21] Kalina RE, Conrad WC. Intrathecal fluorescein for serous macular detachment. *Archives of Ophthalmology*. 1976; 94(8):1421. [DOI:10.1001/archophth.1976.03910040289024] [PMID]
- [22] Wise GN, Dollery CT, Henkind P. *The retinal circulation*. New York: Harper & Row; 1971. <https://www.worldcat.org/title/retinal-circulation/oclc/603898905>
- [23] de Oliveira PRC, Berger AR, Chow DR. Use of evelcil fibrin sealant in optic disc pit-associated macular detachment. *Ophthalmic Surgery, Lasers & Imaging Retina*. 2017; 48(4):358-63. [DOI:10.3928/23258160-20170329-13] [PMID]
- [24] Nadal J, Figueroa MS, Carreras E, Pujol P, Canut MI, Barraquer RI. Autologous platelet concentrate in surgery for macular detachment

- associated with congenital optic disc pit. *Clinical Ophthalmology*. 2015; 9:1965-71. [DOI:10.2147/OPTH.S81976] [PMID] [PMCID]
- [25] Bottoni F, Cereda M, Secondi R, Bochicchio S, Staurenghi G. Vitrectomy for optic disc pit maculopathy: A long-term follow-up study. *Graefes' Archive for Clinical and Experimental Ophthalmology*. 2018; 256(4):675-82. [DOI:10.1007/s00417-018-3925-9] [PMID]
- [26] Karacorlu M, Muslubas IS, Hocaoglu M, Ozdemir H, Arf S, Uysal O. Long-term outcomes of radial optic neurotomy for management of optic disk pit maculopathy. *Retina*. 2016; 36(12):2419-27. [DOI:10.1097/IAE.0000000000001101] [PMID]
- [27] Ooto S, Mitra RA, Ridley ME, Spaide RF. Vitrectomy with inner retinal fenestration for optic disc pit maculopathy. *Ophthalmology*. 2014; 121(9):1727-33. [DOI:10.1016/j.ophtha.2014.04.006] [PMID]
- [28] Theodossiadis GP, Theodossiadis PG. The macular buckling technique in the treatment of optic disk pit maculopathy. *Seminars in Ophthalmology*. 2000; 15(2):108-15. [DOI:10.3109/08820530009040001] [PMID]
- [29] Brockhurst RJ. Optic pits and posterior retinal detachment. *Transactions of the American Ophthalmological Society*. 1975; 73:264-91. [PMID] [PMCID]