



## Case Report

Journal Homepage: <http://crp.tums.ac.ir>

# A Patient With the Leiomyoma of the Cecum: A Case Report



Najmeh Aletaha<sup>1</sup>, Marziyeh Ghalamkari<sup>2\*</sup>, Masoud Sotoudeh<sup>3</sup>, Forough Alborzi<sup>1</sup>, Naser Ebrahimi Daryani<sup>1</sup>

1. Department of Gastroenterology, Tehran University of Medical Sciences, Tehran, Iran.

2. Department of Hematology and Oncology, School of Paramedicine, Tehran University of Medical Sciences, Tehran, Iran.

3. Department of Pathology, Tehran University of Medical Sciences, Tehran, Iran.

Use your device to scan and read the article online



**Citation:** Aletaha N, Ghalamkari M, Sotoudeh M, Alborzi F, Ebrahimi Daryani N. A Patient With the Leiomyoma of the Cecum: A Case Report Case Reports in Clinical Practice .2020; 5(2):35-38.

**Running Title:** A Patient With the Leiomyoma of the Cecum



## Article info:

**Received:** 26 March 2020

**Revised:** 18 April 2020

**Accepted:** 06 May 2020

## Keywords:

Leiomyoma; Cecum;  
Endoscopic resection

## ABSTRACT

Stromal or mesenchymal neoplasms affecting the gastrointestinal tract are relatively rare lesions. A far less common group of Gastrointestinal (GI) mesenchymal tumors is leiomyoma. Surgery is the mainstay treatment for leiomyoma. Complete endoscopic resection of the tumor could be challenging due to its submucosal origin. In this study, we reported a case of a 48-year-old woman with leiomyoma of the cecum, i.e. treated by endoscopic resection.

## Introduction:

Stromal or mesenchymal neoplasms affecting the gastrointestinal tract are relatively rare lesions, i.e. assumed to constitute only 1% of primary Gastrointestinal (GI) cancers [1, 2]. However, the exact incidence of GI stromal and mesenchymal tumors is underestimated due to the lack of exact definition and diagnosis [3].

A far less common group of GI mesenchymal tumors is leiomyoma, which arises from the soft tissue (muscularis mucosa or the muscularis propria) along the entire length of the gut. They are most often located in the esophagus & stomach. Colonic leiomyoma accounts for only 3% of all GI leiomyoma [4, 5].

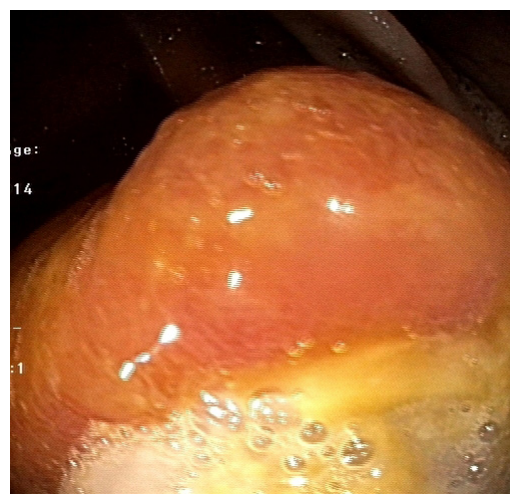
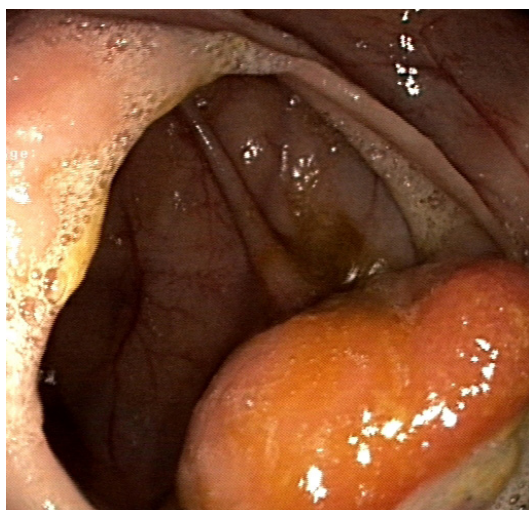
Surgery is the mainstay treatment for leiomyoma. Complete endoscopic resection of the tumor could be

\* Corresponding Author:

**Marziyeh Ghalamkari, PhD.**

**Address:** Department of Hematology and Oncology, School of Paramedicine, Tehran University of Medical Sciences, Tehran, Iran.

**E-mail:** [dr.ghalam@yahoo.com](mailto:dr.ghalam@yahoo.com)



**Figure 1.** Polypoid lesion in the cecum

challenging due to its submucosal origin [1, 4]. The present study reported a case of a 48-year-old woman with leiomyoma of the cecum.

### Case Report

A 48-year-old woman was referred to the treatment center due to vague abdominal pain and constipation in the past 4 months. She reported no complain of any other symptoms, such as nausea, vomiting, weight loss, and fever. Her past medical history was negative. Physical examination demonstrated no abnormality. Laboratory test results were normal except for mild iron deficiency anemia (Hb:11mg/dL, ferritin:17.8ng/mL). Abdominal ultrasonography was normal.

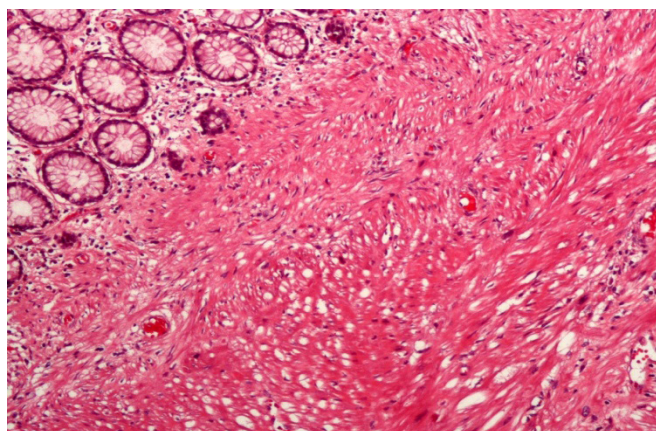
Due to abdominal discomfort and chronic constipation, gastroduodenal endoscopy, and colonoscopy were per-

formed. Upper endoscopy data revealed mild chronic superficial gastritis. Colonoscopy results suggested a large polyp of about 4 cm in diameter in the cecum (Figure 1 A, B).

Biopsies were obtained from the lesion, indicating hyperplastic polyp. Abdominal Computed Tomography (CT) scan also demonstrated a polypoid lesion at the cecum. Tumor markers (carcinoembryonic antigen & cancer antigen 19-9) were negative.

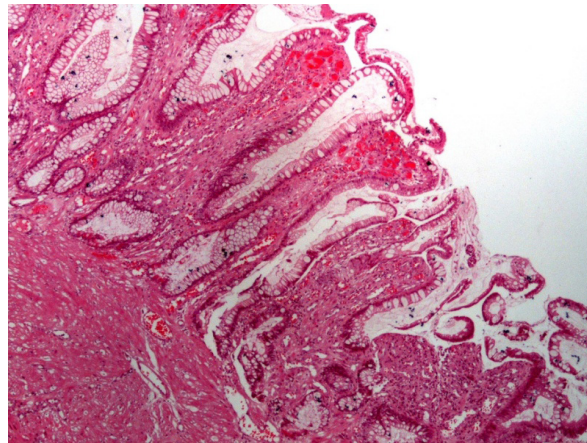
Because of the large size of the lesion and its position in the cecum, the perforation risk of endoscopic procedure was highly probable, and she was a candidate for right hemicolectomy, accordingly.

After hospitalization in our center, another colonoscopy was performed. There were a large, smooth-surface and semi-pedunculated lesion, i.e. about 4 cm at



**Figure 2.** Normal looking colonic mucosa covers the submucosal relatively low cellular spindle cell lesion

\*The Spindle cells are arranged in interlacing fascicles. Tumor cell nuclei are bland-looking. HE Original magnification (X150).



**Figure 3.** Distortions of mucosal glands with variations in size, contour, and distribution



\*These changes are in favor of the reparative/reactive response of colonic mucosa to injury. H&E Original magnification (X60).

the cecum. The lesion was successfully removed with an electro-surgical snare after typical saline submucosal injection. Prophylactic endoclips were used in the base of resection. The patient was discharged one day after the procedure without complication.

Pathologic examination indicated spindle neoplasm without significant atypia or mitosis (Figure 2). Immunohistochemistry stained sections suggested a positive reaction of tumor cells for desmin and Smooth Muscle Actin (SMA) and adverse reaction for pan CK, CD117, CD34, DOG1, and S100. Less than 2% of tumor cell nuclei demonstrated a positive response for Ki67.

There are different pathological reports of biopsies specimen and excisional mass lesions. Accordingly, the specimens reviewed by another GI pathologist failed to meet the criteria for sessile serrated polyp and were inflammatory; reparative reaction to the nearby mucosal ulcer occurred over the submucosal leiomyoma (Figure 3).

The patient recovered well and had no residual tumor in a follow-up colonoscopy conducted after 4 months.

## Discussion

Leiomyomas are benign smooth muscle tumors, i.e. rarely observed in the colon [1]. They could occur in every part of the colon; however, they are more commonly detected in the sigmoid portion [5]. The reported patient's leiomyoma was in the cecum, i.e., unusual.

Leiomyomas are more frequent in men and may be detected incidentally. However, our case was a middle-aged woman whose chief complaint was abdominal pain and constipation. Donali et al. reported 37 pa-

tients with colonic myomatous tumors. Most of them (22 patients) were female; abdominal pain was among their main complaints. Intestinal symptoms, like constipation and diarrhea, were also common reasons for referring to gastroenterologists. Other symptoms, like rectal bleeding and obstructive episodes, such as intussusception and weight loss, had also been reported [5]. Our reported case reported no hematochezia, weight loss, or any colic pain.

The duration of symptoms is also variable, which could be from 10 days to 10 years [5]. However, most patients experience a few months of this condition, as it was about 4 months in the reported patient.

Due to bleeding, anemia is prevalent in leiomyoma. The hemoglobin concentration of our reported case was 11.2 mg/dL with iron deficiency criteria.

The tumor size varies significantly from a few mm to >20 cm with an average size of 6 cm [3, 5]; it was 4 cm in the studied patient.

Our patient demonstrated typical pathologic features of a leiomyoma with spindle muscle cells. Immunohistochemistry studies have broadly aimed for the differentiation of GI mesenchymal tumors [6, 7]; in those cases, it was positive for the desemin and SMA characteristics of leiomyoma.

The first-line treatment for colonic leiomyoma is complete surgical resection. However, endoscopic and laparoscopic equipment have been developed to use a minimal invasive procedure for tumor removal [8]. Complete endoscopic removal in colonic leiomyoma would be problematic due to submucosal origin, which

has a higher risk of perforation and bleeding in large masses [9, 10]. Endoclips could be used in minor perforations [11]. Due to the large tumor size of our patient, prophylactic endoclips was used during endoscopic removal. The procedure was completed without any complications.

## Conclusion

Leiomyoma is among the differential diagnosis of colonic masses. The endoscopic removal of leiomyoma polyps is a useful approach for the treatment of colonic tumors.

## Ethical Considerations

### Compliance with ethical guidelines

All ethical principles were considered in this article.

### Funding

This research did not receive any specific grant from funding agencies in the public, commercial, or non-profit sectors.

### Conflict of interest

The authors declared no conflict of interest.

## References

- [1] Casali PG, Jost L, Reichardt P, Schlemmer M, Blay JY, ESMO Guidelines Working Group. Gastrointestinal stromal tumours: ESMO clinical recommendations for diagnosis, treatment and follow-up. *Annals of Oncology*. 2009; 20(Suppl 4):64-7. [DOI:10.1093/annonc/mdp131] [PMID]
- [2] Sorour M, Kassem M, Ghazal A, EL-Riwini M, Abu Nasr A. Gastrointestinal stromal tumors related emergencies. 2014; 12(4):269-80. [DOI:10.1016/j.jjsu.2014.02.004]
- [3] Gupta P, Tewari M, Shukla HS. Gastrointestinal stromal tumor. *Surgical Oncology*. 2008; 17(2):129-38. [DOI:10.1016/j.suonc.2007.12.002] [PMID]
- [4] Baker HL Jr, Good CA. Smoothmuscle tumors of the alimentary tract; their roentgen manifestations. *The American Journal of Roentgenology, Radium Therapy, and Nuclear Medicine*. 1955; 74(2):246-55. [PMID]
- [5] MacKenzie DA, McDonald JR, Waugh JM. Leiomyoma and leiomyosarcoma of the colon. *Annals of Surgery*. 1954; 139(1):67-75. [DOI:10.1097/0000658-195401000-00008] [PMID] [PMCID]
- [6] Choi AH, Hamner JB, Merchant SJ, Trisal V, Chow W, Garberoglio CA, et al. Underreporting of gastrointestinal stromal tumors: Is the true incidence being captured? *Journal of Gastrointestinal Surgery*. 2015; 19(9):1699-703. [DOI:10.1007/s11605-015-2860-x] [PMID]
- [7] Ogun GO. Mesenchymal tumours of the gastrointestinal tract: The importance and use of immunohistochemistry in characterizing specific tumour entities. *Nigerian Journal of Medicine*. 2015; 24(2):150-4. [PMID].
- [8] Acker S, Dishop M, Kobak G, Vue P, Somme S. Laparoscopic-assisted endoscopic resection of a gastric leiomyoma. *European Journal of Pediatric Surgery Reports*. 2014; 2(1):003-6. [DOI:10.1055/s-0034-1370773] [PMID] [PMCID]
- [9] Sato H, Mizuno Y, Tsukamoto T, Ichikawa T, Kotani Y, Honda K, et al. Endoscopic removal of pedunculated leiomyoma of the sigmoid colon. *Viszeralmedizin*. 2014; 30(6):427-9. [DOI:10.1159/000368791] [PMID] [PMCID]
- [10] Kadakia SC, Kadakia AS, Seargent K. Endoscopic removal of colonic leiomyoma. *Journal of Clinical Gastroenterology*. 1992; 15(1):59-62. [DOI:10.1097/00004836-199207000-00014] [PMID]
- [11] Velchuru VR, Zawadzki M, Levin AL, Bouchard CM, Marecik S, Prasad LM, et al. Endoclip closure of a large colonic perforation following colonoscopic leiomyoma excision. *Journal of the Society of Laparoendoscopic Surgeons*. 2013; 17(1):152-5. [DOI:10.4293/108680812X13517013317554] [PMID] [PMCID]