

Presentation Invasive Mole After Normal Pregnancy: A Very Rare Case Report



Afsaneh Tehranian¹, Akram Ghahghaei-Nezamabadi^{1*}, Marzieh Vahid dastjerdi¹, Sophia Esalatmanesh¹, Akram Seifollahi²

1. Department of Obstetrics and Gynecology, Arash Women's Hospital, Tehran University of Medical Sciences, Tehran, Iran

2. Department of Pathology, Arash Women's Hospital, Tehran University of Medical Sciences, Tehran, Iran

Use your device to scan and read the article online



Citation Tehranian A, Ghahghaei-Nezamabadi A, Vahid dastjerdi M, Esalatmanesh S, Seifollahi A. Presentation Invasive Mole After Normal Pregnancy: A Very Rare Case Report. Case Reports in Clinical Practice. 2023; 8(4): 155-158.

Running Title Invasive Mole After Normal Pregnancy



Article info:

Received: July 4, 2023

Revised: July 24, 2023

Accepted: August 25, 2023

Keywords:

Gestational trophoblastic neoplasia; Invasive mole; Normal pregnancy

ABSTRACT

Gestational trophoblastic neoplasia (GTN) is a rare neoplasm and is a spectrum of proliferative disorders of placenta. Invasive mole is a subtype of GTN that almost always arises after molar pregnancy. This report presents a 35-year-old woman with an atypical presentation of invasive mole after a normal pregnancy. The patient presented with a complaint of vaginal bleeding after normal vaginal delivery. Invasive mole was diagnosed based on findings of imaging and elevated beta human chorionic gonadotropin (β -hCG) levels. Hysterectomy was finally decided upon due to severe vaginal bleeding and the patient's request. Although GTN occurs after normal delivery, the patient recovered without receiving chemotherapy. It is important to consider all subtypes of GTN as a differential diagnosis of patients with abnormal postpartum bleeding and elevated β -hCG levels even after a normal pregnancy.

Introduction

Gestational trophoblastic neoplasia (GTN) is defined as a group of malignant neoplasms that result from abnormal proliferation of trophoblastic tissue. It is divided into choriocarcinoma, invasive mole, placental site trophoblastic tumor (PSTT), and epithelioid trophoblastic tumor (ETT). GTN can occur after molar or non-molar pregnancy [1]. The incidence of GTN varies from 1 per

500-1000 pregnancies in Europe, North, and South America, to 1 per 120 pregnancies in Asian women [2].

Invasive mole is a disease where edematous villi and proliferative trophoblasts invade the myometrium. It usually occurs after a molar pregnancy [3]. GTN typically occurs during reproductive age and is usually cured with chemotherapy. Hysterectomy is considered for patients who do not plan for future fertility [4]. Patients with uncontrollable vaginal or

* Corresponding Author:

Akram Ghahghaei-Nezamabadi

Address: Department of Obstetrics and Gynecology, Arash Women's Hospital, Tehran University of Medical Sciences, Tehran, Iran

E-mail: agna57@yahoo.com

intra-abdominal bleeding, placental site trophoblastic tumors, and chemotherapy-resistant tumors are eligible for surgery [5]. The presentation of GTN after a normal pregnancy is usually with choriocarcinoma, which is very aggressive. However, a rare case of invasive mole following a normal pregnancy is presented here.

Case presentation

A 35-year-old G2L2 female was referred to Arash Hospital (affiliated with Tehran University of Medical Sciences, Tehran, Iran) due to vaginal bleeding. She had a normal vaginal delivery without any complications 5 months prior. She breastfed her baby regularly, and her contraception method was withdrawal. Her physical examination was normal. Serum β -hCG was 1200 mIU/ml, hemoglobin was 9, and other laboratory tests were normal. Transvaginal ultrasound (TVS) ruled out any pregnancy and revealed arteriovenous malformation (AVM) or invasive mole of the uterus (Fig.1). Metastatic work-up revealed no metastasis. A complete abdominal and pelvic computed tomography (CT) scan showed an image of a dilated vein on the left side of the uterus body, confirming the ultrasonography view. Other abdominal organs were normal. The diagnosis of the invasive mole was established according to findings of TVS and her history of previous pregnancy with elevated β -hCG levels. A multidisciplinary consultation was performed, and informed consent was obtained. The patient declined to receive any type of chemotherapeutic agent. Finally, a total abdominal hysterectomy was performed at the patient's request. Microscopic examination revealed an invasive mole (Fig. 2). On the second day of surgery, β -hCG was

reduced to 200 mIU/ml, and she was discharged. Serial β -hCG levels were checked weekly until they became undetectable. After two years of patient follow-up, no recurrence was observed.

Discussion

GTN is an uncommon complication of pregnancy. Clinical manifestations of GTN after non-molar pregnancy include postpartum abnormal vaginal bleeding, bleeding from metastatic sites such as the lung, liver, and spleen, pulmonary symptoms, and neurological signs of brain metastasis [6]. Only 50% of GTN occurs after a molar pregnancy, and the rest of the cases follow after a spontaneous abortion, ectopic pregnancy, or a term pregnancy [7]. The risk of GTN after molar pregnancy is higher than other forms of pregnancy. If GTN occurs after a normal pregnancy, the subtype is usually choriocarcinoma. Invasive moles almost always arise after molar pregnancy. The presentation of an invasive mole after a normal pregnancy is a very rare phenomenon. In patients with a known molar pregnancy, serum β -hCG levels are checked in regular periods until the β -hCG becomes normal [8]. Therefore, malignant GTN is diagnosed earlier following molar pregnancy than patients with a prior normal pregnancy, and a higher mortality rate is seen in patients with GTN following non-molar pregnancy [5, 9].

The patient presented with postpartum vaginal bleeding and elevated β -hCG levels. GTN should be treated with single-agent methotrexate or actinomycin D chemotherapy in patients with non-metastatic (stage I) and low-risk metastatic (stages II and III, score <7) [7, 8].

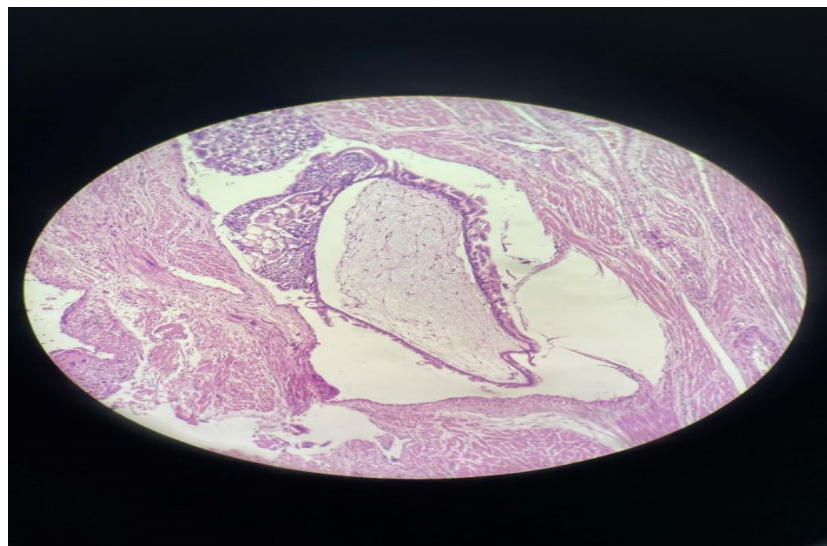


Fig. 1. Microscopic findings showed a hydropic villous with trophoblastic hyperplasia invading myometrium (400 \times magnification).

Presentation of invasive mole after normal pregnancy: a very rare case report

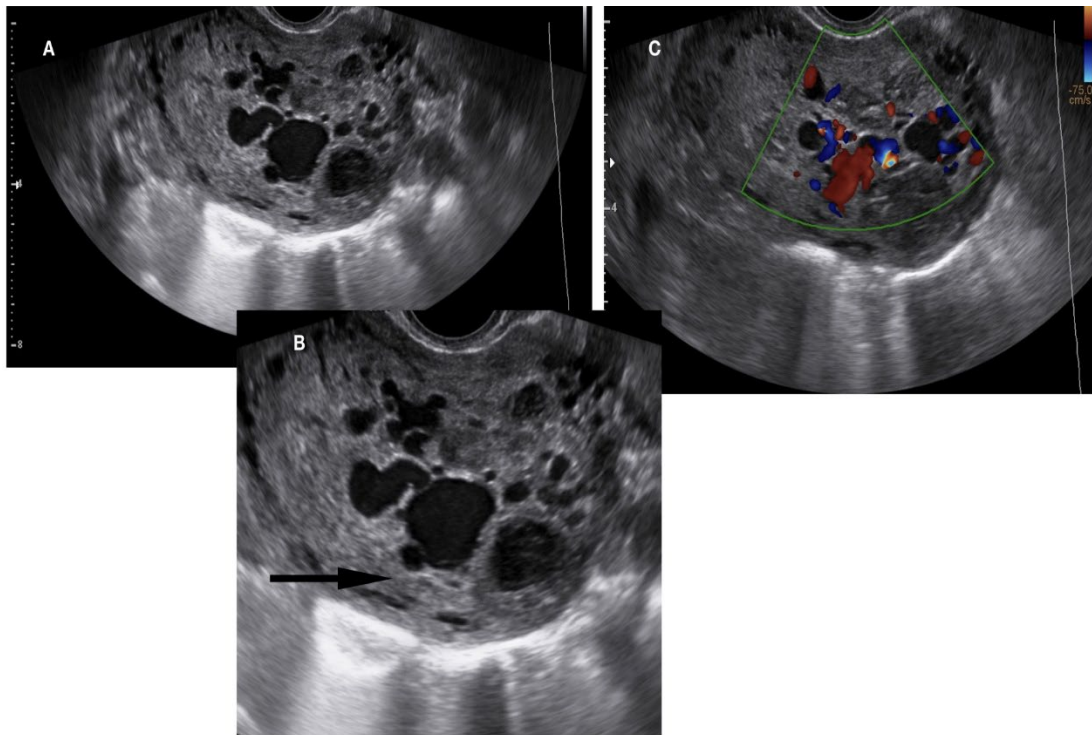


Fig. 2. A complete abdominal and pelvic computed tomography (CT) scan showed an image of a dilated vein on the left side of uterus body, ultrasonography view.

Serum β -hCG levels should be checked weekly for follow-up of these patients. GTN is followed up based on the stage of the disease. This measurement will be continued to detect normal values for three consecutive weeks, and then monthly for 12 months [8].

Patients with ultra-high-risk disease are at increased risk for late recurrence of the disease, and monthly follow-up is increased to 24 months [10].

Persistent or irregular bleeding for more than 8 weeks following pregnancy should be evaluated using an β -hCG test to exclude a new pregnancy or gestational trophoblastic disease [11].

Indications for surgery in patients with GTN include women who have no desire for future fertility, a chemotherapy-resistant lesion, hemoperitoneum, or coexistence of other uterine diseases [10, 12].

Hysterectomy can play a key role in patients who have no planning for future fertility [4]. In a study that was performed in 1959-2009 at the New England Trophoblastic Disease Center, 84.7% of patients with hysterectomy for GTN achieved remission. Also, 75.8% of chemotherapy-resistant patients who underwent

hysterectomy to treat the disease achieved complete remission [13].

In patients with non-metastatic GTN, the total dose of chemotherapy needed to achieve primary remission decreases by early hysterectomy [14].

Hysterectomy does not prevent metastasis, and patients must be followed up with serial β -hCG tests after hysterectomy [8]. Patients with GTN usually are curable if managed optimally. Although invasive moles arise after molar pregnancy in most cases, it must be considered when GTN occurs, and an appropriate therapeutic plan must be implemented.

Conclusions

Invasive mole is the most common form of gestational trophoblastic neoplasia and almost always occurs after a molar pregnancy. The occurrence of an invasive mole after a normal pregnancy is very rare. In postpartum patients with significant vaginal bleeding and persistent levels of β -HCG, GTN can present with an invasive mole, not choriocarcinoma. Therefore, the implementation of an appropriate treatment plan should be considered depending on each case.

Ethical Considerations

Compliance with ethical guidelines

All ethical principles were considered in this article. Written informed consent was obtained from the patient for publication of this case report and any accompanying images.

Funding

There was no funding for this study.

Conflict of Interests

The authors declare that they have no conflict of interest.

Acknowledgements

The authors would like to express their gratitude to the Clinical Research Development Center of Arash Women's Hospital, Tehran University of Medical Sciences, Tehran, Iran for their support, cooperation, and assistance throughout the duration of the study.

References

- [1] Nishino K, Yamamoto E, Oda Y, Watanabe E, Niimi K, Yamamoto T, et al. Short tandem repeat analysis to identify the causative pregnancy of high-risk gestational trophoblastic neoplasia: Molar versus nonmolar pregnancy and its relation to the outcome. *Placenta*. 2021;112:28-35. <https://doi.org/10.1016/j.placenta.2021.06.015>
- [2] Borella F, Cosma S, Ferraioli D, Preti M, Gallio N, Valabrega G, et al. From Uterus to Brain: An Update on Epidemiology, Clinical Features, and Treatment of Brain Metastases From Gestational Trophoblastic Neoplasia. *Front Oncol*. 2022;12:859071. <https://doi.org/10.3389/fonc.2022.859071>
- [3] Aminimoghaddam S, Maghsoudnia A. Unusual Presentation of Invasive Mole: A Case Report. *J Reprod Infertil*. 2017;18(1):205-09.
- [4] Ngu SF, Ngan HYS. Surgery including fertility-sparing treatment of GTD. *Best Pract Res Clin Obstet Gynaecol*. 2021;74:97-108. <https://doi.org/10.1016/j.bpobgyn.2020.10.005>
- [5] Thomakos N, Rodolakis A, Belitsos P, Zagouri F, Chatziniolaou I, Dimopoulos A-M, et al. Gestational trophoblastic neoplasia with retroperitoneal metastases: A fatal complication. *World Journal of Surgical Oncology*. 2010;8(1):114. <https://doi.org/10.1186/1477-7819-8-114>
- [6] Lurain JR. Gestational trophoblastic disease I: epidemiology, pathology, clinical presentation and diagnosis of gestational trophoblastic disease, and management of hydatidiform mole. *American journal of obstetrics and gynecology*. 2010;203(6):531-39. <https://doi.org/10.1016/j.ajog.2010.06.073>
- [7] Ngan HYS, Seckl MJ, Berkowitz RS, Xiang Y, Golfier F, Sekharan PK, et al. Diagnosis and management of gestational trophoblastic disease: 2021 update. *Int J Gynaecol Obstet*. 2021;155 Suppl 1:86-93. <https://doi.org/10.1002/ijgo.13877>
- [8] Berek JS. *Berek & Novak's gynecology*. 16th ed. Philadelphia: Wolters Kluwer; 2020.
- [9] Raguraman S, Muhunthan K, Kabilesan P. Case Report: Rare presentation of invasive mole following term pregnancy after assisted reproduction. *Obstet Gynecol Cases Rev*. 2021;8(5):210. <https://doi.org/10.23937/2377-9004/1410210>
- [10] Horowitz NS, Eskander RN, Adelman MR, Burke W. Epidemiology, diagnosis, and treatment of gestational trophoblastic disease: A Society of Gynecologic Oncology evidenced-based review and recommendation. *Gynecologic oncology*. 2021;163(3):605-13. <https://doi.org/10.1016/j.ygyno.2021.10.003>
- [11] Tidy J, Seckl M, Hancock B. on behalf of the Royal College of Obstetricians and Gynaecologists. Management of Gestational Trophoblastic Disease. *BJOG*. 2021;128(3):e1-e27. <https://doi.org/10.1111/1471-0528.16266>
- [12] Hanna RK, Soper JT. The role of surgery and radiation therapy in the management of gestational trophoblastic disease. *Oncologist*. 2010;15(6):593-600. <https://doi.org/10.1634/theoncologist.2010-0065>
- [13] Clark RM, Nevadunsky NS, Ghosh S, Goldstein DP, Berkowitz RS. The evolving role of hysterectomy in gestational trophoblastic neoplasia at the New England Trophoblastic Disease Center. *J Reprod Med*. 2010;55(5-6):194-8.
- [14] Suzuka K, Matsui H, Iitsuka Y, Yamazawa K, Seki K, Sekiya S. Adjuvant hysterectomy in low-risk gestational trophoblastic disease. *Obstet Gynecol*. 2001;97(3):431-4. [https://doi.org/10.1016/s0029-7844\(00\)01169-8](https://doi.org/10.1016/s0029-7844(00)01169-8)