



Case Report

Journal Homepage: <http://crp.tums.ac.ir>

Pulmonary Artery Aneurysm Dilemma in Pregnancy: A Case Report



Shadi Zamansaraei¹, Milad Nazari Sabet², Parvin Bahrami³

1. Department of Gynecology Surgery, Isfahan University of medical Sciences, Isfahan, Iran.
2. Resident of General Surgery, School of Medicine, Isfahan University of Medical Sciences, Isfahan, Iran.
3. Department of Cardiology, Alzahra University Hospital, Isfahan University of Medical Science, Isfahan, Iran.



Citation Zamansaraei Sh, Nazari Sabet M, Bahrami P. Pulmonary Artery Aneurysm Dilemma in Pregnancy: A Case Report. Case Reports in Clinical Practice. 2023; 8(1):5-8.

Running Title Pregnancy and Pulmonary Artery Aneurysm



Article info:

Received: 06 Jan 2023

Revised: 03 Feb 2023

Accepted: 21 Feb 2023

Keywords:

Pulmonary artery;
Aneurysm; Pregnancy

ABSTRACT

Pulmonary Artery Aneurysm (PAA), defined as greater than 40 mm dilation of the main pulmonary artery wall, in female and above 43 mm in males is a rare and fatal defect. Since there is a high risk for rupture, especially in cases of symptomatic or severe dilatation, surgical intervention is suggested. There is no recommendation about therapeutic methods based on the diameter of the pulmonary aneurysm in pregnancy in the guidelines.

In this rare and unique report, we described a 26-year-old pregnant woman with previous history of biologic pulmonary valve replacement referred to the joint clinic of heart disease and pregnancy at 15 weeks of pregnancy because transthoracic echocardiography showed an aneurysm of the main pulmonary artery (55mm). Due to pulmonary artery diameter and risk of dissection, we informed her about the risks and recommended therapeutic abortion, but she refused and, fortunately no complication occurred during close observation in pregnancy and few months later.

There is no specific recommendation about therapeutic methods based on the diameter of the pulmonary aneurysm in pregnancy in the guidelines, but referring to the aortic aneurysm guidelines recommendation, pregnancy termination when PA diameter > 5.5 cm because of the higher risk of dissection. Other factors should be considered to determine the risk of dissection in pregnancy include; categorized PA aneurysms to high or low intravascular PA pressure, PA diameter growth rate, and causative mechanisms. Thus, if pregnancy occurs, decisions about each patient will vary depending on risk factors.

*** Corresponding Author:**

Parvin Bahrami, MD.

Address: Department of Cardiology, Alzahra University Hospital, Isfahan University of Medical Science, Isfahan, Iran.

E-mail: Parvinbahrami194194@gmail.com



Introduction

Pulmonary Artery Aneurysm (PAA) is defined as greater than 40 mm dilation of the main pulmonary artery and is a rare and fatal defect with incidence of 1 in 14000 individuals(1). PA aneurysms were categorized in high and low intravascular PA pressure. High-pressure PA aneurysms etiologies are: 1) congenital heart disease associated Pulmonary Hypertension (PHT), 2) presences of idiopathic PHT in PA aneurysm, and 3) other causes of remaining high PA pressure. A variety of causal factors for PA aneurysms have been proposed. Pulmonary hypertension (PHT) is one of the major causes (2). Others believe that existence of arteriovenous communications is a key factor in development of PA aneurysms (3).

Etiologies include post stenotic dilatation and structural abnormalities of the PA wall caused by hereditary factors or viral illness. Pulmonary hypertension (PHT) is described as an important cause. The low-pressure PA aneurysms were also divided into 3 groups:1) idiopathic and post stenotic dilatation, 2) tissue abnormality related to PA dilatation, and 3) PA dilatation caused by high flow through the pulmonary artery (4).

Large PA aneurysm may be complicated with valve regurgitation and rupture of an aneurysm (5, 6), especially in cases of symptomatic or large aneurysms. Thus, in cases of dilatation > 60 mm, or in symptomatic cases, surgical intervention is suggested (7). In the developed world, cardiac illness is the main cause of maternal death. Majority of mothers with heart problems can carry their babies to term. However, when it comes to women who have aneurysm susceptibility, pregnancy carries substantial risk, and these women should be advised against getting pregnant if there is no other alternative for risk reduction (8). Despite an increase in number of women with congenital heart defects considering pregnancy, maternal mortality is minimal due to combined skilled specialized cardiac and obstetric treatments (9). As a result, people who care for pregnant women must be aware of risk factors for cardiac problems and how they manifest during pregnancy. In this study, we present a case of a pulmonary artery aneurysm dilemma in pregnancy.

Case Presentation

A 26-year-old pregnant woman, G1, 15th week of Pregnancy was referred to the joint clinic of heart diseases in pregnancy. TTE showed an aneurysm of the main pulmonary artery (53-55mm). She was asymptomatic; but upon following the aneurysm size, the patient was referred for consultation to end or continue her pregnancy and do follow-ups. In history, 9 months before, due to symptoms, physical examination and echocardiography findings, severe PI with a large aneurysm of the main pulmonary artery and right and left PA was diagnosed. CTA and CMR showed aneurysmal dilated proximal and distal part of main PA with diameter of 50 mm, severe PI, and other findings were normal (Figure1).

According to her appearance and Ghent nosology score, Marfan syndrome and other connective tissue abnormalities were less probable. Imaging did not show intracardiac shunt and pulmonary hypertension. Her past medical history was not compatible with infectious causes, thus, idiopathic dilation of the pulmonary artery or PA dilation caused by high flow through the pulmonary artery due to severe PI was the final causative diagnosis. The surgeon decided to replace the pulmonary valve without surgical treatment for the aneurysm. Biologic valve replacement was performed. Subsequently, the patient had no clinical symptoms and no abnormality on the physical examination. She had vital signs as follows; BP: 110/ 65 mmHg, HR: 105 bpm, RR: 19 times /minute, T: 36.8 °C. Sonography from the fetus was done with normal findings.

TTE showed an aneurysm of the main pulmonary artery (53-55mm), biologic Pulmonary Valve with normal motion, and acceptable hemodynamic study; (PVMG: 13mmhg, PPG: 20mmhg), and mild paravalvular leakage; RA & RV size was normal with mild RV systolic dysfunction. Systolic PAP was 20 mmHg and LV size was normal with acceptable systolic and diastolic function (LVEF= 55%) [FIGURE- 2, video1].

Due to absolute PA diameter and also PA diameter growth rate in comparison of current echocardiography with previous study before PVR (PA diameter growth rate >2mm/year?) we considered possible risk of dissection in pregnancy, and we informed her about risks. She refused therapeutic abortion and decided to continue the pregnancy with close observation in the expert center.

For 21 weeks, close follow-up was conducted every 3 weeks for symptoms and surveillance echocardiography for monitoring PA diameters and changes in PAP. Fetal echocardiography was performed at 19 weeks and revealed no pathology. There was no symptom, no changes in PA diameters during pregnancy, but at 36 weeks, recurrent chest pain episodes occurred so cesarean section under general anesthesia was done. The neonate was a healthy boy weighing 2700 grams with normal Apgar score. CT scan was performed 3 months after termination following pleuritic chest pain, the result showed a similar size to MRI and CTA before her valve replacement surgery. Pericarditis was proposed as a possible diagnosis based on ECG and echo study.

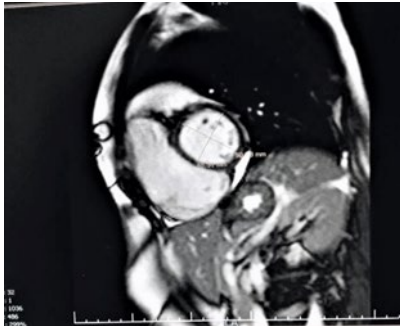

Figure 1. CMR view dimensions of main PA and right and left pulmonary artery, before PVR

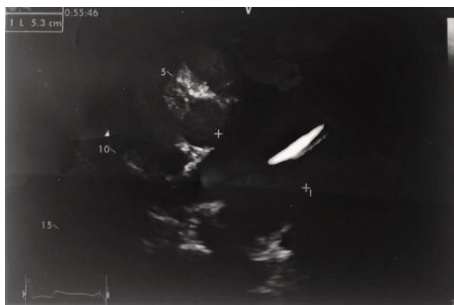
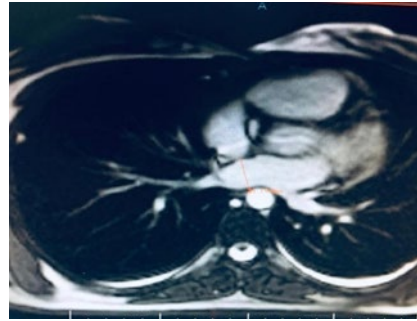
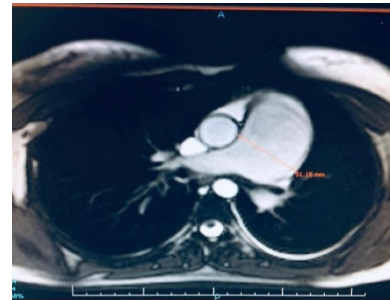

Figure 2. Echocardiography of Short Axis View of Pulmonary Artery with its noticing diameter (53mm).



Discussion

In this large worldwide registry of pregnant women with underlying cardiac disease, we present a case with pulmonary artery aneurysm dilemma in pregnancy. The majority of women with heart disease who become pregnant have positive maternal and fetal results. Maternal mortality during pregnancy in women with cardiac disease is uncommon, except for individuals with Eisenmenger syndrome, pulmonary vascular obstructive disease, and Marfan syndrome with aortopathy (10, 11). Other problems, such as heart failure, arrhythmia, and stroke remain a danger for pregnant women with heart disease. In the assessment of PAA dissection risk, attention to causative mechanisms and categorization of PA aneurysm to high and low intravascular pressure (as described before) is helpful for treatment strategies during pregnancy. PA dissection is more probable in high-pressure (>50 mmHg) PA aneurysms (81% of patients with dissection have PAH (12, 13).

Idiopathic PAA diagnosis can be made by considering four pathologic criteria: (I) simple dilatation of the pulmonary trunk, (II) absence of intracardiac or extracardiac shunts, (III) absence of chronic cardiac or pulmonary disease, and (IV) absence of arterial diseases (14). According to Laplace's law, the tension within the

wall of PA is proportional to the radius and pressure and inversely proportional to the wall thickness. So,

dilation and weakening of the PA wall due to aneurysm formation particularly in presence of PAH cause increased wall stress and can lead to rupture. In patients with a PA diameter >55 mm and PHT, incidence of sudden unexpected death was reported to be higher (15, 16). In non-pregnant patients with idiopathic PAAs without significant PAH, treatment can be either conservative (medical) or surgical. Surgical repair is recommended if aneurysms are >6 cm but a hinge point size and growth rate for surgical intervention is still undefined due to limited experience. or if they are symptomatic (17).

However, there is no unique guideline or consensus for PAA in pregnancy (unlike Aortic aneurysm) and it is more challenging due to hemodynamic and hormonal changes during pregnancy due to the substantial stress on great arteries in the process of labor (18). On the other hand, because of the lower pressure in the right heart cavities (according to Laplace's law), possibility of dissection in pulmonary artery aneurysms may be less than Aortic aneurysms (19). In this case, low-pressure idiopathic PA aneurysm, with diameter 53-55 mm and PA diameter growth rate (>2mm/year), we informed the patient about the risks and needs to closely follow-up or do therapeutic abortion but she refused an abortion and decided to continue the pregnancy with follow-up despite the potential risks. We present this case because of the rarity of PAA and guidelines do not explicitly address to this issue.

Conclusion

The first challenge for PAA in pregnancy involves determining appropriate treatment, risk assessment, and identification of the causative mechanism (20). Other important factors include level of PA pressure (>50 mmHg), absolute PA diameter and growth rate (>55mm and growth rate >2 mm/year) are important which probably implies a vulnerable PA wall with a consequently higher risk of dissection.

Ethical Considerations

Compliance with ethical guidelines

In this study, all ethical issues have been considered

Funding

This research did not receive any grant from funding agencies in the public, commercial, or non-profit sectors.

Conflict of interest

The authors declared no conflict of interest.

References

- [1] Hameed AB. Vascular Dissections and Aneurysms During Pregnancy. *Cardiac Problems in Pregnancy*. 2019;275-84.
- [2] Badagliacca R, Poscia R, Pezzuto B, Papa S, Nona A, Mancone M, et al. Pulmonary arterial dilatation in pulmonary hypertension: prevalence and prognostic relevance. *Cardiology*. 2012;121(2):76-82.
- [3] Fakler U, Mebus S, Kaemmerer H, Will A, Eicken A, Weiss M, et al. A ticking time bomb—high pressure pulmonary artery aneurysm. *The American journal of medicine*. 2008;121(9):777-80
- [4] Duijnhouwer AL, Navarese EP, Van Dijk AP, Loeys B, Roos-Hesselink JW, De Boer MJ. Aneurysm of the pulmonary artery, a systematic review and critical analysis of current literature. *Congenital heart disease*. 2016;11(2):102-9.
- [5] Kreibich M, Siepe M, Kroll J, Höhn R, Grohmann J, Beyersdorf F. Aneurysms of the pulmonary artery. *Circulation*. 2015;131(3):310-6
- [6] Gruber PJ, Askin FB, Heitmiller RF. Pulmonary artery aneurysm in a pregnant woman. *The Annals of thoracic surgery*. 2001;71(3):1023-5
- [7] Theodoropoulos P, Ziganshin BA, Tranquilli M, Elefteriades JA. Pulmonary artery aneurysms: four case reports and literature review. *International Journal of Angiology*. 2013;22(03):143-8.
- [8] Ruys TP, Roos-Hesselink JW, Hall R, Subirana-Domènech MT, Grando-Ting J, Estensen M, et al. Heart failure in pregnant women with cardiac disease: data from the ROPAC. *Heart*. 2014;100(3):231-8.
- [9] Thompson JL, Kuklina EV, Bateman BT, Callaghan WM, James AH, Grotegut CA. Medical and obstetric outcomes among pregnant women with congenital heart disease. *Obstetrics and gynecology*. 2015;126(2):346.
- [10] Chavez P, Wolfe D, Bortnick AE. Management of Ischemic Heart Disease in Pregnancy. *Current Atherosclerosis Reports*. 2021;23(9):1-9.
- [11] Foeller ME, Foeller TM, Druzin M. Maternal congenital heart disease in pregnancy. *Obstetrics and Gynecology Clinics*. 2018;45(2):267-80.
- [12] Regitz-Zagrosek V, Roos-Hesselink JW, Bauersachs J, Blomström-Lundqvist C, Cifkova R, De Bonis M, et al. 2018 ESC guidelines for the management of cardiovascular diseases during pregnancy: the task force for the management of cardiovascular diseases during pregnancy of the European Society of Cardiology (ESC). *European heart journal*. 2018;39(34):3165-241.
- [13] Park HS, Chamarthy MR, Lamus D, Saboo SS, Sutphin PD, Kalva SP. Pulmonary artery aneurysms: diagnosis & endovascular therapy. *Cardiovascular diagnosis and therapy*. 2018;8(3):350.
- [14] Nucho J, Cabezas J-MM, López-Guarch CJ, Martín MV, Charterina SA, Ostolaza YR, et al. Frequency, predictors, and prognostic impact of pulmonary artery aneurysms in patients with pulmonary arterial hypertension. *The American journal of cardiology*. 2019;123(3):474-81.
- [15] Kalra-Lall A, Donaldson J, Martin C. Brief review: pulmonary artery aneurysms and pseudoaneurysms. *The international journal of cardiovascular imaging*. 2019;35(7):1357-64.
- [16] Worku BM, de Angelis P, Wingo ME, Leonard JR, Khan FM, Hameed I, et al. Pulmonary artery aneurysms: Preoperative, intraoperative, and postoperative findings. *Journal of Cardiac Surgery: Including Mechanical and Biological Support for the Heart and Lungs*. 2019;34(7):570-6.
- [17] Emmanuel Y, Thorne S. Heart disease in pregnancy. Best practice & research Clinical obstetrics & gynaecology. 2015;29(5):579-97
- [18] Plowman RS, Javidan-Nejad C, Raptis CA, Katz DS, Mellnick VM, Bhalla S, et al. Imaging of pregnancy-related vascular complications. *Radiographics*. 2017;37(4):1270-89.
- [19] Silversides CK, Grewal J, Mason J, Sermer M, Kiess M, Rychel V, et al. Pregnancy outcomes in women with heart disease: the CARPREG II study. *Journal of the American College of Cardiology*. 2018;71(21):2419-30.
- [20] Oficjalska-Młyńczak J, Turno-Krecicka A, Muzyka-Woźniak M, Teklak D. [Vitreotomy in the treatment of endogenous fungal endophthalmitis in a patient after renal transplantation]. *Klinika oczna*. 2003;105(5):303-6