



## Case Report

<http://wjpn.ssu.ac.ir>**Intracardiac Thrombosis in A Neonate: A Case Report**Seyed Reza Mirjalili<sup>1,2</sup>, Morteza Danaeian<sup>1</sup>, Fatemeh Baghalsafa<sup>2\*</sup><sup>1</sup> Department of Pediatrics, Shahid Sadoughi University of Medical Sciences, Yazd, Iran<sup>2</sup> Mother and Newborn Health Research Center, Shahid Sadoughi University of Medical Sciences, Yazd, Iran

Received: 4 October 2021

Revised: 16 October 2021

Accepted: 1 November 2021

**ARTICLE INFO****Corresponding author:**

Fatemeh Baghalsafa

**Email:**

fatemeh.safa\_67@yahoo.com

**Keywords:**

Thrombosis;

Neonate;

Recombinant tissue plasminogen;

Rivaroxaban

**ABSTRACT**

**Background:** Life-threatening intracardiac thrombosis is rare. Intracardiac thrombosis may affect neonates from the first months of life. Because of the potential risk of serious bleeding, the use of recombinant plasminogen activator (rt-PA) in neonates along with heparin is controversial.

**Case Report:** We reported a 37- day- old term infant presented with fever, restlessness, malaise, and respiratory acidosis. Right atrial thrombosis was identified by ECHO, results of laboratory tests, and examination. She was successfully treated with rt-PA and rivaroxaban.

**Conclusion:** Early echocardiographic detection before the clot grows large and organized, allows complete, safe, and rapid thrombolysis with rt-PA and rivaroxaban.

**Introduction**

Neonates, particularly those who are critically ill, have a significantly increased risk of developing thrombotic events. This increased risk can be explained by the presence of risk factors unique to this period of time that can promote thrombosis (sepsis, inflammation, hypotension, hypoxia, and the use of intravascular catheters in small-caliber vessels) as well as the developmental hemostatic difference in neonate discussed earlier.<sup>1</sup> Acquired and inherited prothrombotic conditions including factor V Leiden and

prothrombin gene mutation; deficiencies of protein C, Protein S, and anti-thrombin, elevated factor V III, lipoprotein (a) and homocysteine and anti-phospholipid antibodies are known risk factors for thrombosis.<sup>2</sup>

The patient we reported was a 37- day old female neonate with intracardiac thrombosis treated with rt-PA and rivaroxaban.

**Case Report**

The patient was a 37- day- old girl first referred to Level II hospital due to fever and restlessness and was admitted to Neonatal

Intensive Care Unit (NICU) with malaise and respiratory acidosis. She was dehydrated and venous blood gas (VBG) measurements were taken. The results were as follows: pH = 6.99, pCO<sub>2</sub> = 24 mmHg and HCO<sub>3</sub> = 5.6 mEq/L. She had received bicarbonate and normal saline in bolus form in two doses and was sent to Shahid Sadoughi Hospital. Laboratory data of the patient on admission are shown in table 1.

**Table 1.** Laboratory Data of the Patient on Admission

Measure	Results (on Admission)
CBC	
WBC	41,600
Neut	67%
Lymph	15%
Hb, g/dL	13.7
Plt, 10 <sup>3</sup> μL <sup>-1</sup>	398
CRP	3+
BUN, mg/dL	87
Cr, mg/dL	1.6
Na, mEq/L	132
K, mEq/L	4.2
Ca, mg/dL	9.4
Mg, mg / L	2.4
VBG	
pH	7.10
pCO <sub>2</sub> , mmHg	22
HCO <sub>3</sub> , mEq/L	6.6
B.E	-11.6

The patient’s Apgar score at 5 minutes after birth was 6/10. She was born at 37 weeks of gestation. She had lost 300 grams of her birth weight of 2450 grams and was 2150 grams at the time of admission. The patient had a 16-day history of hospitalization due to respiratory distress and acrocyanosis at the NICU and ventilatory support for 5 days during the hospitalization period. She was in good general condition and discharged after reaching the full feed and did not have any problems during her stay at home. She had poor feeding started four days before the second hospitalization. She had fever, restlessness, and decreased frequency of urination while did not have convulsion and vomiting. In clinical examination, the patient had sunken eye, crying without tears, anterior fontanel with normal size, and depressed and

long capillary refill time > 4 seconds. She also had respiratory distress with tachypnea and subcostal retraction. The patient had been diagnosed with tachycardia and her blood pressure was not detectable. Holosystolic murmur III/IV in left sternal border (LSB) with the subclavian release was audible through cardiac auscultation. She did not have organomegaly but had hypotonia and her Moro reflex was weak. The patient underwent antibiotic therapy with cefotaxime and vancomycin and fluid therapy continued. Because of hearing the murmur on cardiac examination, echocardiography (ECHO) was carried out on the second day of hospitalization.

She did not have a central venous line (CV line).

Results of the ECHO were as below:

The large mass in the right atrium (RA) into the IVC 15 × 8 mm (Figure 1)

EF = 60%

PFO

No PDA

Acceptable LV and RV systolic function

Due to the presence of a mass and the uncertainty of the nature of the atrial mass, the patient underwent broad-spectrum antibiotic treatment with meropenem, vancomycin, and amphotericin B. Since atrial myxoma was in the differential diagnosis of RA Lary mass, cardiac surgery consultation was performed and It was recommended to continue the treatment of endocarditis and if the size of the mass remains constant, surgery is necessary. Blood cultures were performed in three stages at intervals of twelve hours, which were negative. The patient's condition improved after hydration and antibiotic therapy and milk was started on the fourth day. ECHO test on the fourth day showed that the mass size was reduced to 13 × 5 mm. During this time, repeated attempts were made to send coagulation tests, that each taken sample was clotted. So, according to hematology and cardiology consultation, heparin infusion was started at 28 unit/kg/hr and ECHO f/u was performed every 48 hours. Results of the coagulation

tests indicated that INR = 1, PT = 12 and PTT = 29, which reached the target level during heparin therapy (INR = 1, PT = 12 and PTT = 90). Heparin therapy continued with a prophylactic dose of 10 unit/kg/hr after 5 days. As samples taken seven days after heparin therapy with a prophylactic dose were clotted again and the atrial mass size was unchanged, therapeutic doses of heparin were started. Twenty-four hours later, therapy with reteplase at a dosage of 0.5 mg/kg was initiated due to ECHO, results of laboratory tests, history of sepsis, dehydration, determined nature of the mass, no change in clot size and the possibility of pulmonary embolism. At a single dose prior to treatment, the patient underwent a brain ultrasound that did not include IVH and intracranial hemorrhage. Twenty-four hours after reteplase treatment, heparin was discontinued and the patient was treated with rivaroxaban at a dose of 1 mg/kg/day. Repeat ECHO after 48 h of treatment revealed resolving clot from 15 × 8 mm to 5 × 2 mm (Figure 2).

Due to the nature of the mass and the fact that the mass was thrombotic, other organs were examined during the hospitalization period. In eye examination using an ophthalmoscope, retinal veins thrombosis was not seen. Results of the patient's brain MRI were as follows: high signal intensity on T2 sequence in left transverse and sigmoid sinus was present and brain MRV for R/O of brain venous thrombosis was recommended. The MRV result was entirely normal and demonstrated no filling defect of thrombosis. On Doppler renal ultrasound, the patient did not have renal artery thrombosis.

Additional tests performed for the patient include:

- D dimer = 1341 ng/mL
- Antithrombin III = 61%
- Protein C = 55%
- Protein S = 31%
- Anti phospholipide IgG = 6.7
- Anti phospholipide IgM = 2.7
- Homocysteine = 9.7 μmol/L
- Factor V Leiden = 164

Which Protein C, Protein S, and Antithrombin III were lower than normal.

The patient with the good general condition was discharged after 18 days with oral treatment with rivaroxaban. On F / U echocardiography performed two weeks after discharge:

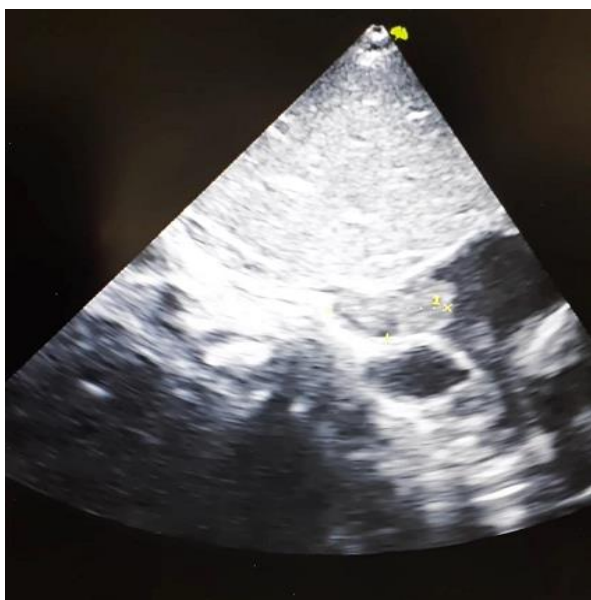
No IVC engorgement and no evidence of thrombosis in IVC were demonstrated and rivaroxaban was discontinued.

To diagnose the underlying cause of thrombosis, we recommended a repeat of Anti-thrombin III, Protein C, and Protein S in the next three months.

### Discussion

Data on Intracardiac thrombosis in the neonate is limited to case reports. The absence of cardiac symptoms is unexpected and depends on the size and duration of the thrombosis.<sup>3</sup> maternal history of gestational diabetes mellitus, *Staphylococcus epidermidis* infection, and central venous catheter (CVC) placement in the superior vena cava (SVC) are risk factors for intracardiac thrombosis. It may also occur due to certain conditions such as prematurity, asphyxia, dehydration, congenital heart disease, etc.<sup>4</sup> Factor V Leiden, prothrombin gene mutation, deficiencies of protein C, protein S, and anti-thrombin, elevated levels of factor VIII, lipoprotein (a), homocysteine and anti-phospholipid antibodies are the other risk factors known for thrombosis.<sup>1</sup> Arrhythmia, respiratory distress, the sudden manifestation of murmur, and signs of right-sided heart failure are the most frequent symptoms in the case of right atrial thrombosis.<sup>5</sup> Complete, safe, and rapid thrombolysis with rt-PA depends on early echocardiographic detection, before the clot grows large and organized.<sup>3</sup> Neonatal thrombotic events are often occurred in low birth weight neonates. Symptomatic thrombosis can result in threatening situations like renal failure, heart failure, and lung embolism.<sup>6</sup> Reports on fatal or life-threatening thrombi are relatively rare. The optimal therapeutic options for infants with

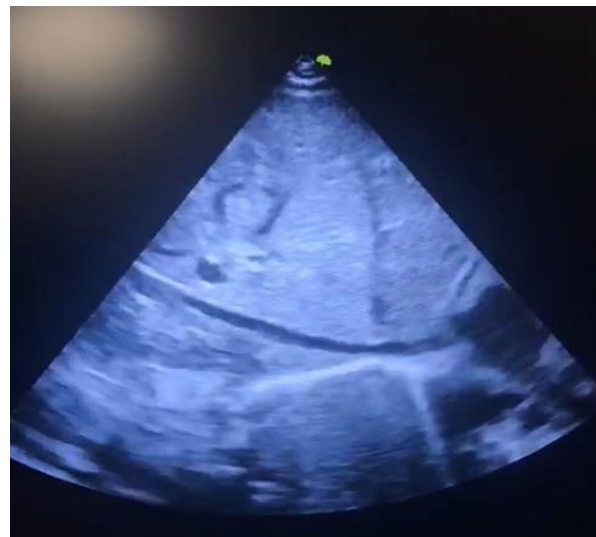
intracardiac thrombosis are not known. Information on management is limited to small case series and case reports.<sup>7</sup> Moreover, spontaneous regression of intracardiac thrombus has been previously reported.<sup>5,8</sup> In the case of asymptomatic thrombosis, some experts believe that it should be treated.<sup>9</sup> The case we reported was admitted due to poor feeding, dehydration, and hypotension which are risk factors for thrombosis.<sup>4</sup> She had a heart murmur on examination, which is a diagnostic sign of right atrial thrombosis.<sup>5</sup> on echocardiography a large mass (15 × 8 mm) in the right atrium was detected (Figure 1).



**Figure 1.** Large Mass in Right Atrium (RA) into the IVC (Size: 15 × 8 mm)

As it was life-threatening, antithrombotic therapy was started.<sup>5</sup> In some studies, the use of rt-PA and enoxaparin has been shown to be effective in dissolving clots<sup>5</sup> and it was effective in our case as well reducing the clot size to 5 × 2 mm (Figure 2). Due to the effectiveness of rivaroxaban in the treatment of thrombosis according to clinical trials<sup>10</sup>, the patient was discharged with a good general condition while oral treatment with rivaroxaban was prescribed. As protein c deficiency was observed during the laboratory tests and antithrombin III was lower than normal, which could be a hereditary factor

involved in thrombosis<sup>1</sup>, it was decided to perform the tests again in the next three months to definitively diagnose the hereditary background of thrombosis.



**Figure 2.** Resolved clot (size: 5 × 2 mm)

### Conclusion

Intracardiac thrombosis in neonates is rare. Early echocardiographic detection is recommended before the clot grows large. Treatment options for acute life-threatening thrombi include antithrombotic therapy. Rt-PA and heparin LMWH (enoxaparin) with rivaroxaban for the treatment of intracardiac thrombi in neonates has also been successful.<sup>11</sup> The increasing use of anticoagulants because of the medical advances in neonates at risk of venous thromboembolism has been improving long term survival.<sup>12</sup>

### Conflict of Interests

Authors have no conflict of interests.

### Acknowledgments

The authors would like to thank the patient's family for their cooperation in this study.

**How to Cite:** Mirjalili SR, Danaeian M, Baghalsafa F. Intracardiac Thrombosis in A Neonate: A Case Report. *World J Peri & Neonatol* 2021; 4(1): 65-9.  
DOI: 10.18502/wjpn.v4i1.7547

## References

1. Revel-Vilk S. The conundrum of neonatal coagulopathy. *Hematology Am Soc Hematol Educ Program* 2012; 2012: 450-4.
2. Martin RJ, Fanaroff AA, Walsh MC. Fanaroff and Martin's neonatal-perinatal medicine: diseases of the fetus and infant. Current therapy in neonatal-perinatal medicine. Philadelphia, PA: Saunders; 2015.
3. Ferrari F, Vagnarelli F, Gargano G, Roversi MF, Biagioni O, Ranzi A, et al. Early intracardiac thrombosis in preterm infants and thrombolysis with recombinant tissue type plasminogen activator. *Arch Dis Child - Fetal Neonatal Ed* 2001; 85(1): F66-9.
4. Ulloa-Ricardez A, Romero-Espinoza L, de Estrada-Loza M, González-Cabello HJ, Núñez-Enríquez JC. Risk factors for intracardiac thrombosis in the right atrium and superior vena cava in critically ill Neonates who required the installation of a central venous catheter. *Pediatr Neonatol* 2016; 57(4): 288-94.
5. Van Overmeire B, Van Reempts PJ, van Acker KJ. Intracardiac thrombus formation with rapidly progressive heart failure in the neonate: Treatment with tissue type plasminogen activator. *Arch Dis Child* 1992; 67(4 SPEC NO): 443-5.
6. Van Elteren HA, Veldt HS, Te Pas AB, Roest AAW, Smiers FJ, Kollen WJ, et al. Management and Outcome in 32 Neonates with thrombotic events. *Int J Pediatr* 2011; 2011: 217564.
7. Bendaly EA, Batra AS, Ebenroth ES, Hurwitz RA. Outcome of Cardiac Thrombi in Infants. *Pediatr Cardiol* 2007; 29(1): 95-101.
8. de Godoy JMP, de Marchi CH, Fonseca Silva MG, Carvalho MCM, Moscardini A, Tonet T. Thrombus in the left ventricle of a newborn. *J Pediatr* 2002; 141(1): 141.
9. Jones S, Monagle P, Newall F. Do asymptomatic clots in children matter? *Thromb Res* 2020; 189: 24-34.
10. Rivaroxaban for treatment in venous or arterial thrombosis in neonates. [Online]. [cited 2015 Oct 01]. Available from: URL: <https://clinicaltrials.gov/ct2/show/NCT02564718>
11. Demirel G, Erdeve O, Oguz SS, Celik IH, Dilmel U. Evaluation and treatment of intracardiac thrombus in ten neonates. *Eur J Pediatr* 2011; 170: 1223.
12. Attard C, Monagle P, Kubitzka D, Ignjatovic V. The in-vitro anticoagulant effect of rivaroxaban in neonates. *Blood Coagul Fibrinolysis* 2014; 25(3): 237-40.