

Serious Suicide Attempt by Hunting Gun with Severely Infectious Wounds and Facial Deformity during COVID-19 Arena; A Case Report

Reza Bidaki ^{a,b} , Maryam Sadeh ^{c*} 

^a Research Center of Addiction and Behavioral Sciences, ShahidSadoughi University of Medical Sciences, Yazd, Iran.

^b Diabetes Research Center, Shahid SadoughiUniversity of Medical Sciences, Yazd, Iran

^c Department of Laboratory Sciences, School of Paramedicine, Shahid Sadoughi University of Medical Sciences, Yazd, Iran.

ARTICLE INFO

ABSTRACT

CASE REPORT

Article History:

Received: 10 Jul 2021

Revised: 25 Sep 2021

Accepted: 9Nov 2021

*Corresponding Author:

Maryam Sadeh

Email:

sadeh_m20@yahoo.com

Tel: +98 9132527679

Citation:

Bidaki R, Sadeh M. Serious Suicide Attempt by Hunting Gun with Severely Infectious Wounds and Facial Deformity during COVID-19 Arena; A Case Report. Journal of Social Behavior and Community Health (JSBCH). 2021; 5(2): 672-677.

The etiology of suicide among students around the world revolves issues such as communication, education, family problems and parents' relationship. We intend to report a case with serious recurrent suicide attempt by gun shot during COVID-19 period. We also present psychiatric and clinical evaluation, cosmetic surgery consultation, as well as microbial assessments in this survey.

The seventeen-year-old single male student from southwest of Iran with asymmetric deformed face was observed with the loss of parts of the nose, nose, chin and mandible region .He had experienced a serious suicide attempt by a threatening plan following rejection. The patient had blurred, hypo phonic and hypotonic speech. Following the shooting, the soft and hard palate, facial, frontal bone and sinus had been destroyed and a foreign body was seen in the frontal sinus. After suicide risk as assessment, It was detected multiple predictive risk factors for recent suicide attempt and the possibility of recurrent suicide in future. Finally, reconstructive surgery was performed. We assessed him via face to face interview in order to identify psychiatric disorders. Also, he was evaluated as probability of committing recurrent suicide.

It is emphasized that in families which young children are prone to psychiatric disorders or emotional problems, availability of a dangerous device such as a gun can be harmful and it should be removed as soon as possible. We suggest the need for psychiatric evaluation especially suicide phenomenon in adolescents and their families as various conflicts in family context.

Keywords: Behavior, COVID-19, Infection control, Psychiatry, Suicide,



Introduction

Suicide is one of the major problems of human societies today, which is sometimes done in totally violent and deadly ways thus being worth of pondering. The etiology of suicide among students around the world pertains to issues such as communication, education, family problems and parents relationship (Arafat, 2019). Social distance is a method for COVID-19 epidemic control, but it may enforce negative consequences on mental health and resilience in human (Gunnell et al., 2020). Complete suicide is more common in males than females, but females attempt this more (Kaggwa et al., 2021; Mamun et al., 2020). Some studies attribute this to women's communication skills with their mothers as role models for managing stressful situations. Additionally, females are also associated with religious social groups that condemn suicide (Mamun et al., 2020; Mugisha et al., 2013). In a population-based cohort study on subjects 18-64 aged using primary care electronic health records in UK, self-harm incidence was 37.6% (34.8-40.3%) lower than expected in April, 2020, and deceleration was greatest for female sex and individuals aged younger than 45 years (Carr et al., 2021). Individuals younger than 20 years were considered and a number of suicide cases rose sharply in the late teens with 79 deaths out of 145 cases of suicide attempts in those aged 18-19 years. Totally, 102 (70%) deaths occurred in male sex, and 92 (63%) through hanging plan. Academic (especially exam) problems (35 [27%] individuals), bullying (28 [22%]), grief (36 [28%]), suicide attempt in family or peers (17 [13%]), somatic conditions (47 [36%]), family tensions (44 [34%]), child abuse or neglect (20 [15%]), excessive drinking (34 [26%]), and illicit drug use (38 [29%]). Suicide associated internet use was also reported in 30 (23%) cases (Rodway et al., 2016).

In a regional study, the findings showed that firearm prevalence is positively associated with firearm suicide rates in conditions like religious adherence, long-term jobless cases, the population

with a significant psychiatric disorder, divorce rate, and in rural areas (Kposowa, 2013).

In this paper, we intend to highlight the importance of psychiatric evaluation about prevention and relapse of new onset suicide behavior in a rural adolescent with previous history of serious suicide and significant deformity in head and neck.

Case Report

This is a case study for which we collected data via face to face interview registered by pen and paper in a private place. Seventeen-year-old single male patient who was right-handed, slender, and a student from a rural, low-socio-economic region in the southwest of Iran, was referred to a psychiatrist by plastic cosmetic surgery for evaluation of psychiatric disorder, suicide probability and confirmation of facial cosmetic surgery.

This survey is presented and accepted in ethical committee of Health university, Shahid Sadoughi University of Medical Sciences. Its ethical code number is IR.SSU.SPH.REC.1400.149

Psychiatric evaluation

The patient was interviewed by a psychiatrist for the assessment of disorders like major depressive disorder, bipolar disorder, psychotic disorder, adjustment disorder, conduct disorder, adult attention deficit hyperactivity disorder, personality disorder, substance related disorder, suicide thoughts, anxiety disorders on the basis of DSM 5 criteria.

Clinical examination

For this case study, some data were collected via patient's evaluation. An asymmetric deformed face was observed with the loss of parts of the nose, upper jaw and mouth. The patient's voice was blurred, hypo phonic and hypovolemic. The patient's mood was euthymic without psychotic features. Following an emotional breakdown as love failure at past month, the patient took twenty tablet Clonazepam 1 mg., and after a while, about a month later, he took his father's hunting weapon and placed it vertically under his chin and shot

impulsively to commit suicide. The patient's action was completely serious and threatening as a high risk behavior. He had no familial history of suicide and substance abuse. Following the shooting, the soft and hard palate, facial, frontal bone, zygomatic bone and maxillary sinus were destroyed and a foreign body was seen in his frontal sinus. Finally, reconstructive cosmetic surgery was performed (Fig 1). The final trigger was attributed to some emotional issues on a girl from his close relatives. There was especial tattoo of two swallows on the dorsum area of the patient's left hand (Fig 2) symbolizing a boy and a girl who love each other. Following the facial injury, the patient developed a serious infection. The patient's wound was sampled by sterile cotton swab and transferred to Brain Heart Infusion (Merck, Germany) and sent to a microbiology laboratory. The BHI tube was incubated at 37 ° C for 24 hours. It was then cultured on Mac Conkey, Blood agar, Nutrient agar (Merck, Germany) and incubated at 37 ° C for 18-24 hours. Identifying bacteria isolates was performed using the conventional techniques of microbiology (Mahon & Lehman, 2019). In the next step, the antibiogram test was performed by Kirby Bauer method and the minimum inhibitory concentration of antibiotics was determined using micro dilution method according to CLSI2018.

. The list of antibiotics used is shown in Table 1.

Klebsiella pneumonia (MDR and CRE) and *Pseudomonas aeruginosa* (PDR and CRE) were obtained by microbiological examination of secretions. Inject able antibiotic treatments were performed for him. The patient also underwent surgery to block blood flow and blockage of arteries following severe injuries. He was then referred to a psychiatrist for counseling and psychotherapy. The psychiatrist reported the patient showing no psychosis or major depressive disorders, no symptoms for bipolar spectrum, obsessive-compulsive disorder, and judgment was not impaired. Suicide and homicide thought were not present at that time.

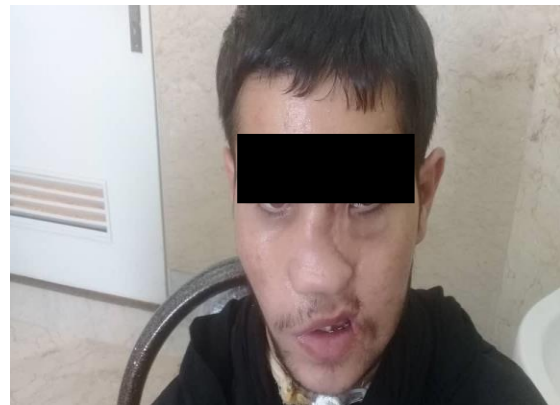

Figure 1. Facial reconstruction by plastic surgeon after suicide attempt via gunshot plan



Figure 2. Tattoo incubation as love symbolization on left dorsum of hand



Table 1. Antimicrobial Susceptibility Patterns and Microdilution Method for *Pseudomonas aeruginosa* and *Klebsiellapneumoniae* isolated from wound infection

Antibiotic	Disk content, µg	Antibiotics Serial Concentrations, µg/mL	MIC Resistance Interpretive Criterion, µg/mL	Antibiotic	Disk content, µg	MIC Resistance Interpretive Criterion, µg/mL
Ofloxacin	5	0.25 - 32	≥8	Ampicillin-sulbactam	10	
Ciprofloxacin	5	0.25 - 32	≥4	Piperacillin-tazobactam	10	
Gentamicin	10	0.5 - 64	≥16	Gentamicin	10	
Imipenem	10	0.5 - 64	≥16	Imipenem	10	≥4
Meropenem	30	1 - 128	≥16	Meropenem	30	
Ceftazidime	30	2 - 512	≥32	Ceftazidime	30	
Amikacin	30	1 - 128	≥64	Amikacin	30	
Aztreonam	30	1 - 128	≥32	Cephazolin	30	
Colistin			≥ε	Ciprofloxacin	5	
Cefotaxime	30	1 - 128	≥64	Cefotaxime	30	
Cefepime	30	1 - 128	≥32	Cefepime	30	
Tetracycline	30	1 - 128	≥16	Sulfamethoxazole /Trimethoprim	1.25	
Ticarcillin	75	4 - 512	≥128	Colistin		≥4
Piperacillin	100	4 - 512	≥128	Piperacillin	100	
Carbenicillin	100	4 - 512	≥512	Ampicillin	10	
Polymyxin B	300	0.25 - 32	≥8	Tetracycline	30	

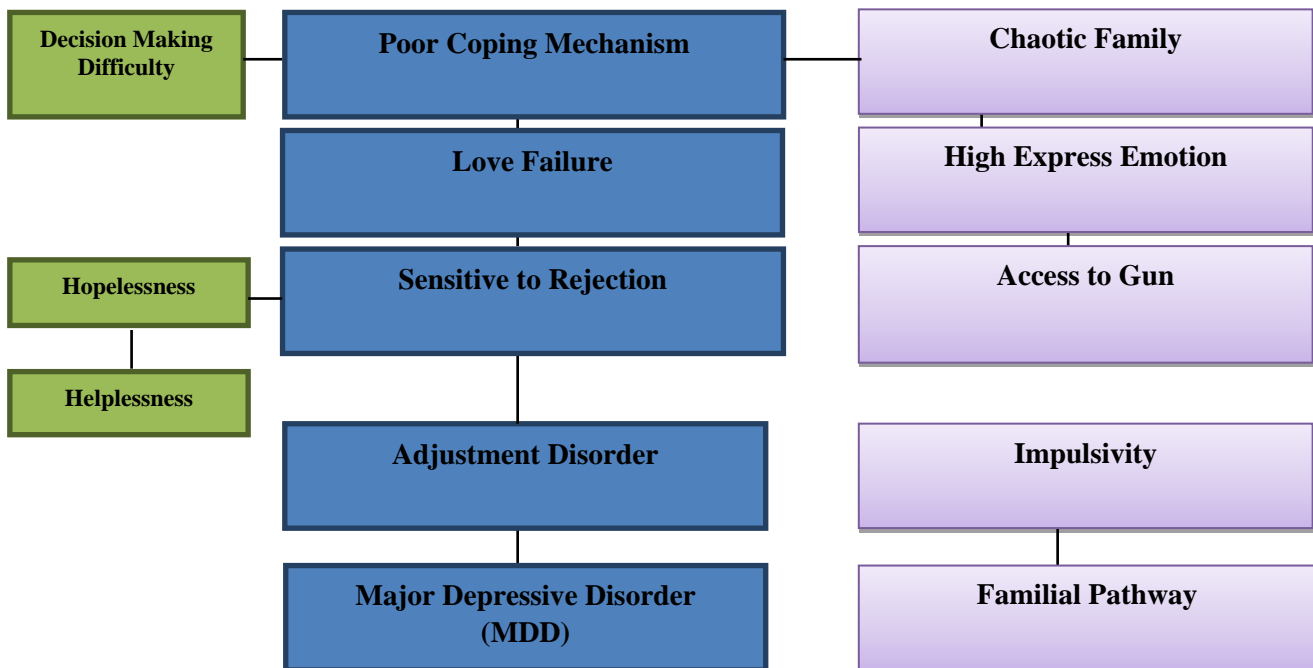


Figure 3. Suggestive etiologies of lethal suicide in a young patient



Discussion

Although we could not determine psychodynamics of suicide, we believe that predisposing factors like love failure, recent rejection, poor coping mechanism, low social skills, chaotic family, specific culture, access to lethal device and COVID-19 pandemic status can play key roles around this social event (Fig 3).

As the patient was evaluated by psychiatrist via interview both alone and also with presence of his father, diagnosis was major depressive disorder with self-accusation and psychomotor retardation. He had no death or suicide ideation. Therefore, psychiatrist prescribed anti-depressant, along with psycho-education for him and his father as outpatient. Psychiatric treatment was emphasized for the patient following cosmetic modality treatments.

In this case, due to impaired interpersonal relationships and poor defense mechanisms anomic suicide was performed impulsively with a single-barreled gun for the second time after taking the drugs. In fact, gunshot in this phase is important because he definitely wished to die. His family owned a single-barreled shotgun used by the father. After committing the self-damage, the patient's appearance became completely deformed, and with surgery it was tried to be corrected to some extent; however, the face projected to be very ugly and deformed. The patient is currently much remorseful so that he has no suicidal thoughts any more.

A review study by Haw et al. (Haw et al., 2004) in the UK found that the majority of gun suicides were committed by gun owners, mostly males who are middle-aged. Except for the patient's age, all other parameters are consistent with the present study. The study also found that people who live with their partners may commit suicide due to interpersonal problems. Also, like the present study, they had a history of self-harm. It is a high risk behavior and therefore we should predict possibility of similar other suicide attempts. Another new problem pertains to the patient's appearance and adaptation of him to this.

Our case was from a rural region with religious adherence and recent adjustment disorder associated with love failure. Of course cultural issues, social interactions and attitude to suicide behavior are important factors in different countries. Also, most of these studies are related to the time before COVID-19 pandemic. We decided to introduce a suicide attempt in COVID-19 pandemic because COVID has an extended Umbrella term for intra and inter psychiatric status, quality of life and social s individual.

It is important to note that the deformity of the patient's face needs to be initially corrected by the surgeon, and psychiatrist should follow the patient mentally, reduce suicidal thoughts in the person, work on the patient's life and family skills, and reduce blame and criticism as for family therapy.

Suicide in early adolescence is an important tragic event that has a score of consequences for the relatives of the victim and is considered a significant challenge for any community.

All physicians have to suggest inaccessibility of the arms/guns to the patients with depressive disorders, suicidal thoughts, drug misuse, high risk behavior, impulsivity, or a psychiatric or organic disorder.

In a study on 50 states in USA, it was found a relationship between household firearm ownership and higher rate of completed suicide (Miller et al., 2007). For this specific case, we believe access to gun ownership is a powerful factor for suicide ideation and attempt.

On the whole, intensive treatment of life-threatening firearm injuries before and after plastic surgery as well as suitable care can increase the outcome of the persons (Balci et al., 2007). Of course, we suggest psychotherapy for the patients and their families parallel to cosmetic surgery.

Conclusion

In cases which there is a dangerous device such as a gun or other harmful object, it should be taken out of the reach of the family members. Precise psychiatric evaluation is vital intervention for estimation of probability of suicide attempts for



them. After committing suicide and probable complications like any change in the appearance and show of deformity on image, it is needed for the medical team to work up and prepare the victim or client to restore qualitative life.

Acknowledgments

We would like to thank the patient for his cooperation and consent in this study.

Conflicts of Interest

We have no competing interests.

Authors' Contributions

Conceptualization, R.B; Methodology, R.B.; Writing -Review & Editing, MS and RB.; Supervision, RB; Writing -Original Draft, MS and RB. All authors read and approved the final manuscript and are responsible about any question related to the paper.

References

- Arafat, S. M. Y. (2019). Psychological autopsy study in Bangladesh: An unmet need to formulate preventive strategy of suicide. *Asian J Psychiatr*, 43, 85-86. <https://doi.org/10.1016/j.ajp.2019.05.019>
- Balci, Y., Canogullari, G., & Ulupinar, E. (2007). Characterization of the gunshot suicides. *J Forensic Leg Med*, 14(4), 203-208. <https://doi.org/10.1016/j.jcfm.2006.06.025>
- Carr, M. J., Steeg, S., Webb, R. T., Kapur, N., Chew-Graham, C. A., Abel, K. M., . . . Ashcroft, D. M. (2021). Effects of the COVID-19 pandemic on primary care-recorded mental illness and self-harm episodes in the UK: a population-based cohort study. *Lancet Public Health*, 6(2), e124-e135. [https://doi.org/10.1016/S2468-2667\(20\)30288-7](https://doi.org/10.1016/S2468-2667(20)30288-7)
- Gunnell, D., Appleby, L., Arensman, E., Hawton, K., John, A., Kapur, N., . . . Collaboration, C.-S. P. R. (2020). Suicide risk and prevention during the COVID-19 pandemic. *Lancet Psychiatry*, 7(6), 468-471. [https://doi.org/10.1016/S2215-0366\(20\)30171-1](https://doi.org/10.1016/S2215-0366(20)30171-1)
- Haw, C., Sutton, L., Simkin, S., Gunnell, D., Kapur, N., Nowers, M., & Hawton, K. (2004). Suicide by gunshot in the United Kingdom: a review of the literature. *Med Sci Law*, 44(4), 295-310. <https://doi.org/10.1258/rsmmsl.44.4.295>
- Kaggwa, M. M., Nuwamanya, S., Ashaba, S., Rukundo, G. Z., & Harms, S. (2021). An Adolescent's Use of Veterinary Medicines: A Case Report Exploring Addiction. *J Psychoactive Drugs*, 1-6. <https://doi.org/10.1080/02791072.2021.1873466>
- Kposowa, A. J. (2013). Association of suicide rates, gun ownership, conservatism and individual suicide risk. *Soc Psychiatry Psychiatr Epidemiol*, 48(9), 1467-1479. <https://doi.org/10.1007/s00127-013-0664-4>
- Mahon, C. R., & Lehman, D. C. (2019). *Textbook of Diagnostic Microbiology*. In: Elsevier.
- Mamun, M. A., Siddique, A. B., Sikder, M. T., & Griffiths, M. D. (2020). Student Suicide Risk and Gender: A Retrospective Study from Bangladeshi Press Reports. *Int J Ment Health Addiction*. <https://doi.org/https://doi.org/10.1007/s11469-020-00267-3>
- Miller, M., Lippmann, S. J., Azrael, D., & Hemenway, D. (2007). Household Firearm Ownership and Rates of Suicide Across the 50 United States. *Journal of Trauma and Acute Care Surgery*, 62(4), 1029-1035. https://journals.lww.com/jtrauma/Fulltext/2007/04000/Household_Firearm_Ownership_and_Rates_of_Suicide.31.aspx
- Mugisha, J., Hjelmeland, H., Kinyanda, E., & Knizek, B. L. (2013). Religious views on suicide among the Baganda, Uganda: a qualitative study. *Death Stud*, 37(4), 343-361. <https://doi.org/10.1080/07481187.2011.641136>
- Rodway, C., Tham, S. G., Ibrahim, S., Turnbull, P., Windfuhr, K., Shaw, J., . . . Appleby, L. (2016). Suicide in children and young people in England: a consecutive case series. *Lancet Psychiatry*, 3(8), 751-759. [https://doi.org/10.1016/S2215-0366\(16\)30094-3](https://doi.org/10.1016/S2215-0366(16)30094-3)