

The protective effect of curcumin against aluminum chloride-induced oxidative stress and hepatotoxicity in rats

Ebrahim Cheraghi^{1*}, Kambiz Roshanaei²

¹Department of Biology, Faculty of Sciences, University of Qom, Qom, Iran

²Department of Biology, Faculty of Sciences, Qom Branch, Islamic Azad University, Qom, Iran

ARTICLE INFO

*Corresponding author:

[e.cheraghi@qom.ac.ir](mailto:echeraghi@qom.ac.ir)

Article history:

Received: Jan 5, 2019

Accepted: Mar 9, 2019

Keywords:

Aluminum chloride,
curcumin,
hepatotoxicity,
oxidative stress

ABSTRACT

Aluminum is recognized as a public health concern because of its potential toxic effects on human health. Therefore, the present experiment was undertaken to determine the effectiveness of curcumin (CUR) in reducing the hepatotoxicity induced by aluminum chloride (AlCl₃) in animals. In this experimental study, forty male rats were allocated to five groups (N = 8), viz. no treatment (control), solvent (DMSO or distilled water), CUR (10 mg/kg B.W.), AlCl₃ (10 mg/kg B.W.), and CUR+AlCl₃ (each with 10 mg/kg B.W.). Treatments were performed by intra-peritoneal injections for 28 days. On the final day, animals were sacrificed, and liver function markers in blood plasma, hepatic antioxidants, and lipid peroxidation index in liver homogenate were estimated. AlCl₃ treatment resulted in a significant increase in plasma AST, ALT, ALP and LDH activities with decreased total protein compared to control. AlCl₃ significantly reduced superoxide dismutase (SOD), catalase (CAT) and glutathione (GSH) levels but increased malondialdehyde (MDA) level in the liver compared to control. AlCl₃ also caused various histopathological changes in the livers of rats. Curcumin could normalize nearly all these parameters. CUR improved levels of changes in different parameters when was combined with AlCl₃. It is concluded that CUR has beneficial effects being able to antagonize AlCl₃ toxicity.

Citation: Pharm Biomed Res 2019;5(1): 11-18.

Introduction

A copious amount of aluminum metal exists in the earth's crust. The metal is a constituent of cooking utensils and medicines such as anti-acids, deodorants, food additives, which has facilitated its access into the body (1). In the ionic form, aluminum is measurable in not only all natural waters, but also most types of animal and plant tissues (2). Because of its reactivity, aluminum is naturally present as combined with other elements forming compounds such as aluminum sulfate and chloride (3). The risk of exposure and related health issues in humans exacerbated by the wide abundance of aluminum. The concentration of this metallic element in the consumers' organs will rise due to high consumption of aluminum-containing products resulting in damages to various tissues including kidney, liver, heart, blood, bone, and brain (4). The toxic effects of aluminum are attributed to mediation by reactive oxygen species (ROS) generation giving rise to oxidative deterioration of cellular lipids, proteins and DNA, as well as induction of changes in the activities of tissue antioxidant enzymes, altered gene expression, and apoptosis (5-6). Evidence indicates that aluminum induced changes in hemato-biochemical parameters, increased lipid peroxidation, and decreased the activities of antioxidant enzymes in plasma and different tissues (7-9). The kinetics of aluminum-induced toxicity includes activation of Fe²⁺ and Fe³⁺ ions to cause oxidative damage (10). The excessive mitochondrial ROS generation sparks

hepatocyte apoptosis and depletes endogenous antioxidant enzymes via activation of the caspases cascade. Consequently, the external supply of antioxidants is important to inhibit caspase activation and also to defend against the injurious effects of oxidative stress (11).

In order to regulate the progression of diseases associated with oxidative stress, various antioxidants, and plant phenolics have examined as chemoprotective agents in epidemiological and experimental studies. Curcumin (*Curcuma longa* Linn), a hydrophobic polyphenol extracted from turmeric, can be used as both an antioxidant and a therapeutic agent with no specific side effects (12). As a free radical scavenger, curcumin can largely suppress the production of ROS both *in vitro* and *in vivo* (13). This diarylheptanoid was reported to have anti-carcinogenic, anti-inflammatory, and anti-bacterial properties (14) acting as a potent cancer chemo-preventive agent (15) and a suppressor of tumor cell proliferation (16).

As shown by recent studies, curcumin has a robust scavenger of oxygen free radicals that increase intracellular glutathione concentration, thereby protecting against lipid peroxidation (17). Curcumin administration has reported to prevent oxidative stress caused by arsenic, gentamicin, cadmium, paracetamol and carbon tetrachloride in rats (18-22). Accordingly, the present research sought to investigate aluminum chloride toxicity in the liver of rats and to elucidate the

protective action of curcumin against the hepatotoxicity of aluminum chloride.

Materials and methods

Chemicals

Curcumin powder (C₂₁H₂₀O₆, Aldrich Chemical Co. Inc., USA,) dissolved in dimethyl sulfoxide (DMSO). Aluminum chloride (AlCl₃; Aldrich Chemical Co. Inc., USA,) diluted with distilled water before administration.

Experimental protocol

In this experimental study, a total of 40 male Wistar rats (200-220 g) were obtained from the animal house of Razi Institute (Tehran, Iran). Rats were housed in individually ventilated cages on a 12-hour light/dark cycle, a temperature of 24 ± 2 °C, with water and food given *ad libitum*. The experimental protocol was provided in previous study (23), approved by the Animal Ethics Committee in accordance with the guide for the care and use of laboratory animals prepared by Qom University of Medical Sciences (Qom, Iran) (approval ref no.1396.63).

All rats were fed by a standard pellet diet and closely monitored to ensure normal growth and behavior during a two-week adaptation period. The rats were then weighed and allocated to five groups of eight animals (two control groups and three experimental groups) to receive the following treatments for 28 days (24):

Group I (control group): No injections,

Group II (solvent group): Intraperitoneal (IP) injections of only the vehicle (distilled water or DMSO),

Group III (experimental group): IP injections of curcumin 10 mg/kg body weight in 0.2 ml DMSO (25),

Group IV (experimental group): IP injections of aluminum chloride 10 mg/kg body weight in 0.2 ml distilled water (24),

Group V (experimental group): IP injections of both curcumin and aluminum chloride at the above-mentioned doses.

The rats were re-weighed, euthanized, and dissected after the treatment period. Blood samples were collected into heparinized capillary tubes through cardiac puncture. The samples were poured into dry, clean centrifuge tubes, centrifuged at 1500 g (Hettich, EBA20, UK) for 20 minutes and the plasma stored at - 20 °C for future evaluation and analysis.

The livers were excised immediately, washed in physiological saline followed by weighing and dividing into two parts. One part was prepared for histology examination by the method of Bancroft and Gamble (26). The other part was homogenized in 25% Tris HCl (50 mM) buffer pH 7.4. The homogenate was centrifuged at 10,000 g for 20 minutes, the supernatant was stored at - 20 °C, and then used for total protein analysis by the method of Lowry (27). A part of the crude homogenate was used for the estimation of tissue thiobarbituric acid (TBA) reactive substances and antioxidant enzymes.

Biochemical analysis of liver function

Plasma aspartate transaminase (AST; ab105135), alanine aspartate transaminase (ALT; ab105134)

alkaline phosphatase (ALP; ab83369), and lactate dehydrogenase (LDH; ab102526) activities were determined by ELISA kits according to the manufacturer's instructions (Abcam Corporation, Japan).

Tissue thiobarbituric acid reactive substances and antioxidant enzymes in the liver

The extent of lipid peroxidation (LPO) in terms of thiobarbituric acid reactive substances (TBARS) formation was measured according to the method of Esterbauer and Cheeseman (28). The absorbance of the sample was measured at 530 nm using a blank containing all the reagents except the sample. Because 99% of TBARS consists of malondialdehyde (MDA), TBARS concentrations of the samples were determined using the extinction co-efficient of MDA (1.56×10⁵ M cm⁻¹).

The content of reduced glutathione (GSH; ab156681), and the activities of superoxide dismutase (SOD; ab65354) and catalase (CAT; ab83464) were estimated using reagent kits (Abcam Corporation, Japan) according to the manufacturer's instructions.

Histological analysis

Briefly, an abdominal incision was made, pieces of the liver were fixed and embed in 10% formalin, ed Sections of 5 μm thickness were obtained using a rotary microtome, stained with Heidenhain's Azan and Reticulin, and observed under a light microscope (26).

TUNEL method for analysis of apoptosis

The *in situ* DNA fragmentation was visualized by terminal deoxynucleotidyl transferase dUTP nick end labeling (TUNEL) method. In a nutshell, liver sections were dewaxed, predigested with 20 mg/ml proteinase K for 20 min, and incubated in phosphate buffered saline (PBS) solution containing 3% H₂O₂ for 10 min to hinder the endogenous peroxidase activity. The sections were incubated with the TUNEL reaction mixture, fluorescein-d UTP (Roche Applied Science, Germany) for 60 min at 37 °C according to the manufacturer's instructions. Afterward, the slides were rinsed thrice with PBS and incubated with secondary anti-fluorescein-POD-conjugate for 30 min. For chromogenic reaction, Hoechst stain (Sigma-Aldrich Co. Inc., USA) was added to the thrice-rinsed PBS. The step of using the TUNEL reaction mixture was omitted in negative control serial sections to control method specificity; instead, the nucleotide mixture was used in the reaction buffer. The apoptotic index was determined at 10-random locations within each liver section (29).

Statistical analysis

The normality of continuous variables was confirmed using the Kolmogorov-Smirnov test. Data were reported as mean ± standard error (SE) and analyzed with one-way analysis of variance (ANOVA) and Tukey's post-hoc test. P values less than 0.05 were considered significant. All analyses were performed with SPSS 16.0 for Windows (SPSS Inc., Chicago, IL, USA).

Results

Effects of treatments on the body and liver weights

Changes in total body and liver weights are shown in Table 1. The total body weight dropped significantly in rats of AlCl₃-treated group compared to those received CUR (P < 0.001), CUR+ AlCl₃ (P < 0.05) and the controls (P < 0.001). Besides, very significant increases were noted in the liver weights of AlCl₃-treated rats (with liver hypertrophy) compared to the other groups (P < 0.01).

Effects of treatments on plasma biochemical markers

Table 1 shows some biochemical indexes indicative of liver injury in rats. Data revealed significant rises in plasma levels of AST, ALT, ALP, and LDH in AlCl₃-treated rats compared to CUR and CUR+AlCl₃ group and also the controls (P < 0.05). In CUR and CUR+AlCl₃ treatments, there were no significant differences in plasma AST, ALT, ALP and LDH levels in comparison with the control and solvent groups. The total protein showed a significant reduction in rats of AlCl₃-treated group as opposed to CUR and CUR+AlCl₃ and control rats (P < 0.05). There was a significant increase in total protein of CUR rats compared to that of AlCl₃ group (P < 0.05), but CUR treatment was not significantly different from the control and solvent groups (Table 1).

Effects of treatments on lipid peroxidation

Malondialdehyde (MDA) levels in the tissue's homogenates of the liver (Fig. 1-A) increased in the AlCl₃-treated group compared to those of CUR+AlCl₃ and the control rats (P < 0.0001). CUR+AlCl₃ group showed no significant changes in the liver MDA levels compared to the control rats (P > 0.05). Levels of MDA in the studied tissues decreased significantly in CUR rats as opposed to the other groups (P < 0.05).

Effects of treatments on antioxidant enzyme activities

Figure 1-B, C and D show changes of GSH, SOD and CAT activities in the liver tissue indicating liver oxidative damage. Exposure of rats to AlCl₃ produced significant drops in GSH, SOD and CAT enzyme activities compared to other groups (P < 0.05). The rats received CUR+AlCl₃ exhibited significantly elevated levels of GSH in comparison with AlCl₃ group (P < 0.05) but not with the control. Compared to AlCl₃ group, the animals in CUR+AlCl₃ treatment displayed significant elevations of SOD activities in tissue homogenates of the liver (P < 0.05), but were not different from the control. Moreover, CAT activities in liver tissues of CUR+AlCl₃ rats were significantly higher than that of AlCl₃ group (P < 0.05), but showed no differences with the control. In contrast, treatment with curcumin resulted in a significant amelioration of the enzyme (GSH, SOD and CAT) activities.

Effects of treatments on apoptosis and histological structures of the liver

Rats treated with AlCl₃ showed significantly higher TUNEL-positive cells (P = 0.001) than the other groups. Treatment with CUR+AlCl₃ resulted in significantly lower number of TUNEL-positive cells when compared with AlCl₃-treated rats (P = 0.01). However, this value was not significantly different compared to control group. Moreover, the number of apoptotic cells dropped significantly in rats treated with CUR alone (P = 0.0001) as compared to those treated with AlCl₃ alone and in CUR+AlCl₃ group (Fig. 2-3).

Histological structures of the liver in rats treated with curcumin (Fig. 4-B, b) showed normal tissue structures of the liver similar to the control tissue (Fig. 4-A, a). After four weeks of administration, liver histological structures

Table 1 Changes in body weight, liver weight, and biochemical parameters of rats treated with aluminum chloride (AlCl₃), curcumin (CUR), CUR+AlCl₃, solvent and control.

Parameters	Experimental groups				
	Control	Solvent	CUR	AlCl ₃	CUR+AlCl ₃
Body Weight (g)	227.1±3.9 ^{ac}	229.7±3.8 ^{ac}	232.8±5.3 ^c	195.2±4.5 ^b	215.6±2.8 ^a
Liver Weight (g)	2.7±0.08 ^a	2.8±0.1 ^a	2.8±0.1 ^a	3.5±0.1 ^b	2.98±0.07 ^a
ALT (IU/L)	31.2±1.5 ^a	32.2±2.1 ^a	27.5±3.1 ^a	42.9±1.2 ^b	33.1±1.4 ^a
AST (IU/L)	34.9±2.3 ^a	33.5±2.3 ^a	31.3±1.6 ^a	46.6±2.7 ^b	35.6±2.1 ^a
ALP (IU/L)	84.84±8.2 ^a	87.1±8.6 ^a	82.3±3.07 ^a	131.43±7.3 ^b	102.76±7.7 ^{ba}
LDH (IU/L)	156.63±2.5 ^a	159.12±3.2 ^a	160.37±2.9 ^a	191.62±3.4 ^b	169.62±4.1 ^a
Total Protein (g/dl)	9.7±0.5 ^a	9.9±0.5 ^a	10.8±0.8 ^a	6.5±0.7 ^b	9.1±0.9 ^a

- Data are shown as mean ± SEM. Analysis was performed by ANOVA followed by the Tukey's test for multiple comparisons.

- Means within the same row with different letters are significantly differed (p<0.05).

AST: aspartate transaminase; ALT: alanine transaminase; ALP: Alkaline Phosphatase; LDH: Lactate dehydrogenase.

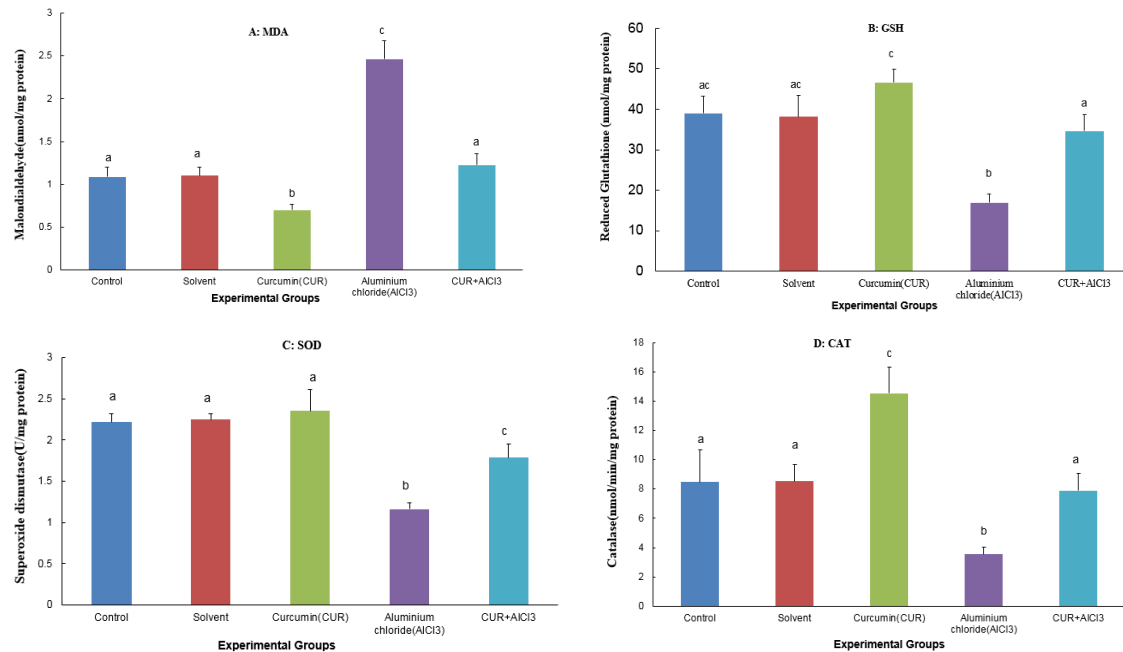


Figure 1 Effects of CUR and AlCl₃ on oxidative stress parameters in liver tissue homogenates of experimental groups: A) Malondialdehyde (MDA), B) Reduced Glutathione (GSH), C) Superoxide dismutase (SOD), D) Catalase (CAT). Bars bearing different letters significantly different ($P \leq 0.05$) (means \pm SEM).

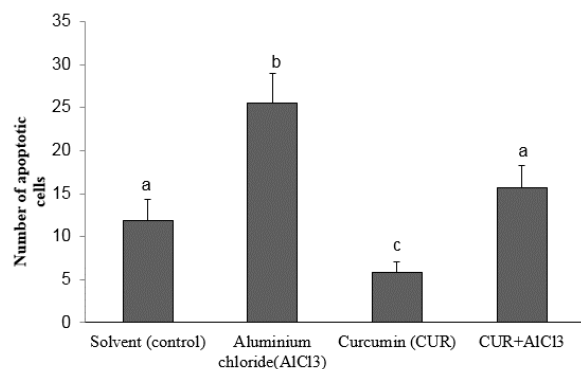


Figure 2 Photomicrograph of the different groups showing the number of apoptotic cells in liver tissue following TUNEL staining. Values are expressed as Mean \pm SEM. Values bearing different superscript on the bar diagram vary significantly ($p < 0.05$, one way ANOVA, Tukey's test).

of AlCl₃ intoxicated rats (Fig. 4-C, c) revealed distortion and inflammation of the portal area, deposition of red blood cells in the portal vein, and lipid droplets, as well as bleeding in sinusoids and distorted portal area.

The histological structure of liver in the CUR+AlCl₃ group after four weeks (Fig. 4-D, d) showed normal hepatocytes nucleus and slight bleeding in sinusoids. Also, an improvement of the liver structure was observed with CUR+AlCl₃ (Fig. 4-D, d) showing no bleeding in the portal vein and a normal bile duct in the normal portal area.

Discussion

The present study was undertaken to determine whether curcumin (CUR) could prevent and/or reduce aluminum chloride-induced oxidative stress and hepatotoxicity in Wistar rats.

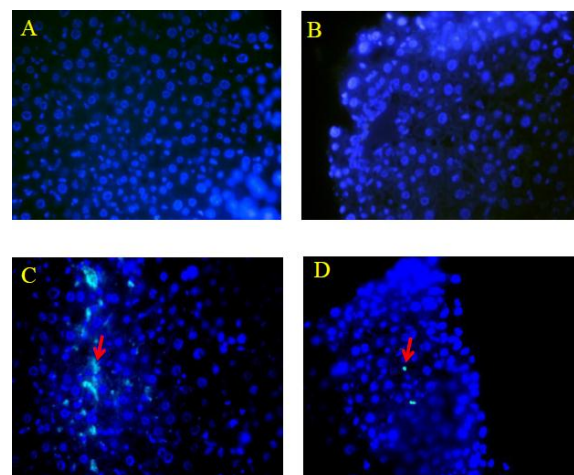


Figure 3 Effects of CUR and AlCl₃ on the number of apoptotic cells in liver by fluorescence microscope (Magnification: x200). A. Solvent (Control), B. Treated with CUR, C. Treated with AlCl₃, D. Treated with CUR+AlCl₃. Compared with the control group, the number of apoptotic cells were significantly increased in AlCl₃ group. The apoptotic of cells (green) can be recognized. AlCl₃; Aluminium chloride, CUR; Curcumin.

The present study recorded elevated levels of MDA but reduced activities of glutathione (GSH), superoxide dismutase (SOD) and catalase (CAT) in the liver samples of aluminum chloride (AlCl₃)-treated rats. Moreover, it the hepatotoxic effect of Al was demonstrated by the elevated activities of ALT, AST, ALP and LDH in the plasma of treated rats with AlCl₃ compared to control with decreased total protein. AlCl₃ significantly reduced SOD, CAT and GSH levels but increased MDA level in the liver compared to control. AlCl₃ also caused various

histopathological changes in the livers of rats. Curcumin (CUR) improved levels of changes in different parameters when combined with AlCl_3 .

Aluminum is ubiquitous in the environment and its extensive industrial use provides an incentive to monitor its toxicity. Reported data indicate that aluminum has a potential of toxicity in humans and animals (6, 30), which may be mediated by free radical generation and alterations in antioxidant enzymes both *in vivo* and *in vitro* (31) leading to neurotoxicity (32-33) and hepatotoxicity (24, 34). The present study further

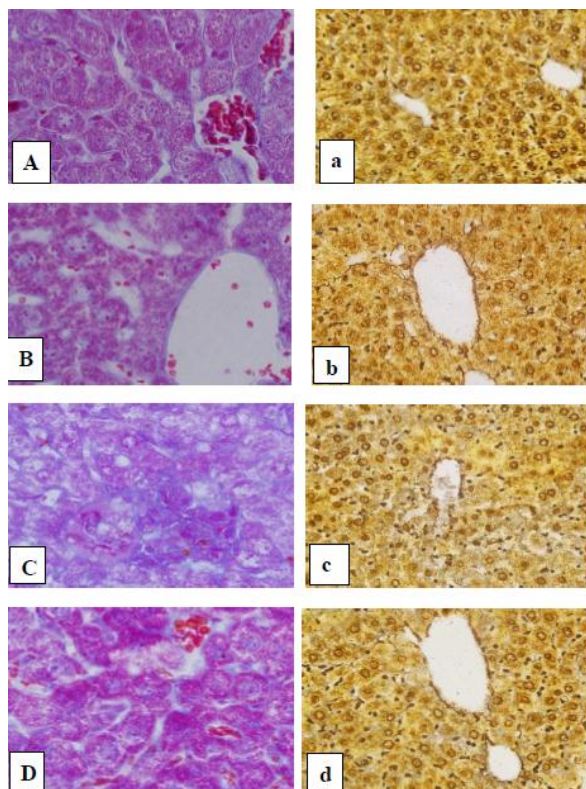


Figure 4 Histopathological changes in the liver tissue of experimental groups (X400, Heidenhain's Azan; X200, Reticulin staining).

(A) Liver section of control rat group showing normal classic hepatic lobule with central vein, hepatic plates, polygonal hepatocytes with central basophilic nuclei. (a) Liver section of control rat group showing normal classic hepatic lobule with normal hepatic scaffold. (B, b) Liver section of CUR treated group showing a feature of normal hepatic parenchyma. (C) Section of liver of AlCl_3 -treated rats showing distorted portal area, bleeding in the portal vein, bleeding in sinusoids, lipid droplets and vacuolar degeneration of hepatocytes and necrosis. (c) Liver section of AlCl_3 -treated rats showing distorted scaffold and aggregation of inflammatory cells. (D, d) Liver section of CUR and AlCl_3 co-treated rat shows improvement of liver structure: normal portal area, no bleeding in the portal vein, normal bile duct, normal hepatocytes nucleus. AlCl_3 ; Aluminum chloride, CUR; Curcumin.

revealed clear signs of AlCl_3 toxicity with reference to decreased body weight and increased liver weight (Table 1). These findings are in agreement with previous reports demonstrating that AlCl_3 toxicity leads to both abnormal body and liver weights (35-36). Our results indicate that CUR might have a beneficial role in lowering AlCl_3 toxicity probably due to its radical scavenging and neutralizing property. Thus, CUR treatment rectifies the falls of body weight and the rises of liver weight.

Lipid peroxidation of biological membranes results in the loss of membrane fluidity, changes in membrane potential, an increase in membrane permeability, and alterations in receptor functions (37). It is known that aluminum is bound to transferrin as the Fe^{3+} carrying protein, thereby, limiting the binding of Fe^{2+} . Peroxidation of membrane lipids is caused by an increase in free intracellular Fe^{2+} giving rise to membrane damage (37). In the present study, there was a significant increase in lipid peroxidation after aluminum chloride exposure, measured in terms of MDA levels in the liver. These observations are similar to those reported by previous studies (7, 37-39), who indicated that aluminum intake produces oxidative stress. In contrast, CUR administration with AlCl_3 decreased significantly the levels of MDA in the liver tissue homogenates. Priyadarsini *et al.*, (40) suggested that curcumin to be capable of exerting antioxidative effects either directly as a chemical antioxidant owing to its capacity to scavenge ROS and nitrogen free radicals, or through regulating cellular defenses, which in turn apply antioxidant impacts. These observations are similar to previous reports (33, 41).

Oxidative stress occurs as a consequence of the imbalance between ROS generation and the antioxidative process in favor of radical production. In the current study, a significant decrease in the activities of liver antioxidant enzymes (GSH, SOD and CAT) reflects the failure of antioxidant defense system to overcome the influx of ROS generated by AlCl_3 exposure. The results are in accordance with Kumar *et al.*, (33), who observed significantly dropped activities of SOD, GSH and CAT after AlCl_3 treatment. On the other hand, aluminum has been shown to be capable of suppressing NADPH-generating enzymes such as glucose 6-phosphate dehydrogenase and NADP-isocitrate dehydrogenase. As NADPH has been found to be a major factor for GSH regeneration, the declined levels of GSH may be further attributed to inadequate NADPH availability (42). Besides, aluminum is able to diminish the activity of liver enzymes (e.g. superoxide dismutase, catalase and GSH) associated with cell antioxidant defense (43). The increased lipid peroxidation leads to inactivation of the antioxidant enzymes by crosslinking with MDA causing an increased accumulation of superoxide, H_2O_2 and hydroxyl radicals, which could further stimulate lipid peroxidation (44). Curcumin supplementation could grant protection against antioxidant defense system failure, which is in line with those of similar studies (45-46). Supplementation of CUR prevented these abnormalities due to its role in stabilizing the cell membrane and protecting the tissue from free radical mediated toxicity. Gaskill *et al.*, (47) reported that releases of transaminases (AST and ALT), ALP and LDH from the cell cytosol can occur secondary to cellular necrosis. The activity of AST significantly increases in such cases and escapes to the plasma from the injured hepatic cells. In addition, ALT levels are valuable indicating the presence of liver diseases, as a large quantity of this enzyme is present in the liver. ALT plasma levels rise when cellular degeneration and/or

destruction occurs in this organ (48). The present study recorded significant rises in the activities of AST, ALT, ALP and LDH enzymes (Table 1) in plasma of rats treated with aluminum as reported in previous studies (7, 36, 38-39, 47, 49). This observation may be due to the leakage of these enzymes from the liver cytosol into the blood stream and liver dysfunction and disturbance in the biosynthesis of these enzymes along with altered permeability of liver membrane. Also, Whihelm *et al.*, (9) reported that aluminum exposure resulted in the metal accumulation in the liver and that it could be toxic to the hepatic tissue at high concentrations. Moreover, AlCl₃ treatment caused a significant decrease in the level of total protein when compared with control group. The inhibitory effect of AlCl₃ on protein profile is in agreement with the previous findings (7, 36). So, the significant decreases in the concentrations of total protein in AlCl₃-treated rats could be attributed to the malnutrition and a reduction in protein synthesis capability of the liver (50). The declined levels of plasma proteins could also be mainly ascribed to the destructive impact of AlCl₃ on liver cells as reflected in the elevated activities of AST, ALT, ALP and LDH enzymes in plasma.

Following treatment of rats with CUR+AlCl₃, the activities of antioxidant enzymes and biochemical indicators were normalized to their control values (Table 1). This lends support to our finding that curcumin could enhance the reduced levels of antioxidant enzymes in AlCl₃-intoxicated rats. CUR treatment was also able to restore the activity of various antioxidant enzymes in AlCl₃-treated rats meaning that curcumin has hepatoprotective and antioxidant properties against hepatotoxins. The primary mechanism for this effect of curcumin may involve scavenging of free radicals causing lipid peroxidation. At the molecular level, curcumin is an atoxic natural inhibitor of NF-κB and, as a result, it modulates the expression of various genes such as cyclooxygenase-2, matrix metalloproteinase-9, inducible nitric oxide synthase, interleukin-8, and anti-apoptotic proteins, all of which are regulated by NF-κB. It also potentially induces protective heat shock proteins and inhibits lipoxygenases (33, 51).

Our findings reveal that CUR treatment alleviated the toxic effects of AlCl₃ on liver histology, when administered together with AlCl₃. Similarly, Gaber *et al.*, (41) investigated the histopathologic effects of curcumin against cadmium (Cd) toxicity, and reported that Cd led to severe histological damage, including apoptotic cell death, and that curcumin treatment partially reversed these effects of Cd. The liver histological structures of our AlCl₃ intoxicated rats illustrated distorted portal area and edema, bleeding in the portal vein, fibrosis around the portal area, and vacuolar degeneration of hepatocytes. These findings may explain the elevation of liver enzymes in plasma. Some of previous studies support our results in that they also proved the liver injury after exposure to AlCl₃ (52). Also, Abdel-Wahab (8) presented evidence that liver sections from rats administered with AlCl₃ showed distorted liver architecture, namely marked necrosis and degeneration of hepatocytes, centrilobular necrosis and congestion of the central vein,

vacuolization of hepatocytes, and dilatation and congestion of the blood sinusoids in addition to infiltration of inflammatory cells. The liver histological structures of the rats treated with curcumin showed a normal tissue structure of the liver similar to that of control group. The liver histological structures in CUR+AlCl₃ group represent no bleeding in the central vein, expansion of sinusoids around the central vein, and normal hepatocytes nucleus. Related studies suggested that CUR could reduce histological alterations caused by cadmium-induced hepatotoxicity (17, 41). It was speculated that a correlation might exist between the histological findings and oxidative status, and that histopathological effects may reflect AlCl₃-induced oxidative stress in the liver tissue. Accordingly, it can be concluded that curcumin may play a protecting role against AlCl₃-induced liver injury due to its ameliorating effects on elevated oxidative stress and to a preventive impact against histological damage in the liver tissue exposed to AlCl₃ toxicity.

This study clearly indicates that AlCl₃ affects both histological and biochemical parameters as well as antioxidative system inducing oxidative stress, which can be ameliorated by co-administration of CUR to overcome this disturbance. In fact, the ameliorative effect of CUR against oxidative stress in AlCl₃ treated rat's results from its antioxidant property by scavenging free radicals and chelating metals as well as regeneration of endogenous antioxidant.

Acknowledgments

The authors are grateful to the Department of Biology, Qom Islamic Azad University.

Conflict of interest

The authors declare that there are no conflicts of interest.

References

1. DeVoto E, Yokel RA. The biological speciation and toxicokinetics of aluminum. *Environ Health Perspect* 1994;102:940-51.
2. Jiang H-X, Chen L-S, Zheng J-G, Han S, Tang N, Smith BR. Aluminum-induced effects on Photosystem II photochemistry in Citrus leaves assessed by the chlorophyll a fluorescence transient. *Tree Physiol* 2008;28:1863-71.
3. Verstraeten SV, Aimo L, Oteiza PI. Aluminium and lead: molecular mechanisms of brain toxicity. *Arch Toxicol* 2008;82:789-802.
4. Zhang K, Zhou Q. Toxic effects of Al-based coagulants on *Brassica chinensis* and *Raphanus sativus* growing in acid and neutral conditions. *Environ Toxicol* 2005;20:179-87.
5. Mailloux RJ, Lemire J, Appanna VD. Hepatic response to aluminum toxicity: dyslipidemia and liver diseases. *Exp Cell Res* 2011;317:2231-38.
6. Exley C. The pro-oxidant activity of aluminum. *Free Radic Biol Med* 2004;36:380-87.
7. Yousef MI. Aluminium-induced changes in hemato-biochemical parameters, lipid peroxidation and enzyme activities of male rabbits: protective role of ascorbic acid. *Toxicol* 2004;199:47-57.
8. Abdel-Wahab WM. AlCl₃-induced toxicity and oxidative stress in liver of male rats: protection by melatonin. *Life Sci J* 2012;9:1173-82.
9. Whihelm M, Jaeger DE, Schüll-Cablitz H, Hafner D, Idel H. Hepatic clearance and retention of aluminium: studies in the isolated perfused rat liver. *Toxicol Let* 1996;89:257-63.

10. Xie CX, Yokel RA. Aluminum facilitation of iron-mediated lipid peroxidation is dependent on substrate, pH, and aluminum and iron concentrations. *Arch Biochem Biophys* 1996;327:222-6.
11. Ozben T. Oxidative stress and apoptosis: impact on cancer therapy. *J Pharm Sci* 2007;96:2181-96.
12. Duvoix A, Blasius R, Delhalle S, Schneidenburger M, Morceau F, Henry E, et al. Chemopreventive and therapeutic effects of curcumin. *Cancer Let* 2005;223:181-90.
13. Gupta SC, Patchva S, Koh W, Aggarwal BB. Discovery of curcumin, a component of golden spice, and its miraculous biological activities. *Clin Exp Pharmacol Physiol* 2012;39:283-99.
14. Araujo C, Leon L. Biological activities of *Curcuma longa* L. *Memórias do Instituto Oswaldo Cruz* 2001;96:723-28.
15. Aggarwal BB, Kumar A, Aggarwal MS, Shishodia S. Curcumin derived from turmeric (*Curcuma longa*): a spice for all seasons. *Phytopharmaceuticals in Cancer Chemoprevention* 2005;23:351-87.
16. Joe B, Vijaykumar M, Lokesh B. Biological properties of curcumin-cellular and molecular mechanisms of action. *Crit rev food Sci Nutr* 2004;44:97-111.
17. Ciftci O, Ozdemir I, Tanyildizi S, Yildiz S, Oguzturk H. Antioxidative effects of curcumin, β -myrcene and 1, 8-cineole against 2, 3, 7, 8-tetrachlorodibenzo-p-dioxin-induced oxidative stress in rats liver. *Toxicol Indust Health* 2011;27:447-53.
18. El-Demerdash FM, Yousef MI, Radwan FM. Ameliorating effect of curcumin on sodium arsenite-induced oxidative damage and lipid peroxidation in different rat organs. *Food Chem Toxicol* 2009;47:249-54.
19. Farombi E, Ekor M. Curcumin attenuates gentamicin-induced renal oxidative damage in rats. *Food Chem Toxicol* 2006;44:1443-48.
20. Eybl V, Kotyzová D, Bludovská M. The effect of curcumin on cadmium-induced oxidative damage and trace elements level in the liver of rats and mice. *Toxicol Let* 2004;151:79-85.
21. Venkatanarayana G, Sudhakara G, Sivajyothi P, Indira P. Protective effects of curcumin and vitamin E on carbon tetrachloride-induced nephrotoxicity in rats. *EXCLI J* 2012;11:641-50.
22. Tung BT, Hai NT, Son PK. Hepatoprotective effect of Phytosome Curcumin against paracetamol-induced liver toxicity in mice. *Brazil J Pharm Sci* 2017;53:1-13.
23. Cheraghi E, Golkar A, Roshanaei K, Alani B. Aluminium-induced oxidative stress, apoptosis and alterations in testicular tissue and sperm quality in Wistar rats: ameliorative effects of curcumin. *Int J Fertil Steril* 2017;11:166-75.
24. Abubakar M, Taylor A, Ferns G. Aluminium administration is associated with enhanced hepatic oxidant stress that may be offset by dietary vitamin E in the rat. *Int J Exp Pathol* 2003;84:49-54.
25. Jalili C, Khani F, Salahshoor M, Roshankhah S. Protective Effect of Curcumin Against Nicotine-induced Damage on Reproductive Parameters in Male Mice. *Int J Morphol* 2014;32:844-9.
26. Bancroft JD, Gamble M. Theory and practice of histological techniques. Churchill Livingstone. London: Elsevier Health Sciences; 2008: 109-36.
27. Waterborg JH. The Lowry method for protein quantitation. In *The protein protocols handbook*. Springer; 2009. pp 7-10.
28. Esterbauer H, Cheeseman K. Determination of aldehydic lipid peroxidation products: Malonaldehyde and 4-hydroxyonenal. *Enzymol* 1990;186:407-21.
29. Negoescu A, Lorimier P, Labat-Moleur F, Drouet C, Robert C, Guillermet C, et al. In situ apoptotic cell labeling by the TUNEL method: improvement and evaluation on cell preparations. *J Histochem Cytochem* 1996;44:959-68.
30. Berlyne G, Ari JB, Knopf E, Yagil R, Weinberger G, Danovitch G. Aluminium toxicity in rats. *The Lancet* 1972;299:564-68.
31. Tabaldi LA, Cargnelutti D, Gonçalves JF, Pereira LB, Castro GY, Maldaner J, et al. Oxidative stress is an early symptom triggered by aluminum in Al-sensitive potato plantlets. *Chemosphere* 2009;76:1402-09.
32. Wen Y-F, Zhao J-Q, Nirala SK, Bhadauria M. Aluminum-Induced Toxicity and Its Response to Combined Treatment of HEDTA and Propolis in Rats. *Pol J Environ Stud* 2012;21:1437-43.
33. Kumar A, Dogra S, Prakash A. Protective effect of curcumin (*Curcuma longa*), against aluminium toxicity: Possible behavioral and biochemical alterations in rats. *Behav Brain Res* 2009;205:384-90.
34. Kutlubay R, Oğuz EO, Güven C, Can B, Sinik Z, Tuncay ÖL. Histological and ultrastructural evidence for protective effects on aluminium-induced kidney damage by intraperitoneal administration of α -Tocopherol. *Int J Toxicol* 2007;26:95-101.
35. Bouasla I, Bouasla A, Boumendjel A, El Feki A, Messarah M. Antioxidant effect of alpha lipoic acid on hepatotoxicity induced by aluminium chloride in rats. *Int J Pharm Sci Rev Res* 2014;29:19-25.
36. El-Demerdash FM. Antioxidant effect of vitamin E and selenium on lipid peroxidation, enzyme activities and biochemical parameters in rats exposed to aluminium. *J Trace Elem Med Biol* 2004;18:113-21.
37. Nehru B, Anand P. Oxidative damage following chronic aluminium exposure in adult and pup rat brains. *J Trace Elem Med Biol* 2005;19:203-08.
38. Ige S, Adeniyi M, Iyalla G. Allium cepa mitigates aluminum chloride-induced hepatotoxicity in male wistar rats. *J Biomed Sci* 2017;6:27.
39. Osama A, Fatma A, El-Boshy M, Huda S. Studies on the Protective Effects of Ginger Extract and in Combination with Ascorbic Acid against Aluminum Toxicity Induced Hematological Disorders, Oxidative Stress and Hepatorenal Damage in Rats. *Ann Vet Anim Sci* 2014;1:137-50.
40. Priyadarsini KI, Maity DK, Naik G, Kumar MS, Unnikrishnan M, Satav J, et al. Role of phenolic OH and methylene hydrogen on the free radical reactions and antioxidant activity of curcumin. *Free Radic Biol Med* 2003;35:475-84.
41. Gabr AM, Salem TA, Ata HS, Meki ARM. Ameliorative effect of curcumin against cadmium-induced hepatotoxicity in rats. *Int J Phytopharmacol* 2014;5:394-402.
42. Newairy A-SA, Salama AF, Hussien HM, Yousef MI. Propolis alleviates aluminium-induced lipid peroxidation and biochemical parameters in male rats. *Food Chem Toxicol* 2009;47:1093-98.
43. Orihuela D, Meichtry V, Prego N, Pizarro M. Short-term oral exposure to aluminium decreases glutathione intestinal levels and changes enzyme activities involved in its metabolism. *J inorg biochem* 2005;99:1871-78.
44. Bano M, Bhatt DK. Ameliorative effect of a combination of vitamin E, vitamin C, α -lipoic acid and stilbene resveratrol on lindane induced toxicity in mice olfactory lobe and cerebrum. *Indian J Exp Biol* 2010;48:150-58.
45. Tarasub N, Junseecha T, Tarasub C, Ayutthaya WDN. Protective effects of curcumin, vitamin C, or their combination on cadmium-induced hepatotoxicity. *J basic clin pharm* 2012;3:273.
46. Sharma D, Sethi P, Hussain E, Singh R. Curcumin counteracts the aluminium-induced ageing-related alterations in oxidative stress, Na⁺, K⁺ ATPase and protein kinase C in adult and old rat brain regions. *Biogerontol* 2009;10:489-502.
47. Gaskill C, Miller LM, Mattoon J, Hoffmann W, Burton SA, Gelens HC, et al. Liver histopathology and liver and serum alanine aminotransferase and alkaline phosphatase activities in epileptic dogs receiving phenobarbital. *Vet Pathol* 2005;42:147-60.
48. Hassoun E, Stohs S. Comparative studies on oxidative stress as a mechanism for the fetotoxic of TCDD, endrin and lindane in C57BL/6j and DBA/2j mice. *Teratol* 1995;51:186.
49. Granados-Castro LF, Rodríguez-Rangel DS, Fernández-Rojas B, León-Contreras JC, Hernández-Pando R, Medina-Campos ON, et al. Curcumin prevents paracetamol-induced liver mitochondrial alterations. *J Pharm Pharmacol* 2016;68:245-56.
50. Cherroret G, Capolaghi B, Hutin M-F, Burnel D, Desor D, Lehr P. Effects of postnatal aluminum exposure on biological parameters in the rat plasma. *Toxicol Let* 1995;78:119-25.

51. Chang D-M. Curcumin: a heat shock response inducer and potential cytoprotector. *Crit Care Med* 2001;29:2231-2.
52. El-Desoky G, Abdel-Ghaffar A, Al-Othman Z, Habila M, Al-Sheikh Y, Ghneim H, et al. Curcumin protects against tartrazine-mediated oxidative stress and hepatotoxicity in male rats. *Europ Rev Med Pharm Sci* 2017;21:635-45.