

Antioxidant and protective effect of hydroalcoholic extract of *Celtis australis* L. on CCl₄ induced hepatotoxicity

Mohammad Shokrzadeh^{1,2}, Hossein bakhshi jouybari^{3,4}, Majedeh Hosseinpour⁴, Ali ziar⁴, Emran Habibi^{2,3*}

¹Department of Toxicology and Pharmacology, Faculty of Pharmacy, Mazandaran University of Medical Sciences, Sari, Iran

²Pharmaceutical Sciences Research Center, Mazandaran University of Medical Sciences, Sari, Iran

³Department of Pharmacognosy and Biotechnology, Faculty of Pharmacy, Mazandaran University of Medical Sciences, Sari, Iran

⁴Student Research Committee, Faculty of Pharmacy, Mazandaran University of Medical Sciences, Sari, Iran

ARTICLE INFO

*Corresponding author:

emrapharm@yahoo.com

Article history:

Received: May 28, 2018

Accepted: Sep 11, 2018

Keywords:

Celtis australis,
CCl₄,
Liver,
Antioxidant,
Toxicity

ABSTRACT

Several human diseases including cancer, rheumatoid arthritis, and neurodegenerative and hepatic diseases are related to the destructive effect of reactive oxygen species (ROS). Antioxidants may provide a possible solution to this problem. This study was carried out to investigate the effect of hydroalcoholic extract of *Celtis australis* on CCl₄ induced hepatotoxicity in mice. The antioxidant activity of *C. australis* was evaluated by 2,2-diphenyl-1-picrylhydrazyl (DPPH) radical scavenging assay. For evaluation of hepatoprotective activity of the extract, the animals were pretreated with 200 and 400 mg/kg of *C. australis* extract intraperitoneally for 7 days and then received CCl₄ (0.5 ml/kg in olive oil). Liver injury was determined by serum biochemical parameters such as Alanine aminotransferase (ALT), Aspartate aminotransferase (AST), Alkaline phosphatase (ALP), glutathione contents of liver tissue, and histopathological studies. A significant reduction in the serum biochemical parameters was observed when compared to the CCl₄ receiving group. The standard antioxidant used in the study was ascorbic acid. *C. australis* extract significantly suppressed the increase in plasma activities of liver enzymes and effectively protected animals against CCl₄-induced hepatic tissue damages. This study confirmed the hepatoprotective effect of the hydroalcoholic extract of *C. australis*.

Citation: Pharm Biomed Res 2018;4(3): 26-31.

Introduction

The liver has multifunctional roles in the body like detoxification and deposition of endogenous and exogenous substances; its function may readily be damaged by viruses, hepatotoxins, and xenobiotics (solvents and drugs)(1). Oxidative damage caused by free radicals is a common mechanism of hepatotoxicity (2). Carbon tetrachloride (CCl₄) is an industrial solvent that is used for induction of liver toxicity in animal models. In fact, liver injury induced by CCl₄ depends on its metabolism by drug metabolizing enzymes located in the endoplasmic reticulum to highly reactive trichloromethyl (CCl₃) and trichloromethyl peroxy radicals (OOCCl₃). These free radicals react with unsaturated fatty acids of phospholipids present in the cell membrane. Products of lipid peroxidation attack biomolecules in the liver cells, which causes cell injury (3). Antioxidant compounds reduce the action of reactive species (ROS) in damaged tissues during the recovery process and detoxify the physiological system (4). Nowadays, antioxidant agents of natural origin and medicinal plants have attracted special interest (5, 6). *Celtis australis* L. commonly called nettle tree or European hackberry (family: Cannabaceae) is an up to 25 m high tree found across southern Europe and western Asia. Traditionally the plant is used in the treatment of diarrhea, dysentery, peptic ulcers, colds, amenorrhea, menorrhagia, intermenstrual bleeding, and

colic (7, 8). Occurrence of some flavonoids (vitexin and isovitexin), triterpenoids, and tannins was reported in this plant (9-11). In earlier reports, the methanolic leaf extract was proven to have antimicrobial (12), antioxidant, and cytotoxic effects (13). Yet systemic pharmacological studies for its use in liver diseases have not been reported. So this study was taken up to investigate the hepatoprotective activity of *C. australis* on CCl₄ induced hepatotoxicity in mice.

Materials and Methods

Chemicals

Carbon tetrachloride, 5,5-Dithiobis-(2- nitrobenzoic) (DTNB), glutathione (GSH), and ascorbic acid were obtained from Merck (Darmstadt, Germany). 1,1-diphenyl-2-picrylhydrazyl (DPPH) was purchased from Sigma, Chemicals Co. (St Louis, MO, USA). ALT, AST, and ALP kits were obtained from Biolabo, France. All other chemicals used were of analytical grade.

Preparation of the extract of *C. australis* (ECA)

The leaves of *C. australis* L. were collected from native species growing in the Caspian Hyrcanian forests of Hezarjarib region, Neka, Mazandaran, Iran. The plants have been identified taxonomically and authenticated by Dr. Masoud Azadbakht, assistant professor, Department of Botany, Senna University, Sari, Mazandaran, Iran.

Voucher specimens of the plants were deposited in the Herbarium of Faculty of Pharmacy, Mazandaran University of Medical Sciences, Iran (voucher no. E1-14-121).

Freshly collected leaves were shade dried and made into coarse powder. The powder was successively extracted using the maceration method with ethanol 70 % (V/V) (3 times, 48 hr). Finally, the fluid extract was filtered and concentrated under reduced pressure by a rotatory evaporator apparatus, dried with a freeze dryer, and stored in a well-closed pot until used for the experiments. The extraction (ECA) yield was 19.6%.

Preliminary phytochemical screening

The hydroalcoholic extract of *C. australis* was screened for the presence of various phytochemicals including alkaloids, sterols, triterpenoids, saponins, anthraquinone glycosides, tannins, and flavonoids (14).

Determination of phenolic contents

The amount of total phenol of hydroalcoholic extract of *C. australis* was determined by the Folin-Ciocalteu method. 0.1 ml of the sample solution was mixed with 0.25 ml, 1 N Folin reagent. After 5 min, 1.25 ml, 20% sodium carbonate solution was added and shaken vigorously. The absorbance of samples was measured at 725 nm after 40 min incubation at room temperature with a double beam Perkin Elmer UV/Visible spectrophotometer. A calibration curve was obtained by standard concentrations of gallic acid. The total phenolic content was expressed as equivalents of gallic acid (15).

Determination of flavonoids contents

The total flavonoid content was determined by the aluminum chloride method. 0.5 ml of methanolic sample solution was mixed with 1.5 ml methanol, 0.1 ml of 10% aluminum chloride in methanol, 0.1 ml of 1 M potassium acetate, and 2.8 ml of distilled water. After 30 min incubation at room temperature, the absorbance of samples was measured at 415 nm. A calibration curve was prepared by standard concentrations of a methanolic solution of quercetin. The total flavonoid content was expressed as equivalents of quercetin (16).

DPPH-free radical scavenging activity

DPPH (2,2-diphenyl-1-picrylhydrazyl) is a stable radical, which was used for determination of free radical scavenging activity of CCFE. Each dose of extract and standard sample was mixed with a methanolic solution of DPPH, then mixtures were incubated at room temperature in the dark for 30 min, and the absorbance was measured at 517 nm. Ascorbic acid was used as a standard and methanolic solution of DPPH as a negative control. Radical scavenging activity was calculated by the following formula:

$((A_c - A_s)/A_c) \times 100$. Where A_c and A_s are absorbance of control and sample, respectively. IC_{50} , the concentration

of the sample which is required to scavenge 50% of DPPH free radical was calculated finally(17).

Reducing ability (FRAP assay)

The determination of total antioxidant activity was done by the FRAP assay (ferric reducing ability), with the slow modification of the Benzie and Strain method (18). The FRAP colorimetric method is based on reduction of Fe (III). Reduction of colorless ferric-tripyridyltriazine produces a blue-colored complex (ferrous-tripyridyltriazine). The working FRAP reagent was prepared daily by mixing 10 volumes of 300 mM acetate buffer (3.1 g $C_2H_3NaO_2 \cdot 3H_2O$ and 16 ml $C_2H_4O_2$), pH 3.6, with 1 volume of 10 mM TPTZ (2, 4, 6-tripyridyl-s-triazine) solution in 40 mM HCl and 1 volume of 20 mM $FeCl_3 \cdot 6H_2O$ solution. Plant extracts (150 μ l) were allowed to react with 2850 μ l of the FRAP solution for 30 min at 37°C in the dark. Absorbance was measured at 593 nm. Results were expressed as μ M Fe (II)/g dry mass and compared with quercetin and ascorbic acid.

Experimental animals

Animals were obtained from the Institute of Experimental Animal Research, Mazandaran, Iran. 8–10 week old mice weighing 20–25 g were used. All mice were maintained under standard conditions (12/12 hr light/dark cycles at room temperature) and fed rodent pellet and tap water. This study was approved by the Ethical Committee of Mazandaran University of Medical Sciences (ID: IR. MAZUMS. REC. 1394. 1441)

Induction of liver injury

Male mice were divided into five groups consisting of six animals in each group. Liver injury was induced in mice by intraperitoneal (i.p) injection of CCl_4 (0.5 ml/kg) dissolved in equal volume of olive oil(19). The extract treatment was started 7 days prior to CCl_4 administration and continued till the end of the experiment. Animals were grouped as follows: Group I, treated with olive oil (vehicle) used as normal group.

Group II, treated with single dose CCl_4 , i.p. (48 hr prior to sacrifice) and served as the disease control group
Groups III and IV, treated with hydroalcoholic extract of *C. australis* suspended in 0.5% Tween-80 and normal saline at doses of 200 and 400 mg/kg daily, respectively for 5 days followed by CCl_4 on day 5.

Group V, treated with ascorbic acid (500 mg/kg) (20) daily for 5 days followed by CCl_4 on day 5.

Assessment of hepatotoxicity

At 48 hr after CCl_4 injection all animals were anesthetized and then blood samples were collected from the carotid artery and serum was separated by centrifugation of blood at a speed of 2000 rpm for 10 min for determination of activities of various serum liver damage enzymes such as alanine aminotransferase

(ALT), aspartate aminotransferase (AST), and alkaline phosphatase (ALP). For the estimation of ALT and AST activities in serum samples, commercially available enzymatic kits (based on the reaction of 2,4-dinitrophenylhydrazine with pyruvate and/or oxaloacetate to yield a brown-colored complex in an alkaline medium) were used. Serum ALP activity was evaluated using the spectrophotometric method. Above biochemical parameters were expressed as U/L (21, 22).

Reduced glutathione (GSH) level

The livers were removed immediately, washed with normal saline and a 50% homogenate prepared in 0.05 M sodium phosphate buffer (pH 7.0). The homogenate was centrifuged at 700 x g for 10 min at 4°C and the supernatant was used for the estimation of GSH. Ellman's reagent (5,5'-Dithiobis (2-nitrobenzoic acid) solution) was added to the sample. The absorbance of the sample was recorded at 417 nm and finally GSH level expressed as $\mu\text{mol/g}$ (23).

Histological analysis

At first, the liver tissue was fixed in buffered formalin and embedded in paraffin. Then cut into thin sections of 4 μm thickness. Sections were then deparaffinized and stained with hematoxylin and eosin (H&E) for examination by a light microscope. Slides were viewed and photographed using a camera microscope (Labomed, LX400).

Statistical analysis

All values for biochemical parameters and *in vitro* antioxidant studies were expressed as mean \pm SEM (standard error of mean) and analyzed by one-way analysis of variance (ANOVA) and TUKEY's test using SPSS16 software. $p < 0.05$ was considered significant. All measurements were replicated 3 times.

Results

The preliminary phytochemical screening of hydro-alcoholic extract of *C. australis* leaves revealed the presence of flavonoids, triterpenoids, saponins, sterols, tannins, loss of anthraquinone glycosides, and alkaloids.

Total phenolic and flavonoid content

Total phenolic and flavonoid content of hydroalcoholic extract of *C. australis* leaves were expressed as mg of gallic acid and quercetin/ g dry extract, and determined from the standard curves with the equations below respectively: ($y=0.006x+0.039$, $r^2=0.996$) and ($y=0.1106x$, $r^2=0.993$), respectively. The hydro-alcoholic extract exhibited high phenol with concentration resulted 109.4 mg gallic acid/g dry extract) and flavonoid (8.2 mg quercetin/g dry extract) content.

Antioxidant properties

The DPPH radical scavenging activity of hydroalcoholic extract of *C. australis* was measured by the

spectrophotometric method and the IC_{50} value was calculated using the regression line equation and compared with the standard (ascorbic acid). The mean IC_{50} value of ascorbic acid was $14.3 \pm 1.08 \mu\text{g/ml}$ and the mean IC_{50} value of hydroalcoholic extract of *C. australis* was $80.5 \pm 1.73 \mu\text{g/ml}$. The reducing ability and antioxidant potentials of the methanol extracts of the leaves of *C. australis* were estimated from their ability to reduce the TPTZ-Fe (III) complex to TPTZ-Fe (II) and $595.98 \mu\text{m Fe (II)/g}$. The FRAP values for the methanol extracts of the leaves of *C. australis* were significantly lower than those of ascorbic acid ($1382.98 \mu\text{m Fe (II)/g}$) and quercetin ($895.98 \mu\text{m Fe (II)/g}$).

Effects of extracts on AST, ALT, ALP, and GSH

The data outlined in Table 1, shows that all biochemical parameters (serum ALT, AST, and ALP activities) were raised significantly ($P < 0.001$) in CCl_4 alone receiving animals compared to the Olive oil (control) group, which indicates acute hepatocellular damage. Also, groups that received ECA (200 mg/kg and 400 mg/kg) followed by CCl_4 injection, and the group that received ascorbic acid (500 mg/kg) then CCl_4 showed significant decrease ($P < 0.001$) in all serum enzymes compared to the CCl_4 alone group. In this study, effects of CCl_4 on the liver tissue when compared with normal revealed a significant decrease ($P < 0.001$) in the reduced glutathione activity. Also, the maximum effect was observed after 5 days pretreatment with 400 mg/kg ECA, when GSH content in liver tissues was significantly ($P < 0.001$) higher ($107.01 \pm 5.51 \mu\text{mol/g}$) than those of the CCl_4 alone treated mice (Table 1). The data clearly show that pretreatment with ECA resulted in significant ($P < 0.001$) dose-dependent alterations of the biochemical parameter levels induced by CCl_4 as reported in Table 1.

Histopathological observations

Results of histopathological studies provided supportive evidence for biochemical analysis.

The liver section of the normal animals exhibited normal cellular architecture with actual cytoplasm, prominent nucleus, distinct central vein, and hepatic lobules without any fatty changes or necrosis (Figure 1A). Histology of liver section of CCl_4 treated mice determined hepatic cells with serious toxicity defined by thorough loss of hepatic architecture with intense peripheral and central vein necrosis, apoptosis, vacuolization of cytoplasm, centrilobular fatty degeneration and congestion of hepatocyte sinusoids (Figure 1B). Histological section of the liver treated with standard ascorbic acid exhibited normal architecture without any fatty changes as shown in Figure 1C. Treatment with a low dose of methanolic extract (200 mg/kg) displayed swelling of hepatocyte, hepatocyte atrophy, degeneration of hepatocytes, proliferation of Kupffer cells, and mild fatty changes with central vein damage (Figure 1D) whereas high dose of methanolic extracts of *C. australis* showed normal

Table 1 Effect of hydroalcoholic extract of *C. australis* on mice serum enzymes and GSH of the liver after CCl₄ administration^a

Groups/Parameter	ALT (U/L)	AST (U/L)	ALP (U/L)	GSH (μmol/g)
olive oil (control)	61.00±0.58***	117.00±1.15***	146.08±2.08***	137.34±3.18***
only CCl ₄	78.33±2.33###	152.33±1.21###	199.67±1.45###	59.67±4.06###
ECA 200 mg/kg+CCl ₄	70.34±0.88#####	139.67±0.88#####	175.34±2.73#####	78.00±1.53###
ECA 400 mg/kg+CCl ₄	68.66±1.21***	132.34±1.45#####	166.33±1.68#####	107.01±5.51#####
ascorbic acid 500 mg/kg+ CCl ₄	64.00±0.57***	123.00±1.15***	150.68±2.96***	121.34±3.18***

^a Values are the mean ± S.E, n = 6, *** Significance $P \leq 0.001$ compared to CCl₄ control, ### Significance $P \leq 0.001$ compared to Olive oil control.

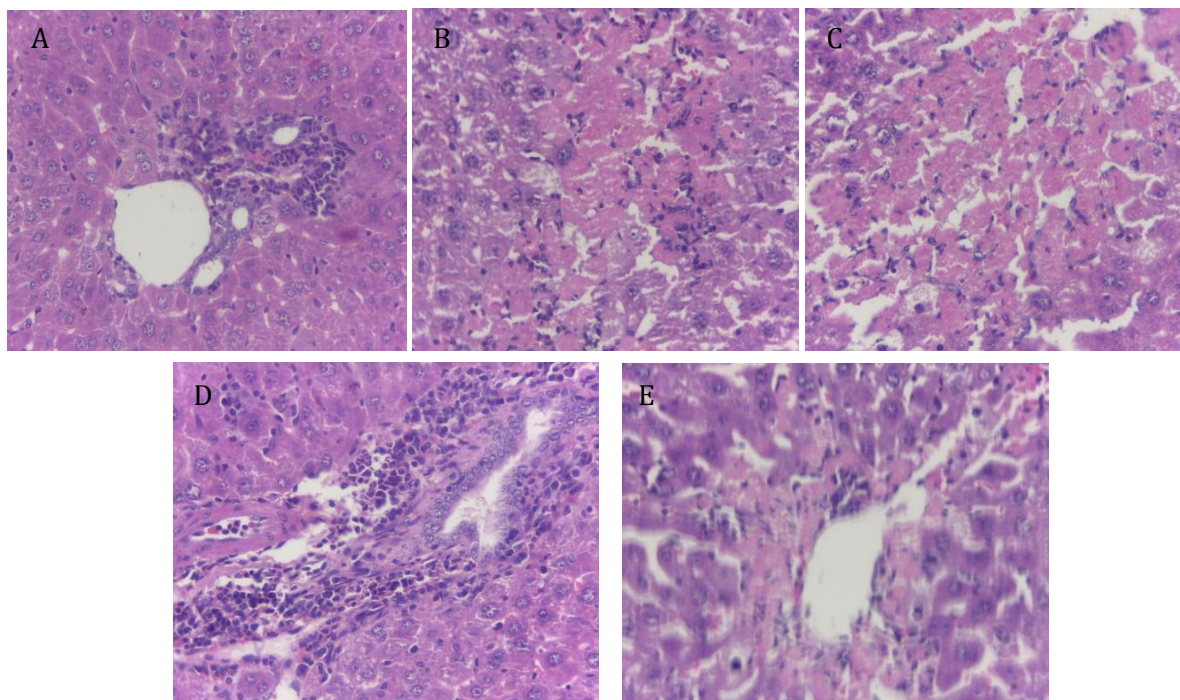


Figure 1 (A): Liver sections of normal control mice exhibiting normal hepatic cells with well-preserved cytoplasm, prominent nucleus, normal central vein and lobules without any fatty damages or necrosis. (B): Liver section of mice treated with CCl₄ showing hepatic cells with serious toxicity defined by thorough loss of hepatic architecture and intense peripheral and central vein necrosis, apoptosis, vacuolization of cytoplasm, centrilobular fatty degeneration, and congestion of hepatocyte sinusoids. (C): Histological liver sections of mice treated with standard ascorbic acid showing normal cells without any fatty changes. (D): Treatment with a low dose of methanolic extract (200 mg/kg) displaying swelling of hepatocytes, hepatocyte atrophy, degeneration of hepatocytes, proliferation of Kupffer cells, and mild fatty changes with central vein damage. (E): High dose of methanolic extracts of *C. australis* showing normal hepatic architecture only with a moderate accumulation of fatty lobules.

hepatic architecture only with moderate accumulation of fatty lobules (Figure 1E).

Discussion

Liver toxicity is a prevalent disorder resulting in serious weakness ranging from severe metabolic disease to

some fatal illnesses. It is a serious challenge to global public health. In modern medical practice, liver-protective drugs are insufficient and sometimes cause serious health problems. Therefore, nowadays herbal remedies have gained much consideration for treating liver diseases due to fewer side effects and more

effectiveness (24). Many of the medicinal plants were examined for their potential antioxidant and protective effects in liver damaged experimental animal models and revealed that hepatoprotective effect of these plants may be related to the existence of various compounds such as polyphenols, flavonoids, terpenoids, coumarins, alkaloids, and phytosterols, which act as antioxidants and free radical scavengers (25). Indeed natural product roles in oxidative stress have two aspects: enhancing the activity of original natural antioxidants like GSH and neutralizing reactive oxygen species by nonenzymatic mechanisms (26). So, with this objective, *C. australis* L like other species of this genus was investigated for its useful role against experimentally induced liver injury in mice due to the presence of high total phenols, flavonoids, triterpenoids, saponins, sterols, and tannins (27, 28). Liver damages are related to oxidative stress. Exposure of hepatocytes to CCl_4 leads to central venous necrosis and steatosis due to the predominant formation of CCl_3^\bullet and CHCl_2^\bullet free radicals, which results in lipid peroxidation and cell destruction (29). In this study, liver damage induced by CCl_4 in mice was determined based on significant raises in ALT, AST, and ALP, which resulted from cell membrane and mitochondrial damage in liver cells and also histopathological observations that are similar to the earlier studies (30, 31). One of the most important factors in a plant for protecting the liver is the ability of its chemical compounds and secondary metabolites to inhibit the aromatase activity of cytochrome P-450, favoring the regeneration of the liver. Therefore, it is suggested that flavonoids in *C. australis* could be a factor facilitating its liver-protective action via inhibition of cytochrome P-450 aromatase (32).

Also, previous studies suggest that antioxidative compounds like phenols and flavonoids may have a protective effect against hepatocellular toxicity by inhibition of lipid peroxidation and protection of glutathione depletion (33, 34). Some flavonoid C-glycosides have been reported from leaves of the *Celtis* species. Isovitexin, 2"-a-L-rhamnopyranosyl-7-O-methylvitexin, cytoside, and 2"-a-L-rhamnopyranosylvitexin were isolated from *C. australis* L. Rich flavone C-glycosides extracts of some plants and isolated flavone C-glycosides showed significant antioxidant and hepatoprotective activity (35).

In this study, ascorbic acid was used as a standard liver-protective agent. Upon treatment with ascorbic acid, all increased biochemical parameters by CCl_4 were reversed back to normal. Earlier findings indicate that ascorbic acid shows appropriate hepatoprotective and antioxidant potential against hepatocellular damage in experimental animal models (36, 37). Administration of *C. australis* extract in high and low dose to mice caused a decrease in the activity of the biochemical parameters of the liver, which may be a result of the stabilization of the cell membrane as well as modification of hepatic tissue damage induced by CCl_4 . It is believed that serum levels of transaminases are normalized with healed

parenchyma and regeneration of hepatocytes (38). In this study, pre-treatment of animals with *C. australis* extracts exhibited an amelioration in liver enzymes, and their tendency to return towards a near normal level proposed that the plant was a suitable hepatoprotectant. Observations and histopathological changes in the liver sections of different treatment groups support this finding.

The results of the present study suggest that hydroalcoholic extract of *C. australis* has hepatoprotective activity that is related to glutathione-mediated detoxification as well as free radical scavenging (antioxidant activity). Its membrane stabilizing effect on hepatic cells may be connected with its phenols, flavonoids, alkaloids, and tannins content. Further study on the leaves of *C. australis* could be undertaken for the isolation and purification of active components.

Conflicts of interest

Authors declare no conflicts of interest.

References

1. Sabiu S, Sunmonu TO, Ajani EO, Ajiboye TO. Combined administration of silymarin and vitamin C stalls acetaminophen-mediated hepatic oxidative insults in Wistar rats. *Rev Bras Farmacogn* 2015;25:29-34.
2. Sasidharan S, Aravindran S, Latha LY, Vijenthir R, Saravanan D, Amutha S. In vitro antioxidant activity and hepatoprotective effects of *Lentinula edodes* against paracetamol-induced hepatotoxicity. *Molecules* 2010;15:4478-89.
3. Yang XJ, Liu J, Ye LB, Yang F, Ye L, Gao J-R, et al. In vitro and in vivo protective effects of proteoglycan isolated from mycelia of *Ganoderma lucidum* on carbon tetrachloride-induced liver injury. *World J Gastroentero* 2006;12:1379-85.
4. Kinoshita S, Inoue Y, Nakama S, Ichiba T, Aniya Y. Antioxidant and hepatoprotective actions of medicinal herb, *Terminalia catappa* L. from Okinawa Island and its tannin corilagin. *Phytomed* 2007;14:755-62.
5. Naidu V, Atmakur H, Katragadda SB, Devabakthuni B, Kota A, Kuncha M, et al. Antioxidant, hepatoprotective and cytotoxic effects of icetexanes isolated from stem-bark of *Premna tomentosa*. *Phytomed* 2014;21:497-505.
6. Harish R, Shivanandappa T. Antioxidant activity and hepatoprotective potential of *Phyllanthus niruri*. *Food chem* 2006;95:180-5.
7. Zehrmann N, Zidorn C, Ganzera M. Analysis of rare flavonoid C-glycosides in *Celtis australis* L. by micellar electrokinetic chromatography. *J Pharmaceut Biomed* 2010;51:1165-8.
8. Demir F, Doğan H, Özcan M, Haciseferoğullari H. Nutritional and physical properties of hackberry (*Celtis australis* L.). *J Food Eng* 2002;54:241-7.
9. El-Alfy TS, El-Gohary H, Sokkar NM, Hosny M, Al-Mahdy DA. A New Flavonoid C-Glycoside from *Celtis australis* L. and *Celtis occidentalis* L. Leaves and Potential Antioxidant and Cytotoxic Activities. *Sci Pharm* 2011; 79:963-75.
10. Spitaler R, Gurschler S, Ellmerer E, Schubert B, Sgarbossa M, Zidorn C. Flavonoids from *Celtis australis* (Cannabaceae). *Biochem Syst Ecol* 2009;37:120-1.
11. Badoni R, Kumar Semwal D, Rawat U, Singh Maniyari Rawat M. Chemical Constituents from Fruits and Stem Bark of *Celtis australis* L. *Helv Chim Acta* 2011;94:464-73.
12. Badoni R, Semwal D, Rawat U. Fatty acid composition and antimicrobial activity of *Celtis australis* L. fruits. *J Sci Res* 2010;2:397-402.
13. El-Alfy TS, El-Gohary H, Sokkar NM, Hosny M, Al-Mahdy DA. A new flavonoid C-glycoside from *Celtis australis* L. and *Celtis*

- occidentalis L. leaves and potential antioxidant and cytotoxic activities. *Sci Pharma* 2011;79:963-75.
14. Bhandary SK, Kumari S, Bhat VS, Sharmila K, Bekal MP. Preliminary phytochemical screening of various extracts of *Punica granatum* peel, whole fruit and seeds. *J Health Sci* 2012;2:35-8.
 15. Makkar H. Quantification of tannins in tree foliage—a laboratory manual, a Joint FAO. IAEA working document, Vienna, Austria. 2000.
 16. Ghasemi K, Ghasemi Y, Ebrahimzadeh MA. Antioxidant activity, phenol and flavonoid contents of 13 citrus species peels and tissues. *Pak J Pharm Sci* 2009;22:277-81.
 17. Pothitirat W, Chomnawang MT, Supabphol R, Gritsanapan W. Free radical scavenging and anti-acne activities of mangosteen fruit rind extracts prepared by different extraction methods. *Pharm Biol* 2010;48:182-6.
 18. Benzie IF, Strain JJ. The ferric reducing ability of plasma (FRAP) as a measure of “antioxidant power”: the FRAP assay. *Anal Biochem* 1996;239:70-6.
 19. Eidi A, Moghadam JZ, Mortazavi P, Rezazadeh S, Olamafar S. Hepatoprotective effects of *Juglans regia* extract against CCl₄-induced oxidative damage in rats. *Pharm Biol* 2013;51:558-65.
 20. Ajayi G, Adeniyi T, Babayemi D. Hepatoprotective and some haematological effects of *Allium sativum* and vitamin C in lead-exposed wistar rats. *Interl J Med and Medic Sci* 2009;1:64-7.
 21. Reitman S, Frankel S. A colorimetric method for the determination of serum glutamic oxalacetic and glutamic pyruvic transaminases. *Ame j C Pathol* 1957;28:56-63.
 22. Ahmadi A, Ebrahimzadeh MA, Ahmad-Ashrafi S, Karami M, Mahdavi MR, Saeedi Saravi SS. Hepatoprotective, antinociceptive and antioxidant activities of cimetidine, ranitidine and famotidine as histamine H₂ receptor antagonists. *Fundam Clin Pharmacol* 2011;25:72-9.
 23. Ellman M. A spectrophotometric method for determination of reduced glutathione in tissues. *Analyt Biochem* 1959;74:214-26.
 24. Ahsan MR, Islam KM, Bulbul IJ, Musaddik MA, Haque E. Hepatoprotective activity of methanol extract of some medicinal plants against carbon tetrachloride-induced hepatotoxicity in rats. *Eur J Sci Res* 2009;37:302-10.
 25. Asadi-Samani M, Kafash-Farkhad N, Azimi N, Fasihi A, Alinia-Ahandani E, Rafeian-Kopaei M. Medicinal plants with hepatoprotective activity in Iranian folk medicine. *Asian Paci J Tropic Biomed* 2015;5:146-57.
 26. Zhu YZ, Huang SH, Tan BKH, Sun J, Whiteman M, Zhu YC. Antioxidants in Chinese herbal medicines: a biochemical perspective. *Nat Prod Rep* 2004;21:478-89.
 27. Ahmed E, Arshad M, Bibi Y, Ahmed MS. Phytochemical and antioxidant potential of crude methanolic extract and fractions of *Celtis eriocarpa* Decne. Leaves from lesser Himalaya region of Pakistan. *Pak J Bot* 2018;50:279-85.
 28. Geidam MA, Adole OS. Effects of The Aqueous Ethanolic Leaves Extract of *Celtis Integrifolia* On Liver Function of Wister Strain Albino Rats. *Inter J sci res manag* 2014;2:713-8.
 29. Boll M, Lutz W, Becker E, Stampfl A. Mechanism of carbon tetrachloride-induced hepatotoxicity. Hepatocellular damage by reactive carbon tetrachloride metabolites. *Z Naturforschung C* 2001;56:649-59.
 30. Venkatakishore T, Rao MP, Thulasi B, Durga PK, Harikrishna B, Prasanth SS. Hepatoprotective activity of ethanolic extract of aerial part of *Gymnema Sylvestre* againsts CCl₄ and paracetamol induced hepatotoxicity in rats, world. *J Biomed Pharm Sci* 2016;5:1007-16.
 31. Go J, Kim JE, Koh EK, Song SH, Sung JE, Lee HA, et al. Protective effect of gallotannin-enriched extract isolated from *Galla Rhois* against CCl₄-induced hepatotoxicity in ICR mice. *Nutrients* 2016;8:107.
 32. Kowalska M, Brandt M, Puett D. Inhibition of cytochrome P-450 aromatase activity by plant extracts. *Planta medica*. 1990;56:675
 33. Oh H, Kim D-H, Cho J-H, Kim Y-C. Hepatoprotective and free radical scavenging activities of phenolic petrosins and flavonoids isolated from *Equisetum arvense*. *J Ethnopharmacol* 2004;95:421-4.
 34. Wu Y, Wang F, Zheng Q, Lu L, Yao H, Zhou C, et al. Hepatoprotective effect of total flavonoids from *Laggera alata* against carbon tetrachloride-induced injury in primary cultured neonatal rat hepatocytes and in rats with hepatic damage. *J Biomed Sci* 2006;13:569-78.
 35. Xiao J, Capanoglu E, Jassbi AR, Miron A. Advance on the flavonoid C-glycosides and health benefits. *Crit rev food sci* 2016;56:29-45.
 36. Al-Attar AM. Hepatoprotective Influence of Vitamin C on Thioacetamide—induced Liver Cirrhosis in Wistar Male Rats. *J Pharmacol Toxicol* 2011;6:218-33.
 37. Bashandy S, AlWasel S. Carbon tetrachloride-induced hepatotoxicity and nephrotoxicity in rats: Protective role of vitamin C. *J Pharmacol Toxicol* 2011;6:283-92.
 38. Jain S, Dixit VK, Malviya N, Ambawatia V. Antioxidant and hepatoprotective activity of ethanolic and aqueous extracts of *Amorphophallus campanulatus* Roxb. tubers. *Acta Pol Pharm* 2009;66:423-8.