

Original Article:

Protective Effect of Curcumin on the Density of Hippocampal Dark Neurons in Mice Model of Aging Induced by D-Galactose: A Histopathological Study



Zahra Heidari¹ , Shabnam Mohammadi^{1*} , Mahdieh Yousefi Taba¹

1. Department of Anatomy and Cell Biology, Faculty of Medicine, Mashhad University of Medical Sciences, Mashhad, Iran.

* Corresponding Author:

Shabnam Mohammadi, PhD.

Address: Department of Anatomy and Cell Biology, Faculty of Medicine, Mashhad University of Medical Sciences, Mashhad, Iran.

Phone: +98 (51) 38002459

E-mail: mohammadish@mums.ac.ir

Copyright© 2019, ASP Ins. This open-access article is published under the terms of the Creative Commons Attribution-NonCommercial 4.0 International License which permits Share (copy and redistribute the material in any medium or format) and Adapt (remix, transform, and build upon the material) under the Attribution-NonCommercial terms.

Article info:

Received: 11 Aug 2019

Accepted: 15 Dec 2019

Keywords:

Ageing, Hippocampus, Neuron

ABSTRACT

Background: Curcumin is the most active ingredient in turmeric root of *Curcuma longa* of the Zingiberaceae family and has a potent antioxidant activity. This study aimed at investigating the effects of curcumin with various doses on the density of dark neurons in the hippocampus of induced D-galactose aging mice model. This experimental study was conducted on 40 adult male BALB/c mice.

Materials and Methods: We randomly divided animals into 5 groups: D-galactose, control, and curcumin 1, curcumin 2, and curcumin 3 groups. D-galactose (300 mg/kg) was intraperitoneally injected into the D-galactose group for 6 weeks. D-galactose and doses of 25, 50, and 100 mg of curcumin were administered, respectively, to the curcumin groups 1-3 every day for 14 days. After 6 weeks, the mice's brains were stained with toluidine blue after tissue passage. Then, the mean dark neuron volume density in each unit of the tissue was assessed using stereological formulas. The obtained data were analyzed by Analysis of Variance (ANOVA) in SPSS.

Results: Compared with the control group, the average number of dark neurons in the hippocampus significantly increased following the administration of D-galactose ($P=0.001$). The average dark neurons frequency in the hippocampus significantly decreased in the 50 and 100 mg/kg curcumin-treated groups ($P=0.001$ for both) compared to that of the D-galactose treated animals.

Conclusion: The results of this study showed that treatment with 100 mg/kg of curcumin reduced the number of dark neurons in the hippocampus of the aging mice. It seems that curcumin decreases dark neurons via the reduction of apoptosis. Also, curcumin is a powerful antioxidant and affects the level of antioxidant status in the brain.

Citation Heidari Z, Mohammadi Sh, Yousefi Taba M. Protective Effect of Curcumin on the Density of Hippocampal Dark Neurons in Mice Model of Aging Induced by D-galactose: A Histopathological Study. *Pharmaceutical and Biomedical Research*. 2019; 5(4):63-68.

Introduction

Studies have shown that the appearance of dark neurons is one of the most prominent neuronal damage in diseases of the nervous system, such as epilepsy and ischemia [1-3]. These neurons are basophilic, pyknotic, with wrinkled cytoplasm and have high tissue staining ability and dense and irregular chromatin [4, 5].

Curcumin is one of the turmeric compounds extracted from the roots of *Curcuma longa* of the Zingiberaceae family. This compound is a polyphenolic substance of formula $C_{21}H_{20}O_6$, with a molecular weight of 386.376 g/mol. Curcumin is a diarylheptanoid and belongs to the group of curcuminoids. They are natural phenols responsible for turmeric's yellow color (Figure 1) [6, 7]. Curcumin is one of the most commonly used dyes in the food industry and products such as jelly, soups, ice cream, dairy, confectionery, cereals, and meat [8]. Curcumin has been approved by the FDA and has not shown any side effects (up to 6000 mg/d intake) [7].

Curcumin exhibits antioxidant, anti-mutagenic, anti-inflammatory, and antinociceptive activities. It is also used for the prevention of cancer and diabetes. Besides, it has a protective effect on neurodegenerative diseases, multiple sclerosis, and Alzheimer disease [9, 10]. The results of a study showed that curcumin administration for 6 to 24 months increased the levels of superoxide dismutase and glutathione peroxidase antioxidant enzymes. Also, pigment densities decreased lipofuscin in the cortex, cerebellum, and hippocampus compared with the control group [11].

Kumar et al. evaluated the effectiveness of curcumin for cellular senescence caused by D-galactose using a water maze. The results showed that curcumin has the therapeutic potential against premature senescence induced by D-galactose in mice and improves behavioral, motor, and antioxidant ability [12].

Another study investigated the administration of curcumin on the life span, oxidative stress, and apoptosis in the brain of transgenic Parkinsonian models. Curcumin was added to the diet at doses of 25, 50, and 100 μ mol. There was a difference in the reduction of oxidative stress and apoptosis and Parkinson symptoms as well as in the longevity of curcumin-treated flies [13]. Kanter et al. reported the positive effects of curcumin administration on reducing cell apoptosis and oxidative stress in diabetic mice [14].

In another study in 2019, the protective action of curcumin against oxidative stress conditions in rats was reported because of its antioxidant ability to quench free radicals and chelating metals as well as the regeneration of endogenous antioxidant [15].

D-galactose is a 6-carbon sugar with a group of aldehydes found naturally in the body. The byproducts of the reaction between D-galactose and galactokinase and galactose-1-phosphate uridylyltransferase enzymes would be free radicals at high concentrations. The aging model induced by D-galactose administration has been accepted as a model that causes mitochondrial dysfunction, neurotoxicity, dysfunctional immune responses, and memory loss in animals [16].

Since curcumin is a potent natural antioxidant and free radical scavenger, we decided to determine the effects of curcumin on dense hippocampal neurons of mice after inducing D-galactose aging (oxidative damage of the brain).

Materials and Methods

Study Animals

This research was an experimental study conducted on 40 adult male BALB/c mice. The Ethics Committee of Mashhad University of Medical Sciences approved the study protocol (Ethical Code: IR.MUMS.fm.REC.1396.466). The mice were housed in the Animal Laboratory of Mashhad University of Medical Sciences under a controlled 12/12 h light/dark cycle at 22° c. The animals were given standard food pellets and water ad libitum. All procedures were performed according to the 'Care and Use of Laboratory Animals' prepared by Mashhad University.

Experimental treatment

We randomly divided animals into 5 groups: D-galactose, control, and curcumin 1, curcumin 2, and curcumin 3 groups. About 300 mg/kg of D-galactose was administered intraperitoneally to the D-galactose group for

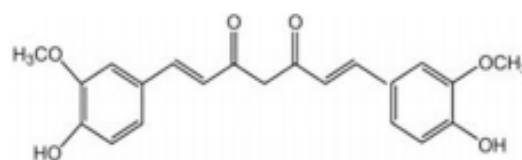


Figure 1. The chemical structure of curcumin [6]

PBR

PBR

6 weeks, whereas no treatment was considered for the control group. The curcumin at doses of 25, 50, and 100 mg were administered to curcumin groups from 1-3, respectively, for 14 days [14, 17].

Histopathological analysis

After 42 days, the mice were anesthetized by ether. Then, using scissors and sterile forceps, their brains were extracted and embedded in 10% formalin. After 72 hours, alcohol dehydration, xylene clearance, and paraffin impregnation were performed. Next, the sections were prepared from the tissues and stained with toluidine blue 1%. To make the staining solution, 1 g of toluidine blue powder was dissolved in 100 mL of alcohol 70% and placed in the refrigerator. Then, 25 mL of the dye was dissolved in 250 mL of NaCl and distilled water and passed through filter paper. Then, 5 sections of each brain were randomly selected and photographed by a computer-camera. Frames were used to count cells. This frame consists of two permitted sides and two forbidden sides. Those cells were counted that were in the frame and did not contact forbidden sides. Finally, dark neurons frequency per unit was computed, according to the Equation 1 [18].

$$1. NA = \frac{\sum Q}{a/f \times \sum P}$$

, where NA refers to the density of dark neurons per unit area, $\sum Q$ is the sum of the calculated cells, a/f refers to the area of the counting frame, and $\sum P$ denotes the sum of the approved frames hit the cross-section.

2.4. Statistical analysis

The obtained data were analyzed by analysis of variance (ANOVA) and Tukey post hoc test in SPSS. The data were represented by Mean \pm SD deviation.

3. Results

Histological findings

Figure 2 displays images of hippocampal tissue sections of the different groups. The average dark neuron frequency in the D-galactose group was 61.41 \pm 2.35 cells/mm², and in the control group, it was 29.03 \pm 2.27 cells/mm² (Figure 3).

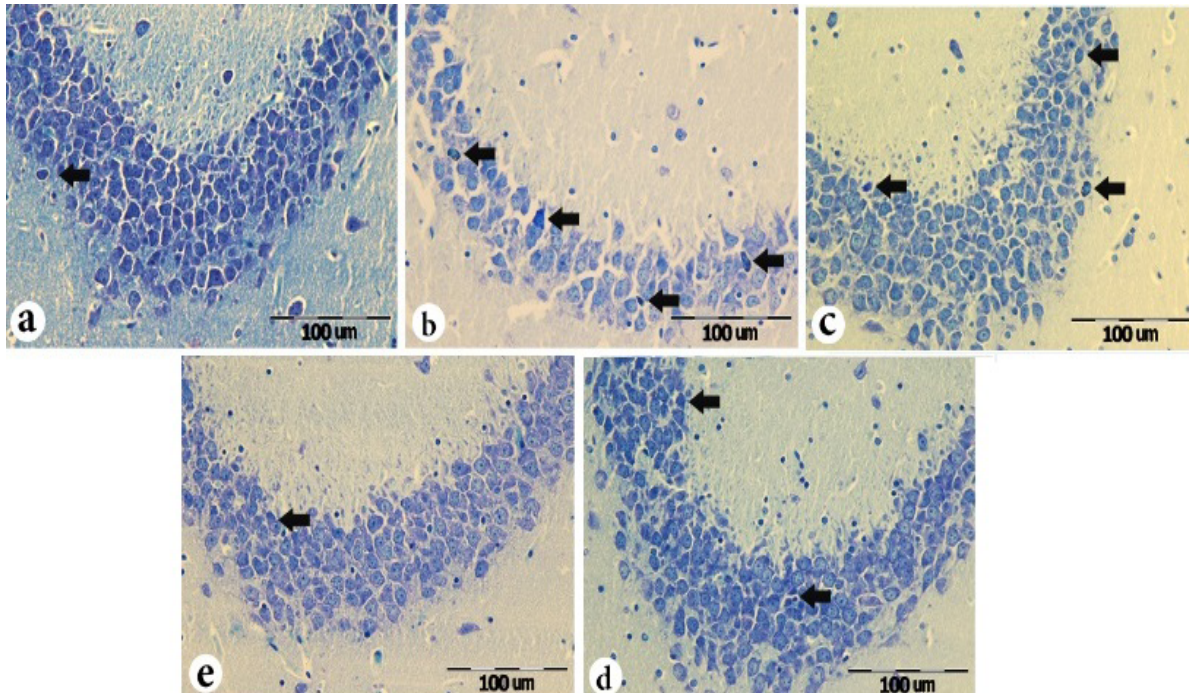


Figure 2. Coronal sections of the hippocampus in different groups

Staining: Toluidine blue (Lens 40)

Dark neurons are marked with an arrow

A. Control group; B. D-galactose group; C. Curcumin group 25 mg/kg; D. Curcumin group 50 mg/kg and E. Curcumin group 100 mg/kg
The arrow shows dark neurons.

PBR

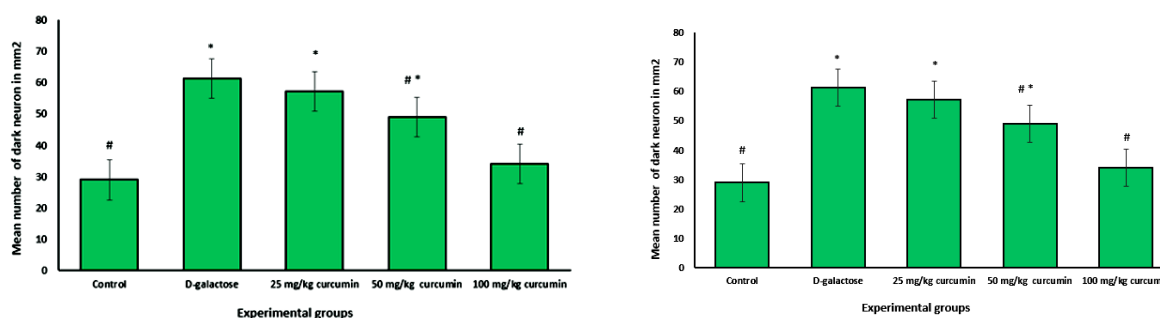


Figure 3. Comparison of mean dark neurons in the hippocampus of mice

* Significant difference from the control group based on the ANOVA and Tukey post hoc test results.

Significant difference from the D-galactose treated animals based on the ANOVA and Tukey post hoc test results.

Statistical analysis showed that the administration of D-galactose significantly increased the mean number of dark hippocampal neurons compared with the control group ($P=0.001$). In addition, curcumin treatment reduced the damage, and there was a significant reduction in the mean number of dark hippocampal neurons compared with the D-galactose group in the 50 mg/kg ($P=0.001$) and 100 mg/kg ($P=0.001$) treated groups (Figure 3).

There was a significant difference in the average dark neurons rate in the 25 and 50 mg/kg curcumin groups ($P=0.001$ for both) compared to that of the control group. Furthermore, we observed a significant difference in the average dark neurons frequency following treatment with 100 mg/kg curcumin compared with the animals treated with 25 and 50 mg/kg ($P=0.001$ for both). There was a significant difference in the average dark neurons rate in the 25 mg/kg curcumin group ($P=0.001$) compared with that of the 50 mg/kg curcumin group.

Discussion

Curcumin is an antioxidant chemical derived from *Curcuma longa* (turmeric or Curcuma). It can react directly with reactive species and upregulates many cytoprotective and antioxidant proteins [19]. Based on our findings, in comparison to the control group, D-galactose administration significantly enhanced the average dark hippocampal neurons frequency. However, treatment with curcumin (50 and 100 mg/kg) significantly reduced the dark neurons rate.

Many studies have shown that nutrition has an impact on brain structure and function. In a study, the administration of thymoquinone (black seed active ingredient) increased the number and size of hippocampal pyramidal neurons compared with the control group [20]. Dietary trace elements such as zinc and copper are important for the structure of chemical intermediates, energy metabo-

lism, and enhancing the brain's antioxidant defense [21]. Fatty acids have receptors on the nuclei of brain cells, thereby affecting gene transcription and expression [22].

In another study, curcumin administration reduced the risk of Alzheimer disease. Furthermore, curcumin administration for 6-24 months increased the level of antioxidant enzymes and decreased the density of aging pigment (lipofuscin) in the brain, cerebellum, and hippocampal cortex compared with the control group [11]. Antioxidant and anti-inflammatory properties of turmeric are effective in the improvement and prevention of cellular damage in patients with Alzheimer. Researchers believe that the positive effect of turmeric on the immune system is a significant factor in the reduction of β -amyloid plaques [10].

Additionally, Kumar et al. evaluated the effectiveness of curcumin for cellular senescence caused by D-galactose using a water maze. The rats were divided into 3 groups (curcumin, D-galactose, and galantamine) and evaluated by behavioral and motor tests. The results showed that curcumin had positive effects against early D-galactose-induced aging and improved behavioral, motor, and antioxidant potency [12].

Siddique et al. also investigated the effect of curcumin on the life span, activity pattern, oxidative stress, and apoptosis in the brain of transgenic Parkinsonian model *Drosophila*. Curcumin was administered at doses of 25, 50, and 100 μ mol for 24 days. Significant dose-related differences were reported in the reduction of oxidative stress, Parkinson, and apoptotic symptoms, as well as in the longevity of curcumin-treated flies [13]. According to Siddique's study, the antioxidant dose was also important in the present study so that the best effect was observed at 100 mg/kg. As other studies have mentioned, the dose of antioxidants is very important [13].

In 2012, Kanter et al. investigated the effect of curcumin on the reduction of testicular injury, cell apoptosis, and oxidative stress in diabetic mice. Rats in the treatment group received curcumin once daily for 8 weeks. Their results showed that curcumin treatment significantly reduced high levels of malondialdehyde and increased superoxide dismutase and glutathione peroxidase in testicular tissue. In curcumin-treated rats, a significant decrease in apoptosis and increased expression of cell nuclear antigen was observed in testicular tissue [14]. According to the present study, curcumin treatment, especially at 100 mg/kg dose, markedly reduces dark hippocampal neurons in old mice. There is not any positive control group in this study, like the agents that their anti-aging effects have been proven before, that was a weakness of this study. In addition, there is no negative control (only the solvent group).

To the best of our knowledge, no study has been published so far on the effects of curcumin on the hippocampal tissue of the aging model. In addition, the oxidative stress levels of hippocampal tissue were examined, which suggests for future studies. Also, it is suggested that the effects of administration of curcumin be studied on the cortex of different areas of the brain and cerebellum using toluidine blue or cresyl violet staining.

Treatment with 100 mg/kg of curcumin reduced the number of dark neurons in the hippocampus of the aging mice. It seems that curcumin decreases dark neurons by reducing apoptosis. Also, curcumin is a powerful antioxidant and affects the level of antioxidant status in the brain.

Ethical Considerations

Compliance with ethical guidelines

This study was approved by Mashhad University, (Ethical Code: IR.MUMS.fm.REC.1396.466). All ethical considerations were observed throughout the research.

Funding

This article extracted from a research project (Code: 951445), funded by the Research Deputy of Mashhad University of Medical Sciences.

Authors' contributions

Methodology: Zahra Heidari, Mahdiah Yousefi Taba; Investigation: Zahra Heidari; Writing-original draft-review and editing: All author; Supervision: Shabnam Mohammadi.

Conflict of interest

The authors declare no conflict of interest.

Acknowledgments

The authors are grateful to Ms. Amini and Ms. Motejaded for providing laboratory services.

References

- [1] Kherani ZS, Auer RN. Pharmacologic analysis of the mechanism of dark neuron production in cerebral cortex. *Acta Neuropathol.* 2008; 116(4):447-52. [DOI:10.1007/s00401-008-0386-y] [PMID]
- [2] Auer RN, Kalimo H, Olsson Y, Siesjö BK. The temporal evolution of hypoglycemic brain damage. I. Light- and electron-microscopic findings in the rat cerebral cortex. *Acta Neuropathol.* 1985; 67(1-2):13-24. [DOI:10.1007/BF00688120] [PMID]
- [3] Baracskaý P, Szepesi Z, Orbán G, Juhász G, Czurkó A. Generalization of seizures parallels the formation of "dark" neurons in the hippocampus and pontine reticular formation after focal-cortical application of 4-aminopyridine (4-AP) in the rat. *Brain Res.* 2008; 1228:217-28. [DOI:10.1016/j.brainres.2008.06.044] [PMID]
- [4] Gallyas F, Farkas O, Mázló M. Traumatic compaction of the axonal cytoskeleton induces argyrophilia: Histological and theoretical importance. *Acta Neuropathol.* 2002; 103(1):36-42. [DOI:10.1007/s004010100424] [PMID]
- [5] Kiernan JA, Macpherson CM, Price A, Sun T. A histochemical examination of the staining of kainate-induced neuronal degeneration by anionic dyes. *Biotech Histochem.* 1998; 73(5):244-54. [DOI:10.3109/10520299809141118] [PMID]
- [6] Alinezhad V, Alinezhad H, Ataee R, Ataie A. Utilization of curcumine and nanocurcumine compounds in cancer therapy. *Pharm Biomed Res.* 2017; 3(3):1-11. [DOI:10.29252/pbr.3.3.1]
- [7] Sharma RA, Gescher AJ, Steward WP. Curcumin: The story so far. *Eur J Cancer.* 2005; 41(13):1955-68. [DOI:10.1016/j.ejca.2005.05.009] [PMID]
- [8] Mangolim CS, Moriwaki C, Nogueira AC, Sato F, Baesso ML, Neto AM, et al. Curcumin- β -cyclodextrin inclusion complex: Stability, solubility, characterisation by FT-IR, FT-Raman, X-ray diffraction and photoacoustic spectroscopy, and food application. *Food Chem.* 2014; 153:361-70. [DOI:10.1016/j.foodchem.2013.12.067] [PMID]
- [9] Khosrojerdi A, Mashayekhi K, Zare Marzouni H. [Curcumin (extracted from tumeric) and its therapeutic effects (Persian)]. *Jorjani Biomed J.* 2017; 4(2):1-20.
- [10] Kamali E, Ghaedi K, Karimi P, Kheradmand P, Tavassoli M. [Biological and anticancer effects of curcumin (Persian)]. *J Isfahan Med Sch.* 2014; 31(265):1-16.

- [11] Bala K, Tripathy BC, Sharma D. Neuroprotective and anti-ageing effects of curcumin in aged rat brain regions. *Biogerontology*. 2006; 7(2):81-9. [DOI:10.1007/s10522-006-6495-x] [PMID]
- [12] Kumar A, Prakash A, Dogra S. Protective effect of curcumin (*Curcuma longa*) against D-galactose-induced senescence in mice. *J Asian Nat Prod Res*. 2011; 13(1):42-55. [DOI:10.1080/10286020.2010.544253] [PMID]
- [13] Siddique YH, Naz F, Jyoti S. Effect of curcumin on lifespan, activity pattern, oxidative stress, and apoptosis in the brains of transgenic *Drosophila* model of Parkinson's disease. *Biomed Res Int*. 2014; 2014:606928. [DOI:10.1155/2014/606928] [PMID] [PMCID]
- [14] Kanter M, Aktas C, Erboga M. Curcumin attenuates testicular damage, apoptotic germ cell death, and oxidative stress in streptozotocin-induced diabetic rats. *Mol Nutr Food Res*. 2013; 57(9):1578-85. [DOI:10.1002/mnfr.201200170] [PMID]
- [15] Cheraghi E, Roshanaei K. The protective effect of curcumin against aluminum-induced oxidative stress and hepatotoxicity in male rats. *Pharm Biomed Res*. 2019; 5(1):11-8. [DOI:10.18502/pbr.v5i1.761]
- [16] Cui X, Zuo P, Zhang Q, Li X, Hu Y, Long J, et al. Chronic systemic D-galactose exposure induces memory loss, neurodegeneration, and oxidative damage in mice: Protective effects of R-alpha-lipoic acid. *J Neurosci Res*. 2006; 83(8):1584-90. [DOI:10.1002/jnr.20845] [PMID]
- [17] Samini F, Samarghandian S, Borji A, Mohammadi G, Bakavian M. Curcumin pretreatment attenuates brain lesion size and improves neurological function following traumatic brain injury in the rat. *Pharmacol Biochem Behav*. 2013; 110:238-44. [DOI:10.1016/j.pbb.2013.07.019] [PMID]
- [18] Attari SS, Mohammadi Sh, Ebrahimzadeh AR, Hosseinzadeh H, Soukhtanloo M, Rajabzadeh AA. Effects of thymoquinone on sperm parameters, apoptosis, testosterone level, and oxidative stress in a mouse model of D-galactose-induced aging. *Pharm Sci*. 2018; 24(3):180-6. [DOI:10.15171/PS.2018.26]
- [19] Shaterpour M, Shaki F, Ghasemi M, Jafari-Sabet M, Ziar A, Ataee R. The protective effect of curcumin against lithium-induced nephrotoxicity in rats. *Pharm Biomed Res*. 2017; 3(2):33-8. [DOI:10.29252/pbr.3.2.33]
- [20] Mohd Yusoff NL, Sahak MKA, Tiong SYX, Hasan Adli DS. Neuronal cell count and morphometric study of hippocampal CA1 pyramidal neurons after chronic *Nigella sativa* administration. *Malays J Microsc*. 2017; 13(1):1-7.
- [21] Jones LC, Beard JL, Jones BC. Genetic analysis reveals polygenic influences on iron, copper, and zinc in mouse hippocampus with neurobiological implications. *Hippocampus*. 2008; 18(4):398-410. [DOI:10.1002/hipo.20399] [PMID]
- [22] Dauncey MJ. New insights into nutrition and cognitive neuroscience. *Proc Nutr Soc*. 2009; 68(4):408-15. [DOI:10.1017/S0029665109990188] [PMID]