

Original Article:

Protective Effect of *Cynara scolymus* L. on Blood Biochemical Parameters and Liver Histopathological Changes in Phenylhydrazine-Induced Hemolytic Anemia in Rats



Milad Allahmoradi¹, Samad Alimohammadi^{1*}, Hadi Cheraghi²

1. Department of Physiology and Pharmacology, Faculty of Veterinary Medicine, Razi University, Kermanshah, Iran.

2. Department of Clinical Pathology, Faculty of Veterinary Medicine, Razi University, Kermanshah, Iran.

* Corresponding Author:

Samad Alimohammadi

Address: Department of Physiology and Pharmacology, Faculty of Veterinary Medicine, Razi University, Kermanshah, Iran.

Phone: +98 (938) 1518467

E-mail: s.alimohammadi@razi.ac.ir

Copyright© 2019, ASP Ins. This open-access article is published under the terms of the Creative Commons Attribution-NonCommercial 4.0 International License which permits Share (copy and redistribute the material in any medium or format) and Adapt (remix, transform, and build upon the material) under the Attribution-NonCommercial terms.

Article info:

Received: 25 Aug 2019

Accepted: 24 Nov 2019

Keywords:

Phenylhydrazine,
Hemolytic anemia,
Cynara scolymus, Rat

ABSTRACT

Background: Artichoke (*Cynara scolymus*) possesses bioactive components with antioxidant effects. This plant has been widely used in traditional medicine.

Objectives: The current study aimed to examine the protective activity of Hydroethanolic Extract of *Cynara scolymus* (HECS) against experimentally-induced hemolytic anemia in rats.

Methods: Hemolytic anemia was induced by intraperitoneal injection of Phenylhydrazine (PHZ) 40 mg/kg for 2 days. PHZ induces oxidative stress and reactive oxygen species formation, which causes hemolytic anemia. Thirty male Wistar rats were divided into 5 groups (n=6 for each group). Group 1 (normal control) was injected with normal saline. Group 2 (anemic control) received only PHZ. Groups 3 to 5 were injected with 100, 200, 400 mg/kg of the HECS by gavage, respectively, daily from day 2 to day 15 after PHZ administration. At the end of the treatment period, their blood and liver samples were collected for biochemical and histopathological analysis.

Results: The results indicated that serum Alkaline Phosphatase (ALP), alanine aminotransferase (ALT), Aspartate Aminotransferase (AST), and Lactate Dehydrogenase (LDH) levels in the PHZ (anemic) group were significantly higher than those in the control group (P<0.05). A significant decrease in serum liver enzymes was determined in rats treated with HECS at different doses compared with the untreated anemic rats (P<0.05). Also, HECS significantly attenuated body weight loss in the PHZ group (P<0.05). Besides, based on the histopathological evaluation, HECS improved disarrangements of the liver parenchyma due to PHZ-induced hepatotoxicity.

Conclusion: HECS has hepatoprotective effects against PHZ-induced toxicity presumably by its antioxidative activity.

Citation Allahmoradi M, Alimohammadi S, Cheraghi H. Protective Effect of *Cynara Scolymus* L. on Blood Biochemical Parameters and Liver Histopathological Changes in Phenylhydrazine-induced Hemolytic Anemia in Rats. Pharmaceutical and Biomedical Research. 2019; 5(4):53-62.

Introduction

Anemia is a common blood disorder and has different types based on its underlying causes. Hemolytic Anemia (HA) is the most frequent form of anemia, which is caused by hemolysis [1]. Hemolysis is a physiological and pathological status produced by the destruction of the Red Blood Cells (RBCs) or a decrease in the erythrocytes half-life [2]. It lowers the hemoglobin concentration below the normal level. Regarding the site of hemolysis, HA is classified as intravascular or extravascular, and regarding its etiology, it is categorized as acquired or inherited [3, 4]. Hemolytic anemia usually develops slowly but in some cases, it can develop suddenly: Both can be mild or severe. The clinical symptoms of HA include jaundice, paleness, fatigue, dyspnea, palpitation, hepatomegaly, and splenomegaly [5].

Several hemolytic agents are known that induce hemolysis in animal models. One of these agents is Phenylhydrazine (PHZ), a hydrazine derivative, which is widely used in industry, agriculture, laboratory, and medicine. However, PHZ is toxic and can cause irreversible cellular damage [6]. It has a variety of toxic effects such as hemolytic anemia, hypoxia, inflammation [7, 8], damage to liver, kidney, and spleen [9, 10], vascular dysfunction [11], carcinogenicity [12], encephalopathy, and neurologic disorders [13].

PHZ has long been used to produce animal models of hemolytic anemia. PHZ mechanism of hemolytic action was related to its interaction with RBCs. This interaction produces hydrogen peroxide and destroys the hemoglobin pigment through the formation of oxidized derivatives and free radicals of hydrazine [9]. PHZ also induces Reactive Oxygen Species (ROS) formation, lipid peroxidation, and protein oxidation due to the reaction with the plasma membrane. Afterward, the oxidative degradation of spectrin in the membrane cytoskeleton will result in hemolytic anemia [14]. Based on reports, PHZ may cause oxidative damage to the liver, too [15]. The formation of destructive free radicals, during the microsomal oxidation of hydrazines, is correlated with hepatotoxicity of hydrazine derivatives [9].

Currently, worldwide interest has grown over using traditional medicines, and various herbal medicinal products are used clinically because of their therapeutic effects [16]. Artichoke (*Cynara scolymus*) belongs to the Asteraceae family and has pharmacological and therapeutic potential [17]. It is cultivated in many countries, particularly in Iran, Turkey, and China, and is a

rich source of natural antioxidants [18]. Phytochemical analysis of *Cynara scolymus* has revealed its various biologically active components like phenolic acids (e.g. cynarin and chlorogenic acid) and flavonoids (e.g. apigenin, luteolin and quercetin) [18, 19]. These polyphenolic constituents exhibit potent ROS and free radicals scavenging ability [20], which in turn play a vital role as an antioxidant in the preventive treatments of oxidative damage-related disorders. Studies have shown the artichoke extract properties, such as hepatocurative [21], lipid-lowering [22], hypoglycemic [23], antioxidant [24, 25], anti-inflammatory, and immunomodulatory [26, 27] in both vivo and vitro experiments.

Based on the literature and considering the unique antioxidant properties of *Cynara scolymus*, the present study aimed to determine the effect of *Cynara scolymus* extract against oxidative stress-mediated HA and hepatic dysfunction in rats induced by PHZ.

Materials and Methods

Chemicals, reagents, and preparation of the extract

Phenylhydrazine (PHZ) was purchased from Sigma-Aldrich (St. Louis, MO, USA). *Cynara scolymus* extract powder was obtained from Dineh Iran Industries Complex (Pharmaceutical Company, Tehran, Iran). The preparation process is as follows:

Fresh *C. Scolymus* leaves (confirmed by a botanist) were collected from Dineh Pharmaceutical Research Center in Qazvin City, Iran, from April to July 2019 and sliced into small pieces. The cleaned artichoke leaves were air-dried at room temperature under the shade and then ground with a laboratory grinder to obtain its powder form. The powder was extracted three times with ethanol/water (70/30, V/V) for 72 h. The hydroethanolic extract was filtered through Whatman No. 1 filter paper. The filtrate was evaporated using a rotary evaporator under vacuum at 40°C to remove the solvent. The dry extract was stored at 4°C until further use. In this study, normal saline was added to the dried extract to achieve the concentrations of 100, 200, and 400 mg/kg of *C. scolymus*.

Alkaline Phosphatase (ALP), Alanine aminotransferase (ALT), Aspartate aminotransferase (AST), and Lactate Dehydrogenase (LDH) commercial kits were purchased from Pars Azmoon Co (Tehran, Iran).

Animals housing conditions

Thirty healthy male Wistar rats, weighing 210-220 g and aged between 8-10 weeks, were obtained from the Animal Care Unit of Faculty of Veterinary Medicine, Razi University, Kermanshah City, Iran. The animals were housed in stainless steel cages under controlled environmental conditions at 22±2°C, with a relative humidity of 55±5% under 12:12 h light-dark cycle. All rats were fed with a standard laboratory pelleted chow diet and freshwater ad libitum. The animals were acclimatized for 1 week before the beginning of the study.

Induction of anemia

Anemia was induced by Intraperitoneal (IP) injection of PHZ at 40 mg/kg for 2 consecutive days. Rats that developed anemia with hemoglobin concentration lower than 14 g/dL were considered as anemic and were used for the study.

Experimental procedure

The rats were randomly assigned into 5 experimental groups with 6 animals per group as follows: Group 1 (control group): The rats were given normal saline orally and daily for 14 days; Group 2 (anemic group): The anemic rats were treated with normal saline orally and daily for 14 days; Group 3 (anemic + Hydroethanolic Extract of *Cynara scolymus* (HECS) (100 mg/kg) group): The anemic rats were treated with HECS orally and daily (100 mg/kg) for 14 days; Group 4 (anemic + HECS (200 mg/kg) group): The anemic rats were treated with HECS orally and daily (200 mg/kg) for 14 days; Group 5 (anemic + HECS (400 mg/kg) group): The anemic rats were treated with HECS orally and daily (400 mg/kg) for 14 days.

In this study, doses of PHZ (to induce anemia) and *C. scolymus* extracts were determined according to previous studies and our unpublished pilot studies [1, 8, 23, 28].

Estimation of acute toxicity

To identify the acute toxicity of the HECS with few animals, we conducted a limit test according to OECD (Organisation for Economic Cooperation and Development) 425 guidelines. The animals were maintained under standard conditions for at least 5 days. They were fasted for 3-4 h before dosing with free access to water ad libitum. The HECS (1000 mg/kg body weight as a single dose, orally) was initially administered to one animal, followed by 24 hours observation. If the animal survived, 4 additional animals were administered with HECS at the same dose under the same conditions. A

total of 5 animals were tested. The same procedure was followed for the control group of 5 rats who received normal saline in the same volume as that of the treated groups. Treated animals were continuously observed for a total period of 14 days [29].

Measurement of body weight

The initial and final body weights of the animals were measured and recorded.

Biochemical analysis

At the end of the experimental period, all rats were anesthetized with an intraperitoneal injection of ketamine and xylazine. Then, their blood samples were directly collected via the cardiac puncture method. Serum specimens were separated by blood centrifugation at 2000 rpm for 10 min at room temperature and were stored at -20°C until biochemical analysis. Afterward, the levels of ALP, ALT, AST, and LDH in their serum were determined using commercial diagnostic kits obtained from Pars Azmoon Co. (Tehran, Iran) [30].

Histopathological examination

After collecting blood samples, all rats were sacrificed, and their livers were immediately dissected. Small pieces of liver tissue were fixed in 10% buffered formalin, embedded in paraffin wax, sectioned into 5-µm thick pieces using a microtome, and then stained with hematoxylin-eosin. The stained sections were observed with a light microscope. The description and scoring of histopathological lesions were carried out as previously described by Ozden et al. [31].

Statistical analysis

The obtained data were prepared in Excel and analyzed by 1-way Analysis of Variance (ANOVA) and Tukey's HSD (Honest Significant Difference) post-hoc test in SPSS V. 21 for Windows (SPSS, Inc. Chicago, IL, USA). The results were expressed as Means±SEM. P<0.05 was defined as the significant difference between the groups. For histopathological evaluation, differences among groups were evaluated using the nonparametric Kruskal-Wallis test, and data were expressed as median and range.

Results

Acute toxicity testing

Single-dose acute toxicity of the HECS was demonstrated through a limit test. Oral administration of the

HECS did not show any animal mortality nor signs of toxicity up to a dose of 1000 mg/kg in 14 days. Therefore, LD50 (Lethal Dose 50) of the HECS was considered to be more than 1000 mg/kg.

Effect of *Cynara Scolymus* extract on body weight

Table 1 presents the initial body weight, final body weight, and Body Weight Gain percentage (BWG %) of the control and anemic rats treated with HECS at different doses during the experiment. There were no significant differences in the initial body weight between all experimental groups ($P>0.05$). Moreover, hemolytic anemia induced a considerable reduction in the final body weight and body weight gain of anemic rats compared to the control group after 14 days ($P<0.05$). Treatment with HECS (200 mg/kg and 400 mg/kg) improved this weight loss ($P<0.05$) (Table 1).

Effect of *Cynara Scolymus* extract on serum levels of liver enzymes

The hepatic response to phenylhydrazine administration and treatment with artichoke extract are presented in Figures 1, 2, 3, and 4. Our results revealed that the intraperitoneal injection of PHZ to rats caused a significant increase in the activities of ALP, ALT, AST, and LDH in the serum compared with those in the control group ($P<0.05$). Furthermore, oral administration of artichoke extract (100-400 mg/kg) significantly attenuated the elevated levels of parameters mentioned above in a dose-dependent manner (mainly at doses of 200 and 400 mg/kg) compared with the PHZ-treated rats ($P<0.05$) (Figures 1, 2, 3, and 4).

Effect of *Cynara Scolymus* extract on histopathological changes of rat livers

No significant gross lesions were observed in any of the rats following necropsy examination. Staining of liver sections of normal control rats showed normal lobular architecture with central veins and radiating hepatic cords (Figure 5 A), while administration of PHZ caused mild to moderate changes in the liver parenchyma, including hepatocyte degeneration, vacuolar degeneration, congestion, dilation of sinusoids, infiltration of the mononuclear cells and small-focal necrosis (Figure 5, B-D). The treatment of PHZ-induced hepatotoxicity with artichoke extract at different doses remarkably but not completely attenuated these lesions and increase serum liver enzyme levels. Generally, artichoke extract at higher doses (200 and 400 mg/kg) had a better constructive effect on the damaged livers compared with its low dose (100 mg/kg) (Figure 5 E, F; Table 2). Generally, the effects of the Hydroethanolic Extract of *Cynara Scolymus* (HECS) are summarized in Figure 6.

Discussion

The present study was designed to elucidate the protective effect of *Cynara scolymus* against PHZ-induced hemolytic anemia and hepatotoxicity in rats. To our knowledge, this is the first report on the role of artichoke extract on liver function indices following PHZ administration. Phenylhydrazine, as a powerful oxidant agent, has been extensively used for the induction of hemolysis in animal models. There is a correlation between oxidative stress and hemolytic anemia. It is well documented that oxidative stress plays a crucial role in the pathogenesis of several diseases, such as hematological abnormalities [32]. The autoxidation of PHZ can increase the production of ROS and PHZ-derived radicals, which causes

Table 1. Effect of *Cynara scolymus* extract on body weight alterations in phenylhydrazine-induced anemic rats (n=6)

Experimental Groups	Mean±SEM			
	Initial Body Weight (g)	Final Body Weight (g)	Body Weight Gain (%)	
Control	217.12±1.33	230.60±2.60	6.21±1.90	
PHZ	218.72±4.13	208.11±5.10*	-4.85±2.31*	
(100 mg/kg)	212.50±5.19	217.87±2.35	2.53±1.70	
PHZ+HECS	(200 mg/kg)	215.62±4.47	222.23±1.18 [#]	3.07±1.41 [#]
(400 mg/kg)	216.00±4.23	226.37±2.68 [#]	4.80±1.53 [#]	

* $P<0.05$ as compared with the control group within each column; [#] $P<0.05$ as compared with PHZ-treated group within each column. PHZ: Phenylhydrazine; HECS: Hydroethanolic extract of *Cynara Scolymus*

PBR

Table 2. Histopathological changes scores of the liver in all experimental groups

Histopathological Changes	Group 1	Group 2	Group 3	Group 4	Group 5	P
Vacuolar degeneration	0	2*	1*	1*	0	0
Congestion of sinusoids	0	2*	1*	1*	1*	0.01
Dilation of sinusoids	0	1*	1*	1*	1*	0
Central vein congestion	1*	2*	1*	1*	1*	0
Lobular inflammation	0	2*	1*	1*	0	0
Focal necrosis	0	2*	1*	1*	0	0

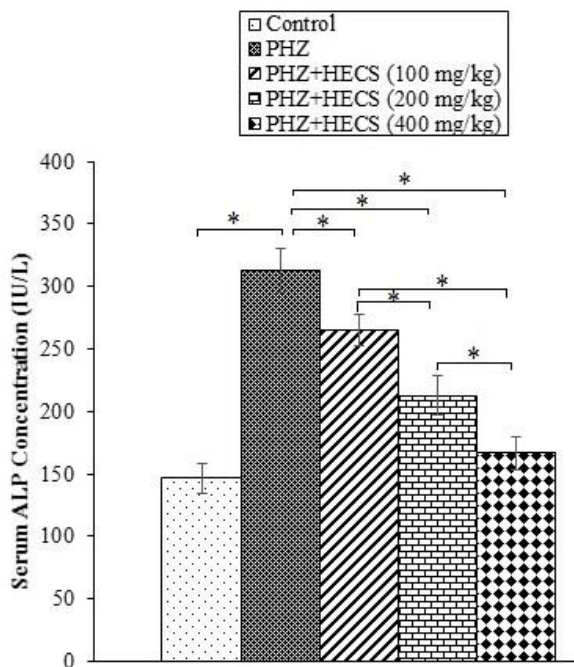
PBR

Scores: No lesion (0); Mild (1+); Moderate (2+); Severe (3+). Group 1: Control; Group 2: PHZ; Group 3: PHZ+HECS (100 mg/kg); Group 4: PHZ+HECS (200 mg/kg); Group 5: PHZ+HECS (400 mg/kg)

P<0.05 was considered significant. The comparison was between all groups. The values are the median (range) for each group. PHZ: Phenylhydrazine; HECS: Hydroethanolic extract of *Cynara Scolymus*

a wide variety of harmful cellular responses, including membrane lipid peroxidation and protein oxidation resulting in the devastation of RBCs membrane integrity and hemolytic anemia [11, 33]. Plant extracts (phytotherapeutics agents) have been used to treat various ailments in recent years due to their efficacy and fewer side effects compared with the standard synthetic drugs [34].

Several studies have demonstrated the *Cynara scolymus* protection against oxidative stress-related conditions. This protection is attributed to the presence of a broad range of polyphenol-type antioxidants in plant extract that have free radical scavenging ability [18].

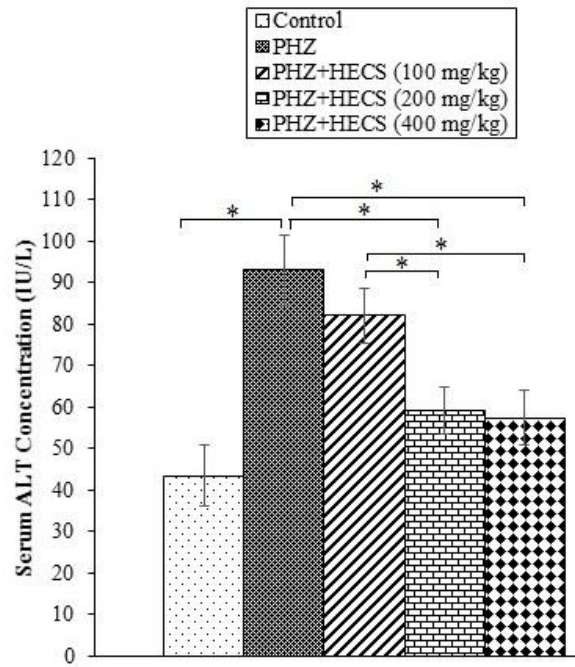


PBR

Figure 1. Effect of *Cynara scolymus* extract at different doses on serum Alkaline Phosphatase (ALP) levels in phenylhydrazine-induced anemic rats

Data are expressed as Mean±SEM (n=6).

* P<0.05. PHZ: Phenylhydrazine; HECS: Hydroethanolic extract of *Cynara Scolymus*



PBR

Figure 2. Effect of *Cynara scolymus* extract at different doses on serum Alanine aminotransferase (ALT) levels in phenylhydrazine-induced anemic rats

Data are expressed as Mean±SEM (n=6).

* P<0.05. PHZ: Phenylhydrazine; HECS: Hydroethanolic extract of *Cynara Scolymus*

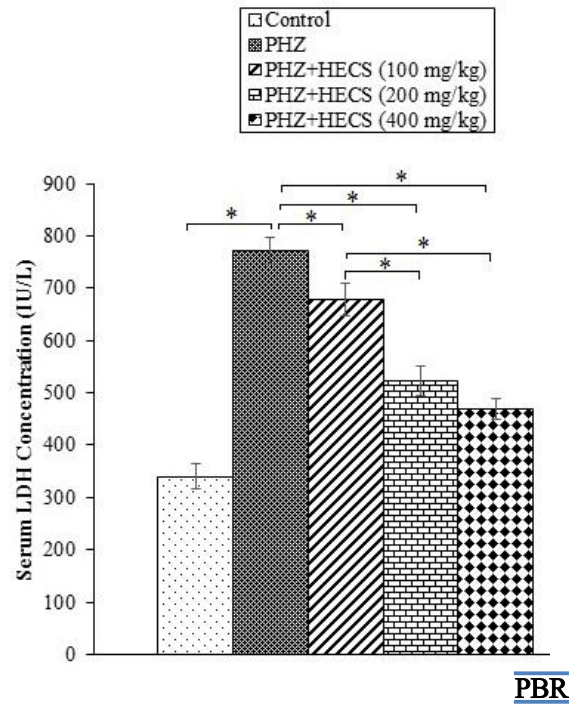
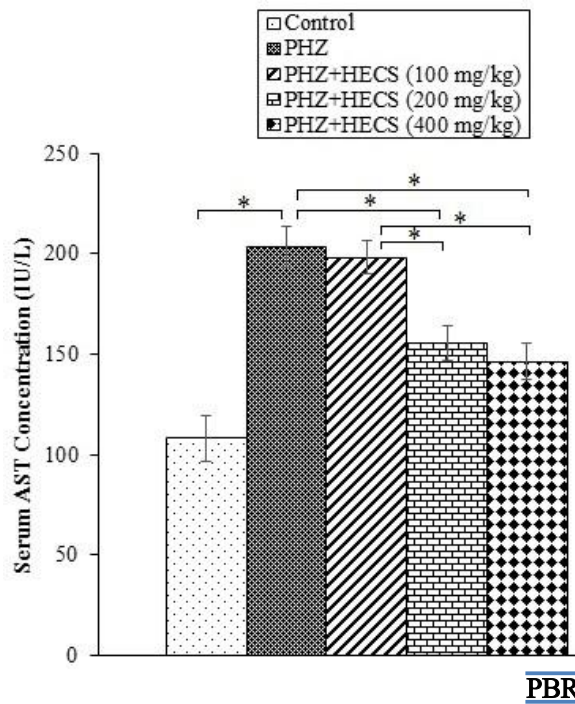


Figure 3. Effect of *Cynara scolymus* extract at different doses on serum Aspartate aminotransferase (AST) levels in phenylhydrazine-induced anemic rats. Data are expressed as Mean±SEM (n=6). * P<0.05. PHZ: Phenylhydrazine; HECS: Hydroethanolic extract of *Cynara Scolymus*

Figure 4. Effect of *Cynara scolymus* extract at different doses on serum Lactate Dehydrogenase (LDH) levels in phenylhydrazine-induced anemic rats. Data are expressed as Mean±SEM (n=6). * P<0.05. PHZ: Phenylhydrazine; HECS: Hydroethanolic extract of *Cynara Scolymus*

In the present study, we observed that injection of PHZ decreased the body weight gain of rats compared with the control group, possibly because of lack of appetite, reduction of disaccharidase activities, and functional changes in the structure of the small intestine that can

result in nutrient malabsorption in the anemic rats [35, 36]. In agreement with our results, a significant decrease in body weight was reported in PHZ-exposed animals [1, 37]. However, after 14 days of HECS treatment, the body weight loss of rats was recovered.

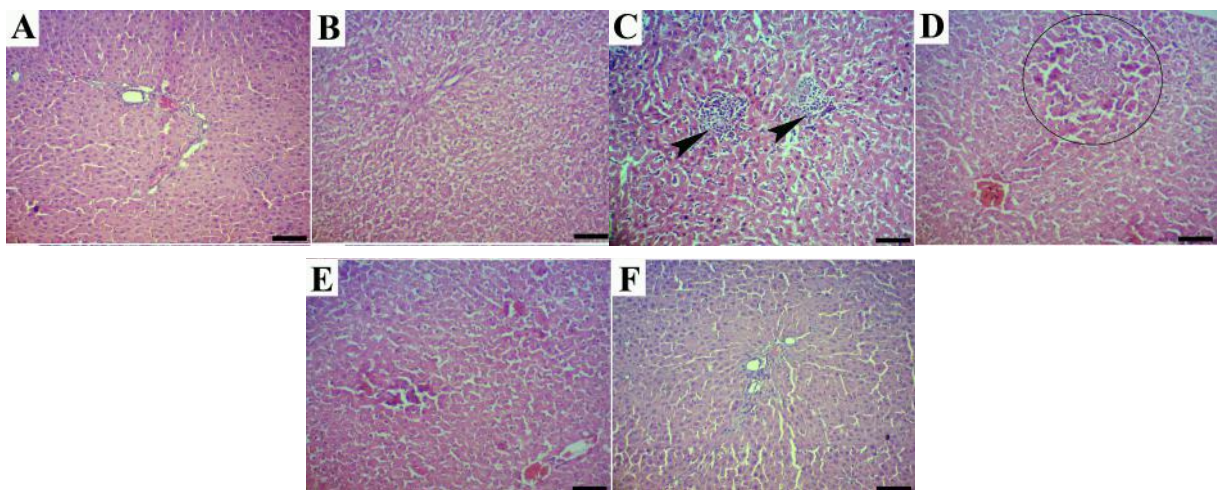


Figure 5. Histopathological observations of rat liver sections in different experimental groups (H&E staining; Scale bar=60 μm) A. Control group: Normal lobular architecture with central veins and radiating hepatic cords; B. Phenylhydrazine group: Hepatocyte degeneration; C. Phenylhydrazine group: Infiltration of mononuclear cells in the liver parenchyma (arrowhead); D. Phenylhydrazine group: Focal necrosis (circle); E and F. Phenylhydrazine group treated with artichoke extract 200 and 400 mg/kg, respectively: Normal liver structure similar to control group

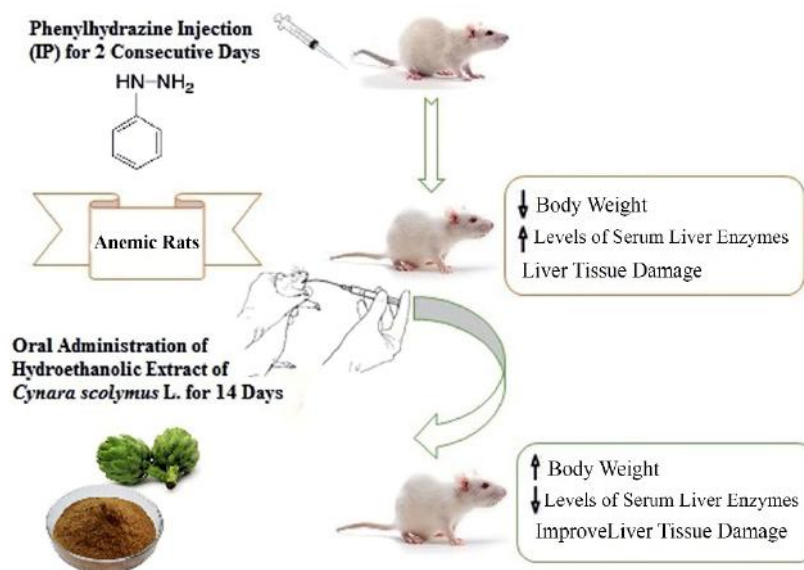


Figure 6. Graphical abstract that summarizes the effects of Hydroethanolic Extract of *Cynara scolymus* in phenylhydrazine-induced anemic rats

It has been reported that *C. scolymus* can improve intestinal health by increasing enzymatic activities, improving intestinal absorption and enhancement of scavenging activity against ROS and free radicals via potent antioxidant compounds [38]. Therefore, the ability of *C. scolymus* extract to modify the body weight changes induced by PHZ in our study may be mediated through the factors as mentioned above.

The liver is a complex and vital organ in the body. It exerts many pivotal functions in maintenance, performance, regulating homeostasis of the body, xenobiotic metabolism, and detoxification. Because the liver is the first site of contact for different types of therapeutic drugs, xenobiotics, and toxins, this organ is vulnerable to chemical-induced injuries [39, 40].

Apart from its hemolytic activity, PHZ is also toxic to the liver. Iron overload within the hepatocytes has been identified following the intoxication of rats with PHZ. The formation of harmful ROS, such as the free hydroxyl radical, is associated with iron overload [15, 41]. Besides, experimental evidence indicates that oxidative stress has been implicated in the pathogenesis of iron-overload-induced hepatotoxicity through elevated levels of ROS, thereby causing damage to hepatocellular membrane lipids, proteins, and DNA [42, 43]. In this regard, several studies have stated that one of the most essential and sensitive laboratory indicators for hepatic injury is measuring the release of intracellular enzymes, such as ALP, ALT, AST, and LDH into the bloodstream. There-

fore, the elevated serum enzyme levels are indicative of hepatocellular damage and disruption of liver plasma membrane integrity [44-47].

Another interesting finding in the present study was that PHZ-induced hepatotoxicity significantly increased the serum concentrations of ALP, ALT, AST and LDH compared with those in the control group. Likewise, histopathological findings showed degenerative changes in the hepatocytes, congestion, mononuclear cells infiltration and small-focal necrosis in PHZ-treated rats. Similar to our results, a remarkable increase in serum ALP, ALT, AST, and LDH levels has also been found in experimental animals after administration of the PHZ [48, 49]. In support of our findings, focal hepatic necrosis, degeneration and fatty changes have also been reported in the liver tissues of rats exposed to PHZ [15, 49].

Cynara scolymus has long been used effectively against liver diseases for its great hepatoprotective potential. For instance, Colak et al. found that elevated levels of serum liver enzymes were significantly decreased by treatment with *Cynara scolymus* extract in carbon tetrachloride-induced hepatic injury [21]. Also, Heidarian and Rafieian-Kopaei [50] and Ben Salem et al. [23] suggested that artichoke extract decreased the elevated liver enzyme levels in the lead-intoxicated rats and diabetes-induced hepatotoxicity, respectively. Similarly, our obtained results indicated that treatment with *Cynara scolymus* extract decreased the substantial elevation of hepatic dysfunction parameters such as ALP, ALT, AST and LDH

levels in PHZ-induced hepatotoxicity. In addition, in rats treated with *Cynara scolymus* extract, significant improvements were observed in histopathological changes in the liver caused by PHZ exposure.

Several researchers have investigated the chemical constituents of the *Cynara scolymus* and have found rich sources of phenolic and flavonoid compounds in it. These compounds have free radical scavenging and antioxidant activity. For example, previous studies have revealed that caffeoylquinic acid derivatives (cynarin and chlorogenic acid), apigenin, luteolin, and quercetin present in *Cynara scolymus* extract are responsible for the hepatoprotective action due to their antioxidant properties [51-54]. Thus, it is suggested that the protective properties of *Cynara Scolymus* may appear by involving these phytotherapeutics agents in the liver. The main strength of the current study was to elucidate the potential role of *Cynara Scolymus* extract on serum biochemical markers involved in hepatotoxicity in PHZ-induced anemic rats.

Although this study had several important findings, some limitations still exist in this investigation, including incomparable data about the antioxidant property of different types of the extract (aqueous, ethanolic and methanolic) under in vitro and in vivo conditions and methodological/ technical limitations. Therefore, further experimental approaches and assessments of oxidative stress markers and antioxidant systems are needed to overcome these limitations.

Conclusion

The observed hepatoprotective property of hydroethanolic extract of *Cynara scolymus* against PHZ-induced hepatotoxicity in rats might be partly due to the presence of various phytochemical constituents with nutritional benefits and potent antioxidant activity. However, further investigation is required to elucidate the underlying cellular and molecular signaling pathways involved in the hepatoprotective effect of HECS.

Ethical Considerations

Compliance with ethical guidelines

Animal experiments in this study were approved by the Animal Ethics Committee of Razi University and followed with the Guidelines for the Care and Use of Laboratory Animals in Research (Animal Ethical Approval Number: 397-2-008).

Funding

The results described in this research were from a Doctor of Veterinary Medicine (D.V.M) student's thesis authored by Milad Allahmoradi, Department of Physiology and Pharmacology, Faculty of Veterinary Medicine, Razi University, Kermanshah, Iran.

Authors' contributions

Conceptualization, Writing-original draft, writing-review and editing, resources, and supervision: Samad Alimohammadi; Methodology: All authors; Investigation, funding acquisition: Samad Alimohammadi, Milad Allahmoradi.

Conflict of interest

The authors declared no conflict of interest.

References

- [1] Lee SH, Suh HJ, Lee HS, Park Y, Park JW, Jung EY. Hematopoietic effect of Bacillus subtilis-fermented antler extract on phenylhydrazine-induced hemolytic anemia in Sprague-Dawley rats. *J Med Food*. 2012; 15(9):774-80. [DOI:10.1089/jmf.2012.2264] [PMID]
- [2] Barcellini W, Fattizzo B. Clinical applications of hemolytic markers in the differential diagnosis and management of hemolytic anemia. *Dis Markers*. 2015; 2015:635670. [DOI:10.1155/2015/635670] [PMID] [PMCID]
- [3] Murakami J, Shimizu Y. Hepatic manifestations in hematological disorders. *Int J Hepatol*. 2013; 2013:484903. [DOI:10.1155/2013/484903] [PMID] [PMCID]
- [4] Dhaliwal G, Cornett PA, Tierney LM Jr. Hemolytic anemia. *Am Fam Physician*. 2004; 69(11):2599-606. [PMID]
- [5] Guillaud C, Loustau V, Michel M. Hemolytic anemia in adults: Main causes and diagnostic procedures. *Expert Rev Hematol*. 2012; 5(2):229-41. [DOI:10.1586/ehm.12.3] [PMID]
- [6] Karbownik M, Reiter RJ, Garcia JJ, Tan DX. Melatonin reduces phenylhydrazine-induced oxidative damage to cellular membranes: Evidence for the involvement of iron. *Int J Biochem Cell Biol*. 2000; 32(10):1045-54. [DOI:10.1016/S1357-2725(00)00056-X]
- [7] Nicolas G, Chauvet C, Viatte L, Danan JL, Bigard X, Devaux I, et al. The gene encoding the iron regulatory peptide hepcidin is regulated by anemia, hypoxia, and inflammation. *J Clin Invest*. 2002; 110(7):1037-44. [DOI:10.1172/JCI0215686] [PMID] [PMCID]
- [8] Diallo A, Gbeassor M, Vovor A, Eklou-Gadegbeku K, Aklikokou K, Agbonon A, et al. Effect of Tectona grandis on phenylhydrazine-induced anaemia in rats. *Fitoterapia*. 2008; 79(5):332-6. [DOI:10.1016/j.fitote.2008.02.005] [PMID]

- [9] Ozcan A, Atakisi E, Karapehlivan M, Atakisi O, Cital M. Effect of L-Carnitine on oxidative damage to liver, kidney and spleen induced by phenylhydrazine in mice. *J Appl Anim Res.* 2007; 32(1):97-100. [DOI:10.1080/09712119.2007.9706855]
- [10] Lim YK, Jenner A, Ali AB, Wang Y, Hsu SI, Chong SM, et al. Haptoglobin reduces renal oxidative DNA and tissue damage during phenylhydrazine-induced hemolysis. *Kidney Int.* 2000; 58(3):1033-44. [DOI:10.1046/j.1523-1755.2000.00261.x] [PMID]
- [11] Luangaram S, Kukongviriyapan U, Pakdeechote P, Kukongviriyapan V, Pannangpetch P. Protective effects of quercetin against phenylhydrazine-induced vascular dysfunction and oxidative stress in rats. *Food Chem Toxicol.* 2007; 45(3):448-55. [DOI:10.1016/j.fct.2006.09.008] [PMID]
- [12] Sharma S, Haldar C. Comparative effect of melatonin and vitamin E on phenylhydrazine-induced toxicity in the spleen of *Funambulus pennanti*. *Environ Toxicol.* 2009; 24(1):1-9. [DOI:10.1002/tox.20383] [PMID]
- [13] Pazar A, Kolgazi M, Memisoglu A, Bahadir E, Sirvanci S, Yaman A, et al. The neuroprotective and anti-apoptotic effects of melatonin on hemolytic hyperbilirubinemia-induced oxidative brain damage. *J Pineal Res.* 2016; 60(1):74-83. [DOI:10.1111/jpi.12292] [PMID]
- [14] Berger J. Phenylhydrazine haematotoxicity. *J Appl Biomed.* 2007; 5:125-30. [DOI:10.32725/jab.2007.017]
- [15] Kim YW, Lee SM, Shin SM, Hwang SJ, Brooks JS, Kang HE, et al. Efficacy of sauchinone as a novel AMPK-activating ligand for preventing iron-induced oxidative stress and liver injury. *Free Radic Biol Med.* 2009; 47(7):1082-92. [DOI:10.1016/j.freeradbiomed.2009.07.018] [PMID]
- [16] Mohammadifard F, Alimohammadi S. Chemical composition and role of opioidergic system in antinociceptive effect of *Ziziphora clinopodioides* essential oil. *Basic Clin Neurosci.* 2018; 9(5):357-66. [DOI:10.32598/bcn.9.5.357] [PMID] [PMCID]
- [17] Lattanzio V, Kroon PA, Linsalata V, Cardinali A. Globe artichoke: A functional food and source of nutraceutical ingredients. *J Funct Foods.* 2009; 1(2):131-44. [DOI:10.1016/j.jff.2009.01.002]
- [18] Ben Salem M, Affes H, Ksouda K, Dhouibi R, Sahnoun Z, Hammami S, et al. Pharmacological studies of artichoke leaf extract and their health benefits. *Plant Foods Hum Nutr.* 2015; 70(4):441-53. [DOI:10.1007/s11130-015-0503-8] [PMID]
- [19] Wang M, Simon JE, Aviles IF, He K, Zheng QY, Tadmor Y. Analysis of antioxidative phenolic compounds in artichoke (*Cynara scolymus* L.). *J Agric Food Chem.* 2003; 51(3):601-8. [DOI:10.1021/jf020792b] [PMID]
- [20] Ceccarelli N, Curadi M, Picciarelli P, Martelloni L, Sbrana C, Giovannetti M. Globe artichoke as a functional food. *Med J Nutrition Metab.* 2010; 3(3):197-201. [DOI:10.1007/s12349-010-0021-z]
- [21] Colak E, Ustuner MC, Tekin N, Colak E, Burukoglu D, Degirmenci I, et al. The hepatocurative effects of *Cynara scolymus* L. leaf extract on carbon tetrachloride-induced oxidative stress and hepatic injury in rats. *SpringerPlus.* 2016; 5:216. [DOI:10.1186/s40064-016-1894-1] [PMID] [PMCID]
- [22] Sahebkar A, Pirro M, Banach M, Mikhailidis DP, Atkin SL, Cicero AFG. Lipid-lowering activity of artichoke extracts: A systematic review and meta-analysis. *Critical Reviews in Food Science and Nutrition.* 2018; 58(15):2549-56. [DOI:10.1080/10408398.2017.1332572] [PMID]
- [23] Ben Salem M, Ben Abdallah Kolsi R, Dhouibi R, Ksouda K, Charfi S, Yaich M, et al. Protective effects of *Cynara Scolymus* leaves extract on metabolic disorders and oxidative stress in alloxan-diabetic rats. *BMC Complementary and Alternative Medicine.* 2017; 17(1):328. [DOI:10.1186/s12906-017-1835-8] [PMID] [PMCID]
- [24] El Morsy EM, Kamel R. Protective effect of artichoke leaf extract against paracetamol-induced hepatotoxicity in rats. *Pharmaceutical Biology.* 2015; 53(2):167-73. [DOI:10.3109/13880209.2014.913066] [PMID]
- [25] Salekzamani S, Ebrahimi-Mameghani M, Rezazadeh K. The antioxidant activity of artichoke (*Cynara Scolymus*): A systematic review and meta-analysis of animal studies. *Phytotherapy Research.* 2019; 33(1):55-71. [DOI:10.1002/ptr.6213] [PMID]
- [26] Zapolska-Downar D, Zapolski-Downar A, Naruszewicz M, Siennicka A, Krasnodebska B, Koldziej B. Protective properties of artichoke (*Cynara Scolymus*) against oxidative stress induced in cultured endothelial cells and monocytes. *Life Sciences.* 2002; 71(24):2897-908. [DOI:10.1016/S0024-3205(02)02136-7]
- [27] El-Boshy M, Ashshi A, Gaith M, Qusty N, Bokhary T, Al-Taweel N, et al. Studies on the protective effect of the artichoke (*Cynara scolymus*) leaf extract against cadmium toxicity-induced oxidative stress, hepatorenal damage, and immunosuppressive and hematological disorders in rats. *Environmental Science and Pollution Research International.* 2017; 24(13):12372-83. [DOI:10.1007/s11356-017-8876-x] [PMID]
- [28] Heidarian E, Soofiniya Y. Hypolipidemic and hypoglycemic effects of aerial part of *Cynara scolymus* in streptozotocin-induced diabetic rats. *Journal of Medicinal Plants Research.* 2011; 5(13):2717-23.
- [29] OECD. Test No. 425: Acute oral toxicity: Up-and-down procedure. In: OECD. OECD guidelines for the testing of chemicals, section 4. Paris: OECD; 2008. [DOI:10.1787/9789264071049-en]
- [30] Shokrzadeh M, Bakhshi Jouybari H, Hosseinpour M, Ziar A, Habibi E. Antioxidant and protective effect of hydroalcoholic extract of *Celtis australis* L. on CCl₄ induced hepatotoxicity. *Pharmaceutical and Biomedical Research.* 2018; 4(3):26-31. [DOI:10.18502/pbr.v4i3.541]
- [31] Özden H, Bildirici K, Üsttiner D, Üsttiner C, Cengiz BP, Tülây A, et al. Histopathologic examination of rat liver after experimental application of fluoxetine. *Türkiye Ekopatoloji Dergisi.* 2005; 11(1):9-15.
- [32] Fibach E, Rachmilewitz E. The role of oxidative stress in hemolytic anemia. *Curr Mol Med.* 2008; 8(7):609-19. [DOI:10.2174/156652408786241384] [PMID]
- [33] Sung YM, Gayam SR, Wu SP. The oxidation of phenylhydrazine by tyrosinase. *Appl Biochem Biotechnol.* 2013; 169(8):2420-9. [DOI:10.1007/s12010-013-0165-7] [PMID]
- [34] Aktar K, Foyzun T. Phytochemistry and pharmacological studies of *Citrus macroptera*: A medicinal plant review.

- Evid Based Complement Alternat Med. 2017; 2017:9789802. [DOI:10.1155/2017/9789802] [PMID] [PMCID]
- [35] Vieira MR, Galvão LC, Fernandes MI. Relation of the disaccharidases in the small intestine of the rat to the degree of experimentally induced iron-deficiency anemia. *Braz J Med Biol Res.* 2000; 33(5):539-44. [DOI:10.1590/S0100-879X2000000500008] [PMID]
- [36] Anbara H, Shalizar Jalali A, Shahrooz R, Razi M. [Protective effect of royal jelly against phenylhydrazine-induced histological injuries of small intestine of mice: Morphometric analyses (Persian)]. *Qom Univ of Med Sci J.* 2016; 9(11):12-21.
- [37] Onyeabo C, Achi NK, Ekeleme-Egedigwe CA, Ebere CU, Okoro CK. Haematological and biochemical studies on Justicia carnea leaves extract in phenylhydrazine induced-anemia in albino rats. *Acta Sci Pol Technol Aliment.* 2017; 16(2):217-30. [DOI:10.17306/J.AFS.0492] [PMID]
- [38] Goñi I, Jiménez-Escrig A, Gudiel M, Saura-Calixto FD. Artichoke (*Cynara scolymus* L.) modifies bacterial enzymatic activities and antioxidant status in rat cecum. *Nutrition Research.* 2005; 25(6):607-15. [DOI:10.1016/j.nutres.2005.06.003]
- [39] Bhakuni GS, Bedi O, Bariwal J, Deshmukh R, Kumar P. Animal models of hepatotoxicity. *Inflamm Res.* 2016; 65(1):13-24. [DOI:10.1007/s00011-015-0883-0] [PMID]
- [40] Gu X, Manautou JE. Molecular mechanisms underlying chemical liver injury. *Expert Rev Mol Med.* 2012; 14:e4. [DOI:10.1017/S1462399411002110] [PMID] [PMCID]
- [41] Ferrali M, Signorini C, Sugherini L, Pompella A, Lodovici M, Caciotti B, et al. Release of free, redox-active iron in the liver and DNA oxidative damage following phenylhydrazine intoxication. *Biochem Pharmacol.* 1997; 53(11):1743-51. [DOI:10.1016/S0006-2952(97)82456-2]
- [42] Emerit J, Beaumont C, Trivin F. Iron metabolism, free radicals, and oxidative injury. *Biomed Pharmacother.* 2001; 55(6):333-9. [DOI:10.1016/S0753-3322(01)00068-3]
- [43] Basu T, Panja S, Shendge AK, Das A, Mandal N. A natural antioxidant, tannic acid mitigates iron-overload induced hepatotoxicity in Swiss albino mice through ROS regulation. *Environ Toxicol.* 2018; 33(5):603-18. [DOI:10.1002/tox.22549] [PMID]
- [44] Djeflal A, Messarah M, Boumendjel A, Kadeche L, Feki AE. Protective effects of vitamin C and selenium supplementation on methomyl-induced tissue oxidative stress in adult rats. *Toxicol Ind Health.* 2015; 31(1):31-43. [DOI:10.1177/0748233712468020] [PMID]
- [45] Rezaei-Kelishadi M, Ghasemi A, Nabi Abdolyosefi N, Zamani-Doabi S, Ramezani M, Changizi-Ashtiyani S, et al. Effects of selenium nanoparticles on kidney and liver functional disorders in streptozotocin-induced diabetic rats. *Physiol Pharmacol.* 2017; 21:155-62.
- [46] Ozer J, Ratner M, Shaw M, Bailey W, Schomaker S. The current state of serum biomarkers of hepatotoxicity. *Toxicol.* 2008; 245(3):194-205. [DOI:10.1016/j.tox.2007.11.021] [PMID]
- [47] Shokrzadeh M, Azadbakht M, Shakibamanesh HR. The hepatoprotective effect of Arnebia euchroma hydro-alcoholic extract against liver toxicity induced by CCl4 in mice. *Pharm Biomed Res.* 2017; 3(4):23-9. [DOI:10.18502/pbr.v3i4.87]
- [48] Anbara H, Shalizar Jalali A, Shahrooz R, Razi M. [Protective effect of royal jelly following phenylhydrazine-induced hepatotoxicity in mice (Persian)]. *Armaghan-e-Danesh.* 2015; 20(7):611-22.
- [49] Goorani S, Shariatifar N, Seydi N, Zangeneh A, Moradi R, Tari B, et al. The aqueous extract of Allium saralicum R.M. Fritsch effectively treat induced anemia: Experimental study on Wistar rats. *Orient Pharm Exp Med.* 2019; 19(4):403-13. [DOI:10.1007/s13596-019-00361-5]
- [50] Heidarian E, Rafieian-Kopaei M. Protective effect of artichoke (*Cynara scolymus*) leaf extract against lead toxicity in rat. *Pharm Biol.* 2013; 51(9):1104-9. [DOI:10.3109/13880209.2013.777931] [PMID]
- [51] Speroni E, Cervellati R, Govoni P, Guizzard S, Renzulli C, Guerra MC. Efficacy of different *Cynara scolymus* preparations on liver complaints. *J Ethnopharmacol.* 2003; 86(2-3):203-11. [DOI:10.1016/S0378-8741(03)00076-X]
- [52] Küskü-Kiraz Z, Mehmetçik G, Dogru-Abbasoglu S, Uysal M. Artichoke leaf extract reduces oxidative stress and lipoprotein dyshomeostasis in rats fed on high cholesterol diet. *Phytother Res.* 2010; 24(4):565-70. [DOI:10.1002/ptr.2985] [PMID]
- [53] El Sayed AM, Hussein R, Motaal AA, Fouad MA, Aziz MA, El-Sayed A. Artichoke edible parts are hepatoprotective as commercial leaf preparation. *Rev Bras de Farmacognosia.* 2018; 28(2):165-78. [DOI:10.1016/j.bjp.2018.01.002]
- [54] Ben Salem M, Ksouda K, Dhoubi R, Charfi S, Turki M, Hammami S, et al. LC-MS/MS analysis and hepatoprotective activity of artichoke (*Cynara Scolymus* L.) leaves extract against high fat diet-induced obesity in rats. *Biomed Res Int.* 2019; 2019:4851279. [DOI:10.1155/2019/4851279] [PMID] [PMCID]