

## The Effect of Topical Application of 0.1% Betamethasone Ointment on the Peritoneal Adhesion and Inflammation Following Laparotomy: A Histopathological Animal Experiment

Seyed Abdollah Mousavi<sup>1\*</sup>, Seyed Jaber Mousavi<sup>2</sup>, Maryam Ghasemi<sup>3</sup>, Hooshang Akbari<sup>4</sup>, Ali Haqqani<sup>5</sup>

<sup>1</sup>Pediatric Infectious Diseases Research Center, Department of Pediatrics, School of Medicine, Mazandaran University of Medical Sciences, Mazandaran, Iran

<sup>2</sup>Department of Community Medicine, School of Medicine, Mazandaran University of Medical Sciences, Sari, Iran

<sup>3</sup>Department of Pathology, School of Medicine, Mazandaran University of Medical Sciences, Sari, Iran

<sup>4</sup>Department of Anesthesiology, School of Medicine, Mazandaran University of Medical Sciences, Sari, Iran

<sup>5</sup>Department of General Surgery, School of Medicine, Mazandaran University of Medical Sciences, Sari, Iran

\*Corresponding authors: Seyed Abdollah Mousavi, Pediatric Infectious Diseases Research Center, Department of Pediatrics, School of Medicine, Mazandaran University of Medical Sciences, Mazandaran, Iran. Email: [dr.a.mosavi@gmail.com](mailto:dr.a.mosavi@gmail.com)

Received: Aug 3, 2019, Accepted: Sep 25, 2019

### Abstract

Adhesion band is one of the most important challenges after the operation. Regarding to the use of corticosteroid medications in inflammatory conditions, no studies have been conducted on the topical application, even though limited success have been reported with the systemic therapy. Since the systemic therapy of corticosteroids has its own limitation, the present study was designed to investigate the effect of using topical betamethasone on the prevention of peritoneal adhesion in an animal model. A total of 24 rats were randomly divided into two groups (control and betamethasone) and underwent laparotomy. Then, the adhesion was induced with the abrasion of dry gauze on the small intestine in both groups. In the betamethasone group, 0.1% betamethasone ointment was applied on the site of abrasion. After the 14 days, the animals were sacrificed, laparotomy was then performed with a U-shaped incision, and the number and location of the adhesions were reported. Histological parameters such as inflammatory reactions and collagen precipitations were evaluated, and neovascularization, abnormal mucosal proliferation, foreign body granulation, fibroblastic maturation were also observed. The results showed that the mean number of adhesions in the betamethasone and control groups were 1.08 and 1.17, respectively. Though betamethasone reduced the number of adhesions, the decrease was not statistically significant. Likewise, the results of histopathological evaluations showed no significant differences between the two groups ( $P>0.05$ ). Our study demonstrated that the local application of betamethasone ointment in a single dose after laparotomy could not be effective in preventing peritoneal adhesion and inflammatory processes. Further investigations with larger sample sizes treated with higher doses of corticosteroids are required to find better the effects of topical betamethasone ointment on the peritoneal adhesion and inflammation following laparotomy.

**Keywords:** Corticosteroid, Betamethasone, Laparotomy, Inflammatory

### Introduction

Adhesion bands (AB) constitute one of the most important challenges faced following an operation, especially one performed in the gastrointestinal tract. Further, this complication is one of the primary causes of post-laparotomy morbidity, which can occur several years after the operation (1, 2). Following any tissue damage, exudate and fibrin accumulate, while white blood cells, macrophages, and mesothelial cells are proliferated and differentiated. These events lead to the accumulation of fibrin in conjunction with the formation of fibrous

bands and AB at the site of the surgical manipulation (3, 5). The said band can be located among the viscera, omentum, intestine, and abdominal wall, coupled with the accumulation of fibrous connective tissues and vascularization on the same (6). The incidence of such complications, following major abdominal surgeries, lies between 63–97%. Approximately, one-third of these patients are re-admitted owing to abdominal symptoms, over 20% in the first year post-operation (7). Till date, various methods have been used for preventing or treating AB, including the modification of techniques,

manipulations during operations, and the application of mechanical methods such as the creation of liquid or solid mechanical barriers and chemical agents between affected tissues (7).

In addition, several medications have been researched to aid the prevention of fibrin organization, inhibition of the fibroblasts' proliferation, and migration of inflammatory cells. These agents include selective non-steroidal anti-inflammatory drugs, corticosteroids, calcium channel blockers, histamine antagonists, antibiotics, fibrinolytic agents, anti-coagulants, antioxidants, hormones, vitamins, colchicine, and immunosuppressive drugs (7, 8). Furthermore, a study conducted on animals demonstrated that corticosteroids reduce AB formation by reducing vascular permeability and releasing cytokines as well as chemotactic factors (9). Dexamethasone is one of the synthetic corticosteroids used to reduce adhesion during operation and inflammatory edema (10, 11). On the other hand, betamethasone, another drug from this family, was used only in an animal study to prevent the formation of AB in a pelvic operation, which yielded favorable results (12). Regarding the use of corticosteroid medications in inflammatory condition, no studies have been conducted on the topical application in AB, even though limited success have been reported with the systemic therapy. Since the systemic therapy of corticosteroids has its own limitation, the use of local therapy could probably reduce its complications from systemic use. Accordingly, the present study was designed to investigate the effect of topical betamethasone on the prevention of peritoneal adhesion in an animal model.

## Materials and methods

This experimental study was conducted on 24 male Sprague-Dawley rats. All rats were kept at a Mean±SD temperature of 25-27 °C and provided with rodents' standard water and food ad libitum. This study was conducted after approval by the Ethics Committee (Code: IR.MAZUMS.REC.94) and following the animal protection laws.

The rats were randomly divided into 2 groups. They were anesthetized for the operation, using intramuscular injections of 40 mg/kg ketamine dihydrochloride. Then, their abdomens were shaved and disinfected with a 10% povidone-iodine solution. Free gloves were used during the procedure. All animals underwent laparotomy with a vertical 3-cm midline incision. The adhesion was induced by abrasion in an area of 2 cm<sup>2</sup> with dry gauze at the anti-mesenteric surface of the middle part of the small intestine.

It was followed by a sterile gauze scraping until a punctuate hemorrhage was created. In the experimental group, after this procedure and before closing the abdominal wall, 0.1% betamethasone ointment (Pars Darou Company, Tehran, Iran) was applied over the 2-cm<sup>2</sup> abrasion area. Afterward, the skin and fascia were closed in a single layer by using a simple continuous suture with 3-0 nylon.

Then, the animals were provided with free access to water and food for 14 days after the operation. On the 14<sup>th</sup>

day, the animals were scarified with ether. Next, they underwent laparotomy with a U-shaped section, and their adhesion rates were recorded (13). The number and location of the adhesions were reported using the Nair et al. classification by a surgeon, who was blind to the groups (14) (Table 1).

**Table 1.** Macroscopic adhesion scores

Description of Adhesive Band	Grade
Complete absence of adhesions	0
Single band of adhesion between viscera, or from one viscus to abdominal wall	1
Two bands either between viscera or from viscera to abdominal wall	2
More than two bands between viscera, or viscera to abdominal wall, or whole of intestines form a mass without being adherent to abdominal wall	3
Multiple dense adhesions or viscera directly adherent to the abdominal wall, irrespective of number or extent of adhesive bands	4

The biopsies taken from the AB region were fixed in 10% formalin. After routine tissue preparation, the serial sections were prepared with a 5-µm thickness and stained with hematoxylin and eosin. Based on the Quesada scoring system, the inflammatory reaction in biopsies was evaluated by a pathologist who was blind to the groups (15) (Table 2).

**Statistical Analysis:** The data were analyzed in SPSS 18. An independent samples t test was performed to compare the statistical significance of the continuous variables of both groups. The Chi-square test was performed for analyzing numerical data and the Fischer exact test for nonparametric data.  $P < 0.05$  was considered statistically significant.

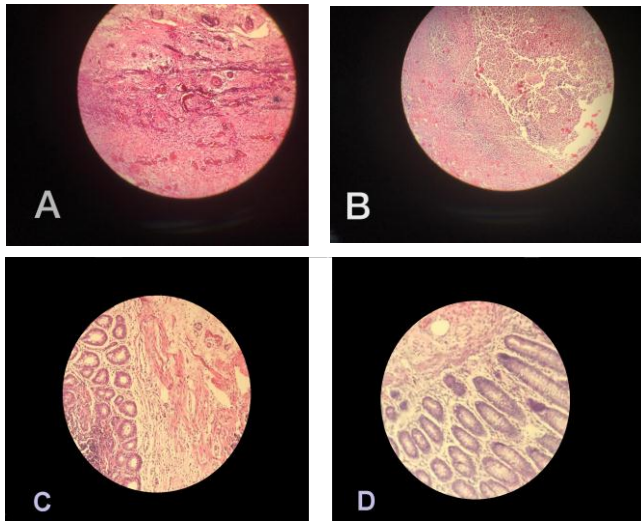
**Table 2.** Microscopic adhesion scores

Description of Adhesive Bands	Score
Presence of suture material (present or absent)	1
Continuity of mucosal epithelium (present or absent)	2
Abnormal proliferation of mucosal epithelium (present or absent)	3
Inclusion of mucosal tissue in the muscle layer (present or absent)	4
Presence of foreign body granulation tissue	5
Inflammatory reaction	6
Neovascularization	7

## Results

The Mean±SD weight values of the animals in the betamethasone and control groups were 136 (14.3) g and 129 (11.5) g, respectively. A total of 19 cases (79.1%) showed evidence of AB, which was 91.6% in the betamethasone group and 66.6% in the control group ( $P=0.31$ ). The Mean±SD number of adhesions the betamethasone and control groups were  $1.08\pm 0.66$  and  $1.17\pm 1.19$ , respectively. However, these differences were not significant ( $P=0.83$ ).

After assessing the location of the adhesions, it was found that except for one case in the control group, in which the intestine adhered to the abdominal wall, the rest of the adhesions were created between the intestine loops (intestine to intestine). In the pathological evaluation (Figure 1), mucosal epithelium in the abrasion site was observed in 15 cases, among which 10 were in the betamethasone group and 5 in the control group. Abnormal mucosal proliferation occurred in two cases, both of which belonged to the control group. However, these differences were not significant, too ( $P = 0.15$ ).



**Figure 1.** Histopathological findings of adhesion bands under light microscopy (Hematoxylin and Eosin stained slides 100× magnification). A. Grade 4 neovascularization; B. Grade 4 inflammation in untreated abrasion control group; C. Grade 1 inflammation and neovascularization in treated group (betamethasone); D. No significant inflammatory reaction in same group.

In terms of the inflammatory response and neovascularization, 19 samples were identified (Table 3) based on severity. However, there were no significant differences between the two groups ( $P=0.13$ ). The samples were examined for foreign body granulation, fibroblastic maturation (fibroplasia), and collagen sedimentation. The results showed no significant differences between the two groups ( $P>0.05$ ) (Table 4).

## Discussion

In an animal study conducted by Sahin et al., the role of 4 substances to prevent peritoneal adhesion following abdominal operation was examined (16).

For this purpose, they classified the rats into five groups; the control group, the chitin layer group, Na hyaluronate/

**Table 3.** Inflammatory responses in adhesion band region between the two groups

Inflammatory reaction	Group		Total
	betamethasone	control	
Absent	1	0	1
Mild	7	3	10
Moderate	2	4	6
Severe	1	1	2
<b>Total</b>	<b>11</b>	<b>8</b>	<b>19</b>

**Table 4.** Macroscopic and microscopic adhesion scores according to the groups

Parameter	Betamethasone group, Mean±SD	Control group, Mean±SD	Sig.
<b>Macroscopic adhesion score</b>	$1.08 \pm 0.66$	$1.17 \pm 1.16$	$P = 0.94$
<b>Microscopic adhesion score</b>	$5.83 \pm 2.79$	$4.75 \pm 4.02$	$P = 0.5$

carboxymethyl cellulose group, Na hyaluronate group, and injectable methylprednisolone group.

Finally, they concluded that all chemicals significantly reduced adhesion compared with the control group. We used corticosteroids in our study. However, it seems that systemic application may have more complications and, thus, we avoided it. In another study, Kucukozkan et al. examined the effect of saline, sodium cromoglycate, dexamethasone, and aprotinin alone or in combination, to reduce pelvic adhesions following operation in rabbits (10). All chemicals were injected intraperitoneally after the operation. In the end, they concluded that the intraperitoneal injection of sodium cromoglycate significantly reduced pelvic adhesions. Furthermore, the addition of dexamethasone and aprotinin proved to enhance sodium cromoglycate effect. In this study, they used systemic corticosteroids along with the intraperitoneal injection of sodium cromoglycate that acts as a catalyzer and an enhancer.

Sanfilippo et al. conducted a study on the effect of betamethasone on the reduction of peritoneal adhesion (12). They studied the intraperitoneal injection of methylprednisolone acetate, hydrocortisone acetate, betamethasone phosphate, and dexamethasone sodium

phosphate in an animal study after laparotomy and erosion of the uterus. One month later, they performed laparotomy and found that betamethasone phosphate significantly reduced tissue fibrosis in women compared with the other groups, but it did not affect the amount of inflammation and adhesion. Although this study was similar to our research regarding the use of betamethasone phosphate, the route of administration was intraperitoneal injection.

In this study, we avoid using systemic corticosteroids to reduce its potential complications. However, it was reasonable to use a coating on the top of the ointment to increase the amount of drug contact with the tissue. This subject can be further investigated in a new study. To increase the accuracy and reliability of obtained results, it seems better to conduct this study in larger sample sizes and with different forms of betamethasone (comparison of injection and topical form) with and without coating on the place of drug contact.

### Conclusion

The single-dose local application of betamethasone ointment after laparotomy cannot be effective in preventing peritoneal adhesion and inflammatory processes.

### Conflicts of Interests

The authors declare no conflict of interest regarding the publication of this paper.

### Acknowledgments

We express our gratitude to the Clinical Research Development Unit of Bu-Ali Sina Hospital and Mazandaran University of Medical Sciences for their collaboration in performing the study.

### References

1. Parker MC. Epidemiology of adhesions: the burden. *Hosp Med* 2004; 65:330-6.
2. Boland GM, Weigel RJ. Formation and prevention of postoperative abdominal adhesions. *J Surg Res* 2006; 132:3-12
3. Corona R, Verguts J, Schonman R, Binda MM, Mailova K, Koninckx PR. Postoperative inflammation in the abdominal cavity increases adhesion formation in a laparoscopic mouse model. *Fertil Steril* 2011; 95:1224-8.
4. diZerega GS. Biochemical events in peritoneal tissue repair. *Eur J Surg Suppl* 1997; 577:10-6.
5. diZerega GS, Campeau JD. Peritoneal repair and post-surgical adhesion formation. *Hum Reprod Update* 2001; 7:547-55.
6. Diamond MP, Freeman ML. Clinical implications of postsurgical adhesions. *Hum Reprod Update* 2001; 7:567-76.
7. Arung W, Meurisse M, Detry O. Pathophysiology and prevention of postoperative peritoneal adhesions. *World J Gastroenterol* 2011; 17:4545-53.
8. Risberg B. Adhesions: preventive strategies. *Eur J Surg Suppl* 1997; 577:32-9.
9. Liakakos T, Thomakos N, Fine PM, Dervenis C, Young RL. Peritoneal adhesions: etiology, pathophysiology, and clinical significance. Recent advances in prevention and management. *Dig Surg* 2001; 18:260-73.
10. Kucukozkan T, Ersoy B, Uygur D, Gundogdu C. Prevention of adhesions by sodium chromoglycate, dexamethasone, saline and aprotinin after pelvic surgery. *ANZ J Surg* 2004; 74:1111-5.
11. Gong JF, Zhu WM, Yu WK, Li N, Li JS. Conservative treatment of early postoperative small bowel obstruction with obliterative peritonitis. *World J Gastroenterol* 2013; 19:8722-30.
12. Sanfilippo JS, Cox JG, Nealon NA, Barrows GH. Comparison of corticosteroid therapy in the prevention of pelvic tissue reaction and adhesion formation. *Int J Fertil* 1986; 30:57-61.
13. Kurukahvecioglu O, Koksak H, Gulbahar O, Erdem O, Engin D, Yazicioglu O, et al. Infliximab "TNF-alpha antagonist" decreases intraabdominal adhesions. *Saudi Med J* 2007; 28:1830-5.
14. Nair SK, Bhat IK, Aurora AL. Role of proteolytic enzyme in the prevention of postoperative intraperitoneal adhesions. *Arch Surg* 1974; 108:849-53.
15. Quesada G, Diago V, Redondo L, Rodriguez-Toves L, Vaquero C. Histologic effects of different suture materials in microsurgical anastomosis of the rat uterine horn. *J Reprod Med* 1995; 40:579-84.
16. Sahin M, Cakir M, Avsar FM, Tekin A, Kucukkartallar T, Akoz M. The effects of anti-adhesion materials in preventing postoperative adhesion in abdominal cavity (anti-adhesion materials for postoperative adhesions). *Inflammation* 2007; 30:244-9.