

A Rare Case of a Type IV Dual Left Anterior Descending Artery and Ectopic Left Anterior Descending and Circumflex Arteries Requiring Surgery

Muhammad Mansoor, MBBS, FCPS¹, Waqar Ahmad Khan, MBBS, FCPS¹,
Fakhar Abbas, MBBS, FCPS, MD², Usha Kumari, MBBS, FCPS, MD^{3*}

¹National Institute of Cardiovascular Disorders, Karachi, Pakistan.

²Mayo Hospital, King Edward Medical University, Lahore, Pakistan.

³Dow University of Health Sciences, Karachi, Pakistan.

Received 03 January 2022; Accepted 28 February 2022

Abstract

Congenital anomalous coronary arteries (CACAs) comprise an important variant of the coronary vasculature. They are benign in the vast majority of cases, whereas a small minority may be affected by serious consequences such as myocardial infarction, arrhythmia, cardiac arrest, and even death. We herein describe a 62-year-old man with sudden and severe substernal chest pain; Q waves in electrocardiographic leads II, III, and aVF; and positive serum troponin I enzyme. Left heart cardiac catheterization revealed triple coronary vessel disease with a 60% to 70% occlusion in the left main coronary artery (LMCA). The left anterior descending (LAD) and the left circumflex artery arose from the ostium of the right coronary artery. Additionally, a rudimentary type IV dual LAD originated from the LMCA. A coronary artery bypass graft surgery was performed using a left internal mammary artery graft for the LAD and a saphenous vein graft for the diagonal branches (I & II) of the LAD and the posterior descending artery. The patient was discharged after an uneventful 1-week hospital course.

J Teh Univ Heart Ctr 2022;17(2):71-74

This paper should be cited as: Mansoor M, Khan WA, Abbas F, Kumari U. A Rare Case of a Type IV Dual Left Anterior Descending Artery and Ectopic Left Anterior Descending and Circumflex Arteries Requiring Surgery. *J Teh Univ Heart Ctr 2022;17(2):71-74.*

Keywords: Coronary vessel anomalies; Coronary vessels; Angiography; Cardiac catheterization

Introduction

The heart is a vital organ as it pumps blood to the whole body. However, the vitality of the heart depends on the coronary arteries. Coronary arteries arise from various types of mesodermal cells. During embryonic life, defects in coronary angiogenesis may arise, leading to the development of congenital anomalous coronary arteries (CACAs).¹

Most CACAs are benign and account for modest

alterations in the coronary arterial origin. A tiny minority of the vulnerable population develops cardiac problems.² Separate origins of the left anterior descending (LAD) and the left circumflex artery (LCX), origination of the coronary arteries from the sinus of Valsalva, aberrant origination of the ascending aorta, coronary-coronary communications, and absent branches are among the benign variants. The potentially threatening variants include coronary arteries arising from the pulmonary artery or the opposite aortic

*Corresponding Author: Usha Kumari, Dow University of Health Sciences, Karachi, Pakistan. PO Box 74400. Tel: & Fax +92 3082032418. E-mail: ughansham@yahoo.com.



sinus, solitary coronary arteries, and large coronary fistulae.² Bland-White-Garland syndrome is a congenital vascular defect caused by the anomalous left coronary artery from the pulmonary artery (ALCAPA), and it has been reported in 1 out of every 300 000 individuals in the United States. If untreated, 90% of patients with ALCAPA die within infancy due to ischemia or heart failure.³

CACAs are deemed a major concern in children and young adults.¹ In young individuals presenting with cardiac complaints, it is important to include CACAs in the differential diagnosis. Identifying variations in the course and understanding the clinical importance of these variants are crucial. Imaging plays a significant role in the diagnosis of CACAs.¹ Therefore, the angiographer must be able to detect abnormalities to perform correct assessments and minimize management errors. To avoid unintentional manipulation of the vessels during surgery, the cardiovascular surgeon must know the aberrant anatomy.

We herein describe a 62-year-old man diagnosed with non-ST-elevation myocardial infarction due to the aberrant origins of the LAD and the LXC from the right coronary cusp, requiring surgical intervention.

Case Report

A 62-year-old man was brought to the emergency department due to severe substernal chest pain associated with shortness of breath and nausea of 1 day's duration. The pain was central, crushing in nature, and radiating to the left arm.

On physical examination, the patient was lying on the bed in distress. He was conscious and oriented to time, place, and person. In addition, heart rate was 90 beats per minute and regular, without murmurs, rubs, or gallops; oxygen saturation was 97%; jugular venous pressure was normal; and no peripheral edema was detected. Further, the systemic review yielded no significant findings. The patient had a 60-pack-year of smoking history, and his family history was insignificant.

Baseline investigations were normal. Twelve-lead electrocardiography (ECG) demonstrated left-axis deviation, and leads II, III, aVF showed Q waves. The blood troponin-I level was 6 ng/mL. The patient was diagnosed as non-ST-elevation myocardial infarction Killip class I. He was given aspirin (300 mg), clopidogrel (300 mg), and enoxaparin (1 mg/kg) and was admitted to the hospital.

Left heart cardiac catheterization showed that the left main coronary artery (LMCA) was 60% to 70% occluded. The LMCA gave rise to the septal and diagonal (I & II) branches. Additionally, there was an 80% occluded rudimentary LAD branch (type IV dual LAD) (Figure 1). The right coronary cusp gave rise to the LAD with a 90% to 95% occlusion (Figures 2 & 3) and the LCX with a 70% to 80% occlusion

(Figure 2). The right coronary artery arose from the septal branches. In addition, it had a 100% occlusion in its proximal segment (Figure 2), and it was filled by the left coronary system retrogradely via the collateral circulation.

Echocardiography illustrated a normal-sized LV with mild systolic dysfunction, akinetic inferior and mid-posterior walls, and an ejection fraction of 45%. The cardiac valves were structurally normal.

The patient was referred to a tertiary care cardiovascular center, where he was advised to undergo coronary artery bypass graft surgery. A left internal mammary artery graft was used for the LAD, and a saphenous vein graft was utilized for the diagonal arteries I and II and the posterior descending artery. Postoperative transthoracic echocardiography demonstrated a normalized left ventricular ejection fraction of 50%.

After a 1-week hospital course, the patient was discharged home with the following medications: aspirin (300 mg once daily), clopidogrel (75 mg once daily), metoprolol (25 mg twice daily), enalapril (5 mg once daily), atorvastatin (20 mg once daily), and furosemide (40 mg once daily). Written informed consent was obtained from the patient for the publication of the case.

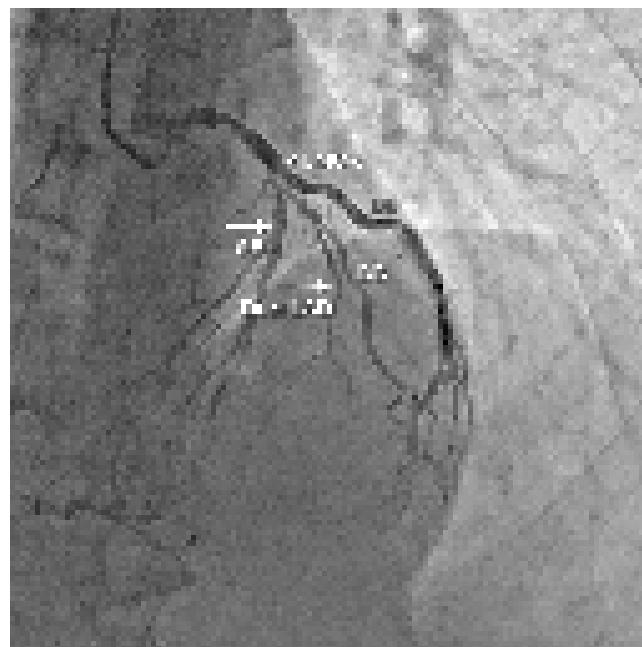


Figure 1. The coronary angiogram shows the left-sided coronary system in the right oblique angle cranial view.

LMCA, Left main coronary artery (The arrow shows a 60% to 70% occlusion.); SB, Septal branch of the LMCA; Dual LAD, Type IV dual LAD (rudimentary left anterior descending artery) (The arrow shows an 80% occlusion.); DB, Diagonal branches of the LMCA

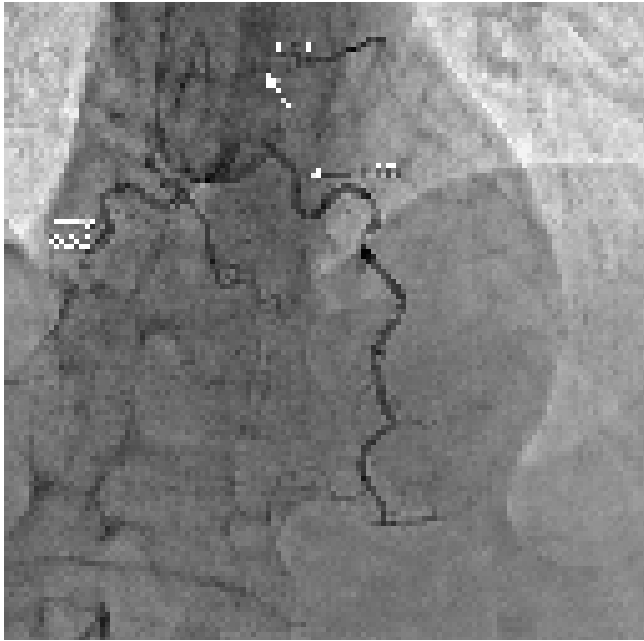


Figure 2. The coronary angiogram shows the left-sided coronary system in the anteroposterior cranial view.

LCX, Left circumflex artery arising from the right coronary cusp (The arrow shows a 90% to 95% occlusion.); RCC, Right coronary cusp giving rise to the right coronary artery (The arrow shows a 100% occlusion.); LAD, Left anterior descending arising from the RCC (The arrow shows a 70% to 80% occlusion.)

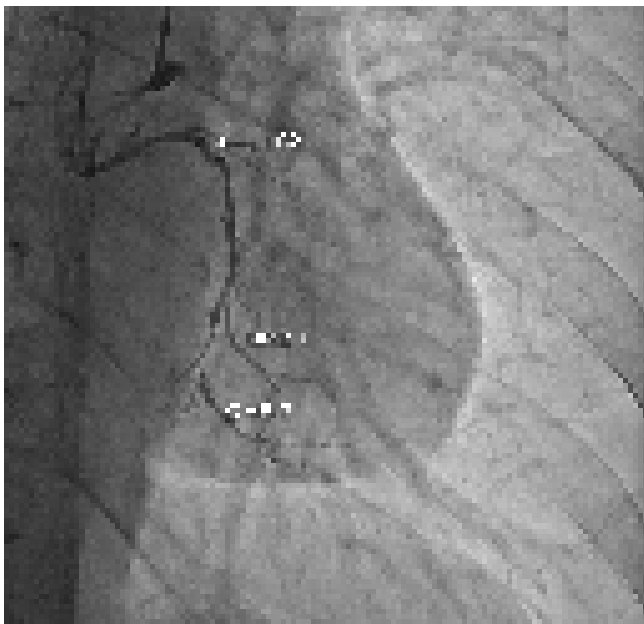


Figure 3. The coronary angiogram shows the right-sided coronary system in the caudal view.

LAD, Left anterior descending artery; LCX, Left circumflex artery aberrantly arising from the right coronary cusp; OMB-1 and OMB-2, Obtuse marginal (I & II) branches; RCC: Right coronary cusp

Discussion

CACAs are uncommon and have an incidence rate ranging from 0.2% to 5.7%.^{1,4} They are linked to various inborn cardiac defects such as the transposition of the major cardiac vessels, bicuspid aortic valves, arteriovenous fistulae, and the tetralogy of Fallot.^{1,4} The LAD originates from the LCX at the right and left sinuses of Valsalva, accounting for 2.3% and 30.4% of CACAs, respectively.² A single aberrant origin of the LAD from the right coronary artery, as identified in our case, is a rare finding.

It is critical to understand the effects of CACAs for their identification. The vast majority of CACAs are identified by chance, and almost 81% are known to be benign without any clinical relevance. Malignant abnormalities, on the other hand, can induce ischemic cardiac lesions, particularly when there is a high oxygen demand by the myocardium. Angina pectoris, cardiac arrhythmia, sudden cardiac death, syncope, and heart failure can also result from these abnormalities.² Coronary abnormalities are considered the second most frequent reason for sudden cardiac death, especially in athletes, accounting for 19%.⁵ Moreover, it has also been proposed that abnormal vascular genesis and abnormal progression may predispose an individual to atherosclerosis.⁶

There is a dearth of comprehensive data on the care of patients with CACAs, particularly if they are asymptomatic. In high-risk patients, management varies from mere observation to surgical intervention. Multidetector computerized tomography, a noninvasive technique, is useful in identifying the course of the complex vasculature, including origin and termination. The technique has been established as the gold standard for diagnosing and classifying CACAs.⁷ Nonetheless, coronary angiography, an invasive procedure, has gained superiority given that it is more accessible and provides the opportunity to perform a concurrent intervention if required.⁸

The treatment of anomalous arteries necessitates thoughtful consideration. Corrective surgery is indicated if a patient has a severe malignant CACA. The problem arises in asymptomatic cases with an underlying malignant CACA. Some may advise against surgery because of the overall scarcity of sudden cardiac death, particularly in those aged above 30 years.⁹ Meanwhile, if the coronary architecture allows for instrumentation, percutaneous stenting can be used for treating lesions caused by atherosclerosis.¹⁰ In other cases, open-heart surgery may be drawn upon.

Written informed consent was acquired from the patient regarding the publication of the case.

In this case, the patient had the LAD and the LCX ectopically arising from the right coronary cusp. The rare, albeit serious, sequelae of CACAs mandate increased awareness regarding their timely diagnosis and management among cardiologists and cardiac surgeons.

Conclusion

In this case, the patient had the left anterior descending and the left circumflex artery ectopically arising from the right coronary cusp. The rare, albeit serious, sequelae of congenital anomalous coronary arteries mandate increased awareness regarding their timely diagnosis and management among cardiologists and cardiac surgeons.

References

1. Pérez-Pomares JM, de la Pompa JL, Franco D, Henderson D, Ho SY, Houyel L, Kelly RG, Sedmera D, Sheppard M, Sperling S, Thiene G, van den Hoff M, Basso C. Congenital coronary artery anomalies: a bridge from embryology to anatomy and pathophysiology--a position statement of the development, anatomy, and pathology ESC Working Group. *Cardiovasc Res* 2016;109:204-216.
2. Yamanaka O, Hobbs RE. Coronary artery anomalies in 126,595 patients undergoing coronary arteriography. *Cathet Cardiovasc Diagn* 1990;21:28-40.
3. Vilá Mollinedo LG, Jaime Uribe A, Aceves Chimal JL, Martínez-Rubio RP, Hernández-Romero KP. Case Report: ALCAPA syndrome: successful repair with an anatomical and physiological alternative surgical technique. *F1000Res* 2016;5:1680.
4. Akcay M, Camlıdag I, Gulel O. Percutaneous coronary intervention for coronary arteries with origin and course anomalies: case reports and literature review. *J Teh Univ Heart Ctr* 2019;14:141-145.
5. Rajani AR, Rafiq MA, Mian MH, Baslaib FO. Anomalous left anterior descending artery: an uncommon cause of ST elevation myocardial infarction. *BMJ Case Rep* 2015;2015:bcr2014209221.
6. Mironov A, Galligan S, Kakauridze A, Marmur JD. An obstructed anomalous left anterior descending coronary artery arising from the right coronary artery requiring surgical intervention. *Case Rep Cardiol* 2016;2016:3589214.
7. Fujimoto S, Kondo T, Orihara T, Sugiyama J, Kondo M, Kodama T, Fukazawa H, Nagaoka H, Oida A, Yamazaki J, Takase S. Prevalence of anomalous origin of coronary artery detected by multi-detector computed tomography at one center. *J Cardiol* 2011;57:69-76.
8. John J, Miller JH, Leslie SJ. A case of anomalous coronary artery origin: The role of computerised tomography. *SAGE Open Med Case Rep* 2016;4:2050313X16628729.
9. Cheitlin MD, MacGregor J. Congenital anomalies of coronary arteries: role in the pathogenesis of sudden cardiac death. *Herz* 2009;34:268-279.
10. Masuda N, Matsukage T, Ikari Y. Successful transradial intervention for two lesions with dual anomalous origins of coronary arteries. *J Invasive Cardiol* 2011;23:E117-120.