



Intramyocardial Mass with an Echo-Free Center as an Echocardiographic Presentation of Hypertrophic Cardiomyopathy

Zahra Alizadeh-Sani, MD^{1,2}, Ali Hosseinsabet, MD^{3*}

¹Rajaie Cardiovascular Medical and Research Center, Iran University of Medical Sciences, Tehran, Iran.

²Omid Hospital, Iran University of Medical Sciences, Tehran, Iran.

³Tehran Heart Center, Tehran University of Medical Sciences, Tehran, Iran.

A 43-year-old man presented to the emergency department with atypical chest pains. Physical examinations yielded no significant findings. Serial electrocardiography and high-sensitivity troponin measurements were normal. Transthoracic echocardiography in the emergency department revealed increased septal wall thickness; therefore, the patient was referred to the echocardiography ward for further evaluation.

The echocardiographic findings were normal, except for an intramyocardial mass with an echo-free center in the base-to-mid portion of the inferior and inferoseptal walls (Figures 1. A, B & C). Additionally, the base and mid portions of the anteroseptal wall were hypertrophied. Cardiac magnetic resonance imaging demonstrated myocardial hypertrophy in the base and mid portions of the anteroseptal, inferoseptal, and inferior walls (Figures 2. A, B, C, D & E), as well as a patchy mid-wall appearance of late gadolinium enhancement, at the anterior and posterior junction of the right ventricle to the left ventricle (Figures 2. F, G & H). The findings were typical of hypertrophic cardiomyopathy.

What was revealed in the late gadolinium-enhanced images was compatible with the echo-free space in echocardiography. Otherwise speaking, the cardiac magnetic resonance images delineated the background pathology (hypertrophic cardiomyopathy) and revealed fibrosis as the etiology of the echo-free space in echocardiography. Holter monitoring of electrocardiography was unremarkable.

To our knowledge, intramyocardial masses with echo-free centers as an echocardiographic presentation of hypertrophic cardiomyopathy have not been reported yet. Accordingly, in the differential diagnosis of the aforementioned echocardiographic findings, hypertrophic cardiomyopathy should be included. Cardiac magnetic resonance imaging in this condition is helpful.

J Teh Univ Heart Ctr 2021;16(2):89-91

This paper should be cited as: Alizadeh-Sani Z, Hosseinsabet A. Intramyocardial Mass with an Echo-Free Center as an Echocardiographic Presentation of Hypertrophic Cardiomyopathy. *J Teh Univ Heart Ctr* 2021;16(2):89-91.

Keywords: Cardiomyopathy, hypertrophic; Chest pain; Echocardiography

*Corresponding Author: Ali Hosseinsabet, Associate Professor of Cardiology, Tehran Heart Center, North Karegar Street, Tehran, Iran. 1411713138. Tel: +98 21 88029731. Fax: +98 21 88029731. E-mail: a-hosseinsabet@tums.ac.ir



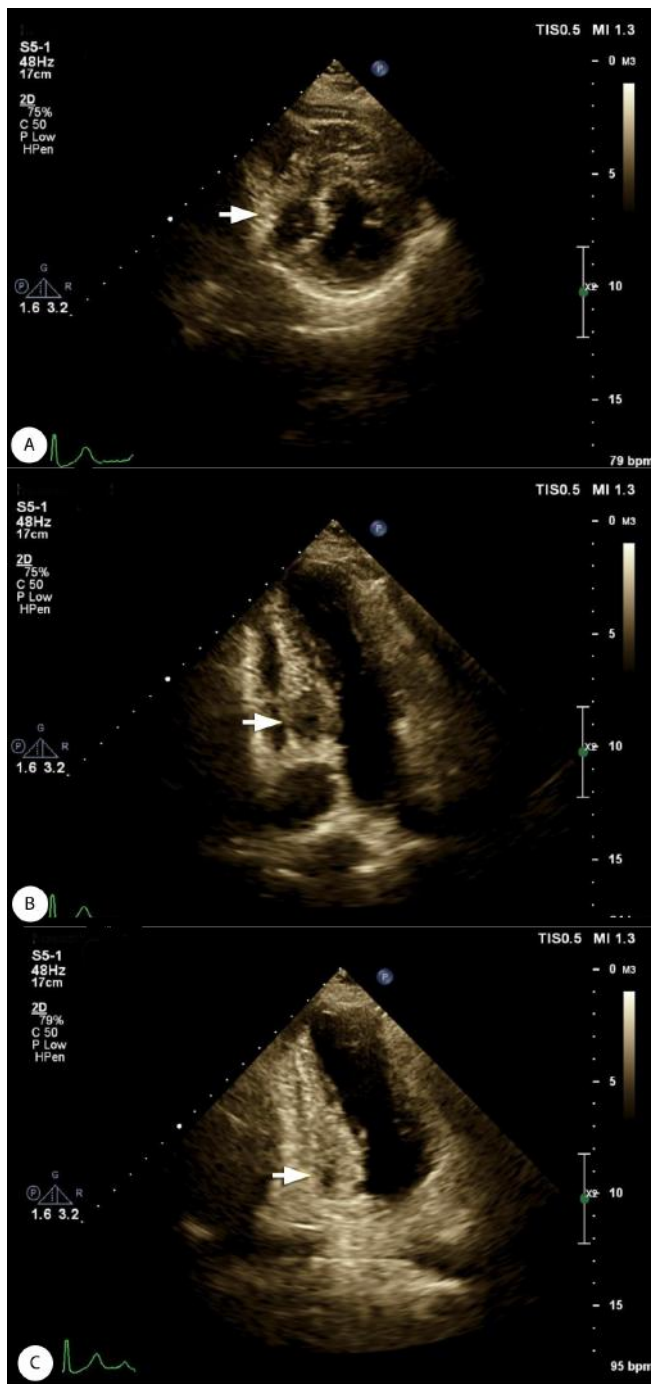


Figure 1. Transthoracic echocardiography shows an intramyocardial mass with an echo-free center (arrow) in the base-to-mid portion of the inferior and inferoseptal walls.

A) Short-axis view, B) Modified apical 4-chamber view, and C) Apical 2-chamber view

LA, Left atrium; LV, Left ventricle; RA, Right atrium

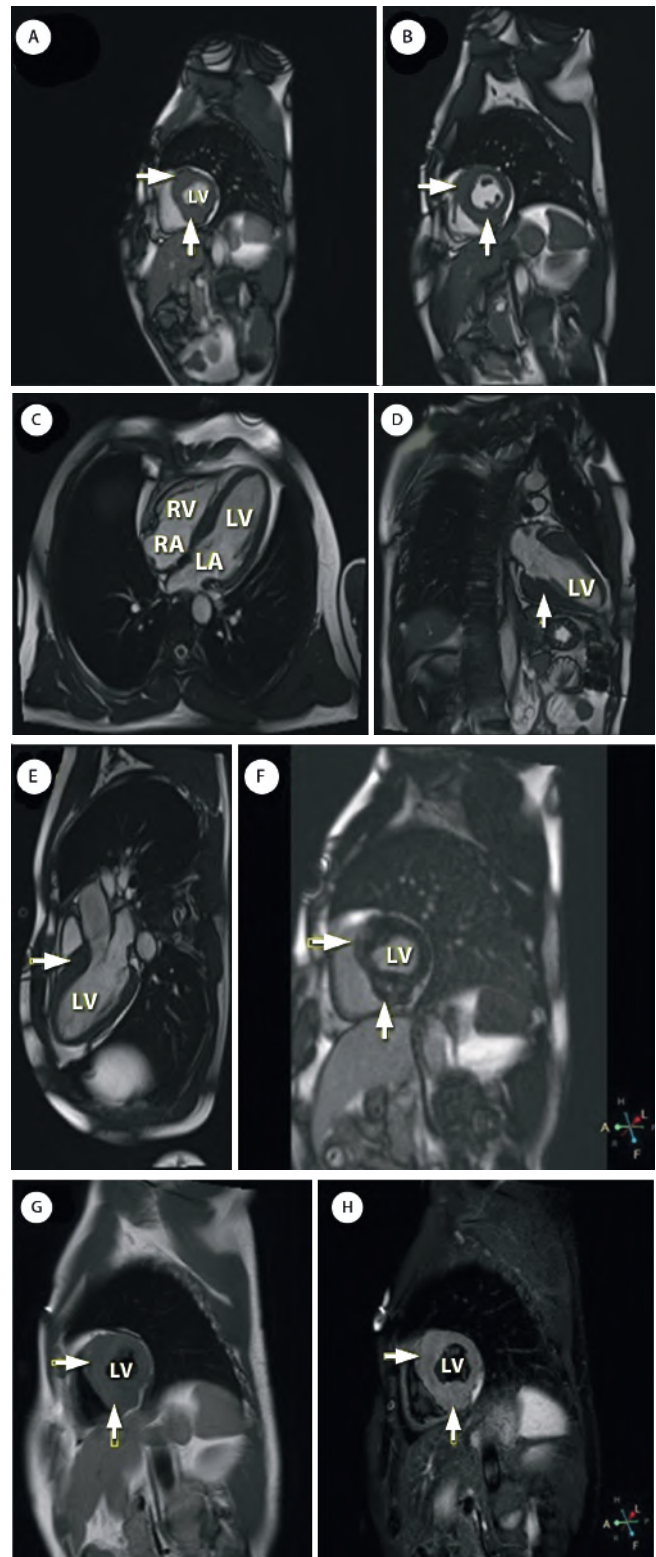


Figure 2. Diastolic SSFP images (A–E) with T1- and T2-weighted and late gadolinium-enhanced images (F–H) illustrate asymmetric septal hypertrophy and base- and mid-inferior wall hypertrophy in cardiac magnetic resonance imaging (arrows). Additionally, patchy mid-wall fibrosis is demonstrated in the late gadolinium-enhanced images (arrows).

A) Basal short-axis view, B) Mid-ventricular short-axis view, C) 4-chamber



view, D) 2-chamber view, E) 3-chamber view and G-H) Basal short-axis view
SSFP, Steady-state free precession; LA, Left atrium; LV, Left ventricle; RA, Right atrium; RV, Right ventricle

To watch the following videos, please refer to the relevant URLs:

<https://jthc.tums.ac.ir/index.php/jthc/article/view/1346/969>

Video 1. Echocardiography reveals an intramyocardial mass with an echo-free center in the base-to-mid portion of the inferior and inferoseptal walls.

<https://jthc.tums.ac.ir/index.php/jthc/article/view/1346/970>

Video 2. Cardiac magnetic resonance imaging in the steady-state free precession mode reveals asymmetric septal hypertrophy and hypertrophy in the base-to-mid portion of the inferior wall.