



Unusual Needle Migration into the Heart of a Pediatric Patient

Noor Mohamad Noori, MD¹, Seyed Hosein Soleimanzadeh Mousavi, MD^{2*},
Changiz Azadi Ahmadabadi, MD²

¹Children and Adolescents Health Research Center, Ali-Ibn-Abitaleb Hospital, Zahedan University of Medical Sciences, Zahedan, Iran.

²Ali-Ibn-Abitaleb Hospital, Zahedan University of Medical Sciences, Zahedan, Iran.

Received 09 June 2020; Accepted 28 October 2020

Abstract

Sharp-object penetration into the chest is rare and may lead to life-threatening complications, hence the significance of early detection and removal. We present an uncommon case of the accidental penetration of a sewing needle into the chest of a 5-year-old girl, with the needle traveling from the entrance site to the right ventricle through the lung tissue. Due to the possibility of cardiovascular accidents, the patient was transferred to a special ward. For positioning and correct actions, TTE and CT scan of the chest with and without contrast were performed and the presence of a tangential needle with the right ventricular wall and inside the pericardium was reported. The patient was taken to the operating room, and after exploring, a 2 cm needle was inserted into the right ventricle and removed. The patient was discharged after 5 days.

J Teh Univ Heart Ctr 2021;16(1):34-37

This paper should be cited as: Noori NM, SH Soleimanzadeh Mousavi, Azadi Ahmadabadi C. Unusual Needle Migration into the Heart of a Pediatric Patient. *J Teh Univ Heart Ctr 2021;16(1):34-37.*

Keywords: Needles; Echocardiography; Foreign-body migration; Heart ventricles

Introduction

The accidental entry of a sewing needle into the chest is a rare occurrence.¹ In this situation, due to the high dynamics and mobility of the chest, the probability of needle displacement and migration is very high.² In the limited number of the reported cases of accidental needle penetration into the chest, open-heart surgery is recommended as the ultimate solution.^{3,4} External objects inside the right ventricle (RV) are exceedingly uncommon. In this paper, we report a case of the accidental entry of a sewing needle into the chest of a 5-year-old girl, who underwent surgery for foreign-object removal.

Case Report

A 5-year-old girl with accidental needle penetration into the right side of the chest while playing was referred to our medical center from a rural hospital. The interval between referral and arrival at our center was 12 hours. Upon arrival, the patient was transferred to the pediatric intensive care unit due to the possibility of cardiovascular events. She was asymptomatic at admission with a visible scar mark on the right side of the chest at the entrance site of the needle. She had normal vital signs and heart and lung sounds. The rest of her physical examination revealed nothing remarkable except for intermittent restlessness in the absence of associated dyspnea.

*Corresponding Author: Seyed Hosein Soleimanzadeh Mousavi, Zahedan University of Medical Sciences, Ali-Ibn-Abitaleb Hospital, Khalije Fars Highway, Zahedan, Iran. 9816743111. Tel: +98 54 33372151. Fax: +98 54 33372152. E-mail: dr_soleimanzadeh@yahoo.com.





Eleven hours after hospitalization, via chest radiography and transthoracic echocardiography (TTE), our pediatric cardiologist detected a hyper-refractile linear structure behind the sternum. The object was tangent to the RV wall and superior to the tricuspid valve. One end of the needle was tangent to the lateral wall of the RV, and the other end was embedded into the lung tissue and moving with each heartbeat (Figures 1 & 2).

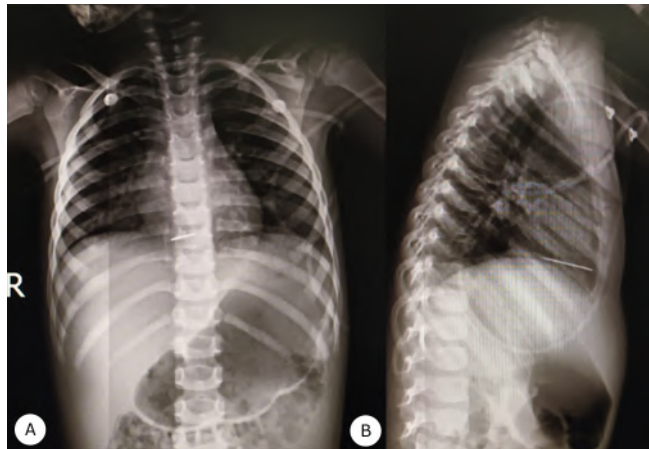


Figure 1. Posteroanterior (A) and Lateral (B) chest radiography views show a sewing needle in the lung cavity and the mid-mediastinum.

The patient's restlessness was aggravated with time. Two hours after TTE, a chest computed tomography (CT) scan showed the needle in the RV inside the pericardium. The difference in the location of the needle in the scan relative to that in echocardiography suggested the migration of the needle into the heart wall (Figure 3).

The patient was treated with prophylaxis antibiotics for any infection possibilities. After consultation with a cardiac surgeon, she was sent to the operating room just 72 hours after needle penetration. A right thoracotomy revealed 0.5 cm of the needle, but the remainder of the needle (3 cm) was lodged in the RV. The surgeon grasped the needle with anatomical forceps and extracted it from the heart gently, without incising the muscle (Figure 4).

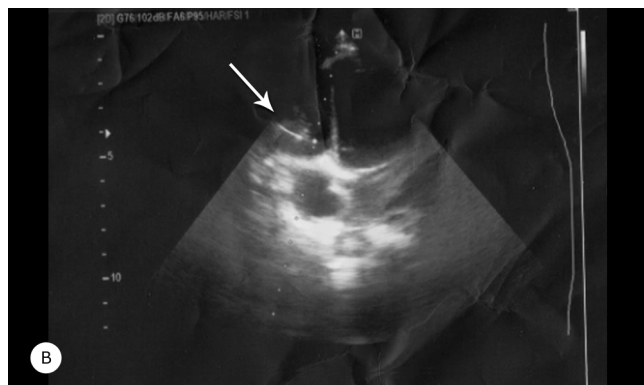
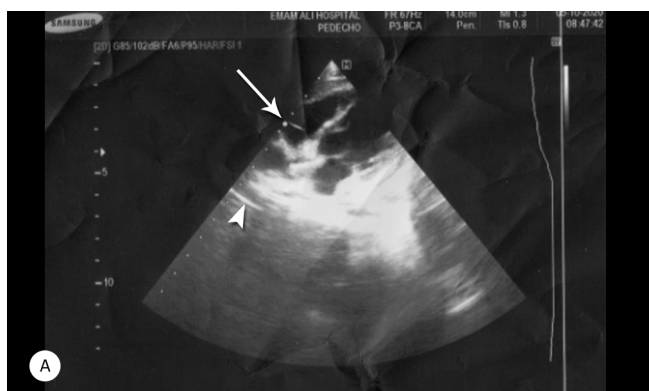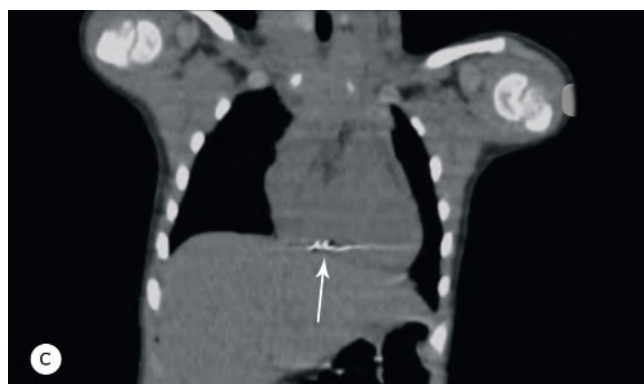
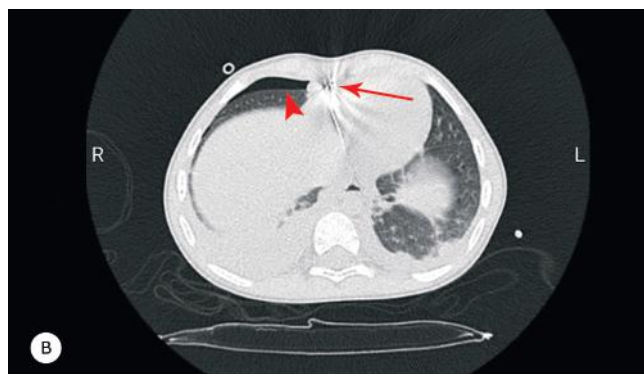
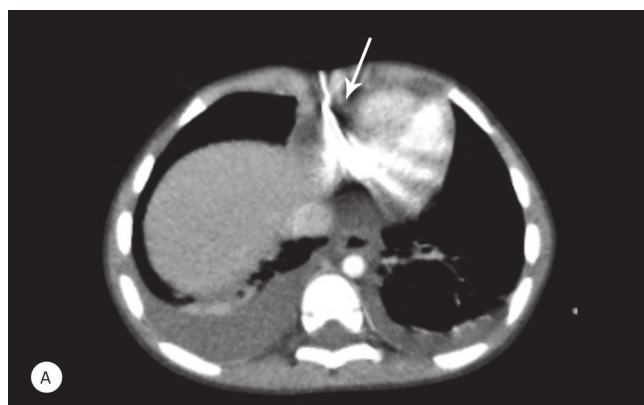


Figure 2. Transthoracic echocardiography views (A & B) show a hyper-refractile linear structure (arrows) tangent to the right ventricular wall, together with its acoustic shadow (arrowhead).



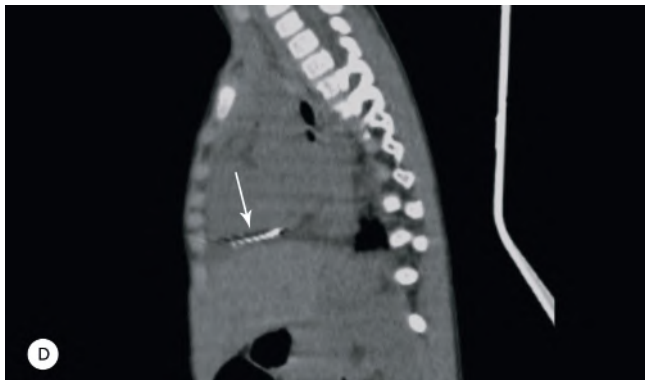


Figure 3. Computed tomography scans show the needle (arrow) in the lower front part of the chest (A & B). The entry point of the needle is from the fat area around the pericardium tangent to the diaphragm. A small bubble of air is seen in the anterior part of the pericardium near the right ventricle in the upper part of the needle (arrowhead) (B). Coronal (C) and Sagittal (D) views show that the needle pathway is very close to the pericardium (arrows).




Figure 4. The image shows the sewing needle, about 3.5 cm in length.

Afterward, the laceration was repaired, and 100 mL of blood was evacuated from the pericardium cavity. The control TTE and chest X-ray showed no remaining pericardial effusion.

Discussion

Piercing heart injury caused by needles is uncommon.⁵ In this situation, the high dynamics and mobility of the chest elevate the probability of needle displacement and migration.² The literature contains only a few reports on accidental needle penetration into the chest; nevertheless, all of them underscore the role of surgery in foreign-object removal.⁴ There are no standard guidelines concerning the removal of the needle for the management of symptomatic patients.⁶ Such patients can remain asymptomatic after

several years; still, chest pain and dyspnea are the most common symptoms.⁷ The most frequent complications of needle penetration into the chest are pericarditis, cardiac tamponade, endocarditis, and even sudden death.⁸

Foreign bodies that reach the heart more often do so in consequence of direct trauma (e.g., a bullet) or the unintentional insertion of an endovascular device (e.g., a needle), which is followed by intravenous travel to the heart.⁹ Previous studies have shown that piercing heart injury in the pediatric population is more common with sewing needles, whereas in adults, it tends to be a consequence of addiction, domestic violence, and suicide.⁴ In these cases, the needle frequently passes through blood vessels, and migration through body tissues is less commonly reported in studies.

Our patient was asymptomatic, and a chest X-ray initially showed the needle in the chest cavity. A few hours later, a TTE examination demonstrated that the needle was tangent to the RV. At the same time, a chest CT scan showed that the needle had entered the RV pericardium. Due to the emergency nature of the case, the patient was transferred to the operating room 72 hours after the penetration of the needle. During surgery, it was observed that 3 cm of the needle was inside the RV. This scenario indicates the high tendency of needles to migrate into the lung tissue and penetrate the heart. Fortunately, our patient did not have any side effects owing to our immediate action.

Timely diagnosis and treatment are crucial to the treatment of patients with piercing heart injury. We recommend emergency TTE and CT scanning in pediatrics with sharp object penetration into the chest. Surgery, as an emergency treatment modality, should be considered because of the rapid migration of sharp objects to the heart. Delayed treatment may result in damage to the walls of the heart and rupture of the heart muscle.

Conclusion

Even though sharp object penetration into the heart is rare, a close determination of the exact location for further management is needed. An emergency open-heart surgery for the removal of the sharp object seems to be safer and more effective than conservative procedures.

References

1. Talwar S, Subramaniam KG, Subramanian A, Kothari SS, Kumar AS. Sewing needle in the heart. *Asian Cardiovasc Thorac Ann* 2006;14:63-65.
2. Dal F, Hatipoğlu E, Teksöz S, Ertem M. Foreign body: a sewing needle migrating from the gastrointestinal tract to pancreas. *Turk J Surg* 2018;34:256-258.
3. Soren S, Surjit, Chaudhury S, Bakhla AK. Multiple self-inserted pins and nails in pericardium in a patient of schizophrenia: case



- report and review. *Ind Psychiatry J* 2015;24:82-87.
4. Perrotta S, Perrotta A, Lentini S. In patients with cardiac injuries caused by sewing needles is the surgical approach the recommended treatment? *Interact Cardiovasc Thorac Surg.* 2010;10:783-792.
 5. Supomo, Darmawan H. An unusual foreign body in the heart: a case report. *Ann Thorac Cardiovasc Surg* 2018;24:205-207.
 6. Ghatak A, Baik P, Cardoso R, Dobrinsky J, Kaynak H, Marzouka G, Stang R, Carrillo R, Williams D, Heldman AW. The story of the lost needle: foreign body embolization to the heart. *J Cardiol Cases* 2015;11:175-177.
 7. Gungor H, Duygu H, Yildiz BS, Gul I, Zoghi M, Ozerkan F. A remnant sewing needle in the right ventricle as a cause of chest pain. *Clin Cardiol* 2010;33:E23-25.
 8. Yamamoto H, Fukasawa Y, Kato T. Ventricular tachycardia and chest pain due to foreign body in the pericardium caused by self-injurious behaviour. *Cardiol Young* 2019;29:1217-1218.
 9. LeMaire SA, Wall MJ, Jr, Mattox KL. Needle embolus causing cardiac puncture and chronic constrictive pericarditis. *Ann Thorac Surg* 1998;65:1786-1787.