



Case Report

Treatment of Chylothorax with Pleurodesis, a Lesser Known Complication of Behçet's Disease: A Case Report

| 180

Ertan Demirdaş, MD^{1*}, Kıvanç Atilgan, MD¹, Zafer Cengiz ER, MD¹, Süleyman Emre Akin, MD²¹Department of Cardiovascular Surgery, Faculty of Medicine, Bozok University, Yozgat, Turkey.²Yozgat State Hospital, Yozgat, Turkey.

Received 17 November 2017; Accepted 23 August 2018

Abstract

Behçet's Disease (BD) is a multisystemic vasculitis which usually affects optical, genital, and oral mucosae and often reoccurs intermittently. Chylothorax is a very rare complication of BD which usually causes thrombosis in the major venous system. A 27-year-old man with a 10-year history of BD referred to our cardiovascular surgery department with symptoms of serious aches in the left arm, edema, and apparent veins on the left anterior chest wall. A total thrombosis of the left internal and external jugular veins and the left subclavian vein was observed. One month after a successful treatment and discharge, the patient returned to our clinic with symptoms of dyspnea and coughs. A chest radiograph showed a consolidated region. A milky liquid was aspirated through thoracocentesis from the left thorax, and its biochemical analysis helped us arrive at a diagnosis of chylothorax. The patient was hospitalized and administered corticosteroids and immunosuppressive therapy with a high-carbohydrate and low-fat dietary regimen for BD. Thereafter, a left thoracic drainage system was established. On the seventh day of hospitalization, due to a progressing cheilosis flow, a pleurodesis process was applied with talcum powder. However, the chylous drainage was continued and 60 mL of venous autologous blood was injected into the left thorax through a drainage tube. The treatment was successful, and the patient was discharged from the hospital uneventfully. At 1 month's follow-up, the chest radiograph was normal.

J Teh Univ Heart Ctr 2018;13(4):180-182

This paper should be cited as: Demirdaş E, Atilgan K, Cengiz ER Z, Emre Akin S. Treatment of Chylothorax with Pleurodesis, a Lesser Known Complication of Behçet's Disease: A Case Report. *J Teh Univ Heart Ctr 2018;13(4):180-182.*

Keywords: Chylothorax; Behcet syndrome; Vasculitis; Thrombosis

Introduction

Behçet's Disease (BD), which has an autoimmune pathophysiology, is a multisystemic vasculitis that usually reoccurs intermittently and affects optical, genital, and oral mucosae.¹⁻⁴ Although occasionally detected in various parts of the world, BD is seen more frequently in the Middle East, the Mediterranean region, and the Far East Asian countries.³⁻⁵ Chylothorax is a very rare complication of BD which usually causes thrombosis in the major venous system.²

Case Report

A 27-year-old man with a 10-year history of BD, which had been left untreated for the preceding 2 years, referred to our cardiovascular surgery department with symptoms of serious aches in the left arm, edema, and apparent veins on the left anterior chest wall. The color Doppler ultrasonography of the left upper extremity venous system showed a total thrombosis of the left internal and external jugular veins and the left subclavian vein.

*Corresponding Author: Ertan Demirdaş, Cardiovascular Surgery Department, Faculty of Medicine, Bozok of University, Erdoğan Akdağ Kampüsü Atatürk Yolu 7, Km 66900, Yozgat, Turkey. Tel: +90 5302422511. Fax: +90 3542171072. E-mail: dr.ertandemirdas@gmail.com.

A single dose of low molecular weight heparin (LMWH) (7500 IU/0.3 mL of bemiparin sodium) treatment for a day, antibiotics, and anti-inflammatory drugs were ordered. One month after the hospital discharge, the patient returned to our clinic with symptoms of dyspnea and coughs. A physical examination revealed decreased occultation sounds in the middle and bottom fields of the left thorax. A posteroanterior direct chest radiograph illustrated a consolidated region, in line with the auscultation findings (Figure 1). A milky liquid was aspirated via thoracocentesis from the left thorax and was subsequently biochemically analyzed; the results demonstrated total protein of 4.3 g/dL, albumin of 2.2 g/dL, total cholesterol of 47 mg/dL, and triglycerides of 287 mg/dL.

In light of the findings, a diagnosis of chylothorax was established. The patient was hospitalized and received single doses of LMWH, 0.5 mg of colchicine, 40 mg of an oral corticosteroid (prednisolone), 2 doses of oral immunosuppressive therapy (50 mg of azathioprine), and a high-carbohydrate and low-fat dietary regimen. A left thoracic drainage system was established for the patient. On the seventh day of hospitalization, due to a progressing cheilosis flow, a pleurodesis process was applied with talcum powder. However, the chylothorax progression continued for the following 3 days. Venous autologous blood (60 mL) was injected into the left thorax via a drainage tube, which was clamped in order to avoid the leakage of the blood back through it. For the ensuing 3 hours, the patient was moved into different lying positions. Two days later, the cheilosis flow decreased to an acceptable level, and the dietary limitations were canceled. At the end of the 15th day following the autologous blood pleurodesis process, the cheilosis flow totally disappeared. The patient was discharged with a treatment of an oral anticoagulant (5 mg of warfarin) and a single dose of an oral immunosuppressive therapy (50 mg of azathioprine). One month after the hospital discharge, no pathology was observed on a posteroanterior direct chest radiogram (Figure 2).

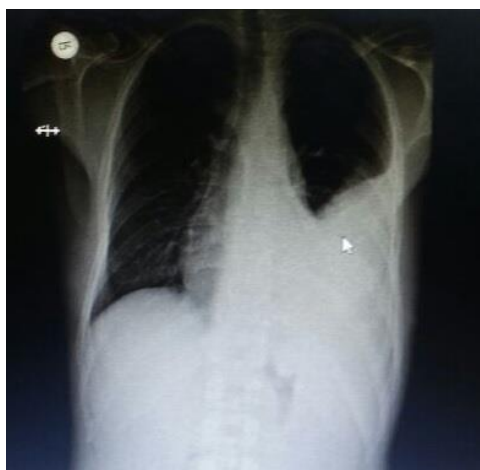

Figure 1. Posteroanterior chest radiography, on admission, shows a consolidated region in the left thoracic cavity (arrow).

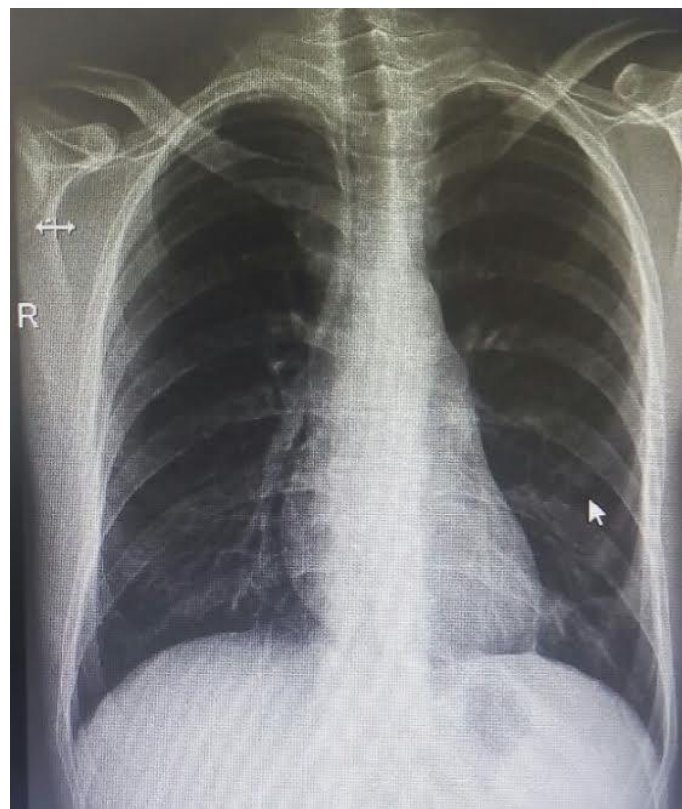


Figure 2. Control posteroanterior radiography, 1 month after the hospital discharge, shows the total resolution of the consolidated region (arrow).

Discussion

An inflammatory, multisystemic, and chronic vasculitis, BD can affect the optical, genital, and oral mucosae in the human body independently of size.⁶ The venous system is more vulnerable than the arterial system in BD.⁷

Chylothorax can be defined as the collection of a lymphatic liquid in the pleural space for any reason. The thoracic duct provides the lymphatic drainage of the cheilosis liquid, most of which comes from the intestines and drains into the venous system at the junction of the left subclavian and left jugular veins. Any obstruction at this junctional area may result in chylothorax.⁸ In BD, the thrombosis of the superior vena cava, the innominate vein, and the left subclavian vein may cause a disorder in the lymphatic drainage, which may lead to chylothorax.⁹

In the treatment of chylothorax related to BD, less invasive techniques should be preferred. These techniques basically are pleural effusion drainage, anticoagulant therapy for thrombosis, oral corticosteroids, immunosuppressive treatments, and high-carbohydrate and low-fat dietary regimens. In resistant cases, pleurodesis or the ligation of the thoracic duct via videothoracoscopy and thoracotomy should be preferred.¹⁰⁻¹²



In this case, we managed to treat a chylothorax related to BD with autologous blood pleurodesis.

Conclusion

Chylothorax related to BD, albeit a rare complication, is possible to cure with both medical and invasive techniques.

References

1. Yoo WH, Moon JS, Kim SI, Kim WU, Min JG, Park SH, Lee SH, Cho CS, Kim HY. A case of Behçet's disease with superior and inferior vena caval occlusion. *Korean J Intern Med* 1998;13:136-139.
2. Calamia KT, Schirmer M, Melikoglu M. Major vessel involvement in Behçet disease. *Curr Opin Rheumatol* 2005;17:1-8.
3. Erkan F, Gül A, Tasali E. Pulmonary manifestations of Behçet's disease. *Thorax* 2001;56:572-578.
4. Marzban M, Mandegar MH, Karimi A, Abbasi K, Movahedi N, Navabi MA, Abbasi SH, Moshtaghi N. Cardiac and great vessel involvement in "Behcet's disease". *J Card Surg* 2008;23:765-768.
5. Zouboulis CC. Epidemiology of Adamantiades-Behçet's disease. *Ann Med Interne (Paris)* 1999;150:488-498.
6. Mendes D, Correia M, Barbedo M, Vaio T, Mota M, Gonçalves O, Valente J. Behçet's disease--a contemporary review. *J Autoimmun* 2009;32:178-188.
7. Sarica-Kucukoglu R, Akdag-Kose A, Kayabali M, Yazganoglu KD, Disci R, Erzengin D, Azizlerli G. Vascular involvement in Behçet's disease: a retrospective analysis of 2319 cases. *Int J Dermatol* 2006;45:919-921.
8. Ozcelik C, Onat S, Bayar ES. Combined late diagnosed right main bronchial disruption and chylothorax from blunt chest trauma. *Ann Thorac Surg* 2004;78:e61-62.
9. Moon H, Lee YJ, Lee SI, Yoo WH. Chylothorax and chylopericardium as the initial clinical manifestation of Behcet's disease. *Rheumatol Int* 2008;28:375-377.
10. Al Jaaly E, Baig K, Patni R, Anderson J, Haskard DO. Surgical management of chylopericardium and chylothorax in a patient with Behçet's disease. *Clin Exp Rheumatol* 2011;29:S68-70.
11. Cöplü L, Emri S, Selçuk ZT, Kalyoncu F, Balkanci F, Sahin AA, Bariş YI. Life threatening chylous pleural and pericardial effusion in a patient with Behçet's syndrome. *Thorax* 1992;47:64-65.
12. Maayan H, Izbicki G, Heyd J, Cyter R, Silberman S, Deeb M. Persistent chylothorax in Behcet's disease treated with a blood patch. *Isr Med Assoc J* 2008;10:588-589.