



Purulent Pericarditis with Cardiac Tamponade Secondary to *Candida Albicans* after Total Parenteral Nutrition: A Case Report

Ömer Kertmen, MD, Gökhan Gök, MD, Murat Akçay, MD*

Department of Cardiology, Faculty of Medicine, Ondokuz Mayıs University, Samsun, Turkey.

Received 02 October 2019; Accepted 10 February 2020

Abstract

Purulent pericarditis is characterized by a purulent pericardial fluid, which usually originates from the extension of a nearby bacterial infection site or by blood dissemination. *Candida* species is a rare cause of pericarditis; and if not treated, it is extremely fatal. In this report, we describe a 54-year-old man who had esophagojejunostomy due to gastric adenocancer 2 months before his admission into our emergency department with dyspnea, orthopnea, chest pain, and somnolence. Physical and echocardiographic examinations revealed massive fibrinous pericardial effusion, causing pericardial tamponade. We performed urgent pericardiocentesis. The culture of the purulent pericardial fluid illustrated *Candida albicans*. There was no gastropericardial fistula after endoscopic and computed tomographic evaluations of the gastrointestinal tract. After receiving 1 month of antimicrobial treatment, the patient recovered completely. During his follow-up, he remained asymptomatic and had no pericardial fluid for 6 months. Our case indicates the possibility of the occurrence of purulent pericarditis with tamponade, secondary to the dissemination of *Candida albicans* from total parenteral nutrition after gastric carcinoma surgery without gastropericardial fistulae or anastomosis leak.

J Teh Univ Heart Ctr 2020;15(3):128-130

This paper should be cited as: Kertmen Ö, Gök G, Akçay M. Purulent Pericarditis with Cardiac Tamponade Secondary to *Candida Albicans* after Total Parenteral Nutrition: A Case Report. *J Teh Univ Heart Ctr* 2020;15(3):128-130.

Keywords: Pericarditis; Cardiac tamponade; *Candida albicans*; Parenteral nutrition, total

Introduction

Purulent pericarditis is characterized by purulent pericardial fluid, which usually originates from the extension of a nearby bacterial infection site or by blood dissemination.¹ *Candida* species is a very rare cause of pericarditis and is associated with a high grade of mortality; it is caused by a history of immunosuppression or mostly due to gastropericardial fistulae after gastric surgery.^{2,3}

We herein describe a male patient with an unusual case

of large purulent pericardial effusion secondary to *Candida albicans*. He had a history of total parenteral nutrition and esophagojejunostomy due to gastric adenocancer 2 months prior to his admission into our hospital.

Case Report

A 54-year-old man was admitted into our emergency department with worsening dyspnea, orthopnea, palpitation,

*Corresponding Author: Murat Akçay, Assistant Professor of Cardiology, Ondokuz Mayıs University, Faculty of Medicine, Department of Cardiology, Kurupelit Campus, Atakum 55139, Samsun, Turkey. Tel: +90 362 3121919. Fax: +90 362 457 6041. E-mail: drmuratakay@hotmail.com.



and nausea. The patient had been anuric for 2 days. There was no history of any heart disease. Five months before his admission into our hospital, on account of epigastric pain, nausea, vomiting, and weight loss, he had received a diagnosis of gastric adenocarcinoma. Accordingly, he was given neoadjuvant chemotherapy and radiotherapy. Subsequently, 2 months prior to his referral to us, he underwent esophagojejunostomy. During the course of all these procedures, he had been given total parenteral nutrition via peripheral venous catheters. Upon his admission into our hospital, an immediate physical evaluation revealed cold and sweaty extremities, pronounced jugular venous distention, reduced heart sounds, and abdominal tenderness. Additionally, he had a blood pressure of 90/50 mmHg, a pulse rate of 125/min, and a respiratory rate of 22/min. His electrocardiogram (ECG) illustrated generalized ST-elevation and generalized PR-segment depression, with the exception of aVR. As regards the laboratory tests, the patient had an alanine aminotransferase level of 2618 U/L, an aspartate aminotransferase level of 2617 U/L, a C-reactive protein level of 281 mg/L, a creatinine level of 4.56 mg/dL, a white blood cell count of 25.800/mm³, a hemoglobin level of 11,8 g/dL, an albumin level of 2.88 g/dL, and a sedimentation rate of 86 mm/h. Echocardiography showed large fibrinous pericardial effusion (Figure 1A and Figure 1B).

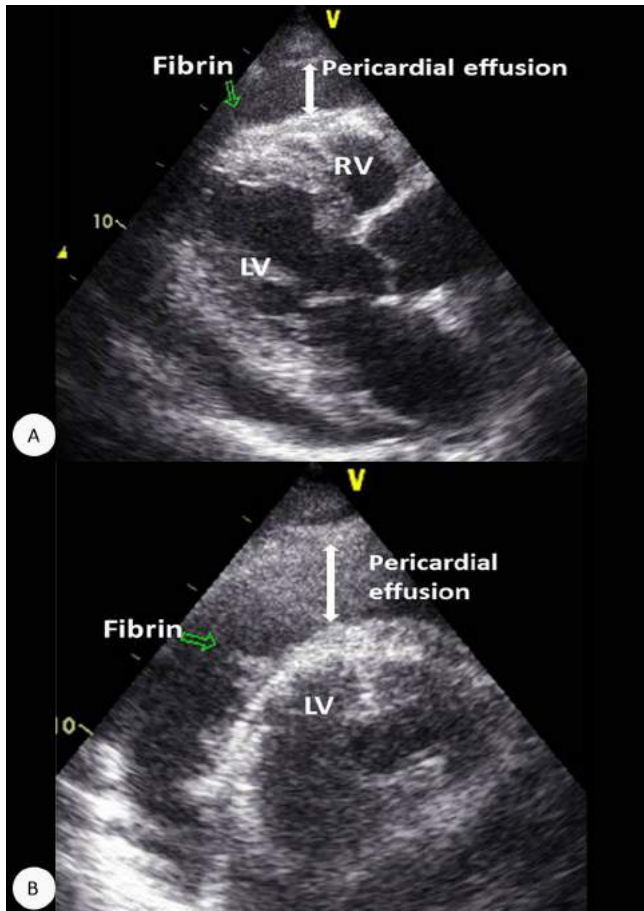


Figure 1. A) Transthoracic echocardiography (parasternal long-axis view), showing fibrinous pericardial effusion (arrows indicate the fibrin). B) Transthoracic echocardiography (parasternal short-axis view), showing the fibrinous pericardial effusion (arrows indicate the fibrin). C) Macroscopic imaging of the purulent pericardial fluid
LV, Left ventricle; RV, Right ventricle

The patient underwent urgent echocardiography-guided pericardiocentesis. Totally, 600 cc of purulent pericardial fluid was drained (Figure 1C). Consultations were done with infectious disease specialists, who started an empiric antibiotic treatment with teicoplanin (1×400 mg/d) and meropenem (3×1 g/d). The microbiological culture of the pericardial fluid yielded *Candida albicans*; consequently, caspofungin (1×50 mg/d) was added to the therapy. While the patient was on the parenteral antimicrobial therapy, an upper gastrointestinal tract endoscopy and abdominal computed tomography with oral contrasts were performed. There was no gastropericardial fistula, nor was there any leak at the anastomoses. During the follow-up, the patient's laboratory parameters, including the serum creatinine level, returned to normal limits and his urine output became normal. After an echocardiographic follow-up and the completion of 1 month of antibiotherapy, he was discharged from the hospital without any complications. During his follow-up, the patient remained asymptomatic and had no pericardial fluid for 6 months. In addition, no pathological ¹⁸F-FDG (fludeoxyglucose) accumulation was observed on positron emission tomography.

Discussion

Purulent pericarditis results in cardiac tamponade in 80% of cases; and if left untreated, it has a high grade of mortality.^{1, 4} Pericardial effusion must be drained through percutaneous or surgical procedures.¹ Antimicrobial therapy should include broad-spectrum antibiotics initially targeting both Gram-negative and Gram-positive species. What should also be considered is a fungal etiology. If the patient

undergoes immunosuppression, including prior antibiotic therapy, the use of a central venous catheter, parenteral nutrition, and thoracic surgery, fungal causes especially *Candida* species should be kept in mind.^{2,5}

Candidal pericarditis is a rare disease, and the cases of tamponade causing multiorgan failure are even fewer. *Candida albicans* is mostly seen in the pericardial fluid when there is a gastropericardial fistula after gastric operations.^{1,3} Our case also had undergone esophagojejunostomy 2 months prior to his referral to us. Thus, after antimicrobial culture results, our best possible diagnosis was candidal pericarditis. Nevertheless, at the patient's upper gastrointestinal tract, endoscopy and computed tomography with oral contrasts showed no gastropericardial fistulae. Cognizant of the fact that he had been subjected to immunosuppression in the form of chemotherapy, throughout which he had total parenteral nutrition, we entertained the notion that it could have been the cause of yeast infections. Indeed, in patients undergoing immunosuppressive treatments, we should terminate parenteral nutrition as soon as possible and remain vigilant against fungal infections disseminated from catheters. It, therefore, appears that the possible explanation for the clinical case presented herein is the spread of *Candida albicans* from total parenteral nutrition following gastric carcinoma surgery in the absence of gastropericardial fistulae or anastomosis leak. If left untreated, this type of pericarditis is highly fatal, which renders an early diagnosis, hospitalization, and proper treatment vital.

Conclusion

We presented a case of purulent pericarditis with cardiac tamponade in the wake of a gastric carcinoma operation without gastropericardial fistulae or anastomosis leak in the immunosuppressive period secondary to the dissemination of *Candida albicans* from total parenteral nutrition.

References

1. Rabinovici R, Szewczyk D, Ovadia P, Greenspan JR, Sivalingam JJ. Candida pericarditis: clinical profile and treatment. *Ann Thorac Surg* 1997;63:1200-1204.
2. Khoueiry Z, Delseny D, Leclercq F, Piot C, Roubille F. Cardiac tamponade likely due to candida infection, in an immunocompetent patient. *Ann Cardiol Angeiol (Paris)* 2013;62:122-123.
3. Tang CP, Wang YW, Shiao YT, Lee RC, Lan KH, Chao Y. Gastropericardial fistula and *Candida albicans* pericarditis: a rare complication of gastric adenocarcinoma treated with radiation and chemotherapy. *J Chin Med Assoc* 2009;72:374-378.
4. Kraus WE, Valenstein PN, Corey GR. Purulent pericarditis caused by *Candida*: report of three cases and identification of high-risk populations as an aid to early diagnosis. *Rev Infect Dis* 1988;10:34-41.
5. Hashemi Fesharaki S, Aghili SR, Shokohi T, Boroumand MA. Catheter-related candidemia and identification of causative Can-

didia species in patients with cardiovascular disorder. *Curr Med Mycol* 2018;4:7-13.