



# Percutaneous Balloon Mitral Valvuloplasty and Early Right Atrial Clot Formation: A Case Report

Rezvaniyeh Salehi, MD, Naser Aslan Abadi, MD, Razieh Parizad, PhD,  
Sanam Mirzayi, MD, Elnaz Javanshir, MD\*

Cardiovascular Research Center, Tabriz University of Medical Sciences, Tabriz, Iran.

Received 05 August 2019; Accepted 04 February 2020

## Abstract

Percutaneous balloon mitral valvuloplasty (PBMV) has recently become the treatment of choice for many patients suffering from mitral stenosis. In the current report, we introduce a 26-year-old woman who presented to us with palpitation and exertional dyspnea but without any remarkable medical history. ECG illustrated the sinus rhythm, transthoracic echocardiography (TTE) showed severe rheumatic mitral stenosis and (2+) mitral regurgitation, and transesophageal echocardiography (TEE) demonstrated severe mitral stenosis and no thrombus. Accordingly, the patient underwent percutaneous transvenous mitral commissurotomy (PTMC). On the following day, TTE showed a fresh mobile thrombus in the right atrium attached to the atrial septum, which was confirmed by TEE. As a result, the patient received 1 mg/kg (60 mg) of enoxaparin subcutaneously twice daily plus 5 mg of warfarin daily. Subsequent TTE revealed no mass 4 days after the treatment. Evidence suggests that endocardial surface injury and trans-septal puncture during PTMC may be associated with clot formation, which is aggravated by low blood flow in the right atrium and the catheter as a foreign body. This case report emphasizes the importance of post-PTMC anticoagulant therapy.

*J Teh Univ Heart Ctr 2020;15(2):77-80*

**This paper should be cited as:** Salehi R, Aslan Abadi N, Parizad R, Mirzayi S, Javanshir E. Percutaneous Balloon Mitral Valvuloplasty and Early Right Atrial Clot Formation: A Case Report. *J Teh Univ Heart Ctr 2020;15(2):77-80.*

**Keywords:** Mitral valve stenosis; Balloon valvuloplasty; Thrombosis; Anticoagulant

## Introduction

Percutaneous balloon mitral valvuloplasty (PBMV) has recently become the treatment of choice for many patients suffering from symptomatic mitral stenosis. This stands true especially among patients with a Wilkins score of less than 8. Further, PBMV application is gaining attention in other patients previously thought not to benefit from the procedure.<sup>1-2</sup> Thus, patients with symptomatic mitral stenosis need not unnecessarily be treated with open or closed surgical mitral commissurotomy.

The main mechanism with which PBMV renders therapeutic benefits is a fracture of the commissures.<sup>3</sup> Evidence suggests that PBMV has equal or even better results and comparable restenosis rates compared with surgical mitral commissurotomy.<sup>3, 4</sup> In addition, evidence emerging from clinical trials have shown that mitral stenosis treatment with PBMV provides a larger valve area and better long-term durability than does closed commissurotomy.<sup>5</sup>

Various methods have been developed to perform PBMV, amongst which the Inoue single-balloon method is the most popular among cardiologists. When compared with the

\*Corresponding Author: Elnaz Javanshir, Assistant Professor of Cardiology, Cardiovascular Research Center, Madani Heart Center, Daneshgah Ave, Tabriz, Iran. 5166614756. Tel: +98 041 33363880. Fax: +98 041 33363880. E-mail: elnaz.javanshir@yahoo.com.

double-balloon technique, this method renders the same efficacy with fewer procedural complications such as apex perforation and cardiac tamponade. These results were replicated 25 years after valvuloplasty.<sup>6</sup>

Additionally, several complications have been reported to follow PBMV. Acute complications include peripheral embolism, emergency need for mitral valve surgery, and severe mitral regurgitation and long-term complications include, but are not limited to, peripheral embolism/stroke, mitral replacement surgery, and re-valvotomy.<sup>7</sup> Hemopericardium, cardiac rupture, cardiac tamponade, and last but not least clot formation have also been reported after PBMV.<sup>2</sup> Given the importance of the abovementioned evidence, we report early right atrial clot formation following PBMV in a patient with severe rheumatic mitral stenosis.

### Case Report

A 26-year-old woman was referred to Madani Heart Hospital, affiliated with Tabriz University of Medical Sciences, Tabriz, Iran, due to palpitation and exertional dyspnea, which had been intensified in the preceding 5 months. The patient had no remarkable medical history, and her ECG illustrated a sinus rhythm. In the physical examination, the first heart sound ( $S_1$ ) was loud, while the second heart sound ( $S_2$ ) was relatively normal. An opening snap was present after  $S_2$ . There was a 3/6 low-pitched rumbling murmur in the apex and a 2/6 systolic murmur in the left sternal border. Furthermore, severe rheumatic mitral stenosis and (2+) mitral regurgitation were detected on transthoracic echocardiography (TTE). Additionally, pulmonary artery pressure and the Wilkins score were calculated to be 38 mmHg and 8, respectively. Transesophageal echocardiography (TEE) showed severe mitral stenosis with a valve area of 1.0 cm<sup>2</sup> by 3D planimetry and no thrombus in the heart. The patient was, therefore, candidate for PBMV (Figure 1).

The patient underwent PBMV using the Inoue-Balloon Catheter with a 28-mm balloon. After valvuloplasty, left atrial pressure dropped from 30 mmHg to 12 mmHg and pulmonary artery pressure decreased from 32 mmHg to 13 mmHg.

On the following day, TTE showed (2+) mitral regurgitation with no change in intensity, as well as a large filamentous hypermobile mass (size=28 mm×3 mm) with chaotic motion attached to the right atrial side of the interatrial septum near the junction of the inferior vena cava and far from the septostomy site. These findings were subsequently confirmed by TEE (Figures 2 & 3).

Consequently, the patient received 1 mg/kg (60 mg) of enoxaparin through the subcutaneous route twice a day plus 5 mg of warfarin daily through the oral route. The subsequent TTE examinations revealed a decrease in the size of clot

48 hours after the treatment and no mass 4 days after the treatment.

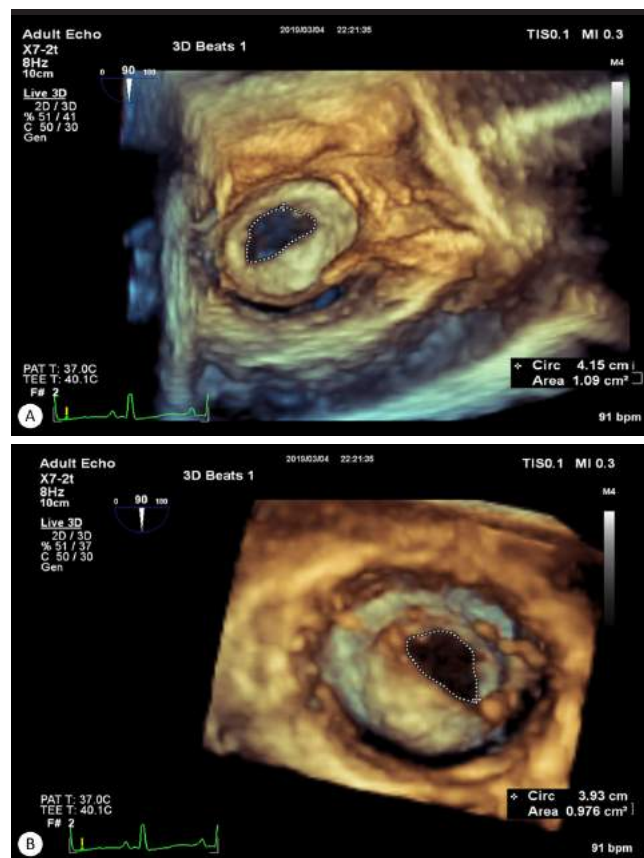


Figure 1. Three-dimensional transesophageal echocardiography before percutaneous transvenous mitral commissurotomy, showing severe mitral stenosis

- A) Severe mitral stenosis from Left atrium (LA) view
- B) Severe mitral stenosis from Left ventricle (LV) view

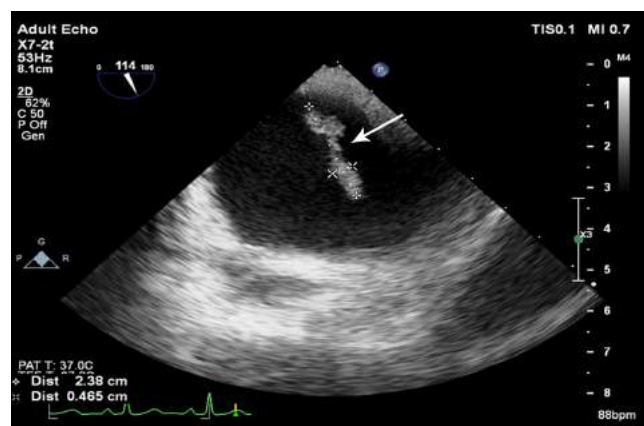


Figure 2. TEE after percutaneous transvenous mitral commissurotomy, showing the right atrium with the clot (arrow) attached to the interatrial septum

TEE, Transesophageal echocardiography

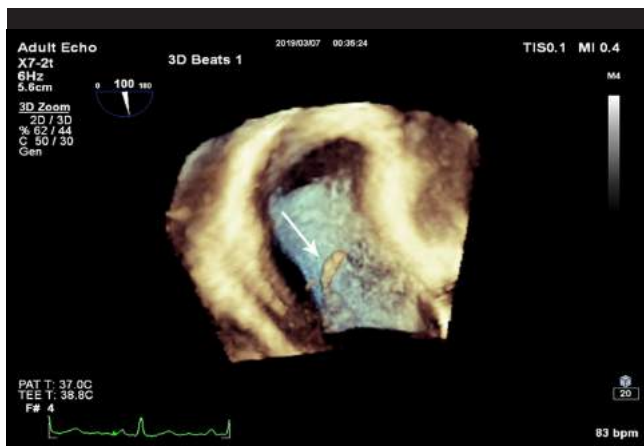


Figure 3. Three-dimensional transesophageal echocardiography, showing the clot attached to the interatrial septum (arrow)

## Discussion

Rheumatic heart disease represents a chronic and progressive entity resulting from a complement-mediated process during which rheumatic fever ignites an inflammatory cascade causing atrioventricular valve damage.<sup>8</sup> The global mortality of rheumatic heart disease is approximately 220 000 deaths per year, which makes it a serious healthcare problem worldwide.<sup>9</sup> The mitral valve is the most commonly affected atrioventricular valve. The accumulation of verruciform fibrotic lesions on this valve results in mitral stenosis and, in some cases, mitral regurgitation, which vary in severity.<sup>10</sup>

Traditionally, open and closed mitral commissurotomy was performed to treat mitral stenosis induced by rheumatic heart disease. However, the subsequent development of PBMV proved to be of equal efficacy with the simultaneous avoidance of the complications of open surgery in selected cases.<sup>11</sup> Amongst various techniques of PBMV, the Inoue single-balloon method has gained unprecedented popularity because it confers the same efficacy with fewer procedural complications.<sup>6</sup> Unavoidable complications occurring during double-balloon techniques such as apex perforation and cardiac tamponade are far less common during the single-balloon method. Nevertheless, complications such as hemopericardium, cardiac rupture, cardiac tamponade, and last but not least clot formation have also been reported after PBMV.<sup>2</sup>

Clot formation in the right and left atria is a rare complication of PBMV which has been previously reported in a few cases.<sup>2, 12, 13</sup> Salehi et al.<sup>12</sup> reported a case of right atrial clot formation following percutaneous transmitral valvuloplasty, which was treated successfully with surgery. The authors argued that PBMV induced a septal defect in a location other than the foramen ovale, resulting in stalk formation and the

subsequent thrombosis. They concluded that PBMV should be routinely backed up by surgery. Nonetheless, in this case, we showed that anticoagulant therapy with enoxaparin, followed by warfarin, completely resolved the existing clot and obviated the subsequent need for surgery. Ateş et al.<sup>2</sup> reported the same incidence in a 40-year-old patient referred for PBMV. The case was successfully treated within 24 hours of unfractionated heparin infusion. The authors believed that endothelial damage to the right atrial surface during trans-septal puncture, low blood pressure in the right atrium, and the presence of the catheter as a foreign body induced clot formation pathways, leading to the subsequent thrombosis in the right atrium. They concluded that anticoagulation should be considered for high-risk patients after PBMV. In another case report, Roldan et al.<sup>13</sup> reported left atrial thrombosis after percutaneous mitral valvuloplasty and proposed that endothelial surface injury was the main mechanism by which clot formation was propagated.

## Conclusion

The findings of the current study mandate further research to incorporate TEE into rheumatic mitral stenosis management before, during, and after percutaneous transvenous mitral commissurotomy for the early detection of clot formation. Moreover, anticoagulation therapy should be considered following PBMV. However, these results should be replicated and validated in larger studies before their routine application in clinical practice.

## References

- Prendergast BD, Shaw TRD, Iung B, Vahanian A, Northridge DB. Contemporary criteria for the selection of patients for percutaneous balloon mitral valvuloplasty. *Heart* 2002;87:401-404.
- Ateş AH, Arslan U, Aksakal A, Yücel H, Atasoy Günaydın İ, Ekbül A, Yaman M. Right atrial clot formation early after percutaneous mitral balloon valvuloplasty. *Case Rep Med* 2016;2016:3058015.
- Nobuyoshi M, Arita T, Shirai S, Hamasaki N, Yokoi H, Iwabuchi M, Yasumoto H, Nosaka H. Percutaneous balloon mitral valvuloplasty: a review. *Circulation* 2009;119:e211-219.
- Arora R, Nair M, Kalra GS, Nigam M, Khalilullah M. Immediate and long-term results of balloon and surgical closed mitral valvotomy: a randomized comparative study. *Am Heart J* 1993;125:1091-1094.
- Dean LS. Percutaneous transvenous mitral commissurotomy: a comparison to the closed and open surgical techniques. *Cathet Cardiovasc Diagn* 1994;Suppl 2:76-81.
- Lee S, Kang DH, Kim DH, Song JM, Song JK, Park SW, Park SJ. Late outcome of percutaneous mitral commissurotomy: randomized comparison of Inoue versus double-balloon technique. *Am Heart J* 2017;194:1-8.
- Aslanabadi N, Ghaffari S, Khezerlouy Aghdam N, Ahmadzade M, Kazemi B, Nasiri B, Separham A, Sohrabi B, Taban M, Aslanabadi A. Poor outcome following percutaneous balloon mitral valvotomy in patients with atrial fibrillation. *J Cardiovasc Thorac Res* 2016;8:126-131.



8. Lu L, Hong L, Fang J, Chen L. Effectiveness of percutaneous balloon mitral valvuloplasty for rheumatic mitral stenosis with mild to severe mitral regurgitation. *Biomed Res Int* 2016;2016:3298343.
9. Carapetis JR, McDonald M, Wilson NJ. Acute rheumatic fever. *Lancet* 2005;366:155-168.
10. Marijon E, Mirabel M, Celermajer DS, Jouven X. Rheumatic heart disease. *Lancet* 2012;379:953-964.
11. Cohen JM, Glower DD, Harrison JK, Bashore TM, White WD, Smith LR, Rankin JS, Sabiston DC, Jr. Comparison of balloon valvuloplasty with operative treatment for mitral stenosis. *Ann Thorac Surg* 1993;56:1254-1262.
12. Salehi N, Abdi S, Esmailzadeh M, Movasaghi N, Abadi MN, Vakili-Zarch A. Right atrium clot formation following percutaneous transmitral valvuloplasty. *Heart Surg Forum* 2013;16:E162-163.
13. Roldán FJ, Vargas-Barrón J, Ríos MA, Espinola-Zavaleta N, Keirns C, Romero-Cárdenas A. Left atrial thrombosis after percutaneous mitral valvuloplasty: resolution with conservative management. *Echocardiography* 2000;17:41-43.