



# Successful Treatment of a Huge Thrombotic Saphenous Vein Graft Occlusion with Aspiration Thrombectomy: A Case Report

Murat Akçay, MD\*

Department of Cardiology, Faculty of Medicine, Ondokuz Mayıs University, Samsun, Turkey.

Received 30 November 2018; Accepted 05 February 2019

## Abstract

Saphenous vein grafts (SVGs) are widely used conduits for the surgical revascularization of coronary arteries, but they are associated with poor long-term patency rates. Acute SVG thromboses often present as acute coronary syndrome and have an extensive atherosclerotic and thrombotic burden. Percutaneous coronary intervention (PCI) is the first treatment option; however, it carries a high risk of distal embolization, no-reflow, and periprocedural myocardial infarction. Reducing the thrombus burden and preventing distal embolization during PCI can be achieved by using some pharmacological strategies (e.g., glycoprotein IIb/IIIa antagonists) and devices (e.g., thrombectomy and filter devices). There are yet no better therapeutic options for patients undergoing PCI of SVG occlusions. Here, we introduce a 52-year-old male patient admitted with a typical acute chest pain of 1 hour's duration. Electrocardiography showed signs of acute inferoposterior myocardial infarction. A thrombotic SVG occlusion was detected in primary PCI, and a huge thrombus content was aspirated. After the thrombus aspiration with stent implantation, the chest pain was relieved and the ST-segment elevation was improved. The patient has been followed without any symptoms for 10 months.

*J Teh Univ Heart Ctr* 2020;15(2):69-72

**This paper should be cited as:** Akçay M. Successful Treatment of a Huge Thrombotic Saphenous Vein Graft Occlusion with Aspiration Thrombectomy: A Case Report. *J Teh Univ Heart Ctr* 2020;15(2):69-72.

**Keywords:** Saphenous vein; Thrombosis; Thrombectomy

## Introduction

Saphenous vein grafts (SVGs) are widely used conduits for the surgical revascularization of coronary arteries, but they are associated with poor long-term patency rates.<sup>1</sup> Acute SVG thromboses often present as acute coronary syndrome. Percutaneous coronary intervention (PCI) is the first treatment option for thrombotic SVG occlusions. SVG occlusions have a high thrombus burden, and PCI carries the risk of distal embolization, no-reflow, and periprocedural

myocardial infarction.<sup>1,2</sup> Embolic protection devices reduce periprocedural complications, but they are underused in clinical practice.<sup>1</sup> Among pharmacological alternatives, glycoprotein IIb/IIIa antagonists have been frequently used as a thrombus reduction strategy. Thrombus aspiration (thrombectomy) devices have also been reported to be successful in reducing the thrombus burden and providing distal flow.<sup>1-3</sup>

Here, we present a patient in whom we detected a huge thrombotic SVG occlusion with acute inferior posterior

\*Corresponding Author: Murat Akçay, Ondokuz Mayıs University, Kurupelit Campus, Atakum 55139, Samsun, Turkey. Tel: +90 362 3121919. Fax: +90 362 4576041. E-mail: drmuratakcay@hotmail.com.

myocardial infarction, successfully treated with thrombus aspiration and stent implantation.

## Case Report

A 52-year-old male patient presented to the emergency department with a typical acute chest pain of 1 hour's duration. The patient was sweaty and anxious on the physical examination and had a systolic blood pressure of 90 mmHg and a diastolic blood pressure of 50 mmHg. Electrocardiography showed ST-segment elevations in DII, DIII, and aVF leads, as well as ST-segment depressions in V<sub>1</sub>-V<sub>3</sub> leads (Figure 1A). His medical history showed double-vessel coronary artery bypass graft surgery (CABG) 2 months earlier due to stable angina pectoris, for which he regularly took diltiazem, acetylsalicylic acid, and atorvastatin. Additionally, there were no cardiovascular risk factors except for family history. The patient's coronary angiography and bypass reports were, however, not available.

Primary PCI was performed based on a diagnosis of acute inferoposterior myocardial infarction within the first hour of chest pain. Coronary angiography showed that the SVG to the right coronary artery (RCA) was occluded with a thrombus (Figure 2A). The left internal mammary artery graft was open and raced with the left anterior descending coronary artery. Additionally, the mid-portion of the circumflex (Cx) obtuse marginalis was 80% stenotic and the Cx and the RCA were totally occluded (Video 1). The lesion on the SVG was passed with a floppy wire and aspirated via manual thrombectomy (Export Catheter, Medtronic Inc., Minneapolis, Minnesota) (Figure 2B). The huge thrombus content was also aspirated (Figure 2C). Tirofiban, a glycoprotein IIb/IIIa inhibitor, at an intracoronary dose of 10 µg/kg was administered. Moreover, severe stenosis was detected in the SVG to RCA anastomosis, and a 2.75×38-mm XIENCE PRO drug-eluting stent (Abbott Vascular, California, USA) was implanted. Post-dilatation with a 3.5×15-mm Emerge NC balloon (Boston Scientific, USA) was performed, and a distal thrombolysis in myocardial infarction (TIMI) flow grade III was provided

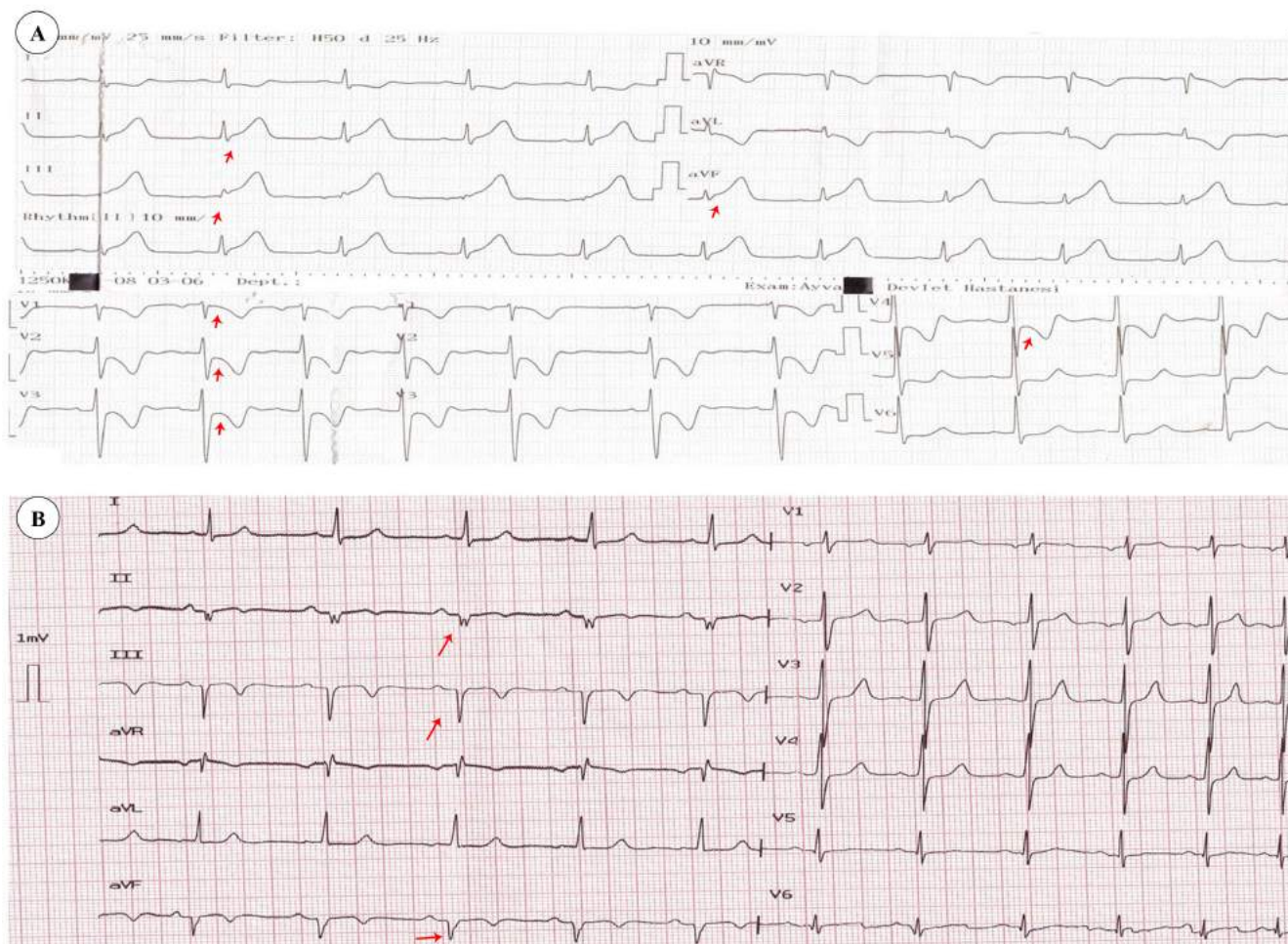


Figure 1. A) Patient's electrocardiography on admission, showing ST-segment elevations in DII, DIII, and aVF leads and ST-segment depressions in V<sub>1</sub>-V<sub>4</sub> leads (arrows indicate the ST-segment elevations and depressions), B) Electrocardiography of the patient on discharge from the hospital, showing recovery in the ST-segments and improvement in Q waves in DII, DIII, and aVF leads (arrows indicate the Q waves)

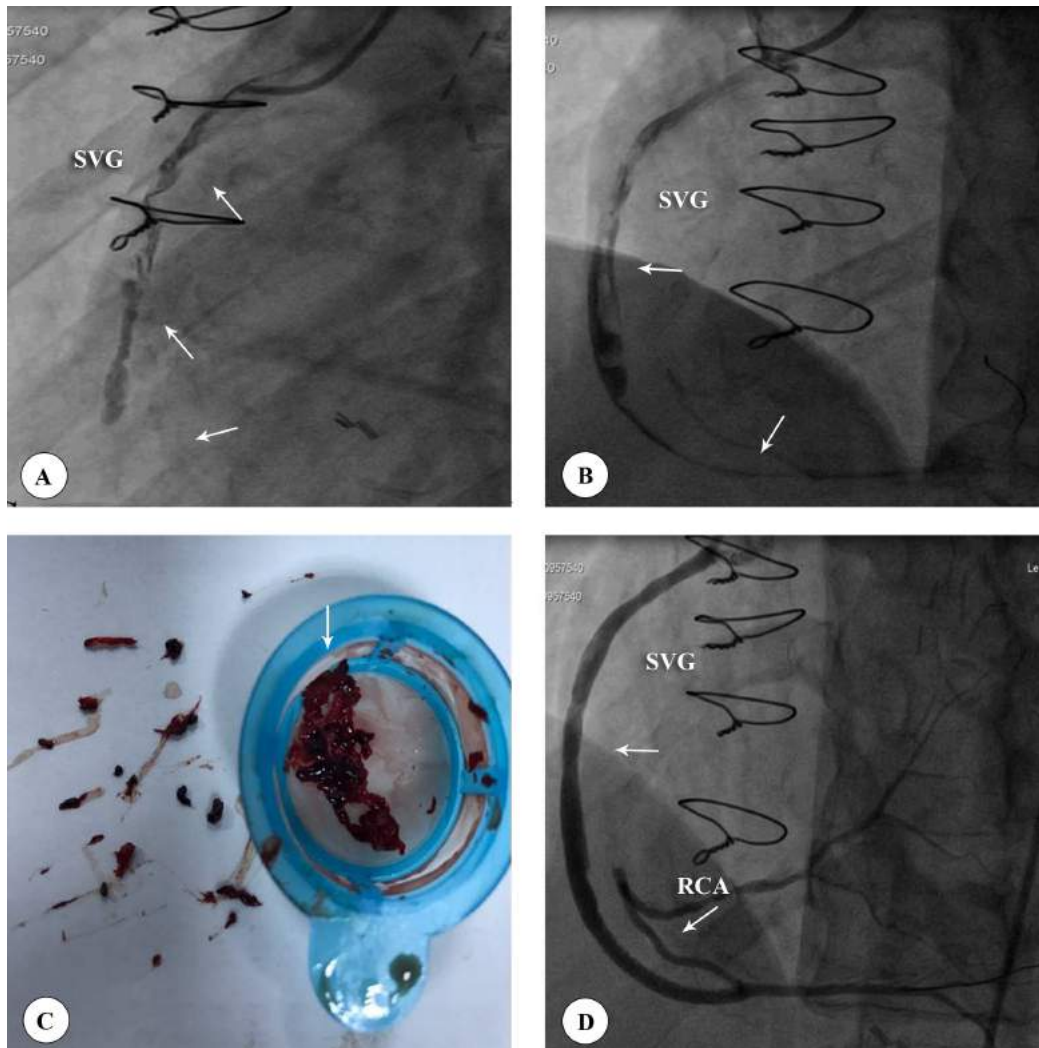


Figure 2. A) Left anterior oblique coronary angiography, showing the thrombotic occlusive saphenous vein graft (SVG) (arrows indicate the degenerated thrombotic SVG), B) Left anterior oblique coronary angiography, showing manual thrombus aspiration and reduced thrombus burden (arrows indicate the thrombus and distal flow), C) Imaging of the aspirated huge thrombus fragments (arrow indicates the huge thrombus fragments), D) Left anterior oblique coronary angiography, showing a patent SVG to right coronary artery (RCA) anastomosis (arrow indicate the patent flow)

(Figure 2D/Video 2). An intravenous infusion of 0.15  $\mu\text{g}/\text{kg}/\text{min}$  of tirofiban was given for 18 hours. After the procedure, the chest pain was relieved and the ST-segment elevation was improved (Figure 1B). The angiographic imaging of the coronary arteries before the surgery was evaluated, and the Syntax Score was calculated to be 30.5 (Video 3). The patient underwent echocardiography, which showed an ejection fraction of 40%, hypokinesia in the inferior and posterior walls, and mild mitral regurgitation. Atorvastatin, nebivolol, prasugrel, acetylsalicylic acid, and ramipril were prescribed, and the patient was discharged without any complications.

Control angiography and PCI on the 80% mid-portion stenosis of the Cx obtuse marginalis were planned. One month later, a 2.75 $\times$ 24-mm XIENCE PRO drug-eluting stent (Abbott Vascular, California, USA) was implanted in the stenotic region. The stent patency of the SVG to RCA anastomosis was optimal (Video 4). One month later, stress

myocardial perfusion scintigraphy was performed and no sign of ischemia was detected. The patient has been followed without any symptoms for 10 months.

## Discussion

Clinical studies have shown that up to 12% of SVGs occlude within the first 6 months and 3.4% as early as 2 to 3 weeks after CABG.<sup>1-3</sup> Acute occlusions of SVGs are frequently associated with extensive atherosclerotic and thrombotic burden.<sup>4</sup> In SVGs, atherosclerosis progresses rapidly, plaque composition is highly friable, and thrombus load is high. Because of the structure of atherosclerosis, PCI on SVGs is associated with increased risk of distal embolization, no-reflow and, thus, periprocedural myocardial infarction and death.<sup>1,5, 6</sup> Compared with native coronary arteries, PCI on



SVGs is associated with poor angiographic outcomes.

Acute SVG thrombosis often presents as ST-segment-elevation myocardial infarction (STEMI). During primary PCI, a high thrombus-loaded SVG occlusion is seen. Relieving the thrombus burden and preventing distal embolization during PCI can be attained by using some pharmacological strategies (e.g., glycoprotein IIb/IIIa antagonists) and devices (e.g., thrombectomy and filter devices).<sup>5-8</sup> In particular in patients with STEMI and large thrombus burden, aspiration thrombectomy may still be effective and provide beneficial clinical outcomes.<sup>1-3</sup> Distal protection filters may improve embolic complications, but they are incapable of preventing distal embolization completely.<sup>1, 2, 7</sup> Furthermore, there are no recommendations as to what is to be done before the visualization of the distal coronary vasculature in acute SVG occlusions. SVGs have no side branches, and SVG distal anastomosis areas are often occluded with extensive thrombi. Hamilos et al.<sup>8</sup> reported a successful outcome using aspiration catheters and distal embolization devices together in totally obstructed SVG occlusions.

SVG thrombosis is also called the “deep vein thrombosis of the heart”, and its probable pathophysiology is assumed to be similar to that of deep vein thrombosis.<sup>4</sup> Therefore, recently, there have been reports of thrombus loss with a noninvasive new oral anticoagulant treatment in cases with focal thrombotic SVG occlusions that allows flow without severe atherosclerosis.<sup>9, 10</sup>

## Conclusion

Acute SVG thrombosis carries a high risk of intraprocedural complications, especially distal embolization and no-reflow. There are yet no better therapeutic options for patients undergoing PCI. Aspiration thrombectomy may be a beneficial and effective treatment technique to decrease the thrombus burden in SVG occlusions, as was the case in our patient.

***To watch the following videos, please refer to the relevant URLs:***

<http://jthc.tums.ac.ir/index.php/jthc/article/view/992/895>

Video 1. Angiographic imaging of the native coronary arteries and bypass grafts

<http://jthc.tums.ac.ir/index.php/jthc/article/view/992/896>

Video 2. Angiographic imaging of thrombus aspiration and percutaneous coronary intervention on the saphenous vein graft

<http://jthc.tums.ac.ir/index.php/jthc/article/view/992/897>

Video 3. Angiographic imaging of the left and right native coronary arteries before the bypass surgery

<http://jthc.tums.ac.ir/index.php/jthc/article/view/992/898>

Video 4. Angiographic imaging of the control saphenous vein graft stent patency and percutaneous coronary intervention on the circumflex artery

## References

1. Kim FY, Marhefka G, Ruggiero NJ, Adams S, Whellan DJ. Saphenous vein graft disease: review of pathophysiology, prevention, and treatment. *Cardiol Rev* 2013;21:101-109.
2. Lee MS, Park SJ, Kandzari DE, Kirtane AJ, Fearon WF, Brilakis ES, Vermeersch P, Kim YH, Waksman R, Mehilli J, Mauri L, Stone GW. Saphenous vein graft intervention. *JACC Cardiovasc Interv* 2011;4:831-843.
3. Sentürk T, Aydın Kaderli A, Aydın O, Yeşilbursa D, Akin Serdar O. Successful treatment of saphenous venous graft thrombus by tirofiban infusion. *Heart Lung* 2010;39:237-239.
4. Pothineni NV, Bahia A, Gobal F, Ahmed Z, Uretsky BF, Hakeem A. "DVT" of the heart: A "novel" treatment for an old problem. *JACC Cardiovasc Interv* 2015;8:e165-166.
5. Deharo P, Strange JW, Mozid A. Primary percutaneous coronary intervention of native chronic total occlusions to treat ST elevation myocardial infarction secondary to acute vein graft occlusion. *Catheter Cardiovasc Interv* 2017;90:251-256.
6. Bitigen A, Gurel E, Tanalp AC, Aung SM, Başaran Y. Acute anterior myocardial infarction due to aortosaphenous vein graft occlusion with very large thrombus burden. *Exp Clin Cardiol* 2007;12:203-205.
7. Balghith M. Use of Microvena Snare catheter in non-ST elevation myocardial infarction due to saphenous vein graft occlusive thrombi. *Heart Views* 2012;13:19-21.
8. Hamilos MI, Kochiadakis GE, Karalis I, Skalidis EI, Igoumenidis NE, Vardas PE. Combined use of aspiration catheter and distal embolisation protection device to facilitate angioplasty of a totally occluded saphenous vein graft. *Hellenic J Cardiol* 2007;48:117-121.
9. Marmagkiolis K, Cilingiroglu M. Rivaroxaban for the treatment of saphenous vein graft thrombosis. *Rev Port Cardiol* 2016;35:447.e1-3.
10. Saigan M, Isawa T, Ootomo T. Apixaban for the treatment of saphenous vein graft thrombosis presenting as unstable angina: a case report. *Thromb J* 2017;15:10.