



Accelerated Idioventricular Rhythm: Not Always a Reperfusion Arrhythmia

Riyaz Charaniya, MD, DM, Mit Chaudhari, MD*, Dinesh Joshi, MD, DM

Department of Cardiology, U. N. Mehta Institute of Cardiology and Research Centre (UNMICRC), Civil Hospital Campus, Ahmedabad, India.

Abstract

Accelerated idioventricular rhythm (AIVR) is a relatively slow ventricular rhythm that often occurs during the reperfusion phase of an acute myocardial infarction. It is generally considered a benign rhythm that does not require treatment. However, we present a case where AIVR was the presenting arrhythmia in a 41-year-old man with acute coronary syndrome, suggesting it might not be as benign as previously reported in the literature. The patient, who presented to our institute, underwent urgent coronary evaluation followed by revascularization, leading to the conversion of AIVR to normal sinus rhythm and improvement in anginal symptoms.

J Teh Univ Heart Ctr 2024;19(4):306-309

This paper should be cited as: Charaniya R, Chaudhari M, Joshi D. Accelerated Idioventricular Rhythm: Not Always a Reperfusion Arrhythmia. *J Teh Univ Heart Ctr* 2024;19(4):306-309.

Keywords: Accelerated idioventricular rhythm; Acute coronary syndrome; Case report

Introduction

A 41-year-old male patient with a history of tobacco chewing for the past 15 years and a surgically treated pituitary macroadenoma via an endoscopic trans-nasal route four months prior presented with typical angina and excessive sweating for five hours. The patient initially sought medical attention at a private hospital, where an ECG was conducted, revealing a normal sinus rhythm (Figure 1). Subsequently, he was referred to the UN Mehta Institute of Cardiovascular Research Centre for further evaluation and management. Upon presentation, the patient experienced persistent typical anginal chest pain unresponsive to nitrates while maintaining stable vital signs and exhibiting no remarkable findings during the systemic examination. An ECG revealed accelerated idioventricular rhythm (AIVR)

(Figure 2). Echocardiography showed no regional wall motion abnormalities and preserved left ventricular function. Given the clinical presentation, an initial diagnosis of acute coronary syndrome was made, and a screening troponin test was performed, which showed elevated levels.

Due to the risk of life-threatening arrhythmia and ongoing anginal chest pain, an urgent coronary angiography evaluation was performed. The angiography revealed a 70% lesion in the left anterior descending artery, a normal and dominant left circumflex artery, and a complete thrombotic occlusion of the right coronary artery (Figure 4). Consequently, the patient underwent primary angioplasty and stenting of the infarct-related artery, which was the right coronary artery in this case (Figure 5). Post-procedure, the patient reported relief from angina, and the ECG changes reverted (Figure 3).

*Corresponding Author: **Mit Chaudhari**, Department of Cardiology, U. N. Mehta Institute of Cardiology and Research Centre (UNMICRC), Civil Hospital Campus (Medicity), Asarwa, Ahmedabad, 380016, Gujarat, India. Cell: +91 9638246480. Tel: +91 9319342917. Fax: +91 79 22682092. E-mail: mitchaudhari16@gamil.com.



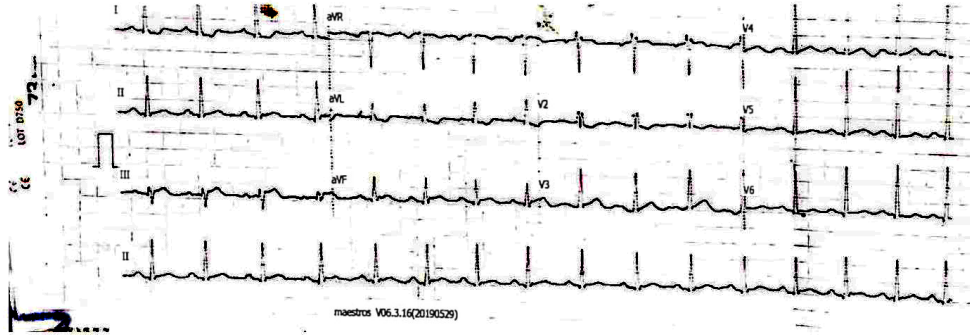


Figure 1. The patient's ECG at presentation to a local private hospital was normal.

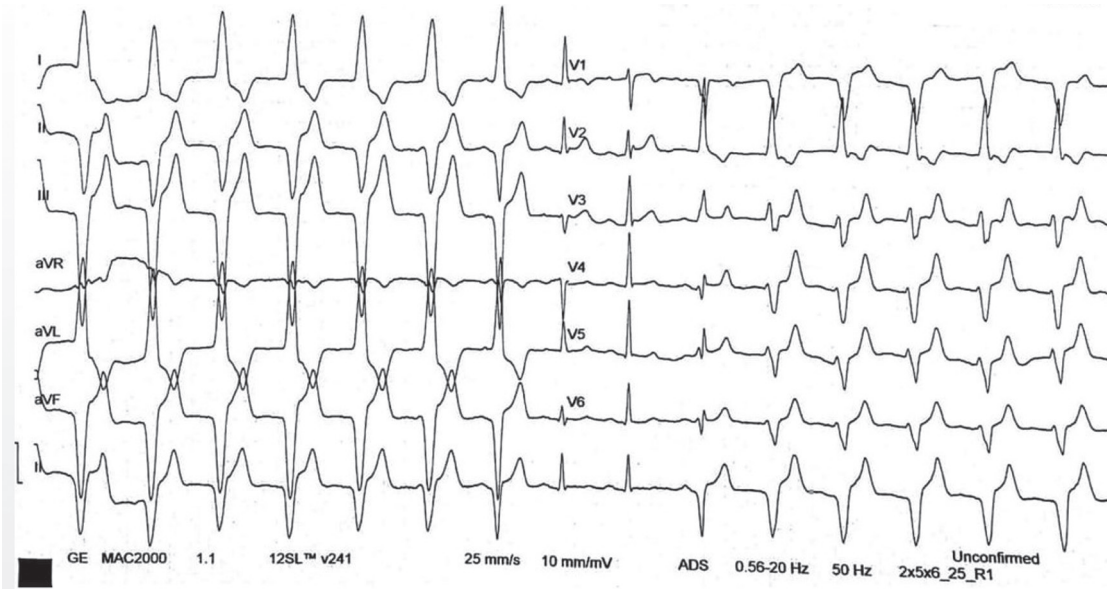


Figure 2. Upon arrival at our hospital, the patient's ECG revealed an accelerated idioventricular rhythm with intermittent normal sinus beats.

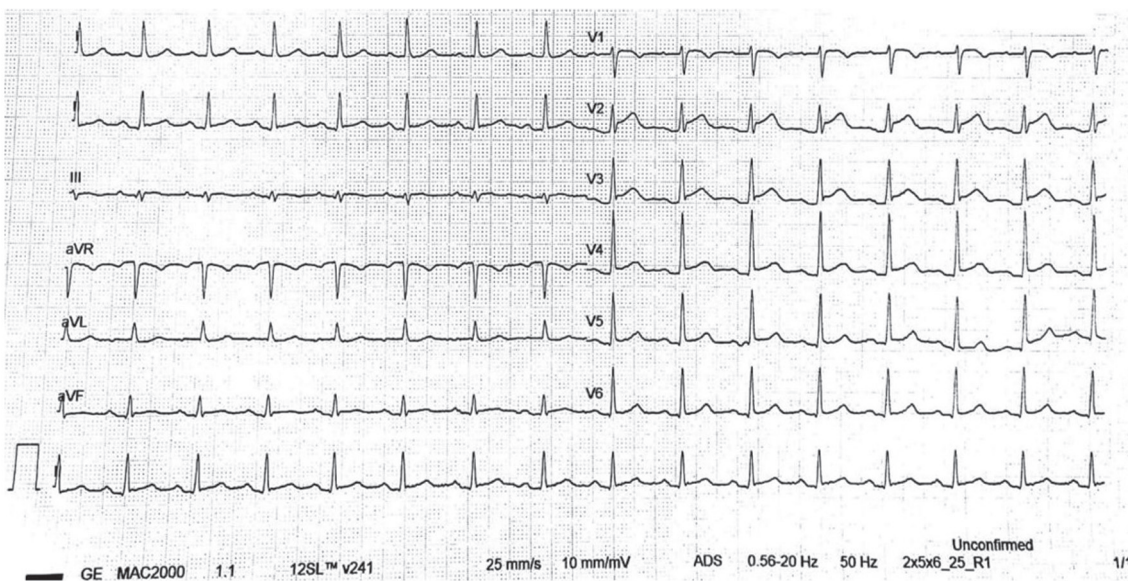


Figure 3. The image shows the patient's ECG post-procedure after revascularization.

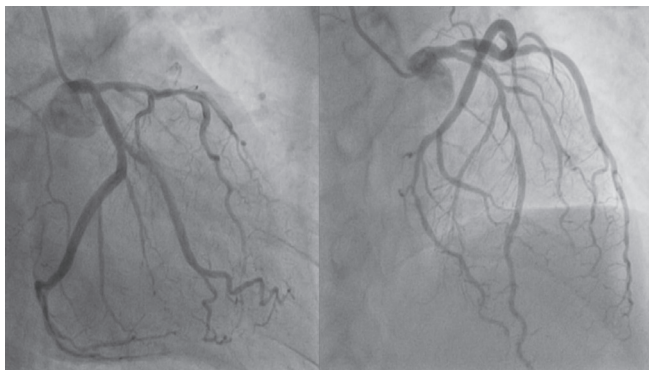


Figure 4. The coronary angiogram shows a dominant left circumflex artery, along with a 70% lesion in the left anterior descending artery.

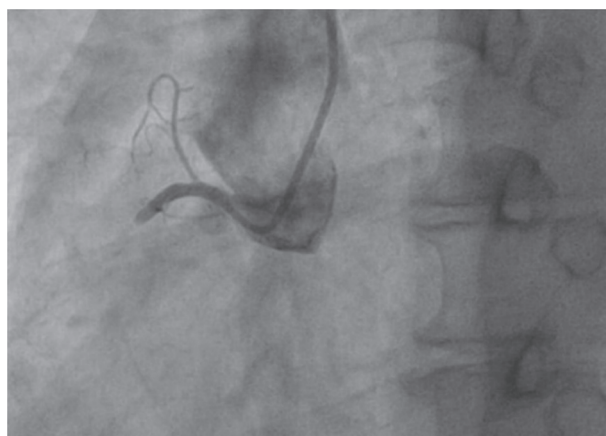


Figure 5. The coronary angiogram shows the total thrombotic occlusion of the right coronary artery.

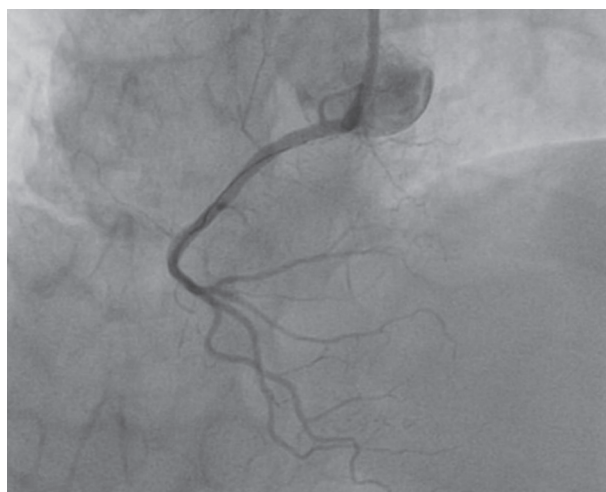


Figure 6. The right coronary artery exhibits optimal blood flow following revascularization.

Discussion

AIVR typically consists of 3 or more consecutive

premature ventricular beats at a heart rate of 60 to 100 bpm. The heart rate in AIVR is generally faster than that observed in ventricular rhythm (30-40 bpm) but slower than that seen in ventricular tachycardia (<110–120 bpm). AIVR is widely regarded as a benign and well-tolerated arrhythmia that generally does not necessitate specific treatment.¹ AIVR is commonly observed during the reperfusion phase of an acute myocardial infarction. The early emergence of AIVR is regarded as a favorable prognostic indicator, implying successful revascularization following thrombolysis.²⁻⁴ Additionally, AIVR has been reported in cases of drug toxicity (eg, digitalis), cardiomyopathies, post-resuscitation periods, and, rarely, in young adults such as athletes.¹

In the presented case, AIVR was the initial arrhythmia observed upon presentation, yet the patient continued to experience persistent typical anginal chest pain. Further coronary evaluation revealed the presence of an occluded coronary artery despite the presence of AIVR on ECG.

Conclusion

This case demonstrates that even in the absence of the characteristic ST elevation indicative of acute coronary syndrome, the presence of rhythm disturbances such as AIVR, accompanied by typical angina pain, warrants urgent coronary evaluation. It is crucial to recognize the diverse clinical manifestations of acute coronary syndrome, as exemplified by this case.

An additional noteworthy aspect is that although the patient exhibited a dominant left coronary circulation, the infarct-related artery, in this instance, was the non-dominant right coronary artery.

Recognize that AIVR may not always be a benign rhythm and could necessitate urgent coronary evaluation when considered within the clinical context, particularly in patients presenting with typical angina pain.

Understand the potential for occlusion of even a non-dominant coronary artery to result in dangerous arrhythmias, such as AIVR, and acute coronary syndrome-like presentations.

References

1. Riera AR, Barros RB, de Sousa FD, Baranchuk A. Accelerated idioventricular rhythm: history and chronology of the main discoveries. *Indian Pacing Electrophysiol J* 2010;10:40-8.
2. Goldberg S, Greenspon AJ, Urban PL, Muza B, Berger B, Walinsky P, Maroko PR. Reperfusion arrhythmia: a marker of restoration of antegrade flow during intracoronary thrombolysis for acute myocardial infarction. *Am Heart J* 1983;105:26-32.
3. Khan A, Nadeem S, Kokane H, Thummar A, Lokhandwala Y, Mahajan AU, Nathani PJ. Is accelerated idioventricular rhythm a good marker for reperfusion after streptokinase? *Indian Heart J* 2016;68:302-305.



4. Gorgels AP, Vos MA, Letsch IS, Verschuuren EA, Bär FW, Janssen JH, Wellens HJ. Usefulness of the accelerated idioventricular rhythm as a marker for myocardial necrosis and reperfusion during thrombolytic therapy in acute myocardial infarction. *Am J Cardiol* 1988;61:231-235.