



# Coarctation Balloon Angioplasty in a Rare Case with Congenitally Corrected Transposition of the Great Arteries and Ebstein's Anomaly

Afrouz Alipour, MD, Behzad Alizadeh, MD\*, Bita Zargaran, MD

Department of Pediatric, Faculty of Medicine, Mashhad University of Medical Sciences Mashhad, Iran.

Received 28 May 2023; Accepted 15 January 2024

## Abstract

The coexistence of aortic coarctation, Ebstein's anomaly, and transposition of the great arteries is an extremely rare occurrence. In this case report, we present a unique instance of complex congenital heart disease in a neonate who exhibited respiratory distress and cyanosis at birth. Echocardiography revealed several significant findings: congenitally corrected transposition of the great arteries, Ebstein's tricuspid anomaly, moderate-to-severe tricuspid regurgitation, a small muscular ventricular septal defect, and an abnormal left arch with severe coarctation of the aorta. Due to the patient's unstable hemodynamic status, balloon angioplasty was performed. Subsequent long-term clinical follow-up confirmed the efficacy of this intervention.

*J Teh Univ Heart Ctr* 2024;19(2):132-135

**This paper should be cited as:** Alipour A, Alizadeh B, Zargaran B. Coarctation Balloon Angioplasty in a Rare Case with Congenitally Corrected Transposition of the Great Arteries and Ebstein's Anomaly. *J Teh Univ Heart Ctr* 2024;19(2):132-135.

**Keywords:** Coarctation of the aorta; Transposition of great arteries; Ebstein's anomaly; Angioplasty; Percutaneous transluminal angioplasty (PTA)

## Introduction

Congenital heart diseases (CHDs) affect approximately 1%–2% of the general population.<sup>1</sup> Among this group of diseases, Ebstein's anomaly is a rare cyanotic disorder characterized by the apical displacement of the posterior and septal tricuspid leaflets,<sup>2</sup> leading to right ventricular (RV) failure and right atrial enlargement.<sup>3</sup> In patients with Ebstein's anomaly, coarctation of the aorta (CoA) should be assessed.<sup>4</sup> CoA can occur in isolation or with an associated intracardiac abnormality, most frequently ventricular septal defect (VSD), and may obstruct the outflow of the heart.<sup>1</sup> CoA is most commonly located distal to the left subclavian

artery.<sup>5</sup>

Although the clinical presentation of CoA is well known, it remains the most commonly missed CHD in the neonatal period, resulting in significant mortality and morbidity. Cardiogenic shock in neonates, characterized by impaired left ventricular (LV) or RV systolic function or both, respiratory failure requiring tracheal intubation, and metabolic acidosis, is the most frequent presentation of CoA.<sup>6</sup> Another uncommon CHD is congenitally corrected transposition of the great arteries (ccTGA), where both ventricles and their associated great arteries are reversed. In ccTGA, the RV, as the systemic ventricle, pumps oxygenated blood into the aorta.<sup>7</sup> Leftward looping of the embryonic

\*Corresponding Author: Behzad Alizadeh, Associate Professor of Pediatric Interventional Cardiology, Pediatric and Congenital Cardiology Division, Pediatric Department, Faculty of Medicine, Imam Reza Hospital, Ebne Sina Street, Mashhad, Iran. 9137913316. Tel: +98 21 51 38543031. E-mail: Alizadehb@mums.ac.ir.





heart tube is the cause of this rare malformation.<sup>8</sup>

In this report, we present a rare case of a patient with 3 simultaneous CHDs: Ebstein's anomaly, CoA, and ccTGA.

## Case Report

A full-term, 3.5 kg male neonate was delivered via cesarean section in a small town. The newborn exhibited cyanosis and respiratory distress immediately after birth and was subsequently admitted to the neonatal intensive care unit and intubated. His heart rhythm was regular, and a loud pansystolic murmur was audible through the precordium upon auscultation. Upon physical examination, the patient exhibited diminished femoral pulses, while brachial pulses were found to be within normal range. The liver edge was palpable 1 cm below the right costal margin, and the pulse rate was 170 bpm. Blood pressure in the upper and lower limbs was 75/50 and 60/40 mm Hg, respectively. A chest X-ray illustrated an increased cardiothoracic ratio and mild pulmonary venous congestion (Figure 1).

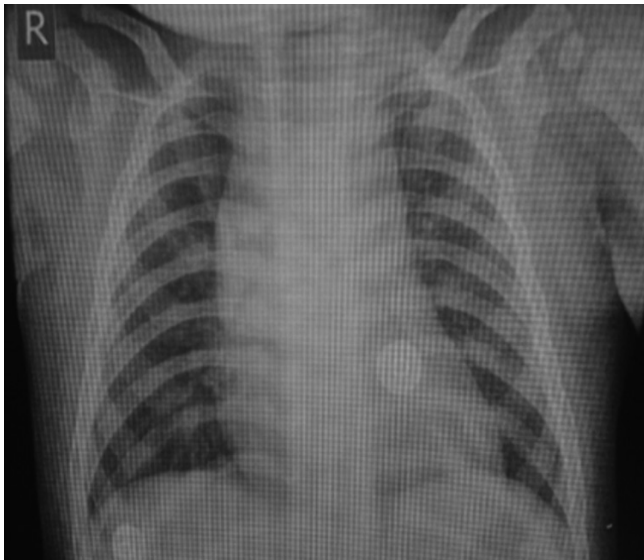

Figure 1. Chest radiography demonstrates an increased cardiothoracic ratio, a prominent right atrium, and pulmonary venous congestion.

The patient was referred to our center for further workup. Transthoracic echocardiography demonstrated ccTGA, Ebstein's tricuspid anomaly, moderate-to-severe tricuspid regurgitation, a small muscular (VSD), an abnormal left arch, and severe CoA (Figure 2). Electrocardiography showed the sinus rhythm, an approximately  $-30^\circ$  mean cardiac axis in the frontal plane, signs of right atrial enlargement, significant Q waves in leads III and aVF, and a poor R progression in the precordial leads, all in favor of the probability of ccTGA.

Computed tomography angiography confirmed these findings. Balloon angioplasty was considered to address the discrete CoA but was postponed due to recurrent

viral infections (Figure 3). Based on close clinical and echocardiography follow-ups of the patient at 7 months of age, balloon angioplasty was performed with a 7×20 mm Tyshak-mini balloon (Figure 4). Preprocedurally, the patient had a pulmonary arterial pressure of 50 mm Hg and a CoA gradient of 55 mm Hg, which decreased to 15 mm Hg after the procedure.

Follow-up echocardiograms were conducted every 3 months. They revealed a narrow isthmus in the aorta but no significant CoA or gradient and only a mild tricuspid regurgitation. The patient's oxygen saturation remained at 98%, and his physical activity level was acceptable.

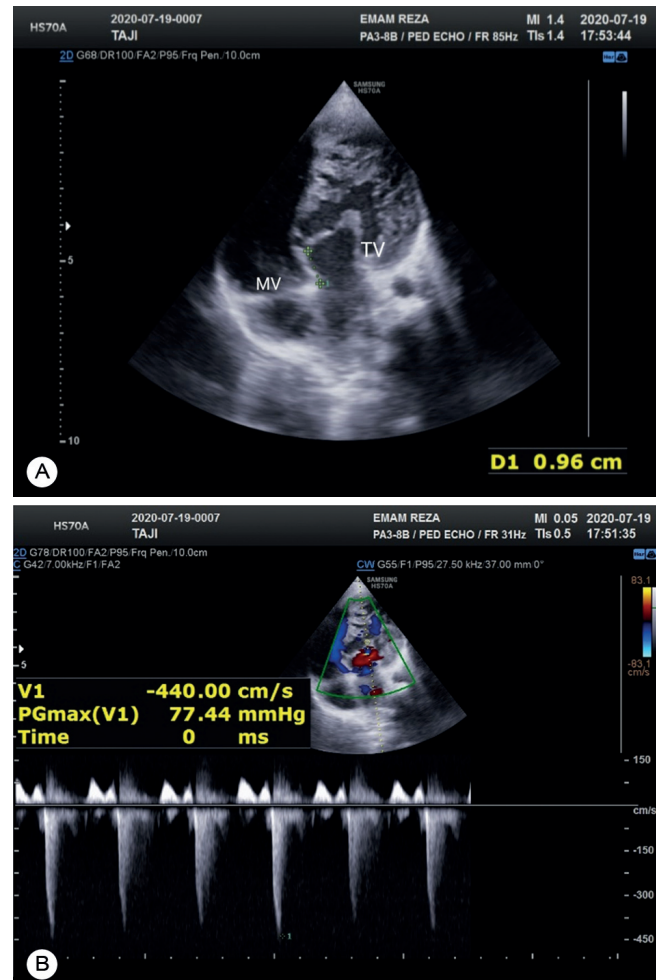


Figure 2. A) The apical 4-chamber view shows characteristic Ebstein's anomaly with the displacement of the tricuspid valve. Additionally, a markedly hypertrophic morphological right ventricle is seen on the left side. B) Continuous-wave Doppler imaging of the tricuspid valve displays a peak gradient of 77.44 mm Hg.

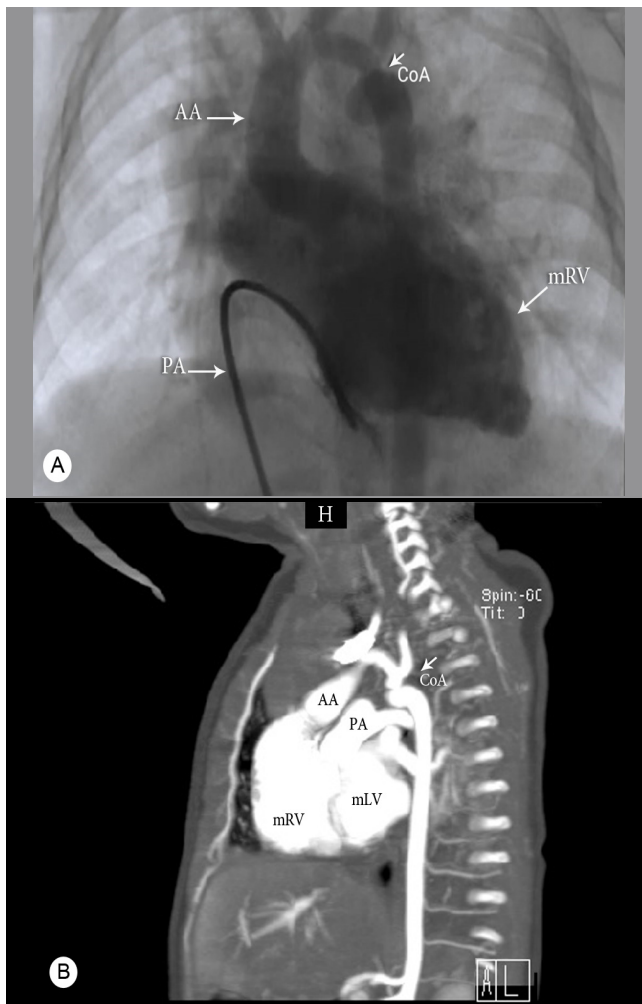


Figure 3. A) This image depicts the course of a venous catheter in our patient diagnosed with congenitally corrected transposition of the great arteries as captured in the anteroposterior view. The catheter, inserted via the right femoral vein, was navigated through the venous system into the right atrium, crossing the tricuspid valve into the morphologic left ventricle (mLV). After the injection in the recirculation phase, with the return of the patient's blood to the left atrium and the morphologic right ventricle (mRV) as the systemic ventricle, the blood entered the ascending aorta (AA) and the arch. Subsequently, the coarctation area was visualized. The contrast medium was injected at a speed of 7 mL/s for a total volume of 10 mL. B) Coarctation of the aorta (CoA) was confirmed in the computed tomography angiogram.

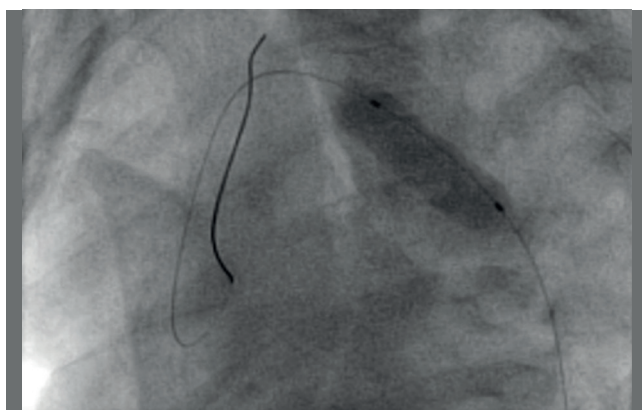

Figure 4. The left anterior oblique view of the aortic root angiogram

displays the successful percutaneous transluminal angioplasty, with the balloon clearly positioned correctly.

## Discussion

The occurrence of 3 concurrent cardiac anomalies in a single patient is exceptionally rare. Ebstein's anomaly is characterized by the downward displacement of the tricuspid valve,<sup>9</sup> and associated cardiac defects should be considered when managing individuals with this condition.<sup>6</sup> Prior studies have reported the coexistence of CoA and Ebstein's anomaly.<sup>4</sup> CoA can be diagnosed on echocardiography by observing flow changes in the thoracic or abdominal aorta.<sup>1</sup> Previous research has also noted the association between CoA and TGA.<sup>10</sup> Our patient had interesting features since he presented with ccTGA, CoA, and Ebstein's anomaly simultaneously.

Surgical intervention or balloon angioplasty with or without stenting, depending on the patient's hemodynamic status, is the typical approach.<sup>1,6</sup> Weight gain is a significant factor when evaluating the feasibility of balloon angioplasty, a common procedure in younger children.<sup>5</sup> Appropriate balloon size is determined based on angiography or echocardiographic sizing.<sup>5</sup> Although balloon angioplasty increases the risk of aneurysm formation, it is less invasive and can be performed on infants aged 6 to 12 months.<sup>11</sup> Unstable hemodynamic and electrophysiological changes may necessitate urgent surgery in symptomatic neonates.<sup>12</sup> Patients with severe CoA undergoing surgery often require reintervention within the first 6 months.<sup>11</sup> These conditions, alongside other associated anomalies, could potentially affect the patient's tolerance to invasive surgical procedures. Therefore, we opted for balloon angioplasty for CoA in our case due to its less invasive nature and lower risk than surgery. This decision was also influenced by the patient's unstable hemodynamic status and recurrent viral infections. Frequent follow-ups are necessary after balloon angioplasty.<sup>12</sup> We initially monitored our patient every 3 months and then every 6 months via echocardiography. The patient is currently 3.5 years old. On the latest follow-up, his physical function remained acceptable, and a narrow aortic isthmus without significant CoA was observed. The management of other anomalies will be based on the patient's clinical condition and progress.

## Conclusion

In this report, we presented an exceedingly rare case of CHDs occurring concurrently. It is important to consider the possibility of associated cardiac abnormalities, such as levo-TGA and Ebstein's anomaly, when evaluating patients with CoA. The management of these patients must be tailored to



their specific hemodynamic condition and requires careful consideration. Moreover, close monitoring and follow-up care are essential components in the successful management of patients who have undergone balloon angioplasty.

## References

1. Desai L, Stefek H, Berhane H, Robinson J, Rigsby C, Markl M. Four-Dimensional flow Magnetic Resonance Imaging for Assessment of Pediatric Coarctation of the Aorta. *J Magn Reson Imaging* 2022;n;55:200-208.
2. Bakhshaliyev S, Özalp ZGK, Güneş M, Genç SB, Kamalı H, Şengül FS, Ergün S, Haydin S. Surgical treatment of Ebstein anomaly in pediatric patients: A 10-year single-center study. *J Card Surg* 2021;36:3138-3145.
3. Walsh EP. Ebstein's Anomaly of the Tricuspid Valve: A Natural Laboratory for Re-Entrant Tachycardias. *JACC Clin Electrophysiol* 2018;4:1271-1288.
4. He BJ, Merriman AF, Cakulev I, Stambler BS, Srivastava D, Scheinman MM. Ebstein's Anomaly: Review of Arrhythmia Types and Morphogenesis of the Anomaly. *JACC Clin Electrophysiol* 2021;7:1198-1206.
5. Doshi AR, Chikkabyrappa S. Coarctation of Aorta in Children. *Cureus* 2018;10:e3690.
6. Ganigara M, Doshi A, Naimi I, Mahadevaiah GP, Buddha S, Chikkabyrappa SM. Preoperative Physiology, Imaging, and Management of Coarctation of Aorta in Children. *Semin Cardiothorac Vasc Anesth* 2019;23:379-386.
7. Kuehl KS, Loffredo CA. Population-based study of l-transposition of the great arteries: possible associations with environmental factors. *Birth Defects Res A Clin Mol Teratol* 2003;67:162-167.
8. Khajali Z, Maleki M, Mohebbi B, Aliramezany M. Coarctation Stenting in a Rare Case with Congenitally Corrected Transposition of the Great Arteries and the Bicuspid Aortic Valve. *J Tehran Heart Cent* 2020;15:27-30.
9. Mishra AK, Barwad P, Bansal V, Mandal B, Srivastava A, Naganur SH. Ebstein's anomaly of tricuspid valve with aortic stenosis and coarctation of aorta: Successful single-stage repair of a rare adult congenital heart disease. *J Card Surg* 2020;35:3160-3165.
10. Ojha V, Singh SP, Ponnuswamy KG, Jagia P. Transposition of great arteries with coarctation of aorta: a rare association demonstrated on dual source CT. *Acta Cardiol* 2021;76:214-215.
11. Ylinen MK, Tyni VE, Pihkala JI, Salminen JT, Sairanen H, Sarkola T. Procedural risk factors, incidence and timing of reintervention after treatment for native coarctation of the aorta in children: a population-based study†. *Eur J Cardiothorac Surg* 2019;55:564-571.
12. Sendzikaite S, Sudikiene R, Lubaua I, Silis P, Rybak A, Brzezinska-Rajszyz G, Obrycki Ł, Jankauskiene A, Litwin M. Multi-centre cross-sectional study on vascular remodelling in children following successful coarctation correction. *J Hum Hypertens* 2022;36:819-825.