



# A Rare Dermatologic Reaction in an Adult Patient Following Coronary Angiography: Acute Generalized Exanthematous Pustulosis

Şahhan Kılıç, MD<sup>1</sup>, İrem Yılmaz, MD<sup>1</sup>, Süha Asal, MD<sup>1</sup>, Hasan Kadir Yelkenci, MD<sup>2</sup>, Mehtap Güner Toprak, MD<sup>3</sup>, Almina Erdem, MD<sup>1</sup>, Tufan Çınar, MD<sup>1\*</sup>, Ahmet Lütfullah Orhan, MD<sup>1</sup>

<sup>1</sup>Department of Cardiology, Sultan II. Abdülhamid Han Training and Research Hospital, Health Sciences University, Istanbul, Turkey.

<sup>2</sup>Department of Dermatology, Sultan II. Abdülhamid Han Training and Research Hospital, Health Sciences University, Istanbul, Turkey.

<sup>3</sup>Department of Pathology, Sultan II. Abdülhamid Han Training and Research Hospital, Health Sciences University, Istanbul, Turkey.

Received 03 January 2023; Accepted 28 March 2023

Acute generalized exanthematous pustulosis (AGEP) is an exceedingly uncommon exanthematous condition caused primarily by drugs and characterized by widespread, numerous, tiny, non-follicular, sterile, and superficial pustules throughout the entire body.<sup>1</sup> This condition has spontaneous recovery in a short period following medication withdrawal.<sup>2</sup> We report the first case of AGEP caused by the use of iohexol following coronary angiography (CA).

A 58-year-old woman presented to our clinic with symptoms of exertional dyspnea and intermittent claudication. The patient had diabetes and hypertension, for which she was taking carvedilol (12.5 mg per day), losartan (50 mg per day), and subcutaneous insulin. Both of the patient's distal lower extremity pulses were weak on physical examination. Her laboratory results were unremarkable. Transthoracic echocardiography revealed a decreased left ejection fraction of 40% with global hypokinesia. She had no history of coronary or peripheral angiography. Thus, CA and peripheral angiography were scheduled. The peripheral angiography demonstrated that both lower limbs were fully occluded distal to the popliteal arteries, with poor distal collateral filling. In addition, diffuse critical coronary artery stenosis was noted on CA. A 120 mL contrast medium containing 350 mg/mL iohexol was utilized throughout the procedure. The patient had no history of contrast media exposure. The procedure was completed without complications. The patient was discharged, and peripheral angioplasty was planned for the following week. She presented to the emergency clinic a day after the procedure with a fever, extensive erythema, and itching (Figure 1. A, B & C). Her vital signs were stable except for a 38.2 °C fever. On physical examination, there were non-follicular pustular lesions all over the body, particularly on the limbs, around the umbilicus, and the face. Laboratory

*J Teh Univ Heart Ctr 2023;18(2):151-153*

**This paper should be cited as:** Şahhan Kılıç, İrem Yılmaz, Süha Asal, Hasan Kadir Yelkenci, Mehtap Güner Toprak, Almina Erdem, et al. A Rare Dermatologic Reaction in an Adult Patient Following Coronary Angiography: Acute Generalized Exanthematous Pustulosis. *J Teh Univ Heart Ctr 2023;18(2):151-153.*

**Keywords:** Drug-related side effects and adverse reactions; Iohexol; Adverse effects; Dermatologic agents; Adverse effects

\*Corresponding Author: Tufan Çınar, Associate Professor of Cardiology, Department of Cardiology, Sultan III. Abdülhamid Han Training and Research Hospital, Selimiye Mh., Tıbbiye Cd., 34668, Üsküdar, Istanbul, Türkiye. Tel: +90 216 5422020. Fax: +90 216 5422010. E-mail: drtufancinar@gmail.com.



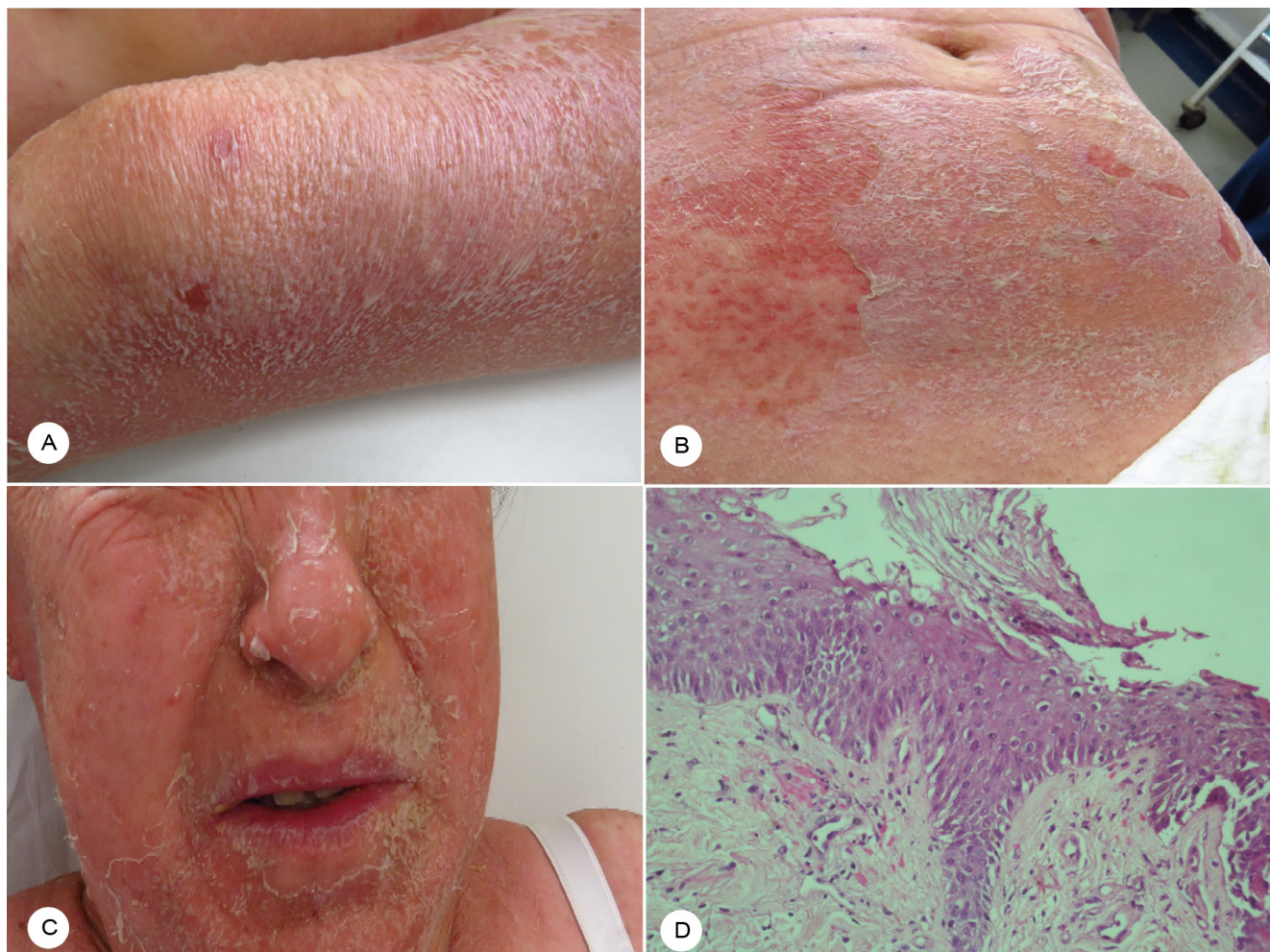


Figure 1. A) Erythema, exfoliation, and non-follicular pustular lesion on the leg  
B) Erythema, exfoliation, and non-follicular pustular lesion around the umbilicus  
C) Erythema, exfoliation, and non-follicular pustular lesions on the face  
D) The histopathological examination shows subcorneal pustulation, intraepidermal neutrophils, epithelial disintegration, spongiosis around the pustule, and a mixed leukocyte response around the vascular structures in the superficial dermis.

tests indicated leukocytosis and a C-reactive protein (CRP) level of 250 mg/L. Eosinophilia could not be detected in blood tests. Coagulation parameters and serological tests were both normal. An experienced dermatologist examined the patient and performed a punch biopsy to confirm AGEP. Subcorneal pustulation, intraepidermal neutrophils, epithelial disintegration, spongiosis around the pustule, and a mixed leukocyte response apparent around the vascular structures in the superficial dermis were identified. There was no eosinophilia in the histopathological examination (Figure 1. D). The AGEP validation score of the EuroSCAR study group was 7. The patient's Naranjo score was +7, indicating the probability that the adverse drug reaction experienced was secondary to the administered medication. The diagnosis of AGEP caused by iohexol usage was confirmed. The skin lesions healed quickly over the next week, and she was discharged uneventfully.

Contrast-related dermatologic reactions can occur following the administration of various contrast agents

during medical imaging procedures. These reactions may manifest as mild skin irritations or more severe dermatologic conditions. The incidence and timing of these reactions can vary depending on the specific contrast agent used. Iodinated contrast agents are commonly used in computed tomography scans and angiographic procedures. These reactions are typically categorized into 2 types: immediate reactions and delayed reactions. Immediate reactions occur within minutes to hours after contrast administration.<sup>3</sup> Symptoms may include urticaria (hives), pruritus (itching), erythema (redness), and angioedema (swelling).<sup>4</sup> These reactions are usually mild and self-limiting. The incidence of immediate skin reactions due to iodinated contrast media is between 1.15 and 0.12%.<sup>3</sup> Delayed reactions are less common and occur several hours to days after contrast exposure.<sup>3</sup> They may present as a maculopapular rash (small, raised bumps), erythema multiforme (target-like skin lesions), or fixed drug eruption (recurring rash at the same site).<sup>5</sup> The incidence of delayed reactions was between 10.1 and 0.03%.<sup>3</sup> These



reactions are also typically mild and resolve without intervention.

2015;73:843-848.

The definitive diagnosis of AGEP is made by both clinical and pathological findings. High neutrophil count and CRP values are observed in most cases. AGEP is a kind of delayed hypersensitivity characterized by the activation of CD4 and CD8 T cells. The EuroSCAR study group, a widely accepted scoring system, has offered several diagnostic criteria to confirm AGEP.<sup>6</sup> The Naranjo score suggests a significant relationship between the drug and the adverse event, emphasizing the need for further investigation and the potential reconsideration of the medication used.<sup>7</sup> Most cases can be easily excluded, but some may be challenging to diagnose, particularly when trying to distinguish between AGEP and generalized pustular psoriasis.<sup>8</sup> In a previous study, although internal organs were not involved, a 5% mortality rate was reported as a result of secondary infections.<sup>9</sup> There is no specific treatment for the disease, and spontaneous recovery is observed with the elimination of the underlying cause, as shown in our case.<sup>2</sup>

In our case, we emphasize that AGEP should be considered in the etiology of a rare dermatological reaction after iohexol use as the possible side effect.

## References

1. De A, Das S, Sarda A, Pal D, Biswas P. Acute Generalised Exanthematous Pustulosis: An Update. *Indian J Dermatol* 2018;63:22-29.
2. Thienvibul C, Vachiramon V, Chanprapaph K. Five-Year Retrospective Review of Acute Generalized Exanthematous Pustulosis. *Dermatol Res Pract* 2015;2015:260928.
3. Iordache AM, Docea AO, Buga AM, Mitrut R, Albulescu D, Zlatian O, Ianosi S, Ianosi G, Neagoie D, Sifaki M, Rogoveanu OC, Branisteanu DE, Calina D. The incidence of skin lesions in contrast media-induced chemical hypersensitivity. *Exp Ther Med* 2019;17:1113-1124.
4. Justiz Vaillant AA, Vashisht R, Zito PM. Immediate Hypersensitivity Reactions. [Updated 2023 March 7]. In: StatPearls [Internet]. Treasure Island (FL): StatPearls Publishing; 2023 Jan-. Available from: <https://www.ncbi.nlm.nih.gov/books/NBK513315/>.
5. Crisafulli G, Franceschini F, Caimmi S, Bottau P, Liotti L, Saretta F, Bernardini R, Cardinale F, Mori F, Caffarelli C. Mild cutaneous reactions to drugs. *Acta Biomed* 2019;90(3-S):36-43.
6. Sidoroff A, Dunant A, Viboud C, Halevy S, Bavinck JN, Naldi L, Mockenhaupt M, Fagot JP, Roujeau JC. Risk factors for acute generalized exanthematous pustulosis (AGEP)-results of a multinational case-control study (EuroSCAR). *Br J Dermatol* 2007;157:989-996.
7. LiverTox: Clinical and Research Information on Drug-Induced Liver Injury [Internet]. Bethesda (MD): National Institute of Diabetes and Digestive and Kidney Diseases; 2012-. Adverse Drug Reaction Probability Scale (Naranjo) in Drug Induced Liver Injury. [Updated 2019 May 4]. Available from: <https://www.ncbi.nlm.nih.gov/books/NBK548069/>.
8. Sidoroff A, Halevy S, Bavinck JN, Vaillant L, Roujeau JC. Acute generalized exanthematous pustulosis (AGEP)--a clinical reaction pattern. *J Cutan Pathol* 2001;28:113-119.
9. Szatkowski J, Schwartz RA. Acute generalized exanthematous pustulosis (AGEP): A review and update. *J Am Acad Dermatol*