

A Comprehensive Review of Left Ventricular Summit Ventricular Arrhythmias

Farzad Kamali, MD^{1,2}, Majid Haghjoo, MD^{1,2}, Yeganeh Pasebani, MD^{1,2}, Abolfath Alizadehdiz, MD^{1,2}, Zahra Emkanjoo, MD^{1,2}, Amirfarjam Fazelifar, MD^{1,2}, Farzad Masoudkabar, MD, MPH³, Ala Keykhavani, MD^{1,2}, Shabnam Madadi, MD^{1,2*}

¹Rajaie Cardiovascular Medical and Research Center, Iran University of Medical Sciences, Tehran, Iran.

²Cardiac Electrophysiology Research Center, Rajaie Cardiovascular Medical and Research Center, Iran University of Medical Sciences, Tehran, Iran.

³Cardiac Primary Prevention Research Center, Cardiovascular Disease Research Institute, Tehran University of Medical Sciences, Tehran, Iran.

Received 26 April 2021; Accepted 10 June 2022

Abstract

The catheter ablation of idiopathic ventricular arrhythmias is accepted as a first-line treatment as it successfully eliminates about 90.0% of such arrhythmias. One of the most challenging ventricular arrhythmias originates from the left ventricular summit (LVS), a triangular epicardial space with the left main bifurcation as its apex. This area accounts for about 14.0% of LV arrhythmias.

The complex anatomy of this region, accompanied by proximity to the major epicardial coronary arteries and the presence of a thick fat pad in this region, renders it a challenging area for catheter ablation.

This article presents a review of the anatomy of the LVS and relevant regions and discusses novel mapping and ablation techniques for eliminating LVS ventricular arrhythmias. Additionally, we elaborate on the electrocardiographic (ECG) manifestations of arrhythmias from the LVS and their successful ablation via the direct approach and the adjacent structures.

J Teh Univ Heart Ctr 2022;17(3):91-102

This paper should be cited as: Kamali F, Haghjoo M, Pasebani Y, Alizadehdiz A, Emkanjoo Z, Fazelifar A, Masoudkabar F, Keykhavani A, Madadi S. A Comprehensive Review of Left Ventricular Summit Ventricular Arrhythmias. *J Teh Univ Heart Ctr 2022;17(3):91-102.*

Keywords: Heart ventricle summit; Ventricular premature complexes; Tachycardia; Ventricular; Ablation techniques

Anatomy of the left ventricular summit (LVS) and relevant sites

The LVS is a triangle region situated in the most superior section of the left epicardial ventricular region, flanked by the 2 branches of the left coronary artery: the left anterior

interventricular artery and the left circumflex artery. The triangle is enclosed by the mitral and septal borders. The most inferior limit of this arc zone is delineated by an arched line with a radius equal to the distance from the left coronary bifurcation artery to the first apparent left coronary artery septal perforator (triangle base). Within this triangular region,

*Corresponding Author: **Shabnam Madadi**, Associate Professor of Clinical Cardiac Electrophysiology, Iran University of Medical Sciences, Rajaie Cardiovascular Medical and Research Center, Valiasr Ave, Adjacent to Mellat Park, Tehran, Iran. 1995614331. Tel: +98 21 23921. Fax: +98 21 22042026. E-mail: drmadadi@gmail.com.

the anterior interventricular cardiac vein, which traverses the anterior portion of the atrioventricular groove, transforms into the great cardiac vein, which continues to the posterior portion of the atrioventricular groove. Thus, the great cardiac vein/the anterior interventricular cardiac vein divides the LVS into 2 distinct areas: the superior area, also referred to as the inaccessible area for radiofrequency ablation (RFA) due to the high risk of coronary vasculature damage, and the inferior area, which is the accessible area for RFA, where interventions are relatively safe.¹ This region comprises the highest portion of the LV epicardium and accounts for 14.0% of LV arrhythmias.²

The ventriculoarterial junction and the sinotubular junction make up the functional aortic annulus. The ventriculoarterial junction consists of a fibrous segment and a muscular segment. The muscular component corresponds to the interventricular septum, below the right coronary cusp and the anterior portion of the left coronary cusp.³

The fibrous section corresponds to the aortomitral continuity and spans between the anterior mitral valve leaflet and the noncoronary and left coronary cusps. The right fibrous trigone is in touch with the central fibrous body (the membranous septum). The His bundle is placed inferior to the junction of the noncoronary cusp and the right coronary cusp on the membranous septum. The left coronary cusp lies in proximity to the intramural component of the LVS and creates the lateral and posterolateral attachments of the aorta to the LV ostium. Due to the presence of substantial epicardial fat at the LVS, the complicated architecture of this region, and its proximity to the main epicardial coronary arteries, ablation in this region may be troublesome.⁴

Ablation of LVS arrhythmias may be performed at the septal right ventricular outflow tract (RVOT), the left coronary cusp, the LV myocardium beneath the left coronary cusp, the distal coronary sinus, and the great cardiac vein, as well as via the epicardial approach. In addition, the septal branches of the left anterior descending artery and the septal veins that drain into the anterior interventricular vein may be targeted for ablation. The left coronary cusp, the great cardiac vein/the anterior interventricular vein junction, the subaortic aspect of the LV myocardium, and both accessible and inaccessible epicardial locations through the percutaneous epicardial approach provide electrocardiographic clues for targeting nearby tissues for effective ablation in LVS arrhythmias.^{3,4} When the ablation of LVS arrhythmias through these other regions fails, epicardial ablation may be tried.^{4,6}

The mechanism of ventricular arrhythmias (VAs) from the LVS seems to be localized (abnormal automaticity or triggered activity). In a few instances, late gadolinium enhancement in the LVS has been observed, although voltage mapping has not substantiated this notion (normal bipolar and unipolar voltages).⁶

ECG manifestations of LVS arrhythmias

LVS premature ventricular contractions (PVCs) and ventricular tachycardias (VTs) have a right bundle branch block (RBBB) pattern with an inferior axis or a left bundle branch block (LBBB) pattern with a low inferior axis and early transition. The breakthrough pattern in lead V_2 is a frequent ECG finding characterized by the sudden disappearance of the R wave in lead V_2 , followed by its recovery in lead V_3 .⁴

The precordial pattern break in V_2 shows that the PVC or the VT originates from an inaccessible region of the LVS near the left anterior descending artery.^{4,5} On ECG, epicardial LV-VTs are characterized by the presence of a Q wave in the leads, reflecting local ventricular activity. A pseudo-delta wave of 34 ms or greater, an intrinsicoid deflection time of 85 ms or greater, and a shortest RS complex of 121 ms or greater are in favor of an epicardial origin, with sensitivity/specificity ranging from 14.0% to 99.0% and 20% to 94.0%, respectively, based on location.⁷

The most common ECG abnormalities in LVS arrhythmias include RBBB or LBBB with V_2 or V_3 transition, a longer R wave in III than in II, a pseudo-delta wave and/or maximum deflection index of 0.55, a V_2 pattern break, a negative lead I, and a more negative aVL than aVR.

The Q-wave ratio in leads aVL/aVR is a helpful marker for distinguishing between successful ablation target locations. A ratio of 1.41 shows that the aortic sinus of Valsalva might be targeted as a successful ablation site. Still, a value between 1.41 and 1.53 suggests that the subvalvular aortic area could be the location of the success signal. In ratios between 1.53 and 1.74, the great cardiac vein/the anterior interventricular vein is the most common site of effective ablation, but a ratio of 1.74 favors an epicardial strategy for ablation.^{2,8}

Concerning VA sources in the great cardiac vein/the anterior interventricular vein and accessible regions, a III/II amplitude ratio of 1.25 and an aVL/aVR amplitude ratio of 1.75 indicate that an epicardial approach is required.^{2,5}

Several ECG measures assess the accessibility of the epicardial zone. The RBBB pattern is typical of PVCs originating from the accessible zone, which is accessible through the anterior interventricular vein or the great cardiac vein. Those originating from an inaccessible zone never exhibit the RBBB pattern.

S waves in leads V_5 or V_6 are more prevalent in arrhythmias originating from the great cardiac vein/the anterior interventricular vein junction and accessible areas, and they are uncommon in those deriving from the inaccessible epicardial region.⁸

Successful epicardial ablation is related to the presence of at least 2 of the following 3 ECG abnormalities in patients requiring a percutaneous epicardial approach: (1) a Q-wave ratio in leads aVL/aVR of greater than 1.85, (2) an R/S wave ratio in lead V_1 of greater than 2, and (3) the absence of the first q wave in lead V_1 , with a sensitivity of 100.0% and a



specificity of 72.0%.⁶

Mapping of the aortic sinus of Valsalva, the subaortic area, and the great cardiac vein for LVS VAs

Most prior research has revealed that LVS VAs might be ablated from the neighboring anatomical areas, including the aortic sinus of Valsalva, the subaortic region, and the great cardiac vein/the anterior interventricular vein junction. According to earlier research, the Q-wave ratio in leads aVL/aVR may predict the successful ablation location. With a sensitivity of 100% and a specificity of 95%, the aVL/aVR Q-wave ratio is correlated with the aortic sinus of Valsalva origin. In the subaortic valve region, this ratio is around 1.41 to 1.53, with a sensitivity of 80.0% and a specificity of 98.0%. In cases with the great cardiac vein/the anterior interventricular vein junction as the success site of PVC/VA elimination, this ratio is around 1.53 to 1.74, with 85.0% sensitivity and 98.0% specificity. In values exceeding 1.74, endocardial ablation is ineffective, and epicardial treatment is suggested.⁵ The average distance from successful sites to the LVS in the aortic sinus of Valsalva, the subvalvular region, and the great cardiac vein/the anterior interventricular vein junction is 11 mm, 16 mm, and 22 mm, respectively. If the distance between the successful site and the LVS tip is more than 11.6 mm, epicardial ablation is necessary. The aVL/aVR Q-wave ratio is directly correlated with the distance between the successful site and the tip of the LVS, with greater distances associated with higher ratios (Figures 1 & 2).^{8,9}

Mapping and ablation of the coronary sinus, the great cardiac vein/the anterior interventricular vein junction, and the intramural LVS

For the mapping of the coronary sinus and the great cardiac vein/the anterior interventricular vein junction, a 4 Fr quadripolar catheter is inserted into the distal portion of the great cardiac vein to record the activation of the great cardiac vein/the anterior interventricular vein and compare it with the other locations in the LVOT. After the mapping of the structures close to the LVS such as the left coronary cusp, the RVOT, the subaortic LVOT, and the anterior mitral valve is done, the coronary venous septum is mapped if the intramural source is suspected.

The following criteria define the intramural origin¹⁰:

1. Isochronal local activation timings in numerous locations with an early signal of slightly more than 10 ms
 2. Ablation efforts at additional locations that fail
- Coronary venous mapping is performed by extending

an Agilis Sheath (St Jude Medical, Sylmar, California) via a long guidewire into the coronary sinus through the right femoral vein. A guidewire might be pushed into the first septal perforator vein to map the intramural component of the LV septum. For the selective cannulation of the first septal perforator branch, a hydrophilic-coated 4 Fr catheter (Terumo) is utilized. After venography, if there is a suitable septal perforator for mapping, a 0.014-inch wire (vision wire) is inserted into that branch and connected unipolar for pace mapping and acquiring activation data.

An epicardial etiology of arrhythmias is postulated if the great cardiac vein/the anterior interventricular vein junction activation time is earlier than that of the other RVOT and LVOT locations. If the activation time in the first septal perforator is earlier than that of the great cardiac vein/the anterior interventricular vein junction, and if the best pace mapping is performed intraseptally in instances with isochronous activation timings with the other neighboring structures, an intramural origin may be suspected.^{4,10}

RF energy application is successively tried from the nearby structures utilizing an open irrigated 3.5 mm tip catheter with a power of 20 W to 50 W and a temperature limit of 42°C to produce an impedance decrease of 10 Ω to 15 Ω (Figures 3 & 4).¹⁰

Epicardial ablation of LVS VAs

The catheter ablation of VAs from the LVS via the epicardial approach is complex because of the closeness of the major epicardial coronary arteries and the ineffectiveness of RFA due to the high quantity of epicardial fat in this area.

In most instances, the ablation of the nearby structures, such as the left coronary cusp, the RVOT, the subaortic region of the LV, and the great cardiac vein/the anterior interventricular vein junction successfully terminates the arrhythmia.

In individuals whose endocardial ablation via the nearby LVS regions is ineffective, epicardial mapping and ablation may be attempted.

In approximately two-thirds of cases, RFA cannot be performed due to the proximity of the major epicardial coronary arteries; however, in a small subset of patients who are at a safe distance from the coronary arteries, RFA is unsuccessful, indicating the existence of a thick layer of fat, rendering the ablation ineffective.

The LVS is split into 2 sections based on the great cardiac vein: 1) toward the triangle's tip, in the superomedial area (the inaccessible zone), and 2) in the triangle's base, the inferolateral part (the accessible zone).

The origin of the arrhythmia is from the midline and apex of the LVS triangle, which is related to the QS pattern in lead V₁ and is associated with effective epicardial ablation.

Conscious sedation or general anesthesia is used for percutaneous epicardial ablation.⁶ After the insertion of

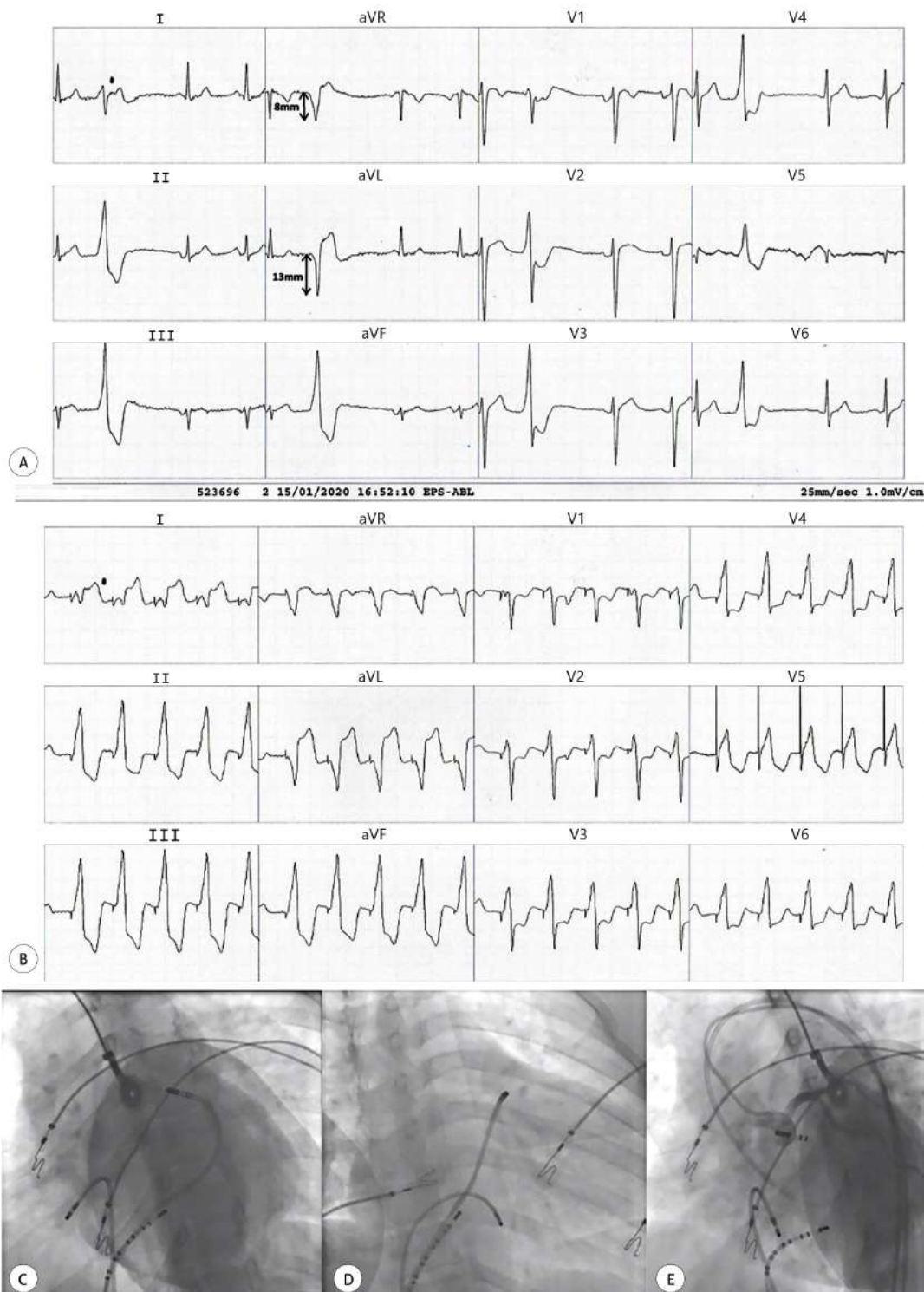


Figure 1. The images depict the successful ablation of an LVS PVC from a 4 mm tip-irrigated ablation catheter. The earliest activation time with perfect pace mapping was recorded in the GCV/ AIV junction (earlier than the endocardial site).

A) The image shows the baseline ECG with a PVC having an LBBB pattern and a right inferior axis with a precordial transition in lead V₃. The Q wave ratio in leads aVL/aVR is 1.62, suggesting that the GCV/AIV could be targeted as a successful ablation site.

B) The image shows perfect pace mapping obtained by pacing from the GCV/AIV.

C & D) The images show the ablation catheter position in the GCV/AIV junction in LAO and RAO fluoroscopic views, respectively.

E) The image demonstrates catheter positions and the coronary anatomy in the LAO projection.

AIV, Anterior interventricular vein; AVL, Augmented vector left; AVR, Augmented vector right; ECG Electrocardiogram; GCV, Great cardiac vein; LAO, Left anterior oblique projection; LBBB, Left bundle branch; LVS, Left ventricular summit; PVC, Premature ventricular complex; RAO, Right anterior oblique projection

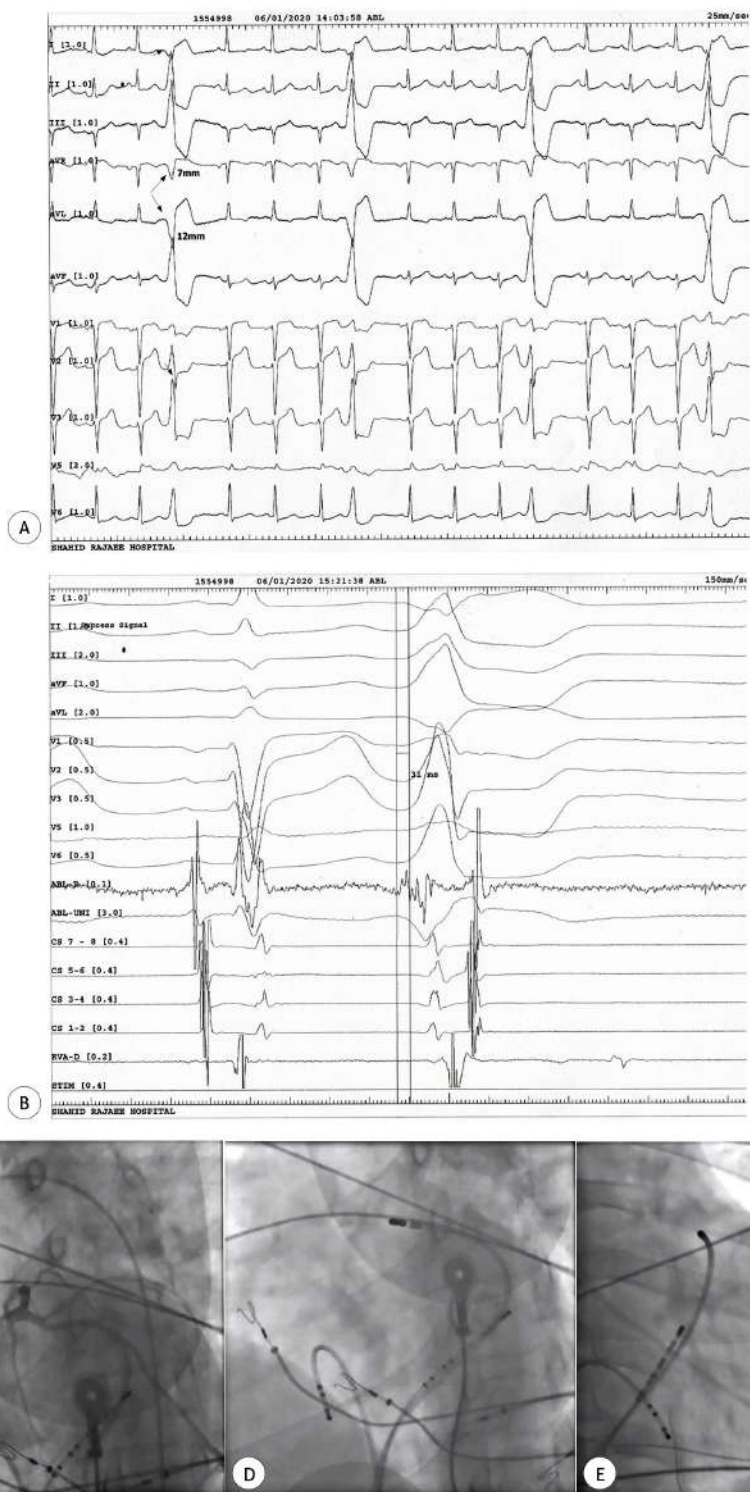

Figure 2. The images depict the successful ablation of an LVS PVC from the great cardiac vein/anterior interventricular vein junction. A) The image shows the baseline ECG with a PVC having an RBBB pattern, an inferior axis (the R wave in lead III is larger than that in lead II), and a QS pattern in lead I. The AVL/AVR Q wave ratio is 1.71, suggesting that the GCV/AIV could be targeted as a successful ablation site. B) The image shows the earliest activation time (31 ms) recorded in the GCV/AIV junction. C) The image shows the coronary anatomy in the LAO caudal position (Spider view). D & E) The image shows the ablation catheter position in the GCV/AIV junction in LAO and RAO fluoroscopic views, respectively.

AIV, Anterior interventricular vein; AVL, Augmented vector left; AVR, Augmented vector right; GCV, Great cardiac vein; LAO, Left anterior oblique projection; LVS, Left ventricular summit; PVC, Premature ventricular complex; RAO, Right anterior oblique projection

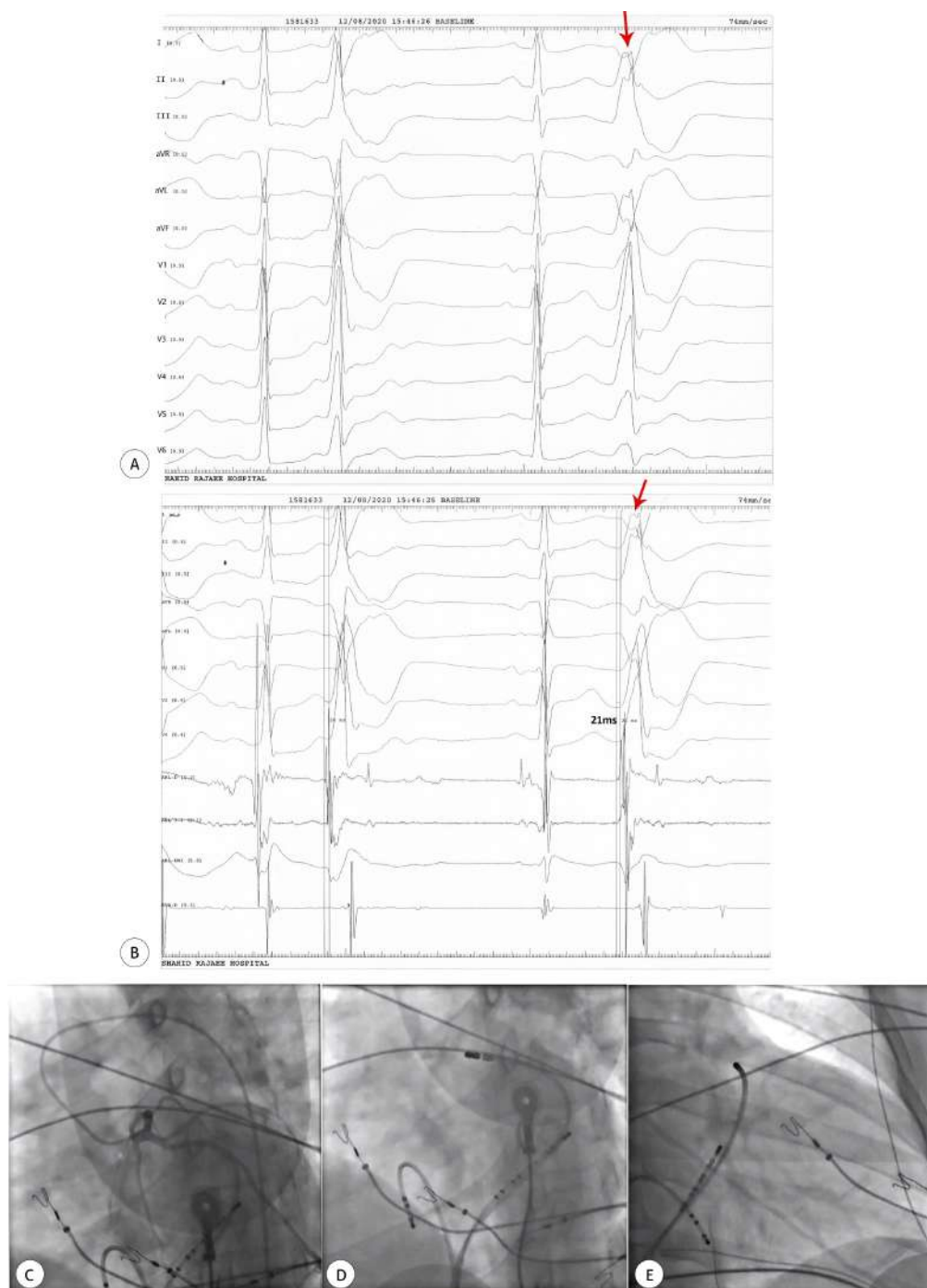


Figure 3. The image shows the successful ablation of an LVS PVC from the LV subvalvular endocardium below the LCC. A) The image shows the baseline ECG with 2 PVCs. The second PVC is a clinical PVC (marked by the arrow) with an RBBB pattern, a right inferior axis, and a QS pattern in lead I. The first PVC is a catheter-induced PVC, while the ablation catheter is located in the LV subvalvular portion of the LCC, which has a different morphology from the clinical PVC. The pace map from this site is also poor. Activation mapping of the GCV/AIV junction, the RVOT, the LCC, and the LV subvalvular endocardium does not reveal a signal earlier than 21 milliseconds at the LV subvalvular endocardium below the LCC. B) The image shows RF ablation with a 4 mm tip-irrigated catheter with a power of 40 W, resulting in the late elimination of the PVC within 20 seconds, while ablation fails in the other sites, including the GCV/AIV junction. B) The image shows the earliest activation time (21 ms) recorded in the LV subvalvular portion of the LCC. C) The ablation catheter position in the GCV/AIV junction is shown in the LAO projection. D) The image shows the ablation catheter position in the LV endocardium opposite the recording of the earliest signal by the ablation catheter at the GCV/AIV site. (Compare the location of the ablation catheter in panels C and D.) AIV, Anterior interventricular vein; AVL, Augmented vector left; AVR, Augmented vector right; ECG, Electrocardiogram; GCV, Great cardiac vein; LAO, Left anterior oblique projection; LCC, Left coronary cusp; LVS, Left ventricular summit; LV, Left ventricular; PVC, Premature ventricular complex; RAO, Right anterior oblique projection; RVOT, Right ventricular outflow tract

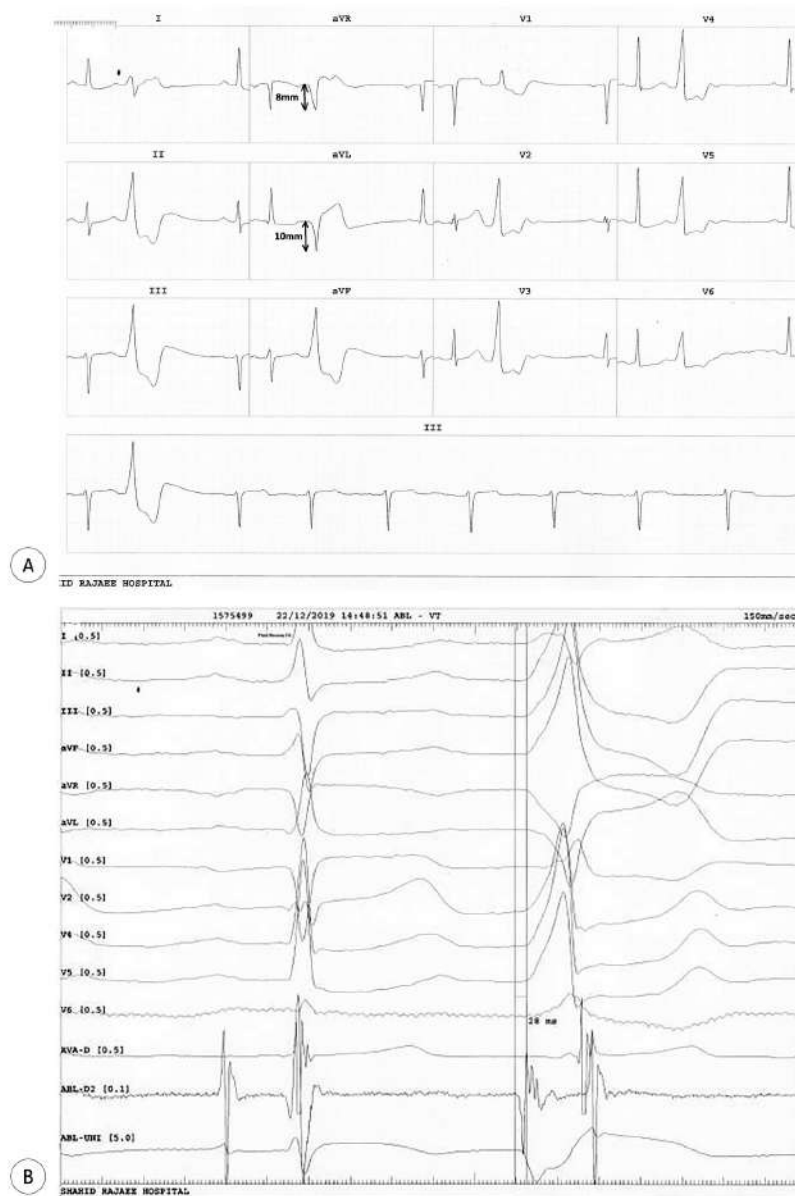

Figure 4. The images illustrate the successful ablation of an LVS PVC using bipolar RF ablation between the earliest GCV site and the earliest site at the LV endocardium below the LCC.

A) The image shows the baseline ECG with a PVC having an RBBB pattern and a right inferior axis with an AVL/AVR Q wave ratio of 1.25.

B) The image shows the earliest activation time (28 ms) recorded in the GCV/AIV junction. RF application in both sites of the subvalvular aorta and the GCV/AIV junction, which records the signal earlier than the other sites, transiently diminishes the PVC but does not completely terminate it.

C & D) The images demonstrate catheter positions and the coronary anatomy in LAO and RAO projections. The proximity of the RF ablation catheter with the coronary arteries (0.5-1 cm) is notable in these fluoroscopic views.

D & E) The images show the fluoroscopic views (LAO and RAO, respectively) of the ablation catheters during bipolar RF ablation between the LV endocardium below the LCC and the GCV/AIV junction.

diagnostic catheters through the femoral vein in the high right atrium, the RV, and the coronary sinus and the conduct of invasive hemodynamic monitoring, the Sosa method is often drawn upon to gain access to the pericardial area.¹⁰

According to earlier research, intracardiac echocardiography is suggested for determining tissue catheter contact, distance from the left main ostium (in the left coronary cusp mapping and ablation), monitoring RF supply, and detecting complications.

In the epicardial method, a 3D electroanatomical mapping system is utilized to identify the anatomical structures close to the LVS and map the activation of the epicardial region. Before ablation, coronary angiography is indicated for defining the course and ostium of the coronary arteries and the distance from catheter ablation at the earliest location. In successful epicardial ablation sites, the first activation point occurs at about -30 ms on the ablation channel prior to the surface QRS (range = -40-20 ms).

As shown by previous research, the efficacy of the epicardial method in LVS VA ablation is low, with an acute success rate of around 22.0% and a long-term arrhythmia suppression rate of 17.0%. In certain instances, cryoablation has been employed as the ablation energy source (Figure 5).¹¹

Retrograde coronary venous ethanol infusion for LVS VAs

Transarterial coronary ethanol ablation has been widely described as an alternate therapy technique in the medical literature. It has become a therapy of last resort for patients with VTs unresponsive to contact-based ablation. Transarterial coronary ethanol ablation is constrained by the risks of arterial instrumentation, the dependence on feasible arterial anatomy, which is frequently affected by the ischemic disease leading to the VT substrate, the risk of unintended collateral damage, and the logistical challenges of requiring interventional cardiology support.¹² Retrograde coronary venous ethanol ablation is an alternate treatment option with more tolerable risks in such instances. Although transarterial coronary ethanol ablation is relatively successful, it is limited by technical difficulties and potential side effects, such as coronary artery dissection, complete atrioventricular block, and pericarditis.

For the establishment of the LVS origin and the vein targets, the coronary sinus is accessed through the femoral vein with an 8.5 Fr sheath. A multielectrode catheter is utilized to map the great cardiac vein and the anterior interventricular vein. The catheter could be a DECANAV catheter (Biosense Webster), a 3 Fr duo-decapolar catheter (MapIT, APT EP, Rogers, Minnesota), or a 2 Fr decapolar catheter (EP Star, Baylis, Toronto, Ontario, Canada). The earliest great cardiac vein/ anterior interventricular vein location is then identified. The multielectrode catheter is withdrawn, and a 6 Fr angioplasty

guide catheter (JR4 [Judkins Right] or left internal mammary artery) is advanced to conduct venograms to find potential intramural venous branches close to the earliest location of the lesion. Left-leaning branches are designated diagonals, while right-leaning branches are considered septal (Central Illustration). As soon as the target branch is located, an angioplasty wire with a diameter of 0.01 inches (BMW; Abbott; Santa Clara, California) is inserted. Next, a fine-cross catheter (Terumo; Elkton, Maryland) is used to cover the wire, leaving about 5 mm of the wire's tip exposed. A maximum of seven 1 mL injections of ethanol may be given, depending on the therapeutic response and the extent of myocardial staining (Figure 2 & 3).¹³

LVS VA ablation via the left atrial appendage

RFA from the left atrial appendage is complicated and is often avoided due to the possibility of perforation. However, there are 2 recorded instances of this method.

In a case report, Yakubov et al¹⁴ successfully ablated LVS VAs via the left atrial appendage. During the procedure, the coding system, and the VT, the ECG had an LBBB pattern and an inferior axis with an R/S transition in lead V₃. The RVOT was the initial activation location (32 s) during PVCs and the inducible VT. Still, the ablation was unsuccessful in this area. Accordingly, following the failure in the RVOT, coronary cusp mapping was performed, and despite a 32 ms early signal in the left coronary cusp ablation, it was unsuccessful. Next, coronary sinus mapping was performed. During the great cardiac vein ablation, the arrhythmia was not eradicated. The accelerated ventricular beat was seen as a localized response of the underlying tissue following the ablation of the left coronary cusp and the great cardiac vein. Pace mapping in these 3 structures was imperfect; hence, the epicardial origin of the arrhythmia between these 3 locations was suspected. Therefore, Yakubov and colleagues endeavored to map and ablate the arrhythmia center via the left atrial appendage.

After the transseptal approach, passage into the left atrial appendage, left coronary artery angiography, and contrast injection into the left atrial appendage to evaluate their dimensional connection, the ablation catheter was inserted toward the LVS. The earliest activation signal was 32 ms in duration. There was a safe gap between the coronary arteries and the ablation catheter tip (≈ 5 mm). Consequently, RFA with a titrated energy level of up to 40 W for 40 seconds and an irrigated setting of 17 mL was performed in the posterior apical part of the left atrial appendage. After the ablation, VTs were inducible no more.

In the second example, described almost 20 years ago, a VT with positive concordance morphology in the V₁-V₆, inferior axis and QS in I and aVL was effectively ablated

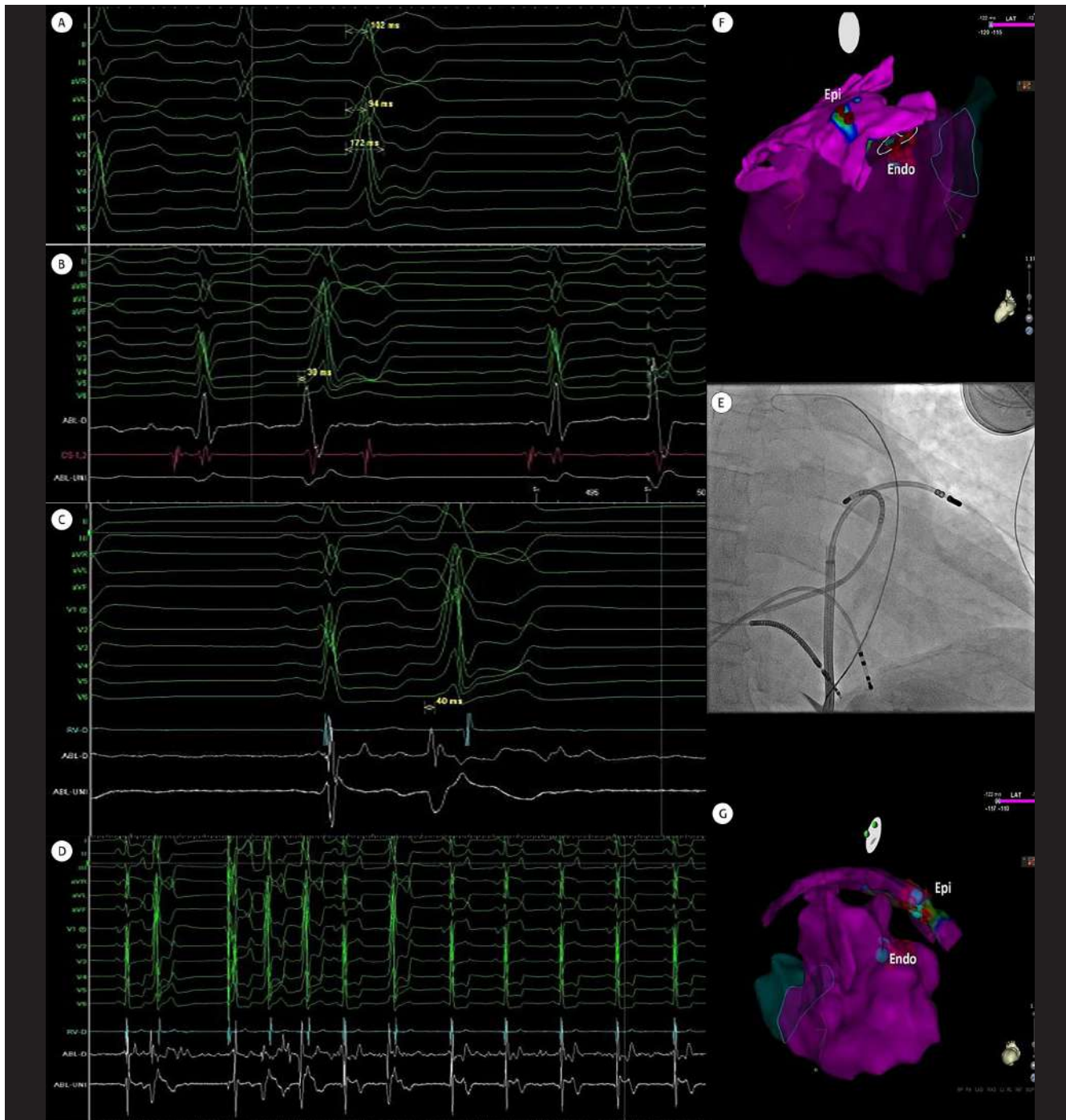


Figure 5. The images depict the successful ablation of an LVS PVC via the epicardial approach.

A) The image shows the baseline ECG with a PVC having an RBBB pattern, a right inferior axis, a QS pattern in lead I, and an MDI of 55% (94/170) in the precordial leads, suggesting the epicardial origin of the PVC.

B) The image shows the earliest signal recorded by endocardial mapping (30 ms) at the antrolateral part of the MV ring. Note that the signal recorded in the ablation catheter is earlier than the signal recorded in the distal CS catheter, which is located in the GCV.

C & D) The images show the successful ablation of the PVC after catheter placement in the anterobasal portion via the percutaneous epicardial approach. As is shown in Panel D, the PVC disappears immediately after the start of ablation.

E) The image displays the RAO fluoroscopic view of the ablation catheter position at the site of the earliest signal (40 ms) in the anterobasal part of the LV.

F & G) The images show the CARTO 3D reconstruction and electroanatomical activation mapping from the anterobasal part of the LV endocardium and epicardium combined. The red dots indicate the ablation sites on the LV endocardium and the opposite side in the epicardium. Successful ablation was possible from the LV epicardium.

AIV, Anterior interventricular vein; AVL, Augmented vector Left; AVR, Augmented vector right; ECG, Electrocardiogram; GCV, Great cardiac vein; LAO, Left anterior oblique projection; LCC, Left coronary cusp; LVS, Left ventricular summit; LV, Left ventricular; MDI, Maximum deflection index; MV, Mitral valve; PVC, Premature ventricular complex; RAO, Right anterior oblique projection; RBBB, Right bundle branch block; RVOT, Right ventricular outflow tract

from the left atrium. Contact force catheters seem to be of great utility in minimizing the danger of perforation in such instances.¹⁵

Ablation of inaccessible LVS VAs via the left pulmonary cusp

There is a single case of successful inaccessible LVS PVC ablation from the left pulmonary cusp after 2 unsuccessful efforts. The patient had numerous PVCs with an early transition in V_1 and the S wave in V_2 , a positive QRS in V_3 - V_6 , and a QS pattern in aVL with an inferior axis.

Pace mapping in the anterior interventricular vein matched the clinical arrhythmia to a degree of 99.0%. However, RF delivery in that region was terminated owing to its proximity to the left anterior descending artery. Previous RF delivery to the LV endocardium and the left coronary cusp failed. Prolonged aortic mitral continuity ablation was related to transient PVC suppression.

With the aid of a reversed U-shaped method and the pull-down procedure in the left pulmonary cusp with an irrigated tip catheter, the PVC was eradicated with no recurrence during the follow-up. The proximity of the left pulmonary cusp to the inaccessible region of the LVS makes it an alternate target for the ablation of arrhythmias in this location. This location is also close to the coronary arteries; thus, coronary angiography is indicated before RFA for measuring coronary artery distance.

In earlier investigations, the use of a reversed U-shaped approach to improve mapping and ablation effectiveness in treating pulmonary sinus cusp-derived VAs was described. Nonetheless, the use of the technique as an alternative for reaching inaccessible LVS VAs is intriguing.¹⁶⁻¹⁸

Bipolar ablation in LVS VAs

Sources of intramural arrhythmias that are deeply rooted are sometimes inaccessible to typical RFA catheters. In such situations, bipolar RFA is required.¹⁹ In documented examples of bipolar ablation in deeply seated outflow tract PVCs, an open irrigated RFA catheter is positioned in the left coronary cusp. Another open irrigated RFA catheter is positioned in the RVOT at the earliest possible time. The left coronary cusp catheter is irrigated using the normal circuit, while the RVOT catheter is irrigated manually with a 50 mL syringe.

The left coronary cusp catheter is then linked to the ablator anode. With the use of a grounding cable, the cathodal port of the ablator is connected to the jumper wire. The connector is attached to the junction box. The RVOT catheter is linked to the anodal end of the jumper. Bipolar energy transmission using the left coronary cusp terminal as the active terminal and the RVOT terminal as the ground stops the arrhythmia.

RF energy is around 20 W at 43°C. In such instances, steam explosions are an issue.

Sequential unipolar RFA and simultaneous unipolar RFA are also possible alternatives in certain comparable circumstances. Simultaneous unipolar RFA necessitates the use of 2 ablaters.¹⁹⁻²¹

In prior research, simultaneous unipolar RFA and sequential unipolar RFA were unable to induce intramural lesions in septal thicknesses more than 12 mm and 15 mm, respectively. Bipolar RFA produced intramural and transmural lesions up to 15 mm in thickness.²¹

Using half saline as a cooling irrigant for irrigated ablation is an intriguing method for overcoming the difficulties of intramural VAs.²² By reducing the ionic content of the irrigant solution, the dispersion of the RF energy to the surrounding environment is decreased, allowing for the formation of lesions that are deeper and bigger.

With careful attention to the impedance drop and temperature curves, it is advised to employ titrated RF energy beginning at 25 W and progressively rising to 45 W.²²⁻²⁴ Maintaining the real-time vision of the tissue target using intracardiac echocardiography is also highly beneficial for detecting steam bubbles that precede bursts.²⁴

Infusion needle RFA for LVS VAs

Catheters irrigated endovascularly can ablate about 7 mm of the tissue surface. Developing an infusion needle ablation catheter is an effort to overcome this issue. The catheter for needle ablation is an 8 Fr catheter with a dome (tip) electrode and a ring electrode. A 27-gauge needle may be extended up to 10 mm from the dome. A thermocouple is housed inside the lumen of the hand needle near the needle's tip. The distal catheter shaft is connected to the electroanatomical mapping system. During mapping, 1 mL/min of heparinized saline flows continuously. The needle functions as a unipolar electrode, and a bipolar electrogram is taken using the needle and the dome. If the location chosen for ablation has been meticulously mapped, 1 mL of saline and contrast is injected for tissue staining after rigorous mapping. If the spot is chosen for ablation, normal saline is injected at a 2 mL/min rate for 60 seconds, followed by dome-based RF energy delivery. RF energy is applied with a temperature-controlled 60°C target and a power titration from 15 W to 35 W.²⁵ Lesion formation is indicated by the absence of capture at the stimulus output previously captured at that place. This catheter gives patients with intramural and inaccessible epicardial origins a novel ablation opportunity.

Surgical ablation of LVS VAs

There are accounts in the literature of successful surgical ablation. In an example of PVC-induced cardiomyopathy with an LVS origin, endocardial mapping via the RVOT,



and the LVOT, the aortic sinus of Valsalva, in conjunction with epicardial mapping via the great cardiac vein, yielded unsatisfactory findings. In addition, a percutaneous epicardial approach was abandoned owing to closeness to the coronary artery; hence, surgical ablation was advised.²⁶⁻²⁸ Due to a flow-limiting lesion in the proximal portion of the left anterior descending artery, the patient was a candidate for coronary artery bypass grafting and concurrent PVC ablation in a hybrid operating room. After a medical sternotomy and the use of CARTO 3D mapping, LVS mapping was performed. Next, a thick layer of epicardial fat (5 mm) covering the proximal coronary arteries was dissected. Mapping revealed an early activation time of approximately -60 ms pre-QRS and a long fractionated electrogram in the sinus beats. Subsequently, cryoablation was performed for 3 minutes at -65°C using the Cryo intracardiac echocardiography system. Twenty seconds after the commencement of the cryoablation, the PVCs were abolished. The second cryoablation for 5 minutes was performed using the same conditions and site. There were no PVCs in subsequent examinations.²⁷⁻²⁹ There are a few rare instances of such cases in the medical literature, and in all of them, an experienced multidisciplinary team is required for favorable outcomes.

Late elimination of LVS VAs by anatomical ablation

The superior (medial or basal) portion of the LV septum is deemed unreachable for RF ablation. In some circumstances, anatomical ablation from the opposite sides of the inaccessible zone, such as the left coronary cusp, the right coronary cusp, the aortic mitral continuity, the RVOT, and the great cardiac vein, might result in the total eradication of LVS VAs.

In certain situations when the initial eradication of VAs is effective, there is a delayed elimination of PVCs during follow-up visits.^{30, 31}

Anatomical ablation is performed with irrigated RF energy, with the earliest signal occurring around -20 seconds before the QRS or with an acceptable pace map 11/12 in the endocardial locations or the great cardiac vein. Lesions caused by RF ablation result from resistive and conductive heat transfer to the tissue.

Ablation lesions are zones of coagulative necrosis surrounded by an area of inflammation. Therefore, surrounding inflammation may result in lesion enlargement and delayed consequences up to 30 days following ablation.

When transmural scarring is not possible, the second mechanism of late elimination may be a circumferential conduction block at the exit locations of VAs. In addition to filling in the spaces between lesions, late growth and maturation may also fill in the spaces between lesions. In a study, late elimination was seen in around 20.0% of LVOT VAs.²

Conclusion

The LVS is a frequent and challenging cause of VAs. LVS VAs might be ablated from the nearby structures, such as the left coronary cusp, the right coronary cusp, the RVOT, the subaortic valve region of the LV, the aortic mitral continuity, the great cardiac vein/the anterior interventricular vein junction, the left atrial appendage, and the left pulmonary cusp. Percutaneous epicardial ablation and direct surgical ablation are alternatives. In situations involving intramural sites and an inaccessible zone, bipolar ablation, half saline as an irritant, transvenous ethanol ablation, and the insertion of a needle catheter have shown encouraging outcomes.

References

1. Kuniewicz M, Baszko A, Ali D, Karkowski G, Loukas M, Walocha JA, Holda MK. Left Ventricular Summit-Concept, Anatomical Structure and Clinical Significance. *Diagnostics (Basel)* 2021;11:1423.
2. Yamada T, McElderry HT, Doppalapudi H, Okada T, Murakami Y, Yoshida Y, Yoshida N, Inden Y, Murohara T, Plumb VJ, Kay GN. Idiopathic ventricular arrhythmias originating from the left ventricular summit: anatomic concepts relevant to ablation. *Circ Arrhythm Electrophysiol* 2010;3:616-623.
3. Ortale JR, Gabriel EA, Iost C, Márquez CQ. The anatomy of the coronary sinus and its tributaries. *Surg Radiol Anat* 2001;23:15-21.
4. Enriquez A, Malavassi F, Saenz LC, Supple G, Santangeli P, Marchlinski FE, Garcia FC. How to map and ablate left ventricular summit arrhythmias. *Heart Rhythm* 2017;14:141-148.
5. Lin CY, Chung FP, Lin YJ, Chong E, Chang SL, Lo LW, Hu YF, Tuan TC, Chao TF, Liao JN, Chang YT, Chen YY, Chen CK, Chiou CW, Chen SA, Tsao HM. Radiofrequency catheter ablation of ventricular arrhythmias originating from the continuum between the aortic sinus of Valsalva and the left ventricular summit: Electrocardiographic characteristics and correlative anatomy. *Heart Rhythm* 2016;13:111-121.
6. Santangeli P, Marchlinski FE, Zado ES, Benhayon D, Hutchinson MD, Lin D, Frankel DS, Riley MP, Supple GE, Garcia FC, Bala R, Desjardins B, Callans DJ, Dixit S. Percutaneous epicardial ablation of ventricular arrhythmias arising from the left ventricular summit: outcomes and electrocardiogram correlates of success. *Circ Arrhythm Electrophysiol* 2015;8:337-343.
7. Tung R, Shivkumar K. Epicardial Ablation of Ventricular Tachycardia. *Methodist Debakey Cardiovasc J* 2015;11:129-134.
8. Bazan V, Gerstenfeld EP, Garcia FC, Bala R, Rivas N, Dixit S, Zado E, Callans DJ, Marchlinski FE. Site-specific twelve-lead ECG features to identify an epicardial origin for left ventricular tachycardia in the absence of myocardial infarction. *Heart Rhythm* 2007;4:1403-1410.
9. Yokoyama K, Nakagawa H, Shah DC, Lambert H, Leo G, Aeby N, Ikeda A, Pitha JV, Sharma T, Lazzara R, Jackman WM. Novel contact force sensor incorporated in irrigated radiofrequency ablation catheter predicts lesion size and incidence of steam pop and thrombus. *Circ Arrhythm Electrophysiol* 2008 ;1:354-362.
10. Sosa E, Scanavacca M, d'Avila A, Pilleggi F. A new technique to perform epicardial mapping in the electrophysiology laboratory. *J Cardiovasc Electrophysiol* 1996;7:531-536.
11. Di Biase L, Al-Ahamad A, Santangeli P, Hsia HH, Sanchez J, Bai R, Bailey S, Horton R, Gallingshouse GJ, Burkhardt DJ, Lakkireddy D, Yang Y, Badhwar N, Scheinman M, Tung R, Dello Russo A, Pelargonio G, Casella M, Tomassoni G, Shivkumar K, Natale A. Safety and outcomes of cryoablation for ventricular tachyar-

- rhythmias: results from a multicenter experience. *Heart Rhythm* 2011;8:968-974.
12. Kreidieh B, Rodríguez-Mañero M, Schurmann P, Ibarra-Cortez SH, Dave AS, Valderrábano M. Retrograde Coronary Venous Ethanol Infusion for Ablation of Refractory Ventricular Tachycardia. *Circ Arrhythm Electrophysiol* 2016;9:10.1161/CIRCEP.116.004352 e004352.
 13. Tavares L, Lador A, Fuentes S, Da-Wariboko A, Blaszyk K, Malaczynska-Rajpold K, Papiashvili G, Korolev S, Peichl P, Kautzner J, Webber M, Hooks D, Rodríguez-Mañero M, Di Toro D, Labadet C, Sasaki T, Okishige K, Patel A, Schurmann PA, Dave AS, Rami TG, Valderrábano M. Intramural Venous Ethanol Infusion for Refractory Ventricular Arrhythmias: Outcomes of a Multicenter Experience. *JACC Clin Electrophysiol* 2020;6:1420-1431.
 14. Yakubov A, Salayev O, Hamrayev R, Sultankhonov S. A case of successful ablation of ventricular tachycardia focus in the left ventricular summit through the left atrial appendage: a case report. *Eur Heart J Case Rep* 2018;2:tyt110.
 15. Sosa E, Scanavacca M, d'Avila A. Catheter ablation of the left ventricular outflow tract tachycardia from the left atrium. *J Interv Card Electrophysiol* 2002;7:61-65.
 16. Futyma P, Moroka K, Derndorfer M, Kollias G, Martinek M, Pürerfellner H. Left pulmonary cusp ablation of refractory ventricular arrhythmia originating from the inaccessible summit. *Europace* 2019;21:1253.
 17. Dong X, Sun Q, Tang M, Zhang S. Catheter ablation of ventricular arrhythmias originating from the junction of the pulmonary sinus cusp via a nonreversed U curve approach. *Heart Rhythm* 2019;16:1513-1520.
 18. Dong X, Tang M, Sun Q, Zhang S. Usefulness of Reversed U-Curve Technique to Enhance Mapping and Ablation Efficiency in the Treatment of Pulmonary Sinus Cusp-Derived Ventricular Arrhythmias. *Am J Cardiol* 2018;122:814-820.
 19. Teh AW, Reddy VY, Koruth JS, Miller MA, Choudry S, D'Avila A, Dukkupati SR. Bipolar radiofrequency catheter ablation for refractory ventricular outflow tract arrhythmias. *J Cardiovasc Electrophysiol* 2014;25:1093-1099.
 20. Pandian J, Nandhakumar V, Saravanan S. Radiofrequency ablation of deep seated outflow tract ventricular tachycardia using custom modified bipolar irrigated radiofrequency ablation setup. *Indian Pacing Electrophysiol J* 2019;19:197-201.
 21. Koruth JS, Dukkupati S, Miller MA, Neuzil P, d'Avila A, Reddy VY. Bipolar irrigated radiofrequency ablation: a therapeutic option for refractory intramural atrial and ventricular tachycardia circuits. *Heart Rhythm* 2012;9:1932-1941.
 22. Nguyen DT, Olson M, Zheng L, Barham W, Moss JD, Sauer WH. Effect of Irrigant Characteristics on Lesion Formation After Radiofrequency Energy Delivery Using Ablation Catheters with Actively Cooled Tips. *J Cardiovasc Electrophysiol* 2015;26:792-798.
 23. Nguyen DT, Gerstenfeld EP, Tzou WS, Jurgens PT, Zheng L, Schuller J, Zipse M, Sauer WH. Radiofrequency Ablation Using an Open Irrigated Electrode Cooled With Half-Normal Saline. *JACC Clin Electrophysiol* 2017;3:1103-1110.
 24. Nguyen DT, Tzou WS, Sandhu A, Gianni C, Anter E, Tung R, Valderrábano M, Hranitzky P, Soejima K, Saenz L, Garcia FC, Tedrow UB, Miller JM, Gerstenfeld EP, Burkhardt JD, Natale A, Sauer WH. Prospective Multicenter Experience With Cooled Radiofrequency Ablation Using High Impedance Irrigant to Target Deep Myocardial Substrate Refractory to Standard Ablation. *JACC Clin Electrophysiol* 2018;4:1176-1185.
 25. Stevenson WG, Tedrow UB, Reddy V, AbdelWahab A, Dukkupati S, John RM, Fujii A, Schaeffer B, Tanigawa S, Elsokkari I, Koruth J, Nakamura T, Naniwadekar A, Ghidoli D, Pellegrini C, Sapp JL. Infusion Needle Radiofrequency Ablation for Treatment of Refractory Ventricular Arrhythmias. *J Am Coll Cardiol* 2019;73:1413-1425.
 26. Atienza F, Arenal Á, Pérez-David E, Elizaga J, Ortuño JE, Ledesma-Carbayo MJ, Sánchez-Quintana D, Fernández-Avilés F. New diagnostic and therapeutic approaches to treat ventricular tachycardias originating at the summit of the left ventricle: role of merged hemodynamic-MRI and alternative ablation sources. *Circ Arrhythm Electrophysiol* 2013;6:e80-84.
 27. Lampert SM, Michaud GF, Couper GS, Muehlschlegel JD. Epicardial cryoablation resulting in precipitous left ventricular dysfunction. *J Thorac Cardiovasc Surg* 2013;145:e41-e42.
 28. Choi EK, Nagashima K, Lin KY, Kumar S, Barbhaiya CR, Baldinger SH, Reichlin T, Michaud GF, Couper GS, Stevenson WG, John RM. Surgical cryoablation for ventricular tachyarrhythmia arising from the left ventricular outflow tract region. *Heart Rhythm* 2015;12:1128-1136.
 29. Okabe T, Rushing GD, Kalbfleisch SJ. Surgical Mapping and Ablation in the Left Ventricular Summit Guided by Presurgery Pericardial Mapping. *J Innov Card Rhythm Manag* 2019;10:3582-3587.
 30. Fenelon G, Brugada P. Delayed effects of radiofrequency energy: mechanisms and clinical implications. *Pacing Clin Electrophysiol* 1996;19(4 Pt 1):484-489.
 31. Nath S, Whayne JG, Kaul S, Goodman NC, Jayaweera AR, Haines DE. Effects of radiofrequency catheter ablation on regional myocardial blood flow. Possible mechanism for late electrophysiological outcome. *Circulation* 1994;89:2667-2672.