



Therapeutic Effects of Edaravone on Azoospermia: Free Radical Scavenging and Autophagy Modulation in Testicular Tissue of Mice

Mahsa Ghaffari Novin ^{1,2#}, Mohammadamin Sabbagh Alvani ^{3#}, Mohammadreza Mafi Balani ³, Abbas Aliaghaei ³, Azar Afshar ³, Fakhroddin Aghajanzpour ³, Reza Soltani ³, Hamid Nazarian ³, Maryam Salimi ³, Ahad Hasan Seyed Hasani ³, Shabnam Abdi ⁴, Mohammad-Amin Abdollahifar ^{3*}, Pourya Raee ^{3*}

1- Mens Health and Reproductive Health Research Center, Shahid Beheshti University of Medical Sciences, Tehran, Iran

2- Islamic Azad University Science and Research Branch, Tehran, Iran

3- Department of Biology and Anatomical Sciences, School of Medicine, Shahid Beheshti University of Medical Sciences, Tehran, Iran

4- Department of Anatomical Sciences & Cognitive Neuroscience, Faculty of Medicine, Tehran Medical Sciences, Islamic Azad University, Tehran, Iran

The first and the second authors have had equal contribution to this manuscript

Abstract

Background: Chemotherapeutic agents such as cyclophosphamide and busulfan have been shown to have a negative impact on the spermatogenesis process. Based on this fact, the objective of this study was to investigate the effects of edaravone on spermatogenesis in busulfan-induced mice.

Methods: Forty adult male mice were equally divided into the four groups: 1) control, 2) edaravone, 3) busulfan, and 4) busulfan + edaravone. Then, the sperm parameters, histopathological examinations, and serum levels of testosterone, follicle-stimulating hormone (FSH), and luteinizing hormone (LH) were also assessed. Caspase-3, Beclin-1, and ATG-7 mRNA levels were also determined using real-time PCR.

Results: Our results revealed that treatment of mice with edaravone in busulfan-induced azoospermia significantly improves sperm parameters, including total count, morphology, and viability ($p < 0.05$). Furthermore, edaravone administration led to a significant increase in serum testosterone ($p < 0.0001$) and FSH ($p < 0.001$) levels, as well as testis weight ($p < 0.05$) and volume ($p < 0.01$). Edaravone also prevented a decrease in the number of testicular cells including spermatogonia ($p < 0.0001$), primary spermatocytes ($p < 0.001$), round spermatids ($p < 0.0001$), Sertoli ($p < 0.01$), and Leydig cells ($p < 0.0001$) in busulfan-treated mice. Additionally, in busulfan-induced azoospermia, edaravone significantly reduced the percentage of sperm with immature chromatin ($p < 0.0001$). Following treatment with edaravone, a decrease in reactive oxygen species (ROS) and an increase in glutathione (GSH) production were noted compared to busulfan-treated mice. Furthermore, caspase-3 ($p < 0.05$), Beclin-1, and ATG-7 ($p < 0.001$) genes expression decreased significantly in treatment groups compared to busulfan-induced azoospermia.

Conclusion: According to our findings, edaravone can improve spermatogenesis in busulfan-induced azoospermia through free radical scavenging and autophagy modulation in testicular tissue.

Keywords: Autophagy modulation, Azoospermia, Busulfan, Edaravone, Free radical scavenger.

To cite this article: Ghaffari Novin M, Sabbagh Alvani MA, Mafi Balani MR, Aliaghaei A, Afshar A, Aghajanzpour F, et al. Therapeutic Effects of Edaravone on Azoospermia: Free Radical Scavenging and Autophagy Modulation in Testicular Tissue of Mice. *J Reprod Infertil.* 2022;23(2):73-83. <https://doi.org/10.18502/jri.v23i2.8990>.

* Corresponding Authors:
Mohammad-Amin
Abdollahifar, Department
of Biology and Anatomical
Sciences, School of
Medicine, Shahid Beheshti
University of Medical
Sciences, Tehran, Iran,
postal code: 19839-63113

Pourya Raee, Department of
Biology and Anatomical
Sciences, School of
Medicine, Shahid Beheshti
University of Medical
Sciences, Tehran, Iran,
postal code: 19839-63113
E-mail:
m_amin58@yahoo.com,
abdollahima@sbmu.ac.ir,
pourayarayi3@gmail.com

Received: Jul. 28, 2021

Accepted: Aug. 25, 2021

Introduction

Obstructive (OA) or non-obstructive (NOA) azoospermia is the medical condition defined as the complete absence of spermatozoa

in semen due to obstruction, inadequate hormonal stimulation, or impaired spermatogenesis. Azoospermia and oligozoospermia also occur due to

exposure to toxic substances, genetic factors, injuries, immunosuppressants, and anticancer drugs such as cyclophosphamide and busulfan (1, 2).

An interruption in germ cell differentiation leading to a spermatogenic arrest may result in either oligozoospermia or azoospermia in men (3-5). Therefore, given the underlying cause of infertility in such conditions, it is important to develop a more effective treatment. In this case, a wide variety of medications such as follicle-stimulating hormone (FSH), antiestrogens, L-carnitine, and antioxidants have been reported to improve the quality of sperm. Based on the critical role of testicular oxidative stress in azoospermia, antioxidant supplementation has been suggested as a promising therapeutic intervention for infertile men with spermatogenic failure (5, 6).

By inducing oxidative stress, excessive amounts of reactive oxygen species (ROS) adversely affect sperm parameters and the DNA integrity of germ cells. Antioxidants prevent damage caused by free radicals and other reactive metabolites by averting their formation, scavenging them, or facilitating their degradation into various less-damaging molecular breakdowns (7-9). Therefore, due to their reducing effects on ROS levels in seminal plasma, antioxidant-based treatment is a possible and practical approach in improving male fertility potential.

Edaravone (3-methyl-1-phenyl-2-pyrazolin-5-one), as an antioxidant molecule, has been used safely for the clinical treatment of acute ischemic stroke in Japan since 2001 (10). The antioxidant properties of edaravone work by inactivating hydroxyl radical (OH) and thus, inhibiting the OH-dependent and OH-independent lipid peroxidation by supplying individual free-radicals with one of its electrons. Several reports have shown that edaravone as a potent scavenger of hydroxyl radicals has anti-apoptotic, anti-necrotic, anti-cytokine, and anti-autophagy effects in various diseases in the brain (11), heart (12), lungs (13), liver (14, 15), testis (15), kidneys (16), pancreas (17), and small intestine (18) in animal models. Furthermore, as demonstrated in a recent study, edaravone treatment significantly relieved morphological damage and increased lipid peroxidation and apoptosis in testicular tissue by suppressing increased oxidative stress in the diabetes-induced testicular dysfunction in the rat (15).

Therefore, it seems that free radical scavenger, edaravone, would be an effective preventative/therapeutic measure for busulfan-induced testicu-

lar dysfunction. However, there is no information available on the effects of edaravone on free radical scavenger and its autophagy modulation in the testicular tissue of azoospermic mice induced by busulfan.

Methods

Animals: In the current study, 40 adult male NMRI mice (27-30 gr) were selected from the laboratory animal center in Pasteur Institute of Iran. Mice were housed at room temperature under a 12 hr light/12 hr dark cycle with free access to water and food. Mice were randomly divided into four experimental groups (10 mice in each group):

I. control group consisted of animals which were intact, II. edaravone group (10 mg/kg), III. busulfan (45 mg/kg, single dose), and IV. busulfan+edaravone (45 mg/kg+edaravone 10 mg/kg) group. All mice were kept for 35 days after a single dose of busulfan injection and next treated with edaravone for 35 days and then sacrificed for subsequent assessments. Experiments of the present study were conducted between December 2020 and February 2021. All procedures were approved by the Medical Ethics Committee of Shahid Beheshti University of Medical Sciences, Tehran, Iran (IR.SBMU.MSP.REC.1400.023).

Semen analysis: The tail of the epididymis was removed and transferred to a Petri dish containing 1 ml warmed Ham's F 10 (Sigma, USA). Then, the epididymis was minced and incubated at 37°C in 5% CO₂ for 15-20 min to release sperm from the epididymis. Next, each 10 µl of sperm mixture was transferred to a 1 ml microtube to evaluate sperm parameters (19). To determine the sperm count and motility, 190 µl of Ham's F-10 medium was added to each microtube, mixed, and then assessed in two individual replicates using Neubauer hemocytometer slide and phase-contrast microscopy, at 200× magnification. Finally, the total sperm count was reported. The sperm viability and morphology were assessed by staining the sperm samples with Eosin-Nigrosine.

Sperm chromatin dispersion (SCD) test: The SCD test was performed using the Halospermt kit (INDAS Laboratories, Spain). In the SCD test, sperm with fragmented DNA cannot produce and visualize the peripheral halo of the dispersed DNA loop, but in healthy sperm, this peripheral halo is observed. A minimum of 300 spermatozoa per sample were scored under the 100x microscope objective (20).

Sperm chromatin maturation assay (Aniline blue staining): For aniline blue staining, a fresh sperm smear of each sample was air-dried and then fixed in 3% buffered glutaraldehyde in 0.2 M phosphate buffer (pH=7.2) for 30 min at room temperature. The smear samples were treated with 5% aqueous AB stain (BDH, UK, Cat. No. 34003, 5 g powder in 100 ml distilled water) in 4% acetic acid (pH=3.5) for 5 min. Finally, 10 μ l of the sample was placed on each slide and counted under a light microscope. It should be mentioned that unstained nuclei were considered normal sperm with mature chromatin, and blue nuclei were considered abnormal sperm with immature chromatin. Then, the percentage of abnormal spermatozoa was reported (20).

Hormonal assessment: Blood samples were obtained from the heart during deep anesthesia. Blood samples were centrifuged at 2500 RPM for 5 min at 4°C prior to storing at -80°C until use. Mice specific ELISA kit was utilized to measure the serum levels of LH and FSH (catalogue No. CSB-E11162r, Cosmo Bio USA).

Tissue preparation: The testicles were fixed in Bouin's solution for 24 hr. The serial sections with 5 and 20 μ m thicknesses using a microtome (Leica RM2125 RTS, Leica Germany) were consistent with the stereological techniques and they were stained by hematoxylin and eosin (H&E) (Sigma, USA). Then, 10 sections were selected by systematic uniform random sampling (SURS). Finally, the volume of testis and testicular cells were evaluated from the morphological appearance.

Stereological assessment: Using a projection microscope designed at Stereology Research Center, testicular volume by Cavalieri's principle was determined based on the following formula:

$$V = \sum P \times \frac{a}{p} \times t.$$

In this equation, the $\sum P$ is the number of points counted, and the a/p is an area of probe points divided by the magnification. The t is the distance between tissue sections (2, 21).

Length density of the seminiferous tubules: The number of seminiferous tubules was counted to determine the length density of seminiferous tubules; using the optical disector method and the following formula:

$$L_v = \frac{2 \sum Q}{\sum P \times \frac{a}{f}},$$

the length density of seminiferous tubules was estimated. In this equation, $\sum P$ is the total number

of the fields counted, and the $\sum Q$ is the total number of the seminiferous tubules profiles counted per tissue section. The a/f is the area of the probe divided by magnification (2).

Number of testicular cells: The optical disector method was used for estimating the number of testicular cells. Using the equation:

$$N_v = \frac{\sum Q}{\sum P \times h \times \frac{a}{f}} \times \frac{t}{BA},$$

the numerical density (N_v) of testicular cells was determined.

In the above formula, $\sum Q$, the number of testicular cells, was estimated using a microcator (Heidenhain, Germany) connected to the stage of the microscope and used for measurement of height of the disector (h) and real thickness of the tissue section (t), and the $\sum P$ is the total number of the fields counted. The a/f is the area of probe divided by magnification, and the BA is the thickness of the tissue section (1, 2).

ROS and GSH measurement: ROS production was measured by 2',7'-dichlorofluorescein diacetate (DCF-DA; Sigma-Aldrich, USA) after reaction of DCF-DA with H_2O_2 for 20 min at 37°C in the dark. This feature lets the flow cytometry apparatus measure DCF with the count of 10^4 cells in the excitation wavelength of 488 nm and emission wavelength of 527 nm (22). Glutathione assay kit (Zelbio GmbH, Germany) was used for determining glutathione peroxidase (GPX) as per the manufacturer's instructions. The GPX activity unit as the content of the sample would catalyze the decomposition of 1 μ mol of GSH in 1 min. To identify the ratio, 10^6 cells were isolated, and two markers named O-Phthalaldehyde (OPA) and N-Ethylmaleimide (NEM) were applied in the test and then read by ELISA reader at 495 nm excitation and 530 nm emission wavelengths (22).

Analysis of gene expression: After RNA extraction, the samples were treated with DNase I (Roche, Switzerland) to eliminate genomic DNA contamination. For cDNA synthesis, a commercial kit (Fermentas, Lithuania) was used at 42°C for 60 min according to the manufacturer's instructions, and to quantify the relative expression of genes by TaqMan real-time PCR based on the QuantiTect SYBR Green kit, RT-PCR (Takara Bio Inc., Japan) was used. PCR was tested using the Primer-Blast tool available at www.ncbi.nlm.nih.gov/tools/primer-blast. β -actin as a house-keeping gene is a standard gene considered as an internal control (Table 1).

Table 1. Primers design

Genes	Primer sequences
β -actin	F: TCAGAGCAAGAGAGGCATCC R: GGTCATCTTCTCACGGTTGG
Caspase-3	F: AGTGGGATTGATGAGGAGATGG R: AGTGGAGTGTAGGGAGAAGGA
Beclin-1	F: AGGCTGAGGCGGAGAGATTG R: TGTGGAAGGTGGCATTGAAGAC
ATG-7	F: AGGACCCAACATAGATCAGAC R: CACTTGAACACTTGAGGCTAC

Statistical analysis: All results in this study were presented as mean±SD. All statistical analyses were performed using the SPSS software version 20 (IMB, USA), and statistical significance was assessed using the one-way ANOVA (and Tukey's post-hoc test). Statistical significance was set at $p < 0.05$.

Results

Sperm parameters: Our results confirmed that the total sperm count in the busulfan group was sig-

nificantly lower than control ($p < 0.0001$), edaravone ($p < 0.0001$), and busulfan+edaravone ($p < 0.05$) groups (Figure 1A). Furthermore, statistical analysis revealed that the sperm count in the busulfan+edaravone group was significantly lower than control ($p < 0.0001$) and edaravone ($p < 0.0001$) groups (Figure 1A). The total number of spermatozoa showed a higher recovery rate in the treatment group than in the busulfan group ($p < 0.05$) (Figure 1A).

The percentage of immotile sperm was significantly higher in the busulfan and busulfan+ edaravone groups compared to other groups ($p < 0.0001$) (Figure 1B). Moreover, our results showed that the sperm viability and normal morphology significantly declined in the busulfan group compared to other groups (Figures 1C and 1D). The results also revealed that the percentages of sperm viability and normal morphology in the busulfan+edaravone group were significantly lower than control ($p < 0.001$ and $p < 0.0001$, respectively) and edaravone ($p < 0.001$ and $p < 0.0001$, respectively) groups (Figures 1C and 1D). Further-

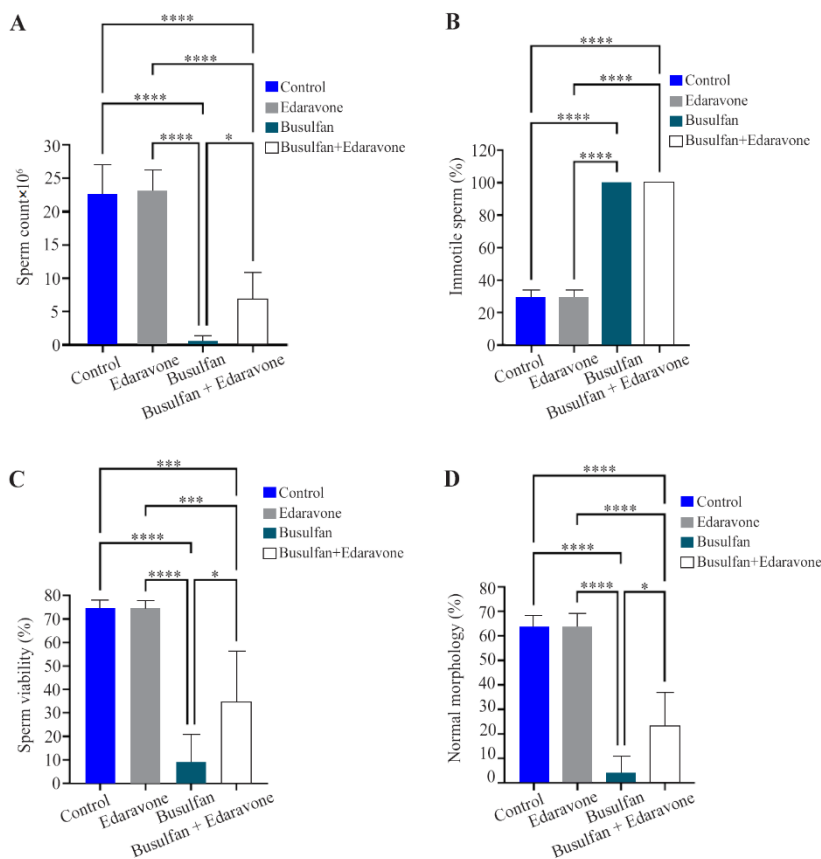


Figure 1. A-D) The effect of edaravone on sperm parameters in study groups. Mean±SD of the total sperm count, percentage of sperm motility, percentage of sperm viability and normal morphology of sperm in different groups (* $p < 0.05$, *** $p < 0.001$, and **** $p < 0.0001$)

more, statistical analysis indicated higher recovery rates of sperm viability and normal morphology in the treatment (busulfan+edaravone) group than the busulfan group ($p < 0.05$) (Figures 1C and 1D).

It is worth mentioning that there were no significant differences between the control and edaravone groups in terms of sperm count, motility, viability, and morphology (Figures 1A, 1B, 1C, and 1D).

Sperm chromatin assessment: Evaluation of DFI showed that the percentage of sperm DNA fragmentation in busulfan and busulfan+edaravone groups was increased when compared to the control ($p < 0.0001$) and edaravone ($p < 0.0001$) groups (Figure 2A), but there was no significant difference between the busulfan and busulfan+edaravone groups (Figure 2A). Our results revealed a considerable increase in the percentage of sperm with immature chromatin in the busulfan group as compared to other groups ($p < 0.0001$) (Figure 2B). The percentage of sperm with immature chromatin also showed a higher recovery rate of the treatment group than the busulfan group. There was no significant difference between the busulfan+edaravone and the control groups (Figure 2B).

In terms of DFI and sperm with immature chromatin, no significant difference was noted between the control and edaravone groups (Figures

2A and 2B).

Hormonal assessment: Hormone assay showed that the treatment by edaravone had a significant impact on serum testosterone level in mice induced azoospermia by busulfan. Our result indicated that the serum testosterone level in the busulfan group was significantly decreased compared to other groups ($p < 0.0001$). Interestingly, the serum testosterone level in the busulfan+edaravone group was remarkably higher than the one in the busulfan and control groups ($p < 0.0001$ and $p < 0.05$, respectively) (Figure 3A). Furthermore, there was no significant difference between the edaravone group and the busulfan+edaravone group (Figure 3A). Our findings indicated that the serum FSH level in the treatment group (busulfan+edaravone) was significantly higher than the one in other groups (Figure 3B). Busulfan could slightly decrease the serum FSH level compared to control and edaravone groups, but the difference was not statistically significant (Figure 3B). Our results also showed that the serum level of LH was not significantly different between the study groups (Figure 3C).

Stereological parameters: The testis weight in busulfan injected mice was significantly decreased compared to other groups (Figure 4A). Statistical analysis revealed that the testis weight in the busulfan+edaravone group was significantly

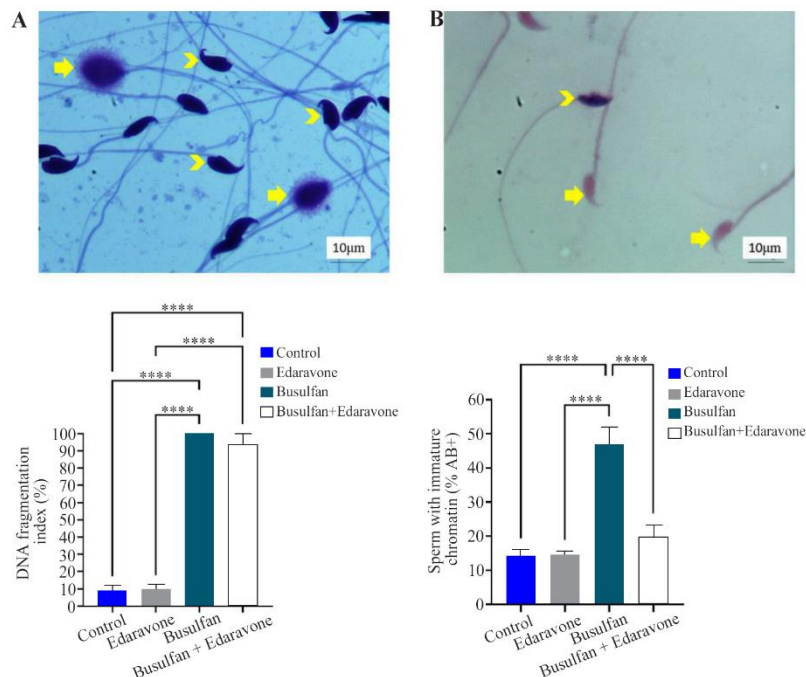


Figure 2. A) Photomicrograph of the DNA fragmentation index and sperm chromatin maturation, 100X. Sperm DNA fragmentation (arrowhead) and, healthy sperm (arrow), and B) Mature chromatin (arrow) and immature chromatin (arrowhead). Mean \pm SD of the percentage of sperm DNA fragmentation and sperm with immature chromatin in the study groups (**** $p < 0.0001$)

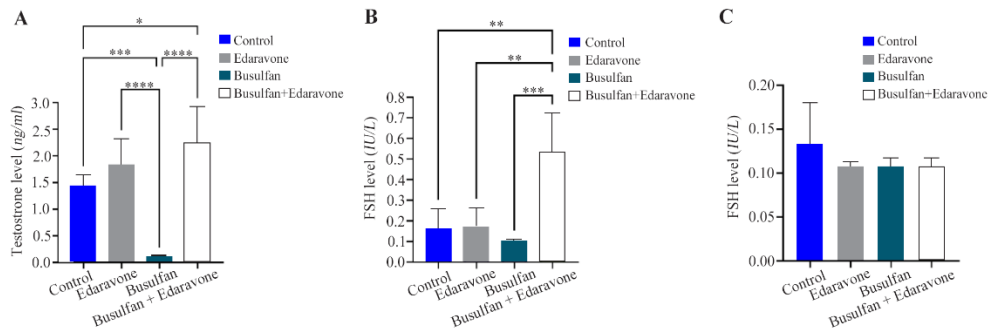


Figure 3. A-C) The effect of edaravone on serum testosterone, FSH, and, LH levels in the testis of busulfan-induced mice. Mean±SD of the serum testosterone, FSH, and LH levels in different groups (* p<0.05, ** p<0.01, *** p<0.001, and **** p<0.0001)

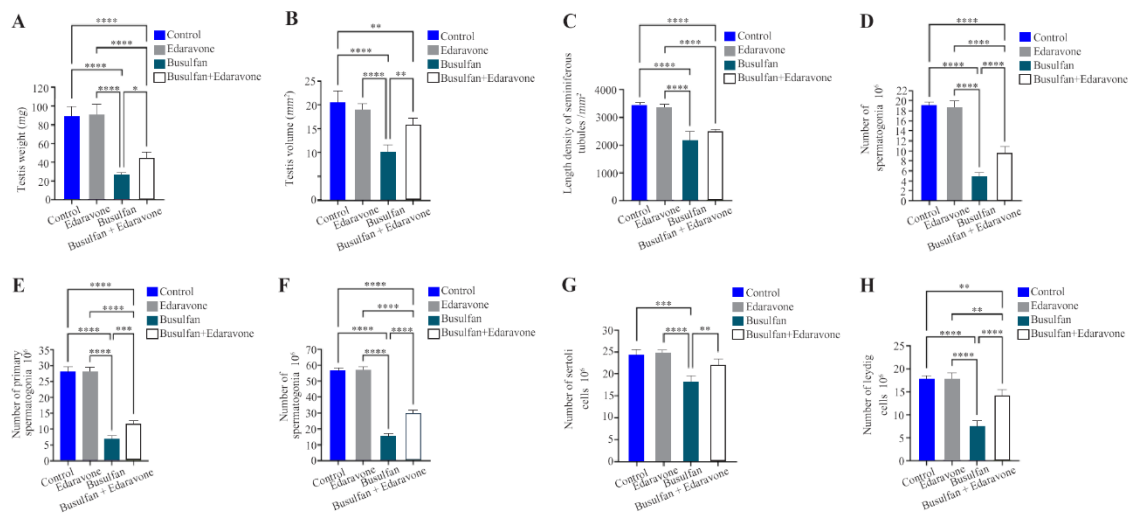


Figure 4. A-H) The effect of edaravone on testis weight and stereological parameters in the testis of busulfan-induced mice. Mean±SD of the testis weight and stereological parameters in different groups (** p<0.05, *** p<0.001, and **** p<0.0001)

lower than control (p<0.0001) and edaravone (p<0.0001) groups (Figures 4A, 5, and 6). The testis weight also showed a higher recovery rate in the treatment (busulfan+edaravone) group compared with the busulfan group (p<0.05) (Figures 4A, 5, and 6). Our results confirmed that the total volume of testis in the busulfan group was significantly lower than the one in other groups (Figures 4B, 5, and 6). Treatment with edaravone (busulfan+edaravone) increased the testis volume significantly in busulfan-induced mice (p<0.01), bringing it to the level of the edaravone group. However, there was still a significant difference between the busulfan+edaravone and control groups (p<0.01) (Figure 4B, 5, and 6). The length density of seminiferous tubules in the busulfan group and busulfan+edaravone group had been significantly

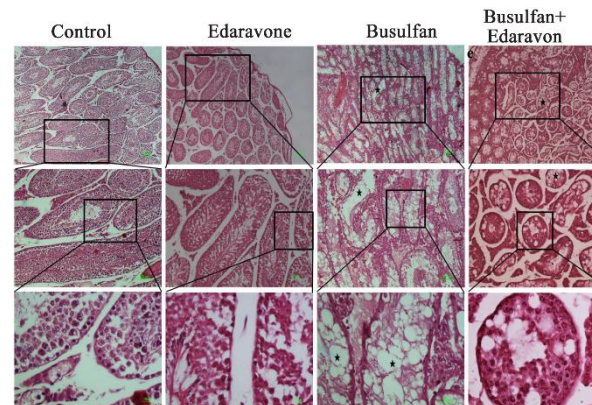


Figure 5. The effect of edaravone on the total number of spermatogenic cells in busulfan-induced mice. Photomicrograph of seminiferous tubules stained with H&E (4X, 10X, and 40X, respectively) in different groups. Empty seminiferous tubule (star)

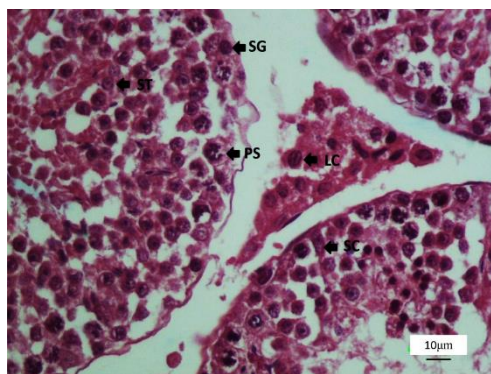


Figure 6. Photomicrograph of the testis stained with H&E, 40X. SG (spermatogonia), PS (primary spermatocyte), ST (round spermatid), SC (sertoli cell), and LC (leydig cell)

decreased when compared to the control ($p < 0.0001$) and edaravone ($p < 0.0001$) groups (Figure 4C, 5, and 6). Furthermore, the treatment with edaravone (busulfan+edaravone group) resulted in a slight increase in the length density of seminiferous tubules in busulfan-induced mice, but this increase was not statistically significant (Figures 4C, 5, and 6).

Our data showed a significant decrease in the number of spermatogonia, primary spermatocytes, and round spermatids in the busulfan group compared to other groups (Figures 4D-F, 5, and 6). Compared to the busulfan group, treatment with edaravone (busulfan+edaravone group) significantly increased the number of spermatogonia ($p < 0.0001$), primary spermatocytes ($p < 0.001$), and round spermatids ($p < 0.0001$) (Figures 4D-F, 5, and 6). Despite the increase in the number of the above mentioned cells, there was still a significant difference between the busulfan+edaravone group compared to control ($p < 0.0001$) and edaravone ($p < 0.0001$) groups (Figures 4D-F, 5, and 6).

According to our results, the number of Sertoli cells had been remarkably decreased in busulfan treated mice compared to other groups (Figure 4G, 5, and 6). Interestingly, when busulfan-induced animals were treated with edaravone, the total number of Sertoli cells increased significantly ($p < 0.01$) and reached its level in the control and edaravone groups (Figure 4G, 5, and 6). In addition, stereological results regarding the number of Leydig cells showed a significant decrease in busulfan compared to other groups ($p < 0.0001$) (Figure 4H, 5, and 6). Despite a significant increase in the number of Leydig cells in the busulfan-induced azoospermia when treated with edaravone ($p < 0.0001$), the increase could not reach

the same level in the control and edaravone groups ($p < 0.01$) (Figure 4H, 5, and 6).

Our findings also indicated that none of the stereological parameters listed above was statistically different between the control and edaravone groups ($p > 0.05$) (Figure 4, 5, and 6).

ROS production: The ROS production level in the testis tissue was measured, and the data showed a significant increase in ROS level in the busulfan group compared to other groups ($p < 0.0001$) (Figure 7A). Although edaravone therapy significantly reduced ROS generation in busulfan-induced azoospermia ($p < 0.0001$), it was not the same in the control group ($p < 0.0001$) and the edaravone group ($p < 0.0001$) (Figure 7A). The data also showed that the ROS level in the control group was not significantly different from the edaravone group (Figure 7A).

Thiols metabolism: Glutathione (GSH) levels were determined in testis tissue and found to be significantly lower in busulfan-treated mice as compared to other groups (Figure 7B). In addition, our data indicated that treatment with edaravone in busulfan-induced azoospermia (busulfan+edaravone) significantly increased the GSH level in the testis tissue when compared to the busulfan group ($p < 0.001$). However, despite this improvement, edaravone (edaravone+busulfan) was unable to restore the GSH level to that of the control group ($p < 0.05$) (Figure 7B).

Real-time PCR analysis: The mRNA expression of one gene involved in apoptosis (caspase-3) and two genes involved in autophagy (Beclin-1 and ATG-7) was examined in testis tissue. According to our results, the transcript of caspase-3 as apoptotic markers had been remarkably increased in busulfan induced mice compared to other groups (Figure 7C). Interestingly, treatment with edaravone in the busulfan+edaravone group significantly increased caspase-3 mRNA expression, restoring it to the level seen in the control and edaravone groups (Figure 7C). Furthermore, our results indicated that Beclin-1 mRNA expression in the busulfan group was considerably higher than the one in the other groups (Figure 7D). Moreover, when treated with edaravone, the busulfan-treated animals exhibited a significant reduction in Beclin-1 gene expression ($p < 0.01$), restoring it to the level seen in the control and edaravone groups (Figure 7D). ATG-7 mRNA expression was also substantially increased in busulfan-induced mice when compared to the control ($p < 0.0001$), edara-

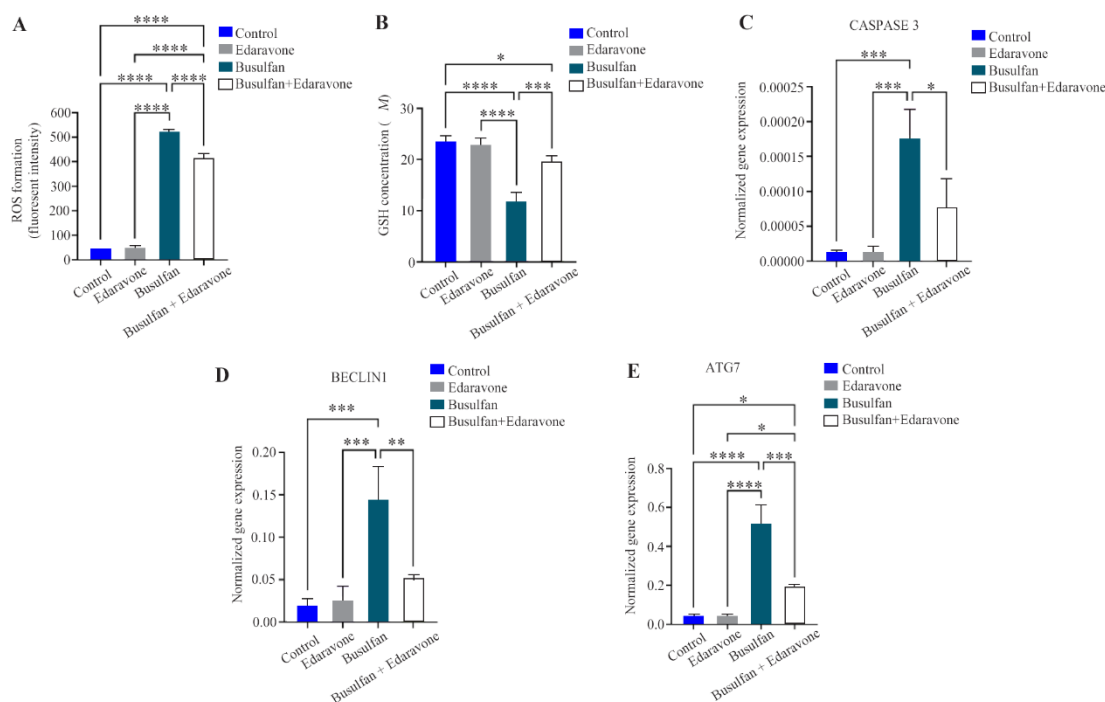


Figure 7. The effect of edaravone on reactive oxygen species (ROS) production, glutathione (GSH) levels, and mRNA expression levels of caspase-3, Beclin-1, and ATG-7 in testis of busulfan-induced mice. Mean±SD of the ROS production, GPX activity, and mRNA expression levels of caspase-3, Beclin-1, and ATG-7 in the study groups (* p<0.05, ** p<0.01, *** p<0.001 and **** p<0.0001)

vone (p<0.0001), and busulfan+edaravone (p<0.001) groups (Figure 7E). Although edaravone therapy significantly decreased the level of ATG7 mRNA in busulfan-induced animals (p<0.001), it could not restore it to the values seen in the control and edaravone groups (p<0.05) (Figure 7E).

Discussion

The results of the present study suggest that edaravone could ameliorate semen quality and quantity, especially in the mice induced by busulfan. Our histological results confirmed that busulfan caused testicular damage, which led to decreased testicular weight and alteration in sperm morphology, sperm count, sperm motility, sperm viability, and disruptions of antioxidative enzymes and hormones compared to the control group. Previous reports back up our findings, clearly demonstrating that the use of busulfan results in depletion of germ cells and interruption of spermatogenesis in male mice (1).

The reduction in testis volume in the present study is due to the marked atrophy of the seminiferous tubules, along with the decreased total number of spermatogenic, Leydig and Sertoli cells

observed in busulfan-treated mice. The current study indicated that exposure to busulfan induced testicular damage, which led to a significant decrease in serum testosterone levels of busulfan-treated mice. This hormonal alteration occurs because testosterone production is dependent on the endocrine function of the interstitial cells. In addition, exposure to busulfan amplifies intracellular ROS production. Overproduction of reactive substances stimulates DNA fragmentation, depletion of germ cells, and impairs functions of Leydig and Sertoli cells. In this study, the inactivation of antioxidant enzymes caused by the unrestrained production of ROS can explain the reduction noted in antioxidant enzyme activity (9). In the present study, it was shown that edaravone treatment markedly improved the above-noted parameters and protected testicular tissues against the adverse consequences of exposure to busulfan. Therefore, it can be concluded that edaravone regulates cell mitosis and meiosis of germ cells and reduces oxidative and nitrosative stresses (15). Furthermore, Tamamura et al. reported that edaravone ameliorated the ischemia-reperfusion injury-induced testicular damage through its ability to scavenge free

radicals in rat testes (23). Edaravone has many functions including scavenging free radicals such as O_2 and SOH and alleviating the damage induced to the mitochondrial membrane by chelating agents (24). Tsounapi et al. also demonstrated the effectiveness of edaravone in reducing oxidative stress and apoptosis in testicular tissue in diabetic rats (15).

In the present study, GSH levels were seen to drop in the busulfan group. However, treatment with edaravone increased these concentrations in the testes. In the busulfan group, reduced levels of GSH in testis tissues were noted. Decreased activity of GSH as scavengers of H_2O_2 may be attributed to excessive production of ROS, which results in excessive intake of antioxidant enzymes or a disturbance of antioxidant enzyme synthesis (25). In the present study, edaravone treatment resulted in a significant reduction in ROS level and an increase in GSH level in busulfan-induced mice. Consistent with our results, it has been reported that edaravone preserved coronary microvascular endothelial function, increased nitric oxide (NO), and decreased ROS in dogs with ischemia/reperfusion injury (26). Similar results were also found in multiple tissues, including heart, lungs (27), liver (28), kidney (16), and brain tissue (29), where treatment with edaravone prevented the decrease in glutathione activity and inhibition of mitochondrial lipid peroxidation through scavenging free radicals. Edaravone may protect against DNA damage by reducing hydroxyl radicals in the testes. In the current study, it was also shown that the gene expression of caspase-3 in the testes of the busulfan group was significantly higher than the one in controls and that treatment with edaravone significantly reduced caspase-3 gene expression. Treatment with edaravone has been shown to alleviate several diseases due to its anti-apoptotic properties, which is achieved through modulating mitochondrial Bcl-xL and Bax (30-32). It was found that busulfan is capable enough to induce cell death (33). Qiao et al. reported that edaravone inhibited the activation of the mitochondrial apoptosis pathway by increasing the expressions of Bcl-2 and inhibiting the expressions of Bax and caspase-3 (33). The aggregation of ROS could bring about defects in homeostasis, resulting in oxidative stress and mitochondrial dysfunction, and induced autophagy. Beclin-1 and ATG-7 genes also play important roles at different stages of the autophagic process (34, 35). This study revealed that mRNA expression of Beclin-1

and ATG-7 in the busulfan group was significantly higher than that in the treatment edaravone group. The overexpression of ATG-1 and Beclin-1 sufficed to increase the overall rate of autophagy in the busulfan group. It seems that busulfan could activate destructive factors generated in testis tissues like hypoxia, oxidative stress, and aberrant hormone secretion and finally activate autophagy. In this study, edaravone normalized the production of oxidative stress and it was saved from the autophagy defect by restoring the oxidative stress state (36).

Conclusion

In conclusion, this study showed that edaravone significantly restored the busulfan-induced structural alterations in the testicular tissue. This protective effect could be linked to the antioxidant properties and increased activity of the antioxidant defense systems of edaravone. This study revealed that edaravone may be a valuable protective agent due to its antioxidant properties although its potential to approximate the sperm parameters to the level in the control groups was not satisfactory enough; therefore, further experiments are needed to validate this association. Due to the lack of information on the properties of edaravone, further studies must be performed to better understand the effects of edaravone on reproductive organs.

Acknowledgement

This work has been performed at the Department of Biology and Anatomical Sciences, School of Medicine, Shahid Beheshti University of Medical Science, Tehran, Iran. This study was financially supported by Men's Health and Reproductive Health Research Center, Shahid Beheshti University of Medical Sciences, Tehran, Iran (Registration number: 27615).

Funding: This study was financially supported by Infertility and Reproductive Health Research Center, Shahid Beheshti University of Medical Sciences, Tehran, Iran (Registration number: 27615).

Conflict of Interest

The authors declare that they have no conflict of interests.

References

1. Ziaei-pour S, Rezaei F, Piryaei A, Abdi S, Moradi A, Ghasemi A, et al. Hyperthermia versus busulfan:

- Finding the effective method in animal model of azoospermia induction. *Andrologia*. 2019;51(11): e13438.
2. Panahi S, Karamian A, Sajadi E, Alighaei A, Nazarian H, Abdi S, et al. Sertoli cell-conditioned medium restores spermatogenesis in azoospermic mouse testis. *Cell Tissue Res*. 2020;379(3):577-87.
 3. Caroppo E, Colpi GM. Hormonal treatment of men with nonobstructive azoospermia: what does the evidence suggest? *J Clin Med*. 2021;10(3):387.
 4. Schlegel PN, Sigman M, Collura B, De Jonge CJ, Eisenberg ML, Lamb DJ, et al. Diagnosis and treatment of infertility in men: AUA/ASRM guideline part II. *Fertil Steril*. 2021;115(1):62-9.
 5. Zhang HL, Zhao LM, Mao JM, Liu DF, Tang WH, Lin HC, et al. Sperm retrieval rates and clinical outcomes for patients with different causes of azoospermia who undergo microdissection testicular sperm extraction-intracytoplasmic sperm injection. *Asian J Androl*. 2021;23(1):59-63.
 6. Zhankina R, Baghban N, Askarov M, Saipiyeva D, Ibragimov A, Kadirova B, et al. Mesenchymal stromal/stem cells and their exosomes for restoration of spermatogenesis in non-obstructive azoospermia: a systemic review. *Stem Cell Res Ther*. 2021;12(1): 229.
 7. Barati E, Nikzad H, Karimian M. Oxidative stress and male infertility: current knowledge of pathophysiology and role of antioxidant therapy in disease management. *Cell Mol Life Sci*. 2020;77(1): 93-113.
 8. Dutta S, Henkel R, Sengupta P, Agarwal A. Physiological role of ROS in sperm function. In: Parekattil SJ, Esteves SC, Agarwal A, editors. *Male Infertility*. Switzerland: Springer, Cham; 2020. p. 337-45.
 9. Sanocka D, Kurpisz M. Reactive oxygen species and sperm cells. *Reprod Biol Endocrinol*. 2004;2:12.
 10. Tanaka M. [Pharmacological and clinical profile of the free radical scavenger edaravone as a neuroprotective agent]. *Nihon Yakurigaku Zasshi*. 2002; 119(5):301-8. Japanese.
 11. Ismail H, Shakkour Z, Tabet M, Abdelhady S, Kobaisi A, Abedi R, et al. Traumatic brain injury: Oxidative stress and novel anti-oxidants such as Mitoquinone and Edaravone. *Antioxidants (Basel)*. 2020;9(10):943.
 12. Chen H, Chen Y, Wang X, Yang J, Huang C. Edaravone attenuates myocyte apoptosis through the JAK2/STAT3 pathway in acute myocardial infarction. *Free Radic Res*. 2020;54(5):351-9.
 13. Kassab AA, Aboregela AM, Shalaby AM. Edaravone attenuates lung injury in a hind limb ischemia-reperfusion rat model: a histological, immunohistochemical and biochemical study. *Ann Anat*. 2020;228:151433.
 14. Ommati MM, Attari H, Siavashpour A, Shafaghat M, Azarpira N, Ghaffari H, et al. Mitigation of cholestasis-associated hepatic and renal injury by edaravone treatment: evaluation of its effects on oxidative stress and mitochondrial function. *Liver Res*. 2021;5(3):181-93.
 15. Tsounapi P, Saito M, Dimitriadis F, Koukos S, Shimizu S, Satoh K, et al. Antioxidant treatment with edaravone or taurine ameliorates diabetes-induced testicular dysfunction in the rat. *Mol Cell Biochem*. 2012;369(1-2):195-204.
 16. Zhao X, Zhang E, Ren X, Bai X, Wang D, Bai L, et al. Edaravone alleviates cell apoptosis and mitochondrial injury in ischemia-reperfusion-induced kidney injury via the JAK/STAT pathway. *Biol Res*. 2020;53(1):28.
 17. Wang B, Lin W. Edaravone protects against pancreatic and intestinal injury after acute pancreatitis via nuclear factor- κ B signaling in mice. *Biol Pharm Bull*. 2020;43(3):509-15.
 18. Yalcin Comert HS, Imamoglu M, Ercin ME, Eksi E, Kandaz M, Alver A, et al. Effect of edaravone on lungs and small intestine in rats with induced radiotherapy. *Indian J Exp Biol*. 2021;59:162-7.
 19. Zarei L, Sadrkhanlou R, Shahrooz R, Malekinejad H, Eilkhani Zadeh B, Ahmadi A. Protective effects of vitamin E and Cornus mas fruit extract on methotrexate-induced cytotoxicity in sperms of adult mice. *Vet Res Forum*. 2014;5(1):21-7.
 20. Fernández JL, Muriel L, Goyanes V, Segrelles E, Gosálvez J, Enciso M, et al. Simple determination of human sperm DNA fragmentation with an improved sperm chromatin dispersion test. *Fertil Steril*. 2005;84(4):833-42.
 21. Ziaiepour S, Ahrabi B, Naserzadeh P, Alighaei A, Sajadi E, Abbaszadeh H-A, et al. Effects of sertoli cell transplantation on spermatogenesis in azoospermic mice. *Cell Physiol Biochem*. 2019;52(3): 421-34.
 22. Ayoubi M, Naserzadeh P, Hashemi MT, Rostami MR, Tamjid E, Tavakoli MM, et al. Biochemical mechanisms of dose-dependent cytotoxicity and ROS-mediated apoptosis induced by lead sulfide/graphene oxide quantum dots for potential bioimaging applications. *Sci Rep*. 2017;7(1):12896.
 23. Tamamura M, Saito M, Kinoshita Y, Shimizu S, Satoh I, Shomori K, et al. Protective effect of edaravone, a free-radical scavenger, on ischemia-reperfusion injury in the rat testis. *BJU Int*. 2010;105(6):870-6.

24. Homma T, Kobayashi S, Sato H, Fujii J. Edaravone, a free radical scavenger, protects against ferroptotic cell death in vitro. *Exp Cell Res*. 2019; 384(1):111592.
25. Zhang J, Wang X, Vikash V, Ye Q, Wu D, Liu Y, et al. ROS and ROS-mediated cellular signaling. *Oxid Med Cell Longev*. 2016;2016:4350965.
26. Sukmawan R, Yada T, Toyota E, Neishi Y, Kume T, Shinozaki Y, et al. Edaravone preserves coronary microvascular endothelial function after ischemia/reperfusion on the beating canine heart in vivo. *J Pharm Sci*. 2007;104(4):341-8.
27. Ito K, Ozasa H, Horikawa S. Edaravone protects against lung injury induced by intestinal ischemia/reperfusion in rat. *Free Radic Biol Med*. 2005; 38(3):369-74.
28. Hayashi C, Ito M, Ito R, Murakumo A, Yamamoto N, Hiramatsu N, et al. Effects of edaravone, a radical scavenger, on hepatocyte transplantation. *J Hepatobiliary Pancreat Sci*. 2014;21(12):919-24.
29. Shichinohe H, Kuroda S, Yasuda H, Ishikawa T, Iwai M, Horiuchi M, et al. Neuroprotective effects of the free radical scavenger Edaravone (MCI-186) in mice permanent focal brain ischemia. *Brain Res*. 2004;1029(2):200-6.
30. Zhao ZY, Luan P, Huang SX, Xiao SH, Zhao J, Zhang B, et al. Edaravone Protects HT22 Neurons from H₂O₂-induced Apoptosis by Inhibiting the MAPK Signaling Pathway. *CNS Neurosci Ther*. 2013;19(3):163-9.
31. Li Y, Liu H, Zeng W, Wei J. Edaravone protects against hyperosmolarity-induced oxidative stress and apoptosis in primary human corneal epithelial cells. *PLoS One*. 2017;12(3):e0174437.
32. Shimazaki H, Watanabe K, Veeraveedu PT, Harima M, Thandavarayan RA, Arozal W, et al. The antioxidant edaravone attenuates ER-stress-mediated cardiac apoptosis and dysfunction in rats with autoimmune myocarditis. *Free Radical Res*. 2010; 44(9):1082-90.
33. Qiao J, Wu Y, Liu Y, Li X, Wu X, Liu N, et al. Busulfan triggers intrinsic mitochondrial-dependent platelet apoptosis independent of platelet activation. *Biol Blood Marrow Transplant*. 2016;22(9):1565-72.
34. Cao Y, Klionsky DJ. Physiological functions of Atg6/Beclin 1: a unique autophagy-related protein. *Cell Res*. 2007;17(10):839-49.
35. Wirawan E, Lippens S, Vanden Berghe T, Romagnoli A, Fimia GM, Piacentini M, et al. Beclin1: a role in membrane dynamics and beyond. *Autophagy*. 2012;8(1):6-17.
36. Yin J, Zhou Z, Chen J, Wang Q, Tang P, Ding Q, et al. Edaravone inhibits autophagy after neuronal oxygen-glucose deprivation/recovery injury. *Int J Neurosci*. 2019;129(5):501-10.