



Persistent Mullerian Duct Syndrome: A Rare Case of an Adult Infertile Male with Bilateral Cryptorchidism

Prakash Sankapal, Venkat Arjun Gite *, Mayank Agrawal, Mahesh Sane, Atul Singal

- Department of Urology, Grant Government Medical College and Sir JJ Hospital, Mumbai, India

Abstract

Background: Persistent mullerian duct syndrome (PMDS) is a very rare form of internal male pseudohermaphroditism in individuals who are phenotypically males with 46 XY karyotypes harboring internal female reproductive organs which are Mullerian derivatives. It occurs as a defect in the genes coding for the Mullerian inhibiting substance (MIS) or the anti Mullerian hormone (AMH) receptor, ultimately leading to failure of regression of Mullerian ducts.

Case Presentation: A 29-year-old male with PMDS presented with complaints of primary infertility. Diagnosis was made with the help of high index of suspicion, radiological imaging, and karyotyping. Our patient underwent exploratory laparotomy with hysterectomy and bilateral orchidopexy.

Conclusion: The purpose of this study was increasing awareness regarding rare entities and surgeons should have high clinical suspicion of PMDS when patient with bilateral undescended testis comes for the evaluation of primary infertility.

Keywords: Anti Mullerian hormone (AMH), Cryptorchidism, Hysterectomy, Karyotyping, Mullerian inhibiting substance (MIS), Orchidopexy, Persistent mullerian duct syndrome (PMDS), Primary infertility.

To cite this article: Sankapal P, Gite VA, Agrawal M, Sane M, Singal A. Persistent Mullerian Duct Syndrome: A Rare Case of an Adult Infertile Male with Bilateral Cryptorchidism. *J Reprod Infertil.* 2021;22(3):216-219. <http://dx.doi.org/10.18502/jri.v22i3.6722>.

* Corresponding Author:
Venkat Arjun Gite, Swastik Building No 4, House No 6, Grant Medical College and Sir JJ Hospital, Mumbai (400008), India
E-mail:
balajigite@yahoo.com

Received: Apr. 15, 2020
Accepted: Sept. 19, 2020

Introduction

Persistent mullerian duct syndrome (PMDS) is a very rare condition with nearly 150 cases described in the literature (1). This rare entity shows adolescents who are phenotypically males with 46 XY karyotypes harboring internal female reproductive organs which are Mullerian derivatives, rendered by a defect in either genes coding for the Mullerian inhibiting substance (MIS) or the anti Mullerian hormone (AMH) receptor, ultimately leading to failure of regression of Mullerian ducts (2).

PMDS is often misdiagnosed due to a lack of familiarity with the condition. This case is presented to stress the intraoperative diagnosis of this condition resulted from a high index of suspicion by operating surgeon and due to rarity of its occurrence.

Case Presentation

A 29-year-old male married for the last two years presented with complaints of primary infertility at Sir JJ Hospital, Mumbai, India in January 2019 despite consummative marriage. On clinical examination, he was phenotypically male with bilateral undescended testis which was previously undiagnosed. He had a normally developed penis, normal in length and width. On evaluation, he had azoospermia on semen analysis. On ultrasonography, he had bilateral undescended testes with right testicle in intra-abdominal location and the left near the deep inguinal ring. Hormonal evaluation showed LH of 19.51 IU/L (Normal), FSH of 41.81 IU/L (Raised), prolactin of 6.21 mIU/L (Normal), and testosterone of 384 ng/dL (Normal).

Left orchidopexy was done for him. During the

surgery, a uterus like structure attached to the left gonad was seen; hence, the procedure was abandoned, and patient was subjected to further evaluation. Left gonad biopsy was taken which showed testicular maturation arrest.

In postoperative period, MRI of the abdomen and pelvis showed right intra-abdominal testis superomedial to bladder and left testis in the left iliac fossa with uterus like structure of size $6 \times 2.4 \times 2$ cm with left fallopian tube which was herniating to the left inguinal canal. Uterus continuing as cervix and upper vagina in the pelvic region was found (Figure 1). There was a calculus in ejaculatory duct/seminal vesicle. He underwent karyotyping which showed male 46 XY genotype and his AMH was low, ie 0.730 (2-16.5 ng/ml). The karyotype was not done prior to the first surgery as there was no clinical feature or radiological investigations which could suggest PMDS.

In his second surgery, the patient underwent exploratory laparotomy with hysterectomy and bilateral orchidopexy (Figures 2-5) (Fowler-Stephens orchidopexy on right side with testicular biopsy and conventional orchidopexy on the left side). After 3 months of follow up, on clinical examination and Doppler ultrasound, his both testes were in scrotal sac and viable.

Discussion

PMDS is a rare form of internal male pseudohermaphroditism, in which uterus and fallopian tubes are present in a normal male 46 XY karyotype. Two factors are at least needed, testosterone and MIF or AMH produced by the testes, to have a normal male sexual differentiation. The latter is

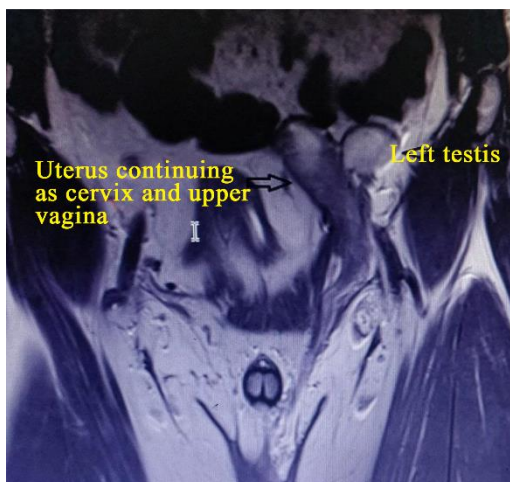


Figure 1. Pelvis coronal view by MRI showing the left testis with uterus continuing as cervix and upper vagina

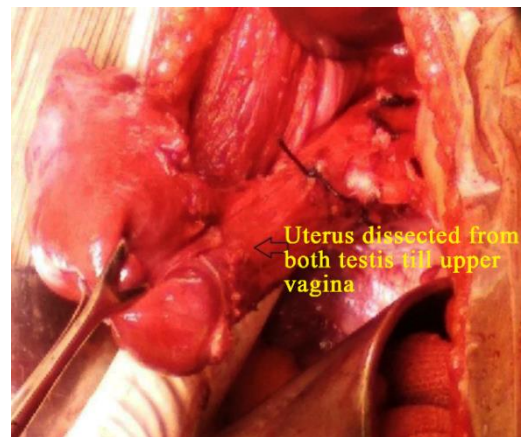


Figure 2. Intraoperative image showing dissected uterus from both testicles till upper vagina

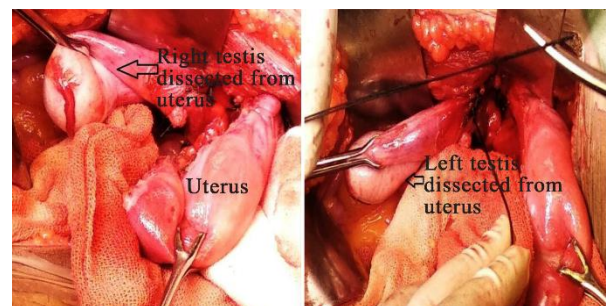


Figure 3. Intraoperative image showing dissected right and left testis from uterus

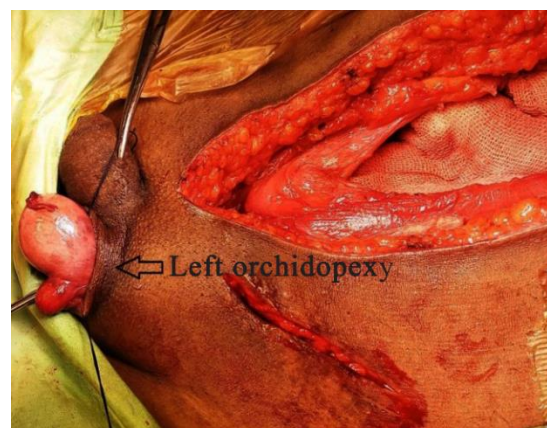

Figure 4. Intraoperative image showing left orchidopexy

responsible for regression of the Mullerian structures in the male fetus. Therefore, in the absence of MIF, the Mullerian duct differentiates into the fallopian tubes, uterus, and upper vagina. AMH does not have a direct role in the descent of the testis, but in case of bilateral abdominal testis,

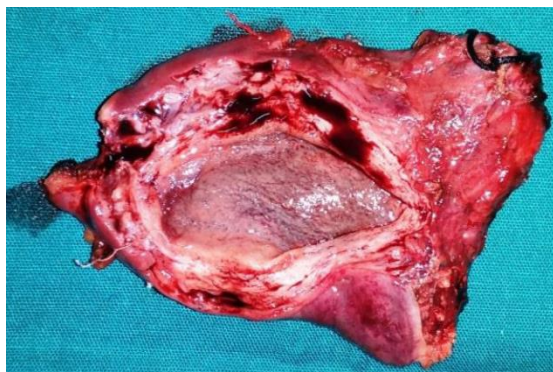


Figure 5. Uterus specimen

Mullerian remnants prevent the mobilization of the testes. The human gene for AMH has been mapped on chromosome 19 (2).

The proposed etiology for PMDS is deficiency of AMH, *ie* abnormality in its receptor or failure to produce AMH before the 8th gestational week (3). The genetic mode of transmission is considered heterogeneous and consanguinity in some cases. The occurrence of PMDS in several pairs of brothers suggests autosomal recessive, male restricted transmission (4).

Without a high index of suspicion, PMDS is usually an unexpected finding at surgery (5). Anatomically, PMDS cases are divided into three categories.

Type I (Male type) in 60-80% of cases: Testis is present in the scrotum/in the inguinal canal and can be brought into scrotum by gentle traction with bilateral intra-abdominal testes in apposition analogous to ovaries.

Type II (Male type) in 20-30% of cases: Transverse testicular ectopia occurs as a rare congenital anomaly.

Type III (Female type) in 10%-20% of cases: Bilateral cryptorchidism occurs when testis is present at ovarian position with respect to the uterus and is fixed in the pelvis (6).

PMDS type III was detected in this study, which is an exceedingly rare clinical presentation.

In the management of young children with undescended testis, serum AMH measurement can be beneficial in accessing the gonadal function, reflecting the normal development of male genitals. A measurable AMH in a boy who presented with bilateral cryptorchidism is predictive of undescended testis, while undetected AMH is suggestive of anorchia or the presence of ovaries as in cases of pure gonadal dysgenesis or female pseu-

dohermaphroditism (3). In our case, AMH test was done in the postoperative period which manifested low levels.

There are reported cases of PMDS in association with testicular tumors, although the incidence of malignant transformation in these patients is like the rate in abdominal testis in otherwise normal men. However, our case did not show any dysplastic changes or malignancy on biopsy. Virilization generally remains unaffected, but infertility is common because most patients have azoospermia, which was seen in our case (7).

Diagnosing PMDS is based on a combination of anatomic and clinical findings. Imaging features, although classic, are often missed (3, 5). Ultrasound scan failed to identify the internal structures as in our case. However, when availability and affordability are not an issue, computed tomography (CT) and magnetic resonance imaging (MRI) are known to show the tubular structures clearly (4). Ideally, this diagnosis should be combined with karyotyping like the procedure done in our study.

The condition is usually detected during the evaluation for undescended testis, infertility or during the surgery for other intra-abdominal conditions. Laparoscopy is especially useful in such cases as it is diagnostic and therapeutic at the same time and offers advantages of minimally invasive approach (8). In our case, open surgical approach was done for the patient.

The testicular biopsy is necessary because usually there is a well reported, cystic structure at the anti-mesenteric side of the testis, making it necessary to differentiate PMDS from an ovotestis (5, 6).

After PMDS is confirmed by karyotyping (46 XY) and testicular histology, the definitive operation is then performed. The surgical management of PMDS is still controversial. Previously, it was advised that there is no need to remove the Mullerian structures (To preserve the vas and its vascularity) but subsequent malignancy of the Mullerian remnant has been reported and so at present, excision of these structures is recommended (6). Complete excision of Mullerian duct remnant can result in damage to the integrity or vascularity of the vas deferens as it is usually found to be intimately adhering to the lateral walls of the uterus, fallopian tubes, and vagina (7). Guerrier et al. suggested that when testes are normal, bilateral proximal salpingectomy, leaving fimbriae with epi-

dymis, corporal hysterectomy and bilateral orchidopexy can be done (4).

However, Manjunath et al. did not find an absolute indication for the removal of Mullerian duct structures. Also, no malignant degeneration of retained Mullerian structures in PMDS has ever been documented (6). In our case, besides hysterectomy, Fowler-Stephen procedure was required to bring right testis down to scrotum suggestive of inability of bringing down the testis without hysterectomy. If the testes are atrophic or cannot be brought down for orchidopexy, orchidectomy alone should be performed (5). The risk of testicular malignancy is similar in PMDS and cryptorchidism, nearly 5 to 18% (9).

In such cases, either bilateral orchidopexy/orchiectomy or ipsilateral orchiectomy with contralateral orchidopexy should be done. This decision should be made based upon the age of the patient, HCG (Human chorionic gonadotropin) stimulation result, and gonad histology (7).

Conclusion

It seems that surgeons should have high clinical suspicion of PMDS when patient with bilateral undescended testis comes for the evaluation of primary infertility. Moreover, diagnosis is improved by a high index of suspicion, imaging, and karyotyping. The main purpose of this study was increasing awareness among the health care providers of a rare entity. Therefore, the best procedure in such problems is a multi-disciplinary team approach, delineating each problem in such rare cases.

Conflict of Interest

The authors declare that they have no conflict of interest.

References

1. Nerune SM, Hippargi SP, Mestri NB, Mehhrotra NM. Persistent mullerian duct syndrome with ovarian endometriosis - a rare case report. *J Chin Diagn Res.* 2016;10(2):ED14-5.
2. Deepika AK. Persistent mullerian duct syndrome with transverse testicular ectopia: rare entity. *J Clin Diagn Res.* 2014;8(3):162-3.
3. Wuerstle M, Lesser T, Hurwitz R, Applebaum H, Lee SL. Persistent mullerian duct syndrome and transverse testicular ectopia: embryology, presentation, and management. *J Pediatr Surg.* 2007;42(12):2116-9.
4. Guerrier D, Tran D, Vanderwiden JM, Hideux S, Van Outryve L, Legeal L, et al. The persistent mullerian duct syndrome: a molecular approach. *J Clin Endocrinol Metab.* 1989;68(1):46-52.
5. Loeff DS, Imbeaud S, Reyes HM, Meller JL, Rosenthal IM. Surgical and genetic aspects of persistence mullerian duct syndrome. *J Paediatr Surg.* 1994;29(1):61-5.
6. Manjunath BG, Shenoy VG, Raj P. Persistent mullerian duct syndrome: how to deal with the mullerian duct remnants-a review. *Indian J Surg.* 2010;72(1):16-9.
7. Wu HC, Chen JH, Lu HF, Shen WC. Persistent mullerian duct syndrome with seminoma: CT findings. *AJR Am J Roentgenol.* 2000;174(1):102-4.
8. Palanisamy S, Patel ND, Sabnis SC, Palanisamy N, Vijay A, Chinnusamy P. Laparoscopic hysterectomy with bilateral orchidectomy for persistent mullerian duct syndrome with seminoma testes: case report. *J Minim Access Surg.* 2015;11(4):273-5.
9. Gutte AA, Pendharkar PS, Sorte SZ. Transverse testicular ectopia associated with persistent Mullerian duct syndrome-the role of imaging. *Br J Radiol.* 2008;81(967):e176-8.