



Successful Targeted Testicular Sperm Extraction Using Microsurgical Technique (microTESE) Following Fine Needle Aspiration (FNA) Mapping in a Non-Obstructive Azoospermia (NOA) Patient: A Case Report

Ponco Birowo^{1,2*}, William Tendi^{1,2}, Nur Rasyid¹, Paul J Turek³, Ivan Rizal Sini², Muhammad Rizal²

1- Department of Urology, Cipto Mangunkusumo Hospital, Faculty of Medicine Universitas Indonesia, Jakarta, Indonesia

2- Indonesian Reproductive Science Institute, Bunda General Hospital, Jakarta, Indonesia

3- The Turek Clinic, San Francisco, USA

Abstract

Background: Management for male infertility can be difficult for some cases. Surgical intervention has long been thought as the last resort to help married couples to conceive. The current guideline recommends testicular sperm extraction with microsurgery technique (microTESE) in severe cases of male infertility. However, the success rate still varies. Thus, a new strategy was needed to further increase the sperm retrieval success rate.

Case Presentation: A 39-year-old male with a history of failed sperm extraction, non-obstructive azoospermia (NOA) and Y-chromosomal microdeletion came to the fertility center to undergo sperm retrieval. Fine needle aspiration (FNA) Mapping was performed prior to microTESE to increase the accuracy of sperm retrieval. After further examination with laser assisted immotile sperm selection (LAISS), five spermatozoa were found.

Conclusion: The combination of FNA Mapping and microTESE increases the chance of a successful sperm extraction.

Keywords: FNA Mapping, LAISS, microTESE, NOA, Y-chromosomal microdeletion.

To cite this article: Birowo P, Tendi W, Rasyid N, Turek PJ, Sini IR, Rizal M. Successful Targeted Testicular Sperm Extraction Using Microsurgical Technique (microTESE) Following Fine Needle Aspiration (FNA) Mapping in a Non-Obstructive Azoospermia (NOA) Patient: A Case Report. *J Reprod Infertil.* 2021;22(1):65-69. <http://dx.doi.org/10.18502/jri.v22i1.4997>.

* Corresponding Author:
Ponco Birowo, Department
of Urology, Cipto,
Mangunkusumo Hospital,
Faculty of Medicine
Universitas Indonesia,
Jakarta, Indonesia,
Indonesian Reproductive
Science Institute, Bunda
General Hospital, Jakarta,
Indonesia
E-mail:
ponco.birowo@gmail.com

Received: Mar. 27, 2020

Accepted: Jun. 20, 2020

Introduction

Infertility in males has been a bothersome problem for married couples. According to World Health Organization (WHO), infertility is defined as the inability of a sexually active, non-contracepting couple to achieve spontaneous pregnancy in 1 year. Infertility affects approximately 15% of couples worldwide. Among them, the prevalence of azoospermic patients is about 11.2% (1).

Generally, azoospermic patients are divided into two groups of obstructive azoospermia (OA) or non-obstructive azoospermia (NOA). This classification is defined by the etiology of azoospermic semen (2).

While generally the spermatozoa from OA patients without spermatogenic dysfunction can be extracted in surgical manner, management in NOA patients is more challenging.

Recently, there are many techniques available to do sperm extraction. However, most of the procedures extract the sperm by blindly obtaining samples from the testes. Therefore, the chance of a successful sperm retrieval in NOA patients is greatly varied. It ranges from as low as 21.6% to as high as 94% depending on the nature of the disease (3). Recent meta-analysis suggests the best method for sperm retrieval with the highest success rate is the testicular sperm extraction using

microsurgery technique (microTESE). The study stated that microTESE was 1.5 times more likely to find sperm when compared to conventional TESE. Furthermore, one of the most concerning complications of conventional TESE was testicular injury, in which microTESE technique had more advantage by causing less damage to the testicular tissue than conventional TESE (4).

One of many factors affecting male infertility is microdeletion of Y-chromosome. This particular chromosome contains an area that has an impact on spermatogenesis called the azoospermia factor (AZF). Currently, there are three major regions of AZF that have been identified to cause spermatogenesis impairment. These are called AZFa, AZFb, and AZFc. Among these, it is believed that complete deletion in AZFa leads to severe azoospermia and Sertoli cell-only syndrome. Sperm extraction is only recommended in patients with partial AZFb deletion or AZFc deletion (5).

Deletion of AZF can be detected by using two multiplex Polymerase Chain Reactions (PCR) in which each reaction contains one locus of each AZF region. Deletion of the AZF is determined by the absence of primers based on the region. The AZFa primers are sY84 and sY86, AZFb primers are sY127 and sY134, while AZFc primers are sY255 and sY254 (6).

A "guiding" procedure, called Fine Needle Aspiration (FNA) Mapping, was introduced to help clinicians determine more accurately the site of extraction on the testes with minimal complications such as hematoma and painless hematospermia that resolve in one week. This procedure includes a systematic sampling of both testes in a three-dimensional manner by using a 23G fine needle (7). The result of these samples then can be used to guide the surgeon about the time to perform sperm extraction and increase the likelihood of a successful sperm retrieval. Furthermore, a study conducted by Ma et al. even recommended FNA Mapping to be used directly as a manner of sperm retrieval in patients with age of 35 years old or more, low Follicle-Stimulating Hormone (FSH) value, and large testicular volume. Otherwise, the chance of retrieval failure was high and microTESE without FNA Mapping was preferred (8).

Aside from the surgical technique, the method of finding viable sperm also plays important role in a successful sperm retrieval especially in difficult cases. Recently, a novel technique called laser-

assisted immotile sperm selection (LAISS) was developed to further identify the viability of the immotile spermatozoa. The procedure includes applying a single laser shot of 129 μ J for about 1.2 msec to the tip of flagellum of the spermatozoon (Figure 1). The spermatozoon is then considered viable when its tail is coiled after the laser shot (9).

Although the FNA Mapping of the testes has been described for 23 years since 1997, the value of the technique in sperm extraction was only recognized in 2011, while the combination with microTESE was performed recently in 2019 (7, 10) This case presented a successful microTESE performed under the guidance of FNA Mapping which was confirmed by the LAISS procedure after a previously failed sperm extraction with NOA and Y-chromosomal microdeletion. The aim of this study was to show the possibility of increasing success rate of microTESE with a prior FNA Mapping.

Case Presentation

A 39-year-old male came to our clinic on 4th October 2018 complaining not being able to conceive after 10 years of marriage. The patient denied having an erectile or ejaculation problem. He also had regular intercourse with his wife two or three times a week with no lubricant. His wife was 43 years old and had been diagnosed with uterine polyps.

The patient also denied having diabetes, hypertension, history of mumps, orchitis, or undescended testes. He had a history of sperm extraction 9 years ago and no sperm was found at that time. However, 3 months prior to his visit to our clinic, the patient underwent a procedure called FNA Mapping on his testes revealing that there were several spermatozoa at specific sites of his testes (Figure 2). However, the procedure was conduct-



Figure 1. Laser assisted immotile sperm selection (LAISS) procedure

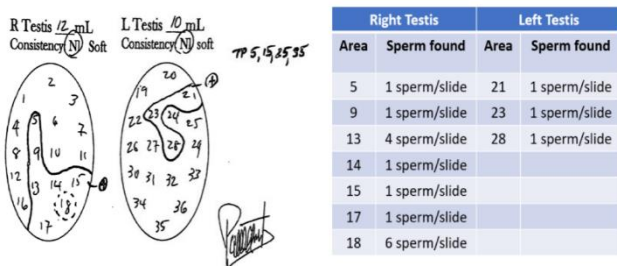


Figure 2. Result of the patient’s fine needle aspiration mapping 3 months before microTESE

ed in Turek Clinic, San Fransisco USA and the patient did not have any plan to stay in USA, thus the fertility program discontinued, and the sperm was not frozen. His medical history was otherwise unremarkable.

Physical examination revealed that the patient had grade II bilateral varicocele. This finding was confirmed by testicular ultrasound, in which the volume of both testes was also evaluated. The volume of his right testis was 8 ml with the longest axis of 3.81 cm whereas the volume of his left testis was 4 ml with the longest axis of 2.69 cm (Confirmed with ultrasound, figure 3).

He was azoospermic with low testosterone level of 2.21 ng/ml and elevated FSH level of 15.64 mIU/ml; he had been treated with Profertil (Clomiphene citrate) and Ovutrig (Human chorionic gonadotropin) for 3 months prior to his visit to our clinic. Also, his Y-chromosome was analyzed for microdeletion and the patient had a microdeletion in the azoospermia factor (AZF)c region (Figure 4).

After further 6 months of hormonal therapy, the patient was still azoospermic with normal testosterone of 5.25 ng/ml and elevated FSH of 22.46 mIU/ml. The patient then underwent sperm extraction at our clinic. First, percutaneous epididymal sperm aspiration (PESA) and microsurgical epididymal sperm aspiration (MESA) were performed on both testes and no sperm was found. After that, the search for viable sperm continued by performing microTESE.

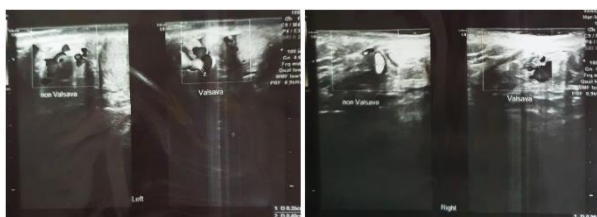

Figure 3. Ultrasound of left testis (Left) and right testis (Right)

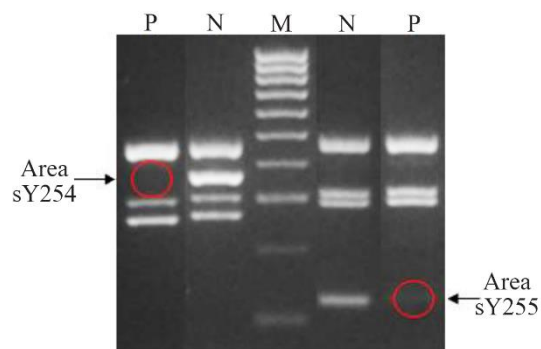


Figure 4. Microdeletion of the patient (P=patient; N=normal; M=marker)

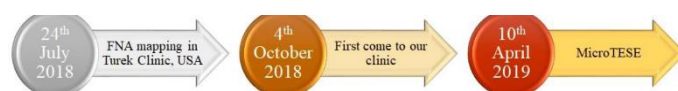

Figure 5. Timeline of the study

Next, microTESE procedure was performed at the specific site of the testes based on the FNA Mapping result in which the sperm was previously found. The procedure was performed on 10th April 2019 (Figure 5). On those sites, the largest tubules were identified and the tubules were analyzed for the spermatozoa under the microscope.

Results

Prior to the microTESE procedure, the patient’s wife was prepared as well. The fertility center managed to gain 6 oocytes, in which only 5 oocytes became mature (M2) and ready to be fertilized. After the patient underwent microTESE procedure, the onsite microscopic examination revealed only 1 motile non-progressive spermatozoa per high-power field (HPF) on the specimen from the right testis (Figure 6).

However, since there were five mature oocytes, the specimens were further examined with LAISS procedure. There were in total 10 spermatozoa with normal morphology tested with LAISS after

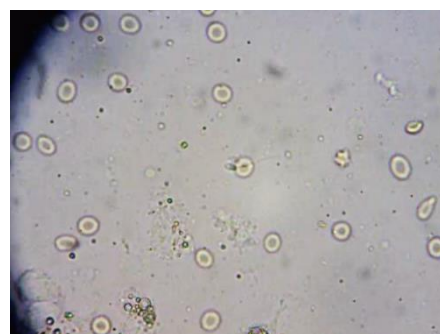


Figure 6. One spermatozoon was found onsite

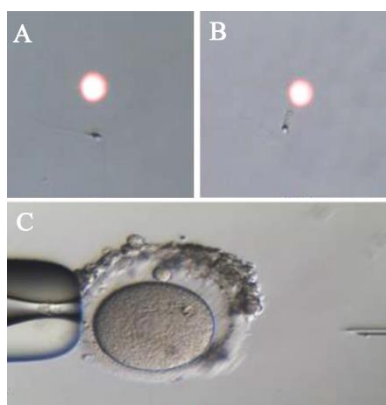


Figure 7. A) Before LAISS procedure; B) After LAISS procedure; C) ICSI procedure. Note that the spermatozoon's tail is curled after LAISS, indicating a viable state of spermatozoon

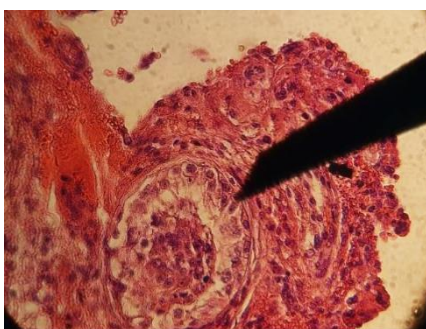


Figure 8. Testicular biopsy revealed few spermatozoa, along with spermatocytes

which only 5 viable spermatozoa were found usable for intracytoplasmic sperm injection (ICSI) to the patient's wife oocytes (Figure 7). Unfortunately, after the procedure, there was no pronucleus found in the oocyte, suggesting that the embryo eventually did not grow and the fertility program discontinued.

In addition, a sample from his testis was taken to be examined in the biology lab and his Johnsen Score was 6.0, with only 3-4 tubules containing spermatid for every 10 tubules examined (Figure 8).

Discussion

In most cases of azoospermia, it is important to determine whether the patient had OA or NOA, since it may influence the choices of therapy. One of the easiest, non-invasive ways to determine whether the patient has OA or NOA is to combine the measurement of testicular long axis and FSH serum level. If the patient has testicular long axis greater than 4.6 cm and FSH serum level of 7.6 IU/L or less, there is a 96% chance of having ob-

structive azoospermia, whereas if the patient's testicular long axis is 4.6 cm or less and FSH serum level is greater than 7.6 IU/L, the patient has approximately 89% chance of having non-obstructive azoospermia or spermatogenic dysfunction (2). Our patient had an elevated level of FSH and small testes. These findings led to diagnosis of NOA.

The next step is to determine the possible known causes including varicocele, hypogonadism, or genetic disorder. Our patient had grade II bilateral varicocele and his hormonal evaluation revealed hypogonadism; he was still being treated on the moment he came to our clinic.

Further analysis of the patient also revealed a microdeletion in Y-chromosome. He had deletion of both loci of the AZFc region (sY254 and sY255) (Figure 4), thus based on the guideline, was still recommended to undergo TESE procedure.

It is interesting to note that before he came to our clinic, he already had a procedure called FNA Mapping on both of his testes. This procedure involves systematic sampling on both testes using needle in a three-dimensional manner. The locations from which the samples were taken are numbered in figure 9 (10).

The purpose of this technique is to locate the site of the testis in which the mature spermatozoa can be found. The result of FNA Mapping on our patient revealed that there were spermatozoa at the site number 5, 9, 13, 14, 15, 17 and 18 on right testis and site number 21, 23, and 28 on left testis.

Recently, Ma et al. managed to formulate an equation to predict the chance of sperm retrieval failure in FNA Mapping as a direct measure of sperm retrieval. The variables included in the formula were age, FSH value and testicular volume with failure risk cut-off value of 64.61%. The sensitivity and specificity of this formula was 0.677 and 0.863 respectively (8). Based on the formula, the risk of failure of our case was 79.25%, which

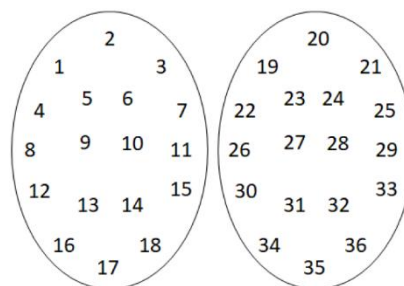


Figure 9. Systematic numbering of testes sampling site

means there was a high chance of retrieval failure.

However, the study above only mentioned the formula to be used as a risk prediction for FNA Mapping as a sperm retrieval method, not a guiding method. Moreover, the study also did not include the AZFc microdeletion when formulating the equation, thus the actual risk of sperm retrieval failure might be different (8).

In addition, a study conducted by Sabbaghian et al. stated that azoospermic patients with AZFc deletion still had a high chance of sperm retrieval success. However, the pregnancy and delivery rates were very low (11). These facts were in accordance with our case which showed that 5 viable spermatozoa were successfully retrieved at positive FNA Mapping sites, but the embryo did not develop.

Another possible reason for the fertilization failure in our case was the possibility of low-quality spermatozoa selected by LAISS procedure. A study by Aktan et al. described that the fertilization rate of spermatozoa selected using LAISS was 45.4%, with the pregnancy and live-birth rate of 25% and 19%, respectively. However, the same study also stated that LAISS technique still has benefit for the patients (12).

The limitation of our study is that the study design was a case report, with only one case available. Therefore, more studies with larger sample size are still needed to further confirm the efficacy of FNA Mapping and microTESE combination in treating NOA patients. Nevertheless, this study provided a novel treatment to be offered for the couples joining the fertility program.

Conclusion

FNA Mapping is a novel and useful technique to precisely locate the sperm in testes before extraction. Combination of FNA Mapping with microTESE technique increases the likelihood of a successful extraction, even after a previously failed TESE procedure.

Acknowledgement

The authors would acknowledge the support of Cipto Mangunkusumo hospital, the Indonesian Reproductive Science Institute of Bunda General hospital, and the Turek Clinic from San Francisco, USA for making it possible to publish this article.

Conflict of Interest

The authors declare that there is no conflict of

interest in the production of this article.

References

1. Jungwirth A, Diemer T, Kopa Z, Krausz C, Minhas S, Tournaye H. EAU guidelines on male infertility. 1st ed. The Netherlands: EAU Guidelines Office; 2018. 48 p.
2. Wein AJ, Kavoussi LR, Partin AW, Peters CA. Campbell-Walsh Urology. 11th ed. Philadelphia PA: Elsevier, Inc.; 2016. 596 p.
3. Salehi P, Derakhshan-Horeh M, Nadeali Z, Hosseinzadeh M, Sadeghi E, Izadpanahi MH, et al. Factors influencing sperm retrieval following testicular sperm extraction in nonobstructive azoospermia patients. *Clin Exp Reprod Med*. 2017;44(1):22-7.
4. Shah R, Gupta C. Advances in sperm retrieval techniques in azoospermic men: a systematic review. *Arab J Urol*. 2017;16(1):125-31.
5. Liu T, Song YX, Jiang YM. Early detection of Y chromosome microdeletions in infertile men is helpful to guide clinical reproductive treatments in southwest of China. *Medicine (Baltimore)*. 2019;98(5):e14350.
6. Birowo P, Putra DE, Dewi M, Rasyid N, Taher A. Y-chromosomal microdeletion in idiopathic azoospermic and severe oligozoospermic Indonesian men. *Acta Med Indones*. 2017;49(1):17-23.
7. Jarvis S, Yee HK, Thomas N, Cha I, Prasad KC, Ramsay JW, et al. Sperm fine-needle aspiration (FNA) mapping after failed microdissection testicular sperm extraction (TESE): location and patterns of found sperm. *Asian J Androl*. 2018;21(1):50-5.
8. Ma Y, Li F, Wang L, Zhao W, Li D, Xian Y, et al. A risk prediction model of sperm retrieval failure with fine needle aspiration in males with non-obstructive azoospermia. *Hum Reprod*. 2019;34(2):200-8.
9. Verheyen G, Todorovic BP, Tournaye H. Processing and selection of surgical-retrieved sperm for ICSI: a review. *Basic Clin Androl*. 2017;27:6.
10. Beliveau ME, Turek PJ. The value of testicular 'mapping' in men with non-obstructive azoospermia. *Asian J Androl*. 2011;13(2):225-30.
11. Sabbaghian M, Meybodi AM, Rafee A, Saba S, Zamanian M, Gilani MAS. Sperm retrieval rate and reproductive outcome of infertile men with azoospermia factor c deletion. *Andrologia*. 2018;50(7):e13052.
12. Aktan TM, Montag M, Duman S, Gorkemli H, Rink K, Yurdakul T. Use of a laser to detect viable but immotile spermatozoa. *Andrologia*. 2004;36(6):366-9.